

Original Article

Toll-like receptor 4 implicated in acute lung injury induced by paraquat poisoning in mice

Wei Liu¹, Li-Ping Shan², Xue-Song Dong¹, Zhi Liu¹

¹Department of Emergency, First Affiliated Hospital of China Medical University, Shenyang, China; ²Department of Urologic Surgery, Shengjing Hospital, China Medical University, Shenyang, China

Received August 6, 2014; Accepted August 31, 2014; Epub October 15, 2014; Published October 30, 2014

Abstract: Objective: To investigate the possible relationship and mechanism of Toll-like receptor 4 (TLR4) and acute lung injury induced by paraquat (PQ) poisoning. Methods: Male wild type mice and male TLR4-knockout mice were used in this study. After paraquat treatment for 24 hours, mice were euthanized and pathology, TLR4 expression and pro-inflammatory cytokines were evaluated. Results: Wild type mice showed deteriorated lung injury, pathological damages and increased TLR4 expression and pulmonary TNF- α , IL-1 β and NF- κ B p65 levels after PQ treatment. TLR4-deficient mice were significantly resistant to paraquat-induced lung injury. Conclusion: TLR4 may be required as a mediator and may play an important role in acute lung injury induced by paraquat.

Keywords: Paraquat, poisoning, acute lung injury, Toll-like receptor 4, inflammation

Introduction

Paraquat (PQ) is the most widely used herbicide in the world [1]. It is the most lethal pesticide, with a mortality of nearly 60-80% when ingested by humans [2]. PQ is absorbed into the bloodstream through the gastrointestinal tract and concentrates primarily in the lungs [3]. Lung concentrations are 10 to 90 times higher than in the bloodstream [4]. Thus, lung injury is particularly severe with rapid progression after PQ poisoning. Rapid emergence of early pulmonary edema, pulmonary hemorrhage and atelectasis develops into irreversible pulmonary fibrosis, which is the primary cause of death [5]. However, the mechanism of paraquat poisoning is not yet fully understood and there is no effective antagonist treatment. Therefore, studying the mechanism and treatment of PQ poisoning is important.

Toll-like receptor 4 (TLR4) is an innate immune system cell transmembrane receptor and a pathogen pattern recognition receptor. It plays an important role in regulating acute inflammatory responses, cell signaling transduction and apoptosis. TLR4 can mediate production of inflammatory cytokines, such as tumor necro-

sis factor- α (TNF- α), interleukin-6 (IL-6) and interleukin-1 β (IL-1 β), and participates in inflammatory signal transduction and proinflammatory responses [6]. Studies have shown that TLR4 can promote the release of inflammatory mediators, resulting in increased damage during the process of acute lung injury (ALI) induced by LPS or other non-inflammatory factors [7, 8].

To date, there have been no studies relating TLR4 expression and ALI induced by PQ poisoning. We investigated the possible mechanisms of TLR4 in PQ-induced ALI using wild type (WT) and TLR4 knockout (TLR4-ko) mice.

Materials and methods

Animals

Male wild type C57BL/6J mice (8 to 10 weeks old, weighing 18 to 22 g) and male TLR4-knockout mice (TLR4-ko, C57BL/10ScN) were purchased from the animal facility at China Medical University. All animals were housed with a daily 12 h illumination cycle and free access to standard feed and water. All procedures involving animals were approved and performed in accordance with the guidelines provided by the institutional ethics commission.

TLR4 implicated in ALI induced by paraquat

Table 1. Results of arterial blood gas analysis

Groups	PH value	PO ₂ (mmHg)	PCO ₂ (mmHg)
WT control group	7.37 ± 0.03	93.2 ± 4.1	40.3 ± 2.1
TLR4-ko group	7.38 ± 0.02	93.5 ± 4.5	40.5 ± 2.4
WT+PQ group	7.38 ± 0.03	60.4 ± 5.3*	26.1 ± 2.6*
TLR4-ko+PQ group	7.36 ± 0.04	75.6 ± 4.8†	32.2 ± 3.3†

Data are expressed as mean±SD, n=10. *P < 0.05 compared with WT control group; †P < 0.05 compared with WT+PQ group.

Experimental design

There were four groups in the experiment as follows: (1) WT (WT mice treated with saline, n=10); (2) TLR4 gene knockout (TLR4-ko mice treated with saline, n=10); (3) WT+PQ (WT mice treated with PQ, n=10); and (4) TLR4-ko+PQ (TLR4-ko mice treated with PQ, n=10). Mice in Group (3) and Group (4) were injected intraperitoneally with 40 mg/kg of PQ (Sigma, St. Louis, MO, USA). Mice in Group (1) and Group (2) were injected intraperitoneally with saline at volumes equivalent to the PQ dosage. After 24 h, all mice were euthanized by exsanguination of the abdominal aorta under deep anesthesia, and 0.2 ml of blood was collected for blood gas analysis. Lung tissue specimens were quickly removed. Lower left lung tissue specimens were fixed in 40 g/L paraformaldehyde for histological analysis. Upper left lung tissue was snap-frozen in liquid nitrogen and stored at -70°C for RNA extraction and western blot analysis. Right lung tissue specimens were snap-frozen at -70°C to detect TNF- α , IL-1 β and NF- κ B p65 protein concentrations.

Histopathologic observation

Lung samples were fixed with 4% paraformaldehyde at 4°C for 24 h and embedded in paraffin, and 4 μ m sections were stained with hematoxylin and eosin for light microscopy.

Real-time quantitative PCR analysis

Lung tissue (20 mg) was snap-frozen in liquid nitrogen and stored at -70°C for RNA extraction. Total lung RNA was extracted using RNAiso reagent (Baoxin Biotechnology Co. Ltd., China) according to the manufacturer's instructions. Total RNA was determined by OD260 measurements. cDNA was synthesized from total RNA using the SYBR PrimeScript RT-PCR kit (Baoxin Biotechnology Co. Ltd., China) and qPCR was

performed on a Prism 7500 Fast PCR System (Applied Biosystems, Inc., USA). mRNA expression was assayed using the following primers: TLR4 sense, 5'-CAGCA-AAGTCCCTGATGACA-3' and antisense, 5'-CCTGGGGAAAACTCTGGAT-3'; GAPDH sense, 5'-TGTGTCCGTCGTGGATCTGA-3' and antisense, 5'-TTGCTGTTGAAGTCGCA-GGAG-3'.

Amplification of TLR4 mRNA required an initial denaturation step at 94°C for 30 s. Temperature cycling consisted of 40 cycles of denaturation at 95°C for 5 s, annealing at 60°C for 60 s, and elongation at 72°C for 90 s. Transcript levels were normalized by comparison with GAPDH using the 2^{- $\Delta\Delta$ CT} method.

Western blot analysis

Lung tissue (20 mg) was homogenized with RIPA buffer. The supernatant was collected to determine protein concentration using a protein assay kit (Beyotime Institute of Biotechnology, China). Samples were diluted to appropriate concentrations, and 20 μ g of each were separated on 12% sodium dodecyl sulfate-polyacrylamide gels, followed by electrophoretic transfer to a nitrocellulose membrane. Membranes were blocked with 5% skimmed milk in a Tris-buffered saline solution containing 0.1% Tween20 and probed with rabbit anti-mouse TLR4 antibody (1:200; Santa Cruz Biotechnology, USA) for 60 min at 4°C. After washing, horseradish peroxidase-coupled sheep anti-rabbit IgG monoclonal antibody (1:500, Wuhan Boster Bio-Engineering Co., Ltd., China) was applied. Proteins were detected by an enhanced chemiluminescence kit (Pierce, USA) according to the manufacturer's instructions and quantified by densitometry analysis using Image-Pro Plus software (Media Cybernetics, Inc., USA). Density ratios of each band were determined by comparison to WT control bands.

TNF- α , IL-1 β and NF- κ B p65 protein levels in lung tissues

Lung tissues were collected and washed in saline and homogenized immediately on ice in 1 ml saline (4°C). Homogenates were centrifuged at 3000 g at 4°C for 15 min. TNF- α , IL-1 β and NF- κ B p65 protein levels were measured

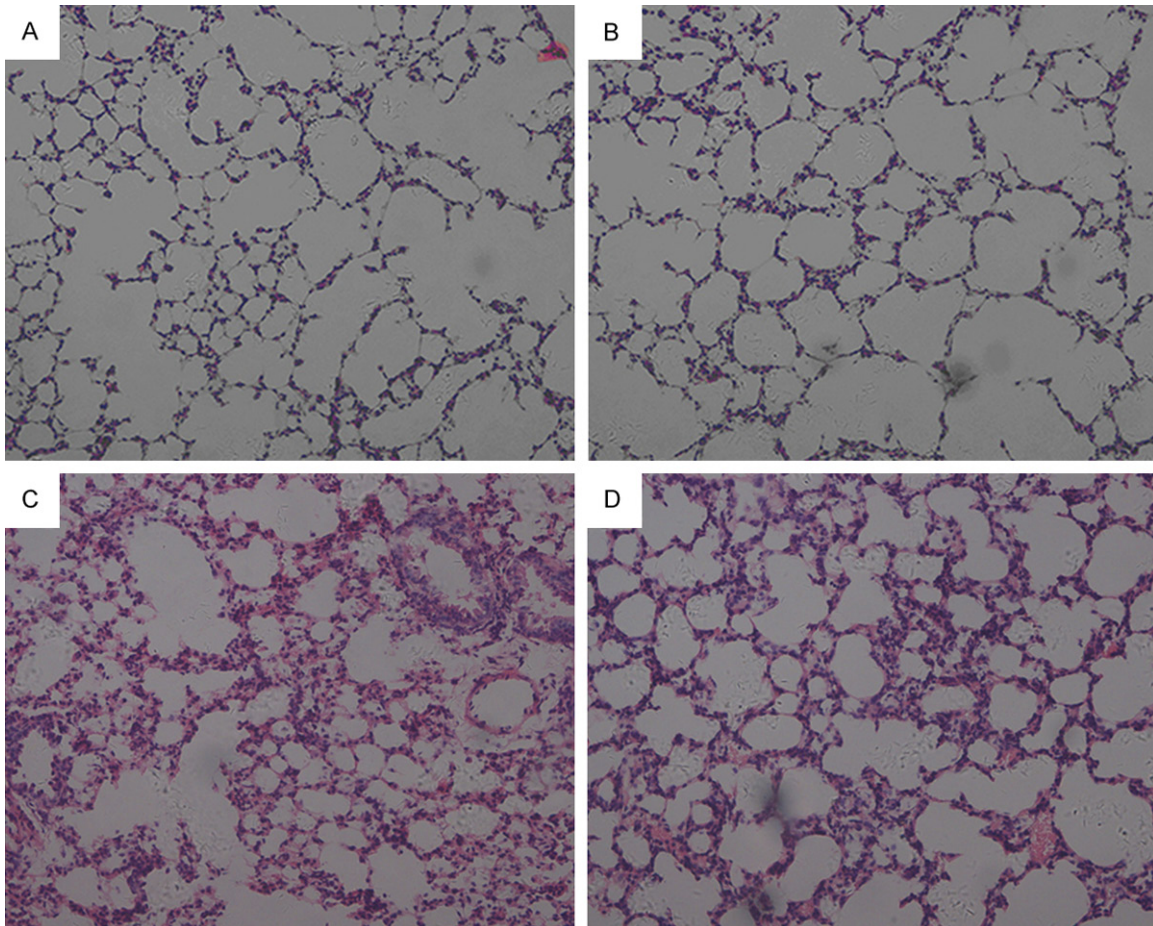


Figure 1. Photomicrographs of lung sections from the WT control group (A), the TLR4-ko group (B), the WT+PQ group (C) and the TLR4-ko+PQ group (D). Morphology was similar in the WT and TLR4-ko groups without PQ treatment (A, B). Obvious pathological changes were observed in the WT+PQ group, including infiltration of many inflammatory cells, destruction of alveolar walls, hemorrhage of alveolar and pulmonary interstitial and thickening of alveolar walls (C). Pathological changes were significantly attenuated in TLR4-ko+PQ mice compared with the WT+PQ group (D). Hematoxylin and eosin staining (200 \times).

with a commercial ELISA kit following the manufacturer's instructions (Wuhan Boster Bio-Engineering Co., Ltd., Wuhan, China). Absorbance was read on a microplate reader and concentrations were calculated according to the standard curve (Dynex MRX, USA) (450 nm wavelength). Protein content in the sample was determined by Coomassie blue assay and corrected per microgram of protein.

Statistical analysis

Results are expressed as the mean \pm SD. Statistical analyses were performed using SPSS 15.0 software. One-way analysis of variance was used to establish whether differences among the four groups were statistically significant. $P < 0.05$ was considered statistically significant.

Results

Arterial blood gas analysis

Knockout of TLR4 did not affect the results of arterial blood gas analysis, including PO_2 , PCO_2 and PH values. After PQ treatment, PO_2 and PCO_2 decreased significantly in the WT+PQ and TLR4-ko+PQ groups compared with the control group ($P < 0.05$). The decrease in PO_2 and PCO_2 was significantly attenuated in the TLR4-ko+PQ group compared with the WT+PQ group ($P < 0.05$). There was no significant difference in PH values between the four groups (**Table 1**).

Histopathology

Lung morphology was similar in the WT and TLR4-ko groups without PQ treatment. Obvious pathological changes were observed in WT

TLR4 implicated in ALI induced by paraquat

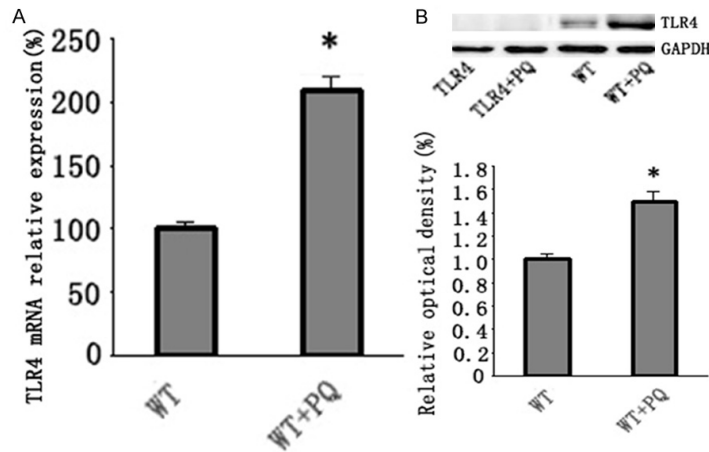


Figure 2. TLR4 mRNA expression and protein levels in different groups. A. TLR4 mRNA expression in the lungs of WT and WT+PQ mice. Total RNA extracted from the lung tissue of mice in the WT and WT+PQ groups; B. Western blot analysis of TLR4 at the protein level. GAPDH was used as an internal control. Bar graphs show the relative intensity of each band compared to WT control group as measured by densitometry. Data are expressed as the mean \pm SD, n=10. * $P < 0.05$ compared with the WT group.

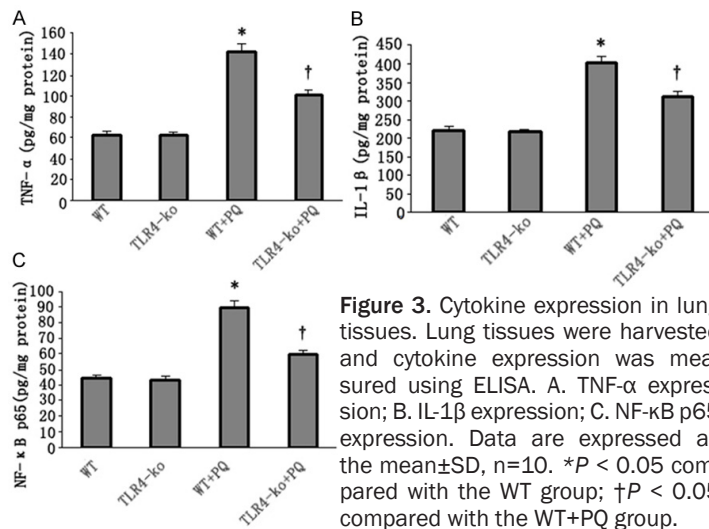


Figure 3. Cytokine expression in lung tissues. Lung tissues were harvested and cytokine expression was measured using ELISA. A. TNF- α expression; B. IL-1 β expression; C. NF- κ B p65 expression. Data are expressed as the mean \pm SD, n=10. * $P < 0.05$ compared with the WT group; † $P < 0.05$ compared with the WT+PQ group.

mice after PQ treatment, including infiltration of inflammatory cells, destruction of alveolar walls, hemorrhage of alveolar and pulmonary interstitial and thickening of alveolar walls. Pathological changes were significantly attenuated in PQ-treated TLR4-ko mice (**Figure 1A-D**).

TLR4 expression in lung tissues

TLR4 mRNA levels in the WT and WT+PQ groups are shown in **Figure 2A**. TLR4 mRNA levels increased significantly after PQ treatment, as did protein levels in western blot analysis com-

pared with WT groups ($P < 0.05$). In contrast, the TLR4 protein was not detected in TLR4-ko mice (**Figure 2B**).

TNF- α , IL-1 β and NF- κ B p65 levels in lung tissues

Deletion of TLR4 did not affect cytokine levels in lung tissue in TLR4-ko group. When treated with PQ, TNF- α , IL-1 β and NF- κ B p65 protein levels increased significantly in the WT+PQ and TLR4-ko+PQ groups ($P < 0.05$). However, TNF- α , IL-1 β and NF- κ B p65 protein levels were significantly attenuated in TLR4-ko mice following PQ exposure compared with the WT+PQ group ($P < 0.05$; **Figure 3**).

Discussion

Although many studies have reported on PQ poisoning, the pathogenesis of lung injury due to PQ poisoning has not been fully elucidated and effective therapies have not been discovered [9-11]. PQ poisoning has the highest mortality rate of pesticide poisonings, particularly in China. Acute lung injury and lung fibrosis are the most serious complications and are key factors in determining the prognosis [12].

In this experiment, WT and TLR4 gene knockout mice were used to investigate early stage lung injury after PQ poisoning. At 24 h after PQ injection, obvious microscopic lung damage was evident (**Figure 1**), followed by a remarkable reduction in PO_2 and PCO_2 in the WT+PQ group compared with the control group. This is consistent with clinical manifestations, such as shortness of breath and dyspnea, in PQ poisoning patients. Lung injury improved significantly in TLR4-ko mice after PQ exposure, indicating that TLR4 is involved in lung injury induced by PQ.

TLR4 is an innate immune system cell transmembrane receptor and has been well documented as a pattern recognition receptor in

acute infection-induced lung injury [13, 14]. TLR4 can be activated by exogenous ligands, such as lipopolysaccharides from Gram-negative bacteria [15-17] and endogenous ligands from necrotic cells including heat-shock proteins (HSP60 and HSP70) [18, 19], from extracellular matrix components. This pathway is characterized by early formation of MyD88, IL-1 related protein kinase (IRAK) and early activation of NF- κ B and mitogen-activated protein kinase (MAPK) through the myeloid differentiation protein 88 (MyD88)-dependent pathway.

Previous studies have reported that TLR4 can promote the release of inflammatory mediators through the MyD88-dependent pathway, resulting in increased lung injury in the process of ALI induced by LPS [7, 8]. In our study, TLR4 mRNA and protein levels increased significantly in the WT group after PQ treatment, followed by severe lung injury. However, lung injury was significantly attenuated in the absence of the TLR4 gene. The results indicate that TLR4 is activated in the lungs by overexpression and aggravated lung injury during PQ poisoning and that TLR4 gene knockout can improve lung injury.

Although many mechanisms contribute to the pathogenesis of lung injury induced by PQ poisoning, activation of pro-inflammatory pathways plays a vital role. However, the mechanisms by which these pro-inflammatory pathways are activated are not fully understood. Previous experiments demonstrated that IL-1 β and IL-6 expression progressively increased after PQ treatment [20]. Our experimental results show that 24 h after intraperitoneal injection of PQ in WT mice, a large number of neutrophils infiltrated into lung tissue, accompanied by a significant increase in NF- κ B, TNF- α and IL-1 β expression. In the TLR4-ko group, NF- κ B, TNF- α and IL-1 β expression decreased with similar neutrophil infiltration.

It is widely accepted that PQ can induce a cascade of redox reactions and release reactive oxygen species, resulting in lipid peroxidation and cell damage [5]. In addition, it has been reported that TLR4 can be activated by endogenous ligands released during cellular injury (damage-associated molecular patterns, DAMPs) [21-23]. We speculate that alveolar epithelial cells and vascular endothelial cells are damaged after PQ treatment and that the damaged

cells form DAMPs, which activate the TLR4 signaling pathway. TLR4 activation results in an excessive inflammatory response and lung injury. Knockout of the TLR4 gene may block the TLR4 signaling pathway and reduce overexpression of NF- κ B, TNF- α and IL-1 β , ultimately protecting the lungs from PQ poisoning.

To our knowledge, this is the first report to directly implicate TLR4 signaling in lung injury and inflammation induced by PQ. Our data confirm that TLR4 participates in lung injury after PQ exposure. Considering that the immune response occurs soon after PQ poisoning, it would be useful to develop new therapies that inhibit TLR4 signaling via neutralizing antibodies or antagonist drugs to reduce lung injury from PQ exposure.

Acknowledgements

This work was supported by National Natural Science Foundation of China (No. 81101415).

Disclosure of conflict of interest

None.

Address correspondence to: Dr. Zhi Liu, Department of Emergency, First Affiliated Hospital of China Medical University, 155 North Street of Nanjing, Shenyang, China. Tel: +86-024-83283055; Fax: +86-024-83282011; E-mail: lzszy2014@163.com

References

- [1] Serra A, Domingos F, Prat MM. Paraquat intoxication. *Acta Med Port* 2003; 16: 25-32.
- [2] Bertolote JM, Fleischmann A. Deaths from pesticide poisoning: a global response. *Br J Psych* 2006; 189: 201-203.
- [3] Dinis-Oliveira RJ, De Jesús Valle MJ, Bastos ML. Kinetics of paraquat in the isolated rat lung: influence of sodium depletion. *Xenobiotica* 2006; 36: 724-737.
- [4] Chen CM, Lua AC. Lung toxicity of paraquat in the rat. *J Toxicol Environ Health A* 2000; 60: 477-487.
- [5] Dinis-Oliveira RJ, Duarte JA, Sánchez-Navarro A, Remião F, Bastos ML, Carvalho F. Paraquat poisonings: mechanisms of lung toxicity, clinical features and treatment. *Crit Rev Toxicol* 2008; 38: 13-71.
- [6] Zhou B, Zhou H, Ling S, Guo D, Yan Y, Zhou F, Wu Y. Activation of PAR2 or/and TLR4 promotes SW620 cell proliferation and migration via phosphorylation of ERK1/2. *Oncol Rep* 2011; 25: 503-511.

TLR4 implicated in ALI induced by paraquat

- [7] Hoth JJ, Wells JD, Brownlee NA, Hiltbold EM, Meredith JW, McCall CE, Yoza BK. Toll-like receptor 4 dependent responses to lung injury in a murine model of pulmonary contusion. *Shock* 2009; 31: 376-381.
- [8] Villar J, Cabrera N, Casula M. Mechanical ventilation modulates Toll-like receptor signaling pathway in a sepsis-induced lung injury model. *Intensive Care Med* 2010; 36: 1049-1057.
- [9] Mydlík M, Derzsiová K, Frank K. Renal replacement therapy in acute poisonings-one center experience. *Przegl Lek* 2013; 70: 381-385.
- [10] Chang JB, Lin CC, Chiou JF, Mau SY, Liu TZ, Chen CH. Treatment of acute paraquat intoxication using recommended megadose of vitamin C: a reappraisal. *Free Radic Res* 2013; 47: 991-1001.
- [11] Yang H, Wen Y, Hou-you Y, Yu-tong W, Chuanming L, Jian X, Lu H. Combined treatment with bone marrow mesenchymal stem cells and methylprednisolone in paraquat-induced acute lung injury. *BMC Emerg Med* 2013; 13 Suppl 1: S5.
- [12] Whitehead GS, Grasman KA, Kimmel EC. Lung function and airway inflammation in rats following exposure to combustion products of carbon-graphite/epoxy composite material: comparison to a rodent model of acute lung injury. *Toxicology* 2013; 83: 175-197.
- [13] Akira S. Mammalian Toll-like receptors. *Curr Opin Immunol* 2003; 15: 5-11.
- [14] Medzhitov R, Janeway C Jr. Innate immunity. *N Engl J Med* 2000; 343: 338-344.
- [15] Poltorak A, He X, Smirnova I, Liu MY, Van Huffel C, Du X, Birdwell D, Alejos E, Silva M, Galanos C, Freudenberg M, Ricciardi-Castagnoli P, Layton B, Beutler B. Defective LPS signaling in C3H/HeJ and C57BL/10ScCr mice: mutations in TLR4 gene. *Science* 1998; 282: 2085-2088.
- [16] Qureshi ST, Lariviere L, Leveque G, Clermont S, Moore KJ, Gros P, Malo D. Endotoxin-tolerant mice have mutations in Toll-like receptor 4(Tlr4). *J Exp Med* 1999; 189: 615-625.
- [17] Laflamme N, Rivest S. Toll-like receptor 4: the missing link of the cerebral innate immune response triggered by circulating gram-negative bacterial cell wall components. *FASEB J* 2001; 15: 155-163.
- [18] Ohashi K, Burkart V, Flohe S, Kolb H. Cutting edge: heat shock protein 60 is a putative endogenous ligand of the toll-like receptor-4 complex. *J Immunol* 2000; 164: 558-561.
- [19] Bulut Y, Faure E, Thomas L, Karahashi H, Michelsen KS, Equils O, Morrison SG, Morrison RP, Arditi M. Chlamydial heat shock protein 60 activates macrophages and endothelial cells through Toll-like receptor 4 and MD2 in a MyD88-dependent pathway. *J Immunol* 2002; 168: 1435-1440.
- [20] Jian XD, Li M, Zhang YJ. Role of growth factors in acute lung injury induced by paraquat in a rat model. *Hum Exp Toxicol* 2011; 30: 460-469.
- [21] Wu HS, Zhang JX, Wang L, Tian Y, Wang H. Toll-like receptor 4 involvement in hepatic ischemia/reperfusion injury in mice. *Hepatobiliary Pancreat Dis Int* 2004; 3: 250-253.
- [22] Tsung A, Hoffman RA, Izuishi K, Critchlow ND, Nakao A. Hepatic ischemia/reperfusion injury involves functional TLR4 signaling in non-parenchymal cells. *J Immunol* 2005; 175: 7661-7668.
- [23] Oyama JI, Blais C, Liu X, Pu M, Kobzik L. Reduced myocardial ischemia-reperfusion injury in toll-like receptor 4-deficient mice. *Circulation* 2004; 109: 784-789.