

Case Report

Massive plasmacytosis with severe marrow suppression induced by methimazole in Graves' disease patients: case report and literature review

Feng Xiao, Chenying Li, Liangshun You, Wenbing Qian, Juying Wei

Department of Hematology, The First Affiliated Hospital, Zhejiang University, College of Medicine, Hangzhou, China

Received April 29, 2014; Accepted May 11, 2014; Epub October 15, 2014; Published October 30, 2014

Abstract: Antithyroid drugs (ATDs) induced leukopenia is commonly seen, but life-threatening agranulocytosis is a rare occurrence. Interestingly, agranulocytosis accompanied with plasmacytosis in bone marrow (BM) is rarer. In this study, we admitted a patient with Graves' disease who had been treated with 15 mg/d methimazole (MMI) for 42 days. She presented with agranulocytosis and plasmacytosis in bone marrow (BM). The patient withdrew taking MMI and was treated with broad-spectrum antibiotics and G-CSF. After two weeks, the patient's peripheral blood improvement was achieved and BM nearly returned to normal level. The case provides evidence that the elder patients with a high dose of MMI treatment are prone to develop agranulocytosis, especially the duration of treatment is longer than three months. We summarize the literatures, and propose our new viewpoint on the mechanism of plasmacytosis in ATDs-induced agranulocytosis patients.

Keywords: Plasmacytosis, bone marrow suppression, methimazole, Grave's disease

Introduction

Graves' disease is an autoimmune disorder that produces antibodies against the thyroid stimulation hormone receptor [1]. According to the management guidelines of the American Thyroid Association, there are three treatment methods including antithyroid medication, ¹³¹I therapy and thyroidectomy [2]. Although leukopenia is a common side effect induced by ATDs, the occurrence of life-threatening agranulocytosis is rare (ranging between 0.1% and 1%) [3], and only three former cases reported methimazole-induced agranulocytosis accompanied with plasmacytosis in BM. We present a Graves' disease patient, who suffered from pancytopenia and massive plasmacytosis after MMI treatment, and point out our hypothesis that may the Interleukin-6 be associated with MMI-induced BM toxicity, which result in massive plasmacytosis in BM.

Case report

We admitted a 32-year-old patient with Graves' disease, who had been treated with 15 mg/d

MMI for 42 days. She presented with sore throat and high-grade fever. Physical examination revealed: high fever (40°C), mild anemia, grade II tonsil enlargement with white secretion, moderate thyroid enlargement. Throat smear showed moderate G⁻ bacilli and little G⁺ cocci. and throat bacterial culture indicated staphylococcus aureus. The patient was treated with broad-spectrum antibiotics (cefoperazone sodium, sulbactam sodium and vancomycin) and G-CSF. However, the patient's condition from bad to worse, the peripheral blood count showed a progressive depression and the globulins increased. On day+10 globulins peaked 56 g/L and CBC as follows: leukocytes $0.6 \times 10^9/L$, neutrophils $0 \times 10^9/L$, platelets $20 \times 10^9/L$, hemoglobin 97 g/dL. What's more, the bone marrow (BM) on day+12 showed hypocellular, 61% plasma cells which were mature (**Figure 1A**), immunoelectrophoresis of serum showed polyclonal increases (IgG and IgA).

The patient's condition improved and the temperature declined to normal on day+17. Peripheral blood improvement was achieved:

Plasmacytosis and bone suppression in Grave's disease

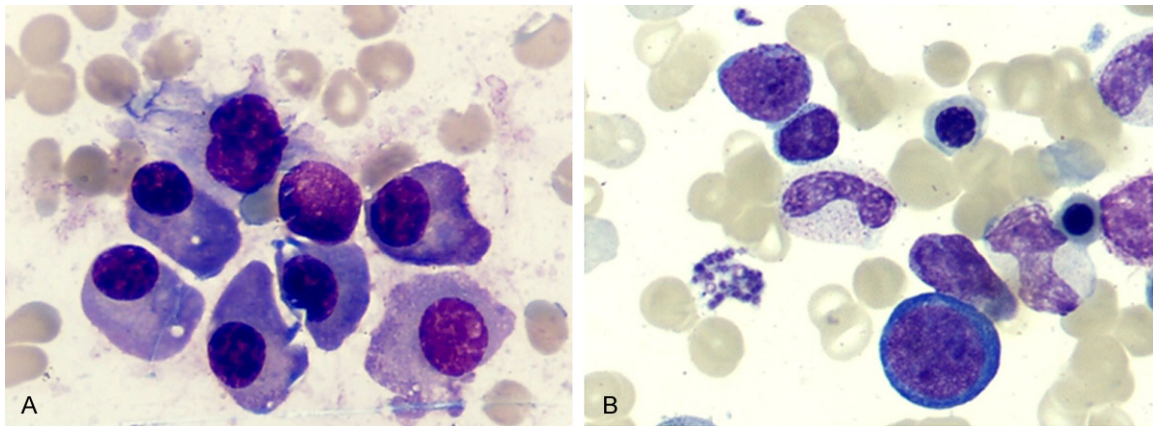


Figure 1. Morphology of BM. A: Mature plasma cells were 61% (on day+12). B: Increased nucleated cells, myeloid hyperplasia with nuclei left (on day+26), ($\times 100$).

Table 1. Agranulocytosis Accompanied with Plasmacytosis Cases Induced by ATDs

Case (reference No.)	1 (12)	2 (3)	3 (13)	4 (our case)
Age/gender	53 F	16 F	40 M	32 F
ATDs/duration	MMI 30 mg 4 w	MMI 30 mg 4 w	MMI 20 mg 50 d	MMI 15 mg 42 d
BM	Hypoplasia with plasmacytosis	Hypoplasia with massive plasmacytosis (98% of plasma cells)	Hypoplasia with plasmacytosis (25% of plasma cells)	Hypoplasia with massive plasmacytosis (61% of plasma cells)
Immunoelectrophoresis of serum	polyclonal increases of IgG, IgA, I, k with normal IgM	polyclonal increases of IgG, IgA, I, k with normal IgM	polyclonal increases of hypergammaglobulins	polyclonal increases of IgG, IgA, I, k with normal IgM
Neutro ($/\mu\text{l}$) At admission	< 100	< 50	< 20	< 20
G-CSF/GM-CSF	+	+	+	+
Steroid	+	+	+	-
Duration until neutron > 1000/ μl	36 days	7 days	8 days	19 days
Duration until platelets > 50000/ μl	19 days	24 days	8 days	16 days
Next Therapy	^{131}I	^{131}I	Unknown	^{131}I

ATD: antithyroid drug; w: week; MMI: methimazole; BM: bone marrow; G-CSF: granulocyte colony-stimulating factor; GM-CSF: granulocyte-macrophage colony-stimulating factor.

granulocytes > 1000 on day+19, platelets > 50 000 on day+16. BM on day+26 showed increased nucleated cells, myeloid hyperplasia with nuclei left (**Figure 1B**). The patient was treated with ^{131}I after 3 months. The follow-up tests including CBC and BM (morphology and cytogenetics) remained normal after twenty four months.

Discussion

It was reported that the dose, duration of treatment and patient characteristics were involved in MMI-induced agranulocytosis. McGavack *et al.* reported that the patients with MMI treatment at the dose of 30 to 60 mg/d, the agranulocytosis rate was only 1.0% [4], and the studies from Wiberg *et al.* showed that treatment with higher dose MMI (120 mg/d), the agranu-

locytosis rate rise to 8% [5]. Hirotooshi *et al.* analyzed 754 cases of ATDs-induced agranulocytosis over 30 years in Japan found that the rare of agranulocytosis was correlation with the duration of treatment (71.6% patients within 60 days and 84.6% within 90 days) [6]. Moreover, a retrospective analysis showed that in older than 40 s patients, the risk of MMI-induced agranulocytosis was 6.4-fold than the youngsters [7]. Therefore, we can conclude that the elder patients with a high dose of MMI treatment are prone to develop agranulocytosis, especially the duration of treatment reach three months.

The most frequently treating agents to ATDs-agranulocytosis are steroids and granulocyte colony-stimulating factor (G-CSF). Some studies reported that G-CSF was effective in treat-

ment with MMI-induced agranulocytosis [8-11], especially in mild and moderate patients. In our study, the patient who treated with MMI (15 mg/d) for 42 days was presented with agranulocytosis, The measure of G-CSF treatment was taken in time, the patient's condition improved on day+17. More interestingly, another BM toxicity emerged in the case was the massive plasmacytosis (61%) in BM, which is seldom in our clinical work. We also find three other similar cases about MMI-induced agranulocytosis accompanied with plasmacytosis in BM (Table 1) [3, 12, 13]. As shown in the table, all four patients presented with agranulocytosis, polyclonal increase of globulins and plasmacytosis in BM. Thus, there comes the question why the patients with Graves' disease are prone to develop plasmacytosis when they are in MMI-induced agranulocytosis.

Some evidences demonstrate that the interleukin-6 (IL-6) play an important role in the association between plasmacytosis and hyperthyroidism. IL-6, a secreted 21-kDa glycoprotein, produced by CD40- and IL-10-stimulated B cells, can not only participate in the differentiation of B cells into plasma cells [14], but also affect the generation of plasma cells which was testified in knockout mice [15]. As we all know, IL-6 has pleiotropic effects and its dysfunction can cause various autoimmune and chronic inflammatory diseases [16]. GD, as an typical autoimmune disease, has been found closely associated with IL-6. Activation of the IL-6 system has been proved in GD [17] and the increased level of IL-6 has been concluded in hyperthyroidism patients [18]. Besides, IL-6 has been detected in thyroid tissues, orbital fat and extraocular muscles [19]. Recently, IL-6 has been reported to be a significantly elevated cytokine in patients with thyroid-associated ophthalmopathy (TAO) [20]. What's more encouraging, an anti-IL-6 antibody was found to suppress plasmablastic cell proliferation in patients with reactive polyclonal plasmacytosis [21]. Therefore, we bring out our hypothesis that the increased level of IL-6 is the mechanism of MMI-induced plasmacytosis in BM.

Further investigations would be needed to demonstrate that IL-6 is the mechanism of MMI-induced plasmacytosis in Grave's disease patients, which could contribute to the prevention and treatment of the rare complication.

Disclosure of conflict of interest

None.

Address correspondence to: Dr. Juying Wei, Department of Hematology, The First Affiliated Hospital, Zhejiang University, College of Medicine, Hangzhou, China. Tel: +86-571-56723004; Fax: +86-571-56723008; E-mail: weijuy@hotmail.com

References

- [1] Prabhakar BS, Bahn RS and Smith TJ. Current perspective on the pathogenesis of Graves' disease and ophthalmopathy. *Endocr Rev* 2003; 24: 802-835.
- [2] Bahn RS, Burch HB, Cooper DS, Garber JR, Greenlee MC, Klein I, Laurberg P, McDougall IR, Montori VM, Rivkees SA, Ross DS, Sosa JA and Stan MN. Hyperthyroidism and other causes of thyrotoxicosis: management guidelines of the American Thyroid Association and American Association of Clinical Endocrinologists. *Endocr Pract* 2011; 17: 456-520.
- [3] Breier DV, Rendo P, Gonzalez J, Shilton G, Stivel M and Goldztein S. Massive plasmacytosis due to methimazole-induced bone marrow toxicity. *Am J Hematol* 2001; 67: 259-261.
- [4] Meyer-Gessner M, Benker G, Lederbogen S, Olbricht T and Reinwein D. Antithyroid drug-induced agranulocytosis: clinical experience with ten patients treated at one institution and review of the literature. *J Endocrinol Invest* 1994; 17: 29-36.
- [5] Wiberg JJ and Nuttall FQ. Methimazole toxicity from high doses. *Ann Intern Med* 1972; 77: 414-416.
- [6] Nakamura H, Miyauchi A, Miyawaki N and Imagawa J. Analysis of 754 cases of antithyroid drug-induced agranulocytosis over 30 years in Japan. *J Clin Endocrinol Metab* 2013; 98: 4776-83.
- [7] Cooper DS, Goldminz D, Levin AA, Ladenson PW, Daniels GH, Molitch ME and Ridgway EC. Agranulocytosis associated with antithyroid drugs. Effects of patient age and drug dose. *Ann Intern Med* 1983; 98: 26-29.
- [8] Tajiri J, Noguchi S, Okamura S, Morita M, Tamaru M, Murakami N and Niho Y. Granulocyte colony-stimulating factor treatment of antithyroid drug-induced granulocytopenia. *Arch Intern Med* 1993; 153: 509-514.
- [9] Fukata S, Kuma K and Sugawara M. Granulocyte colony-stimulating factor (G-CSF) does not improve recovery from antithyroid drug-induced agranulocytosis: a prospective study. *Thyroid* 1999; 9: 29-31.
- [10] Andres E, Kurtz JE, Perrin AE, Dufour P, Schlienger JL and Maloisel F. Haematopoietic growth factor in antithyroid-drug-induced agranulocytosis. *QJM* 2001; 94: 423-428.
- [11] Sprikkelman A, de Wolf JT and Vellenga E. The application of hematopoietic growth factors in drug-induced agranulocytosis: a review of 70 cases. *Leukemia* 1994; 8: 2031-2036.

Plasmacytosis and bone suppression in Grave's disease

- [12] Yamamoto A, Katayama Y, Tomiyama K, Hosoai H, Hirata F, Kimura F, Fujita K and Yasuda H. Methimazole-induced aplastic anemia caused by hypocellular bone marrow with plasmacytosis. *Thyroid* 2004; 14: 231-235.
- [13] Oh EJ, Chae HJ, Park YJ, Park JW and Han K. Agranulocytosis, plasmacytosis, and thrombocytosis due to methimazole-induced bone marrow toxicity. *Am J Hematol* 2007; 82: 500-500.
- [14] Gado K, Domjan G, Hegyesi H and Falus A. Role of INTERLEUKIN-6 in the pathogenesis of multiple myeloma. *Cell Biol Int* 2000; 24: 195-209.
- [15] Pattengale PK. Role of interleukin-6 in the pathogenesis of murine plasmacytoma and human multiple myeloma. *Am J Pathol* 1997; 151: 647-649.
- [16] Tanaka T and Kishimoto T. Immunotherapeutic implication of IL-6 blockade. *Immunotherapy* 2012; 4: 87-105.
- [17] Salvi M, Girasole G, Pedrazzoni M, Passeri M, Giuliani N, Minelli R, Braverman LE and Roti E. Increased serum concentrations of interleukin-6 (IL-6) and soluble IL-6 receptor in patients with Graves' disease. *J Clin Endocrinol Metab* 1996; 81: 2976-2979.
- [18] Pontikides N and Krassas GE. Basic endocrine products of adipose tissue in states of thyroid dysfunction. *Thyroid* 2007; 17: 421-431.
- [19] Hiromatsu Y, Yang D, Bednarczuk T, Miyake I, Nonaka K and Inoue Y. Cytokine profiles in eye muscle tissue and orbital fat tissue from patients with thyroid-associated ophthalmopathy. *J Clin Endocrinol Metab* 2000; 85: 1194-1199.
- [20] Gillespie EF, Raychaudhuri N, Papageorgiou KI, Atkins SJ, Lu Y, Charara LK, Mester T, Smith TJ and Douglas RS. Interleukin-6 production in CD40-engaged fibrocytes in thyroid-associated ophthalmopathy: involvement of Akt and NF-kappaB. *Invest Ophthalmol Vis Sci* 2012; 53: 7746-7753.
- [21] Jourdan M, Bataille R, Seguin J, Zhang XG, Chaptal PA and Klein B. Constitutive production of interleukin-6 and immunologic features in cardiac myxomas. *Arthritis Rheum* 1990; 33: 398-402.