

## Case Report

# A case report for fatal Churg-Strauss syndrome complications: first reported death due to rapid progression of prominently huge hepatic capsular hematoma and multi-system organ hemorrhage

Jiejing Qian, Hongyan Tong, Feifei Chen, Wenyuan Mai, Yinjun Lou, Jie Jin

Department of Hematology, The First Affiliated Hospital, College of Medicine, Zhejiang University, Hangzhou, Zhejiang, People's Republic of China

Received August 13, 2014; Accepted September 20, 2014; Epub October 15, 2014; Published October 30, 2014

**Abstract:** Churg-Strauss syndrome (CSS) is a rare disease that has an extremely low incidence rate. CSS prognosis is good, in general; and there are no reports of multiple-organ hemorrhage in CSS. We report a unique case of CSS, wherein, an elderly man experienced multiple organ hemorrhage – a particularly huge hematoma under the capsule of the liver and poor prognosis.

**Keywords:** Hepatic capsular hematoma, organ hemorrhage, Churg-Strauss syndrome

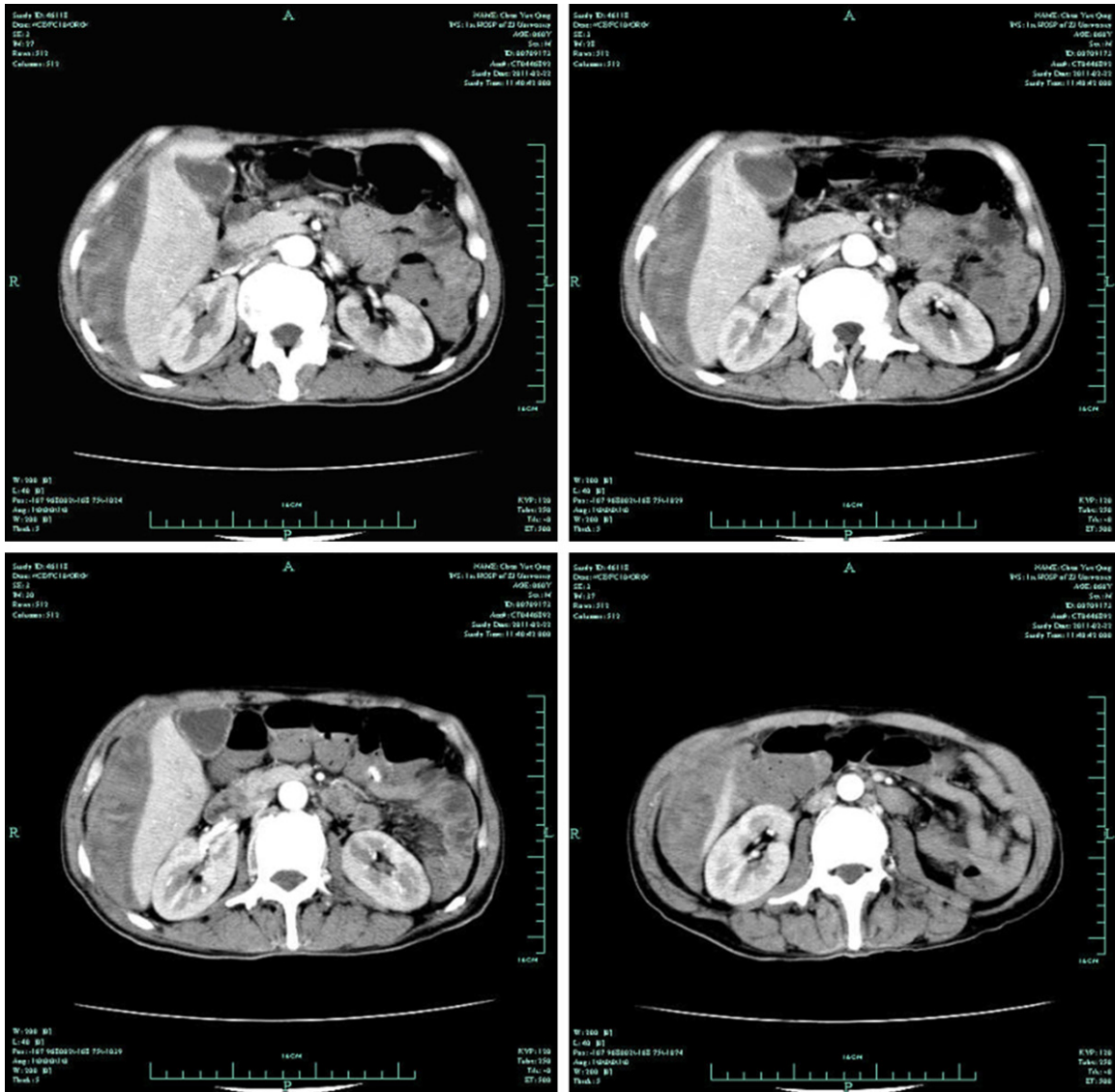
On January 31, 2011, a 60-year-old man was admitted to our department with complaints of left limb numbness and increased eosinophils. The patient had no history of allergy and suffered from mild bronchial asthma during the past 2 years. His temperature was about 37.5°C. Routine blood results revealed that leukocytes were at  $17.3 \times 10^9/L$  (eosinophilia at 42.7%) with normal platelet count and hemoglobin levels. The IgE level was 3,795 IU per milliliter (normal range 0 to 100). Bone marrow biopsy and aspiration revealed an increased in mature eosinophilic myeloid cells (34%). Computed tomography (CT) chest scan showed pneumonia, and cranial magnetic resonance imaging (MRI) showed no apparent abnormalities that could explain the numbness of the patient's left limb. We gave the patient 5 mg of dexamethasone for treatment. Several days after admission, the patient complained of right abdominal pain, combined with nausea and vomiting after eating. Abdominal CT (**Figure 1**) revealed that a prominent huge hepatic capsular hematoma -- indicating a huge hematoma. Three to four days later, multiple organ hemorrhage began to manifest in the patient, such as in the intestinal tract, kidneys, conjunctiva, gum and mucosa. At the same time, purpuric rash appeared on the finger and toe tips

(**Figure 2**), as well as on the patient's back skin area. The result of the cytoplasmic antineutrophil antibodies (c-ANCA) was positive. Thoracic CT revealed infiltrations in the right upper lobe and the left lower lobe of the lungs, and pleural thickening. Skin biopsy (**Figure 3**) specimens obtained from the erythema in the patient's left hand revealed dermal perivascularly with neutrophils and monocytes infiltration; and fibrinoid degeneration of the partial vascular wall. The combined clinical, laboratory and pathological features were suggestive of CSS. Unfortunately, the patient's condition rapidly deteriorated and the patient died within half a month after diagnosis.

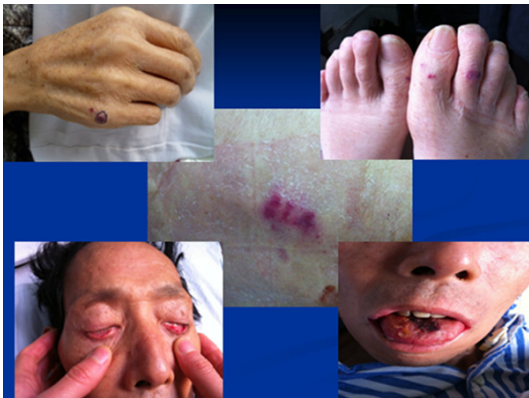## Discussion

CSS with diffuse vasculitis is a rare disease; and the prevalence of CSS in the population varies across reports [1, 2]. Diagnosis of CSS can be difficult due to the absence of typical syndromes. Hammersmith Hospital (London, UK) has defined CSS as a syndrome that includes: (1) a history of asthma; (2) peripheral eosinophilia ( $> 1500$  cells/L); and (3) systemic vasculitis involving two or more organs. **Table 1** shows the list of different categories of diagnostic criteria for the disorder [3-6].

## Fatal Churg-Strauss syndrome complications



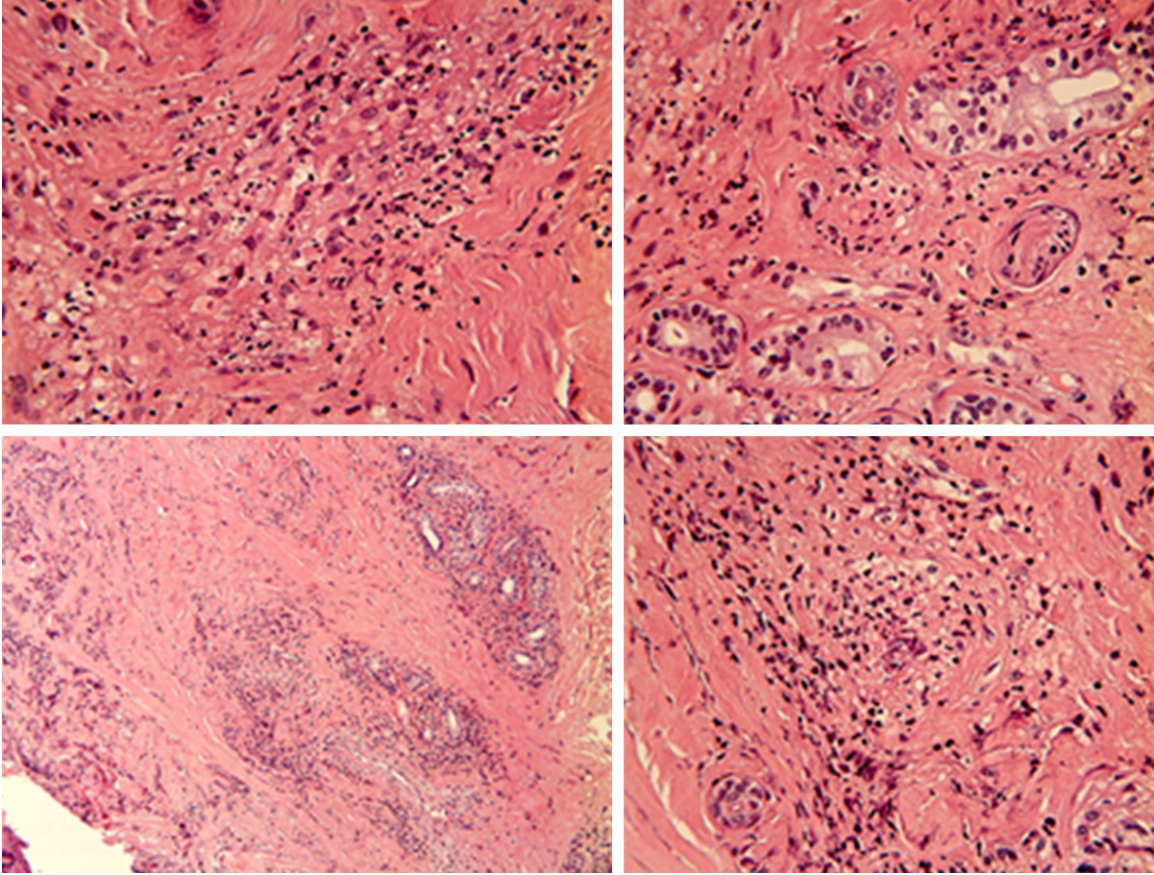
**Figure 1.** Hepatic capsular bleeding (mixed density shadows under the capsule of the right liver and the shadow extending to the pelvis).



**Figure 2.** Skin (hands, feet, and chest) and mucosal (conjunctiva and tongue) nodules with eosinophil infiltration.

CSS can virtually affect any organ, such as the lungs, heart, gastrointestinal tract, skin, kidneys, and peripheral nerves. Among disorders in different organs, pulmonary infiltration is the most common one [3, 5, 7-9]. We did not find any CSS case report involving multiple-organ hemorrhage complications, especially huge hepatic capsular hematoma. There were some CSS cases that presented diffuse alveolar hemorrhage [10]. The prognosis of CSS is good, in general [11, 12]. CSS is often associated with a high titer of serum MPO-ANCA (approximately 40%) [13]. Even though the pathogenic role of MPO-ANCA in CSS is not well understood, it has recently demonstrated that ANCA-positive CSS patients constitute a subset with

## Fatal Churg-Strauss syndrome complications



**Figure 3.** Infiltration of neutrophils and vascular necrosis (skin biopsy).

**Table 1.** Churg-Strauss syndrome definitions

year	Churg and Strauss (1951)	Lanham and colleagues (1984)	American College of Rheumatology (1990)	Chapel Hill Consensus Conference (1994)
	Pathological material obtained at autopsy	Clinical findings with or without pathological material	Clinical findings with or without pathological material;	
Definition	(1) History of asthma (2) Tissue eosinophilia (3) Systemic vasculitis  (4) Extravascular granulomas (5) Fibrinoid necrosis of connective tissue	(1) Asthma (2) Eosinophilia > $1.5 \times 10^9/L$ (3) Evidence of vasculitis that involves at least two organs	(1) Asthma (2) Eosinophilia > 10% (3) Neuropathy, mononeuropathy, or polyneuropathy  (4) Pulmonary infiltration (5) Paranasal sinus abnormality  (6) Extravascular eosinophil infiltration on biopsy findings	Pathological and clinical findings of eosinophil-rich and granulomatous inflammation involving the respiratory tract and necrotizing vasculitis affecting small-to-medium-size vessels and associated with asthma and eosinophilia

different clinical and pathological features, compared to ANCA-negative CSS patients [14]. Indeed, ANCA-positive has been correlated with some organ system manifestations, such as renal involvement, peripheral neuropathy, purpura, and pulmonary hemorrhage. It is believed that neutrophils may cause damage to normal tissues, and this can result in the devel-

opment of vasculitis and glomerulonephritis. On the other hand, experimental studies have shown that MPO-ANCA activates neutrophils which release oxygen radicals, lytic enzymes and inflammatory cytokines. Consequently, neutrophils adhered to endothelial cells cause apoptosis and necrosis [15-17]. Elevated serum MPO-ANCA has been proven to be a good mark-

## Fatal Churg-Strauss syndrome complications

er for the prognosis of systemic vasculitis syndromes. In our case, the positive serum ANCA of the patient might predict multiple organ hemorrhage, including the liver, intestines, kidneys and skin; as well as the rapid progression of symptoms, and poor prognosis.

### Acknowledgements

This study was supported by a grant from the National Science Foundation of China (308-70914) and the Foundation of Innovation Team for Basic and Clinical Research of Zhejiang Province (2011R50015).

### Disclosure of conflict of interest

None.

**Address correspondence to:** Hongyan Tong, Department of Hematology, The First Affiliated Hospital, Zhejiang University, College of Medicine, #79 Qingchun Road, Hangzhou 310003, Zhejiang Province, People's Republic of China. E-mail: hongyanatong@163.com

### References

- [1] Martin RM, Wilton LV, Mann RD. Syndrome, vasculitis, eosinophilia and associated conditions: retrospective analysis of 58 prescription-event monitoring cohort studies. *Pharmacoepidemiol Drug Saf* 1999; 8: 179-189.
- [2] Watts RA, Lane SE, Bentham G and Scott DG. Epidemiology of systemic vasculitis: a ten-year study in the United Kingdom. *Arthritis Rheum* 2000; 43: 414-419.
- [3] Lanham JG, Elkon KB, Pusey CD. Systemic vasculitis with asthma and eosinophilia: a clinical approach to the Churg-Strauss syndrome. *Medicine (Baltimore)* 1984; 63: 65-81.
- [4] Jennette JC, Falk RJ, Andrassy K. Nomenclature of systemic vasculitides: proposal of an international consensus conference. *Arthritis Rheum* 1994; 37: 187-192.
- [5] Churg J and Strauss L. Allergic granulomatosis, allergic angiitis, and periarteritis nodosa. *Am J Pathol* 1951; 27: 277-301.
- [6] Masi AT, Hunder GG and Lie JT. The American College of Rheumatology 1990 criteria for the classification of Churg-Strauss syndrome (allergic granulomatosis and angiitis). *Arthritis Rheum* 1990; 33: 1094-1100.
- [7] Jennette JC and Falk RJ. Small-vessel vasculitis. *N Engl J Med* 1997; 337: 1512-1523.
- [8] Ramakrishna G and Midthun DE. Churg-Strauss syndrome. *Ann Allergy Asthma Immunol* 2001; 86: 603-613.
- [9] Conron M and Beynon HL. Churg-Strauss syndrome. *Thorax* 2000; 55: 870-877.
- [10] Sugino K, Kikuchi N, Muramatsu Y, Sano G, Kusano E, Isobe K, Sakamoto S, Takai Y, Hasegawa C, Shibuya K, Hatanaka K, Uekusa T, Homma S. Churg-Strauss syndrome presenting with diffuse alveolar hemorrhage and rapidly progressive glomerulonephritis. *Intern Med* 2009; 48: 1807-1811.
- [11] Guillevin L, Cohen P and Gayraud M. Churg-Strauss syndrome: clinical study and long-term follow-up of 96 patients. *Medicine* 1999; 78: 26-37.
- [12] Solans R, Bosch JA and Perez-Bocanegra C. Churg Strauss syndrome: outcome and long term follow up of 32 patients. *Rheumatology* 2001; 40: 763-771
- [13] Sinico RA, Di Toma L and Maggiore U. Prevalence and clinical significance of antineutrophil cytoplasmic antibodies in Churg-Strauss syndrome. *Arthritis Rheum* 2005; 52: 2926-2935.
- [14] Pesci A and Manganelli P. Respiratory system involvement in antineutrophil cytoplasmic-associated systemic vasculitides: clinical, pathological, radiological and therapeutic considerations. *Drugs R D* 2007; 8: 25-42.
- [15] Little MA, Smyth CL and Yadav R. Antineutrophil cytoplasm antibodies directed against myeloperoxidase augment leukocytemicrovascular interactions in vivo. *Blood* 2005; 106: 2025-2058.
- [16] Huugen D, Xiao H and van Esch A. Aggravation of antimyeloperoxidase antibody-induced glomerulonephritis by bacterial lipopolysaccharide: role of tumor necrosis factor- $\alpha$ . *Am J Pathol* 2005; 167: 47-58.
- [17] Xiao H, Schreiber A, Heeringa P, Falk RJ and Jannette C. Alternative complement pathway in the pathogenesis of disease mediated by anti-neutrophil cytoplasmic autoantibodies. *Am J Pathol* 2007; 170: 52-64.