

## Original Article

# Triple, double- and single-incision laparoscopic cholecystectomy: a prospective study

Mehmet Zafer Sabuncuoğlu<sup>1</sup>, Mehmet Fatih Benzin<sup>2</sup>, Tugrul Cakir<sup>3</sup>, Isa Sozen<sup>4</sup>, Aylin Sabuncuoğlu<sup>5</sup>

<sup>1</sup>Department of Suleyman Demirel University Faculty of Medicine General Surgery, Isparta, Turkey; <sup>2</sup>Department of Yozgat Akdagmadeni State Hospital General Surgery, Yozgat, Turkey; <sup>3</sup>Department of Antalya Numune Education and Research Hospital General Surgery, Antalya, Turkey; <sup>4</sup>Department of Ankara Numune Education and Research Hospital General Surgery, Ankara, Turkey; <sup>5</sup>Isparta State Hospital Anesthesia and Critical Care Unit, Isparta, Turkey

Received August 20, 2014; Accepted September 20, 2014; Epub October 15, 2014; Published October 30, 2014

**Abstract:** Purpose: Advances in laparoscopic techniques have enabled complicated intra-abdominal surgical procedures to be made with less trauma and a better cosmetic appearance. The techniques have been developed by decreasing the number of incisions in conventional laparoscopic procedures in order to increase patient satisfaction. The aim of this study was to compare the results of cholecystectomies made with 3, 2 or a single incision. Method: A total of 95 cholecystectomy patients from Elbistan State Hospital and Suleyman Demirel University Hospital between 2011 and 2013 were prospectively evaluated. The patients were separated into 3 groups as triple incision laparoscopic cholecystectomy (TILC), double incision laparoscopic cholecystectomy (DILC) and single incision laparoscopic cholecystectomy (SILC). Patients were evaluated in respect of demographic characteristics, operation time, success rate, analgesia requirement, length of hospital stay and patient satisfaction. Results: Successful procedures were completed in 40 TILC, 40 DILC and 15 SILC cases. Transfer to open cholecystectomy was not required in any case. The mean duration of operation was 71 mins (range, 55-120 mins) for SILC cases, 45 mins (range, 32-125 mins) for DILC cases and 42 mins (range, 29-96 mins) for TILC cases. The mean time for the SILC cases was statistically significantly longer than the other two groups ( $p < 0.000$ ). Conclusions: At a comparable level with DILC and TILC, single incision laparoscopic cholecystectomy is a method which can be used without incurring any extra costs or requiring additional instrumentation or training and which has good cosmetic results and a low requirement for analgesia.

**Keywords:** Laparoscopic cholecystectomy, minimal invasive surgery, single incision surgery

## Introduction

Following the first successful laparoscopic cholecystectomy in 1987, it rapidly became the gold standard and with the use of technology in surgery, and the development of new instruments and minimally invasive concepts, techniques with better cosmetic results started to be described. Although laparoscopic cholecystectomies were begun using the technique of 4 incisions, over time there was a tendency to reduce the number of incisions with increased experience and in line with patient requests. With the application of single port cholecystectomy by Navarra in 1987, the idea of scarless surgery increased in popularity [1].

The desire for a better cosmetic result is probably the most important reason for the choice.

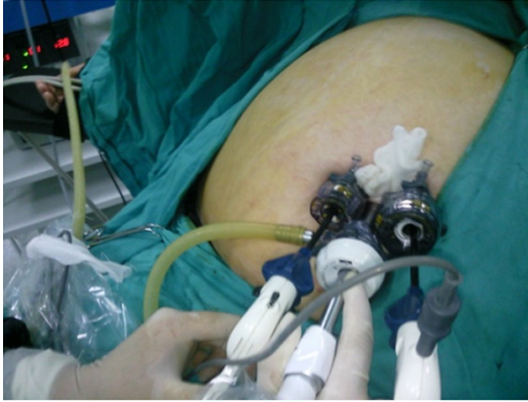Although there are studies on the subject of a reduced number of ports reducing the analgesia requirement, the superiority of SILS over conventional techniques in terms of postoperative pain, return to daily activities and cosmetic results, has not been fully clarified [2, 3].

Despite this method requiring the use of more expensive instruments and a longer learning period, it has become superior with the use of conventional instruments with no additional cost and time requirement.

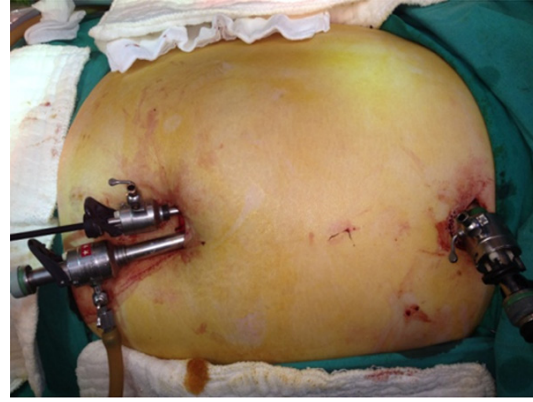
## Method

A total of 133 patients diagnosed with symptomatic cholelithiasis at Elbistan State Hospital and Suleyman Demirel University Hospital between 2011 and 2013 were included in the

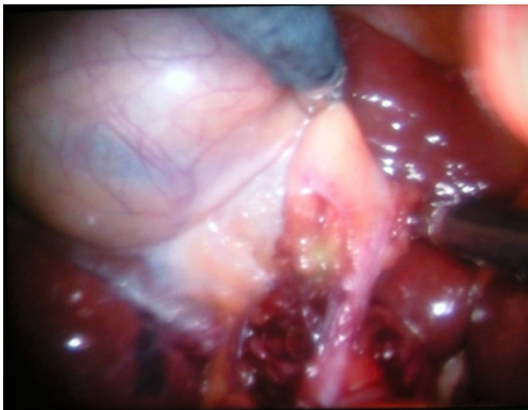## Conventional surgery to single incision surgery



**Figure 1.** Position of trochars in SILC.



**Figure 3.** Trochar position of double incision.



**Figure 2.** Triangle of Calot.

study and 38 patients excluded. While SILS cholecystectomy was applied to 15 selected patients, 80 patients were randomised. The patients selected for SILS were those with no history of cholecystitis.

Exclusion criteria were patients with American Society of Anesthesiologists score (ASA) of more than III, patients with prior abdominal surgery, patients with choledocholithiasis and/or abnormal cholestasis enzyme values, pregnancy, ongoing peritoneal dialysis, the presence of pancreatitis, acute cholecystitis, mirizzi's syndrome, BMI > 35 and those who did not accept inclusion in the study.

All the patients were diagnosed from preoperative abdominal ultrasonography (US) or computerised tomography (CT) and all underwent the same preoperative preparation process. At 30 mins prior to the preoperative incision, 1 g cefazolin was administered intravenously. All the operations were performed by the same

surgeon (MZS) who was experienced in laparoscopic surgery with the standard American technique but had no previous experience of SILS.

The ASA score, indication for operation, operative morbidity, operative time, pain score, length of hospital stay, need for conversion to three or four port laparoscopic cholecystectomy, need for conversion to open cholecystectomy and satisfaction of cosmetic outcome were recorded. A standard analgesia protocol was used with intramuscular nonsteroid anti-inflammatory drug (diclofenac sodium 75 mg) twice a day. When necessary, opioids were added (Pethidine hydrochloride 1 mg/kg).

Postoperative pain was assessed according to a visual analogue scale (VAS) from 0 (no pain) to 10 (worst pain imaginable) at the postoperative 6th hour (VAS-6) and on postoperative day 1 (VAS-24) [4]. Morbidity was evaluated by rates of bile leakage, wound infection, and hospital readmission [4].

Cosmetic outcome was assessed on a scale from 1 (worst satisfaction) to 5 (best satisfaction) at the end of postoperative month 1. A comparison was made of the operation time, success rate, analgesia requirement, length of postoperative hospital stay and patient satisfaction.

### *Operative technique*

All procedures were performed under general anesthesia and orotracheal intubation. All patients were placed in the reverse Trendelenburg position (30°) with the table tilted

## Conventional surgery to single incision surgery

**Table 1.** Patient characteristics

Patient characteristics	TILC	DILC	SILC	P-value
Age (year)	51 ± 13 (18-73)	50 ± 16 (20-70)	57 ± 13 (36-79)	0.157
Gender (M/F)	30/10	16/24	4/11	0.001
BMI	28.67 ± 3.54 (19-35)	27.91 ± 4.31 (18-35)	26.73 ± 4.13 (18-32)	0.336
ASA score	1.85 ± 0.83 (1-3)	1.70 ± 0.65 (1-3)	1.53 ± 0.52 (1-2)	0.471

downward to the patient's left in order to bring the operative field toward the surgeon and displace intra-abdominal organs away from the gallbladder. In both groups, during laparoscopy, the gas used was CO<sub>2</sub> and intra-abdominal pressure was maintained at 12-14 mmHg. In all patients a nasogastric tube was inserted at the beginning and removed after the intervention.

### *Single incision laparoscopic cholecystectomy*

The assistant for the surgeon and the camera was located on the left of the patient. After making a 2 cm infraumbilical incision, first a 10 mm port, then two 5 mm ports were made to form a triangle (**Figure 1**).

Suture retractors were not used due to the challenging anatomy of Callot's triangle. Using conventional instruments, Callot's triangle was dissected by raising the gall bladder from Hartmann's pouch and a standard cholecystectomy was completed (**Figure 2**). The gallbladder was extracted from the abdominal cavity with the use of an Endobag. The fascia was closed with no:0 polypropylene sutures. The dermis of the umbilicus was closed subcuticular with 4/0 polypropylene. A drain was not routinely used.

### *Two incision laparoscopic cholecystectomy*

After making a 1.5 cm infra-umbilical incision, firstly pneumoperitoneum was created with a Veress needle and a 10-mm trocar was placed in the umbilicus. Then a 5 mm port was placed at the corner of the right end of the incision. After the placement of an epigastric 5 mm port, a standard cholecystectomy was performed. The specimen was then removed and only the umbilical fascia was closed with no:0 polypropylene sutures. Trocar wounds were sutured with 4/0 polypropylene. To have a secure view of the Callot triangle and complete the dissection, 1 patient required a 3rd incision (4th port) and 1 patient a 4th incision (5th port). Only the patient where 5 ports were used needed a drain, which was removed on postoperative day 1 and the patient was discharged (**Figure 3**).

### *Three incision laparoscopic cholecystectomy*

After making a 1.5 cm infra-umbilical incision, firstly pneumoperitoneum was created with a Veress needle and a 10-mm trocar was placed in the umbilicus. Then after placing epigastric and midclavicular 5 mm ports, a standard cholecystectomy was performed. The specimen was then removed and only the umbilical fascia was closed with no: 0 polypropylene sutures. Trocar wounds were sutured with 4/0 polypropylene.

### *Statistical analysis*

All statistical analyses were made using SPSS ver. 16.0. Patient age data were compared using the One-Way Anova Tukey test. The non-parametric Kruskal-Wallis test was applied for comparison of BMI, ASA score, operating time, hospital stay, pain scores and cosmetic outcomes. The Mann-Whitney U test was used for the comparison of paired groups. The Chi-square test was applied for the evaluation of complications, need for an additional port and conversion to open surgery. A value of  $p < 0.005$  was accepted as statistically significant.

### **Results**

A total of 95 patients were included in the study. No statistically significant difference was determined between the three groups of patients in respect of age, gender and diagnosis (**Table 1**). 40 TILC, 40 DILC and 15 SILC cholecystectomies were successfully applied.

While no case was transferred to open cholecystectomy, 1 patient in both the TILC and DILC groups had the number of ports increased by one because of difficulties in dissection and insufficient visualisation of Callot's triangle. In the DILC group, 1 patient required a fourth incision and fifth port.

There were no complications such as bile duct damage or massive haemorrhage in any case.

## Conventional surgery to single incision surgery

**Table 2.** Operative data

Operative data	TILC	DILC	SILC	P-value
Operating time (min)	44.50 ± 11.12 (29-96)*	45.85 ± 15.59 (32-125)*,#	79 ± 14.66 (55-120)	< 0.001*
Blood loss (ml)	10.60 ± 5.33 (0-28)	10.15 ± 5.82 (0-32)	11.20 ± 6.25 (0-24)	0.782

Values are presented as mean ± standard deviation (range). \* $p < 0.001$  when compared with SILC, # $p < 0.001$  when compared with TILC.

**Table 3.** Postoperative data

Postoperative data	TILC	DILC	SILC	P-value
VAS-6	4.18 ± 1.17 (2-8)	4.08 ± 1.16 (2-8)	4.67 ± 1.40 (2-8)	0.124
VAS-24	2.38 ± 1.03 (1-5)	2.15 ± 0.83 (1-5)	2.73 ± 0.88 (1-5)	0.051
Opioid use (patient)	11	7	3	0.547
Hospital stay (day)	1.43 ± 0.55 (1-3)	1.20 ± 0.41 (1-2)	1.13 ± 0.35 (1-2)	0.052
Cosmetic satisfaction	3.15 ± 0.74 (1-5)*	3.60 ± 0.67 (1-5)*,#	4.13 ± 1.06 (1-5)	< 0.001*

Values are presented as mean ± standard deviation (range). \* $p < 0.006$  when compared with SILC group; # $p < 0.01$  when compared with TILC group.

**Table 4.** Complications

Complications	TILC	DILC	SILC
Wound infection	2 (5%)	3 (7.5%)	3 (20%)

Values are presented as number and percentage (%). Chi-square was applied for assessment.

The mean amount of blood loss was similar in all the groups (**Table 2**). No patient required re-hospitalisation because of postoperative complications. The operation time of the first 3 SILC cases was longer ( $100 \pm 17.32$  mins [range, 90-120 mins]) which was thought to be due to the process of gaining experience with SILS, the use of conventional instruments rather than articulated ones and patient-related. In subsequent SILS cases, the operating time was shorter ( $73.75 \pm 8.29$  mins [range, 55-85 mins]). From the beginning, the double incision cholecystectomies were completed in a similar time to those with the 3 port method ( $45.85 \pm 15.59$  mins [range, 32-125 mins]).

Although the VAS-6 scores were not statistically significant, the scores of the SILS cases were higher. In the VAS-24 scores, the highest scores were those of the SILS cases (2.73) and the lowest, those of the DILS cases (2.15) ( $p = 0.051$ ).

None of the cases required intraoperative cholangiography. The duration of hospitalisation was found to be similar in all the groups. In 1 patient of the SILC group, wound site inflammation developed which was treated with conser-

vative monitoring and antibiotherapy, without any need for intervention. The data related to complications are given in **Table 4**.

In the evaluation of cosmetic satisfaction, cases in the SILC group scored higher (4.15) than those in the TILC group (3.15) and the SILC group (3.60). The difference between the groups was statistically significant ( $p \leq 0.001$ ). Postoperative data are shown in **Table 3**.

### Discussion

Laparoscopic cholecystectomy is the worldwide gold standard as it has demonstrated shorter hospital stays, lower levels of postoperative pain, a speedy return to work, greatly superior cosmetic results and much lower morbidity rates [1-5]. Initially the 4 port technique was used but increasingly this has been replaced by techniques using fewer incisions which are less traumatic and have better cosmetic results. All these studies have resulted in Minimal Access Surgery.

There are several studies related to a reduced number of ports reducing postoperative pain [6, 7]. The most recent point on this subject is natural orifice transluminal surgery (NOTES). However, this technique is still controversial as it requires a multidisciplinary team, a long and difficult operation process and there are ethical problems related to the transvaginal route. For all these reasons, most surgeons tend towards single site surgery. Among the most important reasons for this tendency are

## Conventional surgery to single incision surgery

the use of conventional instruments, a short learning curve, applying the procedure in known anatomy and the low cost.

The Trichak 3 port method has been shown to be much superior to the 4 port method in terms of the requirement for postoperative analgesia [8]. With the idea of fewer incisions resulting in less pain and higher patient satisfaction, the 2 incision/3 port DILC study group was included. The use of a single incision becomes easier with experience. Although there is no difference between the staff in our clinic, with the exception of a few cases, the surgeons routinely use the 3 port cholecystectomy technique. Therefore in the planning of the study, 2 incision or single incision cholecystectomy was used in accordance with patient requests.

As the most well-known and widely used laparoscopy method, the transumbilical method was used in all the cases of this study. This allows the visualisation of a similar operation field without any additional risk.

The SILC technique has some difficulties compared to conventional cholecystectomy. When using conventional instruments, the lack of articulation and limited area of movement creates difficulties in dissection and critical visual field. With this technique, which may not be ergonomic, the operating time of the first cases will be longer and conformity difficulties will be experienced. The operation time of the cases in the SILC group of the current study was a little longer compared to the mean duration of 75 mins reported in previous studies in literature. When the longer first cases were not included, the times were similar [9-12].

When SILC is applied with conventional instruments, due to the difficulty of working at the same angle, the Callot triangle dissection and placement of the clips may be difficult with the right hand. The main reasons for a prolonged operating time are achieving sufficient dissection of Callot's triangle, obtaining a critical view and then placing the clips at the appropriate angle. Therefore, when difficulties were experienced at this stage of SILC, a transfer to DILC was made at the appropriate stage. Since the application in the first cases of clips and dissection in the 3 port manner similar to the epigastric placement with conventional cholecystectomy, there was no conformity difficulty or extension of operating time.

Again in some SILC cases, to achieve a suitable view of the dissection line, the use of transabdominal sutures has been recommended to raise the fundus. In addition, specially developed port and curved instruments are used. Particularly in difficult dissections and large gall bladder operations, the use of transperitoneal suture technique can be an alternative to the placement of an additional port. In the current series, the transperitoneal suture technique was used in 2 cases of the DILC group and 3 cases of the SILC group [3, 5, 13].

In a study by Tsimoyiannis [7] in which conventional 4 port was compared with the single access technique, the pain scores of the SILC group were found to be lower. However, in similar studies, no difference has been determined between groups in terms of pain scores, length of hospital stay and need for analgesia [13, 14]. In a study by Jung [15], the analgesia requirement and pain scores were reported to be higher in the SILC group. In the current study, the VAS-6 and VAS-24 values of the SILC group were higher but the need for analgesia was found to be similar to that of the other groups. The cases of the DILC group had the lowest results for both values. This is thought to be due to a relatively larger single incision made for placement of the ports and that the operation was completed without the need for a 3rd incision in the right upper quadrant.

In addition, when right upper quadrant postoperative pain is examined separately, it has been reported that 30% of patients with the conventional 3 and 4 port techniques described pain in that area. This rate was reduced to 15% in SILC cases as a port was not placed in that area. The DILC technique described here may similarly relieve postoperative pain.

In meta-analyses and studies which have compared the complications in SILC and conventional cholecystectomy, although the SILS cases had longer operating times, no difference was determined in respect of early and late complications, length of hospital stay or VAS scores [16, 17]. In the current study, no difference was determined between the three groups in respect of complications.

Although there are studies related to higher cosmetic satisfaction of SILS cases, there are also studies showing similar results to those of conventional cholecystectomy [16-18].

## Conventional surgery to single incision surgery

In the evaluation of pain scores, while the VAS-6 scores of the SILC patients were high but not statistically significant, they were also similar to those of the TILC and DILC groups. In the evaluation of the VAS-24 scores, the mean of the SILC group was calculated as 2.7, TILC as 2.4 and DILC as 2.1 ( $p = 0.051$ ). Postoperative data are shown in **Table 3**.

There are studies related to SILC which explain the relevance of the experience of the surgeon. When these studies are examined it has been reported that surgery has been applied by surgeons with experience of an average of more than 50 conventional cholecystectomies and at least 5-10 SILC. This shows that studies were made in the period after overcoming the difficulties of the transition stage to SILC from conventional cholecystectomy. In the current study, SILC was planned but as the surgeons had no experience on this subject, to enable the transition stage to be overcome more easily, DILC was defined. By facilitating the increase in the number of ports needed, this technique, which is similar to conventional cholecystectomy in respect of complications and operating time and is superior in respect of cosmesis and patient satisfaction, can be used as one of the stages in a surgeon's development [17].

The use of conventional instruments in SILC has been described to avoid the additional financial burden in particular. In these cases when difficulties are experienced in dissection, obtaining the critical view angle or in placing the clips, a transition to DILC can be made with an extra incision according to the status of the case. This not only facilitates the process of increasing SILC experience but also does not require any additional cost or preparation.

Single incision laparoscopic cholecystectomy is feasible and safe but its difficult to perform by an unexperienced surgeon. Therefore, DILC can be performed with acceptable operative outcomes, superior cosmetic results and postoperative pain while gain experience. In conclusion, DILC performed by an unexperienced surgeon is at least as successful and safe as a traditional laparoscopic cholecystectomy and can be used during development to SILC as a bridge.

### Disclosure of conflict of interest

None.

**Address correspondence to:** Dr. Mehmet Zafer Sabuncuoglu, Department of Suleyman Demirel University Faculty of Medicine General Surgery, Isparta, Turkey. Tel: 905055174305; E-mail: drmehmetzafer@yahoo.com

### References

- [1] Navarra G, Pozza E, Occhionorelli S, Carcoforo P, Donini I. One-wound laparoscopic cholecystectomy. *Br J Surg* 1997; 84: 695.
- [2] Elsey JK, Feliciano DV. Initial experience with single-incision laparoscopic cholecystectomy. *J Am Coll Surg* 2010; 210: 620-4, 624-6.
- [3] Philipp SR, Miedema BW, Thaler K. Single-incision laparoscopic cholecystectomy using conventional instruments: early experience in comparison with the gold standard. *J Am Coll Surg* 2009; 209: 632-7.
- [4] Wewers ME, Lowe NK. A critical review of visual analogue scales in the measurement of clinical phenomena. *Res Nurs Health* 1990; 13: 227-36.
- [5] Bokobza B, Valverde A, Magne E, Delaby J, Rubay R, Bellouard A, Dabrowski A, Framery D, Desfachelle JP, Prieur E, Hauters P. Single umbilical incision laparoscopic cholecystectomy: initial experience of the Coelio Club. *J Visc Surg* 2010; 147: e253-7.
- [6] Tacchino R, Greco F, Matera D. Single-incision laparoscopic cholecystectomy: surgery without a visible scar. *Surg Endosc* 2009; 23: 896-9.
- [7] Tsimoyiannis EC, Tsimogiannis KE, Pappas-Gogos G, Farantos C, Benetatos N, Mavridou P, Manataki A. Different pain scores in single transumbilical incision laparoscopic cholecystectomy versus classic laparoscopic cholecystectomy: a randomized controlled trial. *Surg Endosc* 2010; 24: 1842-8.
- [8] Trichak S. Three-port vs standard four-port laparoscopic cholecystectomy. *Surg Endosc* 2003; 17: 1434-6.
- [9] Hernandez JM, Morton CA, Ross S, Albrink M, Rosemurgy AS. Laparoendoscopic single site cholecystectomy: the first 100 patients. *Am Surg* 2009; 75: 681-5; discussion 5-6.
- [10] Romanelli JR, Roshek TB 3rd, Lynn DC, Earle DB. Single-port laparoscopic cholecystectomy: initial experience. *Surg Endosc* 2010; 24: 1374-9.
- [11] Ersin S, Firat O, Sozbilen M. Single-incision laparoscopic cholecystectomy: is it more than a challenge? *Surg Endosc* 2010; 24: 68-71.
- [12] Kuon Lee S, You YK, Park JH, Kim HJ, Lee KK, Kim DG. Single-port transumbilical laparoscopic cholecystectomy: a preliminary study in 37 patients with gallbladder disease. *J Laparoendosc Adv Surg* 2009; 19: 495-9.
- [13] Marks J, Tacchino R, Roberts K, Onders R, Denoto G, Paraskeva P, Rivas H, Soper N,

## Conventional surgery to single incision surgery

- Rosemurgy A, Shah S. Prospective randomized controlled trial of traditional laparoscopic cholecystectomy versus single-incision laparoscopic cholecystectomy: report of preliminary data. *Am J Surg* 2011; 201: 369-72; discussion 72-3.
- [14] Ostlie DJ, Juang OO, Iqbal CW, Sharp SW, Snyder CL, Andrews WS, Sharp RJ, Holcomb GW 3rd, St Peter SD. Single incision versus standard 4-port laparoscopic cholecystectomy: a prospective randomized trial. *J Pediatr Surg* 2013; 48: 209-14.
- [15] Jung GO, Park DE, Chae KM. Clinical results between single incision laparoscopic cholecystectomy and conventional 3-port laparoscopic cholecystectomy: prospective case-matched analysis in single institution. *J Korean Surg Soc* 2012; 83: 374-80.
- [16] Aprea G, Coppola Bottazzi E, Guida F, Masone S, Persico G. Laparoendoscopic single site (LESS) versus classic video-laparoscopic cholecystectomy: a randomized prospective study. *J Surg Res* 2011; 166: e109-12.
- [17] Markar SR, Karthikesalingam A, Thrumurthy S, Muirhead L, Kinross J, Paraskeva P. Single-incision laparoscopic surgery (SILS) vs. conventional multiport cholecystectomy: systematic review and meta-analysis. *Surg Endosc* 2012; 26: 1205-13.
- [18] Ma J, Cassera MA, Spaun GO, Hammill CW, Hansen PD, Aliabadi-Wahle S. Randomized controlled trial comparing single-port laparoscopic cholecystectomy and four-port laparoscopic cholecystectomy. *Ann Surg* 2011; 254: 22-7.