Int J Clin Exp Med 2015;8(5):6804-6812
www.ijcem.com /ISSN:1940-5901/IJCEM0006999

Original Article

Amelioration of meconium-induced acute lung injury by parecoxib in a rabbit model

Ai-Min Li, Li-Na Zhang, Wen-Zhi Li

Department of Anesthesiology, The Second Affiliated Hospital of The Harbin Medical University, Harbin 150081, Heilongjiang Province, China

Received February 12, 2015; Accepted April 23, 2015; Epub May 15, 2015; Published May 30, 2015

Abstract: Cyclooxygenase-2 (COX-2) plays important roles in various inflammatory conditions and is significantly increased in meconium-induced lung injury. We investigated the effects of parecoxib on meconium-induced acute lung injury (ALI) in rabbits. Twenty-four rabbits were randomized into sham, control, and parecoxib groups. Rabbits in the control and parecoxib groups underwent tracheal instillation of meconium, followed by intravenous injection of saline or parecoxib and 4 h of ventilation. The airway pressure, dynamic compliance, and ratio of partial pressure of oxygen in arterial blood to fraction of inspired oxygen (PaO_2/FiO_2 ratio) were recorded at baseline (T0) and 4 h after instillation (T1-T4). The lung tissue wet-to-dry weight ratio; neutrophil percentage; and total protein, tumor necrosis factor-α (TNF-α), interleukin (IL)-1β, IL-8, prostaglandin E_2, and malondialdehyde levels in bronchoalveolar lavage fluid (BALF) were evaluated. The myeloperoxidase activity, COX-2 expression, and degree of histopathologic injury in lung tissue were also analyzed. The airway pressure, compliance, and PaO_2/FiO_2 ratio were significantly improved by parecoxib after meconium instillation. The lung wet-to-dry weight ratio, total protein level, and neutrophil percentage in BALF were lowest in the parecoxib group. The TNF-α, IL-1β, IL-8, prostaglandin E_2, and malondialdehyde levels in the BALF were lowest in the parecoxib group. The COX-2 expression and myeloperoxidase activity in lung tissue were significantly reduced by parecoxib. The degree of lung injury was also reduced. In conclusions: Parecoxib effectively ameliorates respiratory function and attenuates meconium-induced ALI. These effects are correlated with prostaglandin E_2 and COX-2 inhibition.

Keywords: Parecoxib, meconium, acute lung injury, cyclooxygenase-2 (COX-2), meconium-induced, meconium aspiration syndrome, extracorporeal membrane oxygenation, rabbit model, respiratory failure, neonates

Introduction

Meconium aspiration syndrome (MAS) is a major cause of lung injury and respiratory failure in neonates. The incidence of MAS requiring intubation is approximately 0.5 per l000 live births [1]. MAS characterized by airway obstruction, ventilation-perfusion mismatch, inflammation, alveolar exudation, surfactant dysfunction, airway hyperreactivity, and other conditions [2, 3]. Meconium can chemoattract neutrophils, monocytes, and macrophages and trigger their leakage through the alveolocapillary membrane [4-6]. Routine treatment of MAS involves intrapartum and post-delivery oral suctioning; however, these techniques do not decrease the incidence of MAS [7]. Moreover, among the pharmacotherapeutic agents used to treat MAS (antibiotics, anti-inflammatories, pulmonary anti-hypertensive, and others), only inhalation of nitric oxide and surfactant have been shown to decrease the need for extracorporeal membrane oxygenation in infants with MAS [8].

Experimental and clinical studies have indicated that cyclooxygenase-2 (COX-2) plays a role in the development of MAS [9-11]. Intrapulmonary meconium significantly upregulates lung COX-2 and nitric oxide synthase (NOS)-2 gene expression. COX-2 is an important modulator in various pathologic inflammatory conditions, and inhibition of COX-2 attenuates proinflammatory cytokines and chemokines [12-14]. Therefore, we hypothesize that administration of a COX-2 inhibitor can alleviate meconium-induced lung injury. In the present study, we administered parecoxib, a COX-2-specific inhibitor, in a rabbit

model of meconium-induced lung injury to determine whether parecoxib can attenuate meconium-induced lung injury.

Materials and methods

This study was approved by the ethics committee of Harbin Medical University. Fresh meconium was collected from the first stools of 20 healthy neonates, lyophilized, and stored at -20°C. Before use, the meconium was suspended with 0.9% NaCl at a concentration of 25 mg/ml. Twenty-four adult New Zealand rabbits weighing 2.5 to 3.0 kg were anesthetized with intravenous ketamine at 20 mg/kg and xylazine at 5 mg/kg followed by continuous infusion of ketamine at 20 $mg \cdot kg^{-1} \cdot h^{-1}$. After induction of anesthesia, a tracheotomy was performed and two 24-G catheters were inserted: one into the femoral artery to monitor the blood pressure and perform blood gas analysis, and the other into the femoral vein to administer anesthetics and saline. The animals were then paralyzed with pipecuronium bromide at 0.6 $mg \cdot kg^{-1} \cdot h^{-1}$ and subjected to ventilation with a tidal volume of 10 ml/kg, frequency of 30 bpm, fraction of inspired oxygen (FiO_2) of 0.21, inspiration time of 50%, and positive end-expiratory pressure of 5 cm H_2O ('683' Small Animal Ventilator; Harvard Apparatus, Holliston, MA, USA). After stabilization, peripheral blood samples were collected for arterial blood gas analysis (Rapidlab 348; Bayer Diagnostics, Muenchen, Germany) and stored for cytokine analysis. Next, the 24 rabbits were randomized into 3 groups: the sham, control, and parecoxib groups. The rabbits in the sham group were ventilated for 4 h. The rabbits in the control and parecoxib groups underwent tracheal tube instillation of a 25-mg/ml meconium suspension at a dose of 4 ml/kg into the right and left lungs followed by ventilation for 4 h. All respiratory parameters were maintained as previously described with the exception of the FiO_2, which was adjusted to 0.8. After instillation of meconium, the rabbits in the control group underwent intravenous injection of 5 ml of saline, and those in the parecoxib group underwent intravenous injection of 1 mg/kg of parecoxib (Pfizer, Kalamazoo, MI, USA). Blood samples were then taken and all parameters were recorded again. The animals were ventilated with oxygen for an additional 4 h. All of the above measurements were performed before meconium instillation (T0) and at 1 (T1), 2 (T2), 3 (T3), and 4 h (T4) after meconium instillation. All rabbits were sacrificed with an overdose of thiamylal at the end of the experiments, at which time blood samples and both lungs were harvested.

Airway pressure and dynamic compliance

The peak pressure and dynamic compliance were monitored with the Datex-Ohmeda S/5 (Datex Instrumentation, Helsinki, Finland).

Arterial blood gas analysis

Arterial blood gases were analyzed with the Rapidlab 348.

Cytokine levels in peripheral blood

The peripheral blood levels of tumor necrosis factor-α (TNF-α), interleukin (IL)-1β, IL-8, and prostaglandin E_2 were detected at all time points using specific enzyme-linked immunosorbent assay kits (R&D Systems, Minneapolis, MN, USA; United States Biological, Salem, MA, USA), according the manufacturers' instructions.

Preparation of bronchoalveolar lavage fluid

Bronchoalveolar lavage fluid (BALF) was harvested from the left lung by infusing 4°C saline (15 ml/kg) containing EDTA-2Na and withdrawing the solution five times. The neutrophils within the BALF were counted with a cell counter. The BALF was centrifuged at 1000 × *g* for 15 min at 4°C and stored at -80°C.

Oxidative stress reaction in meconium-induced ALI

We used colorimetry to detect the malondialdehyde (MDA) level in the BALF using an MDA assay kit (Nanjing Jiancheng Corp., Nanjing, Jiangsu, China). The myeloperoxidase (MPO) activity in the lung tissue was detected using an MPO assay kit (Nanjing Jiancheng Corp.) to investigate the effect of parecoxib on oxidative stress in meconium-induced ALI.

Pulmonary alveolocapillary permeability

The right upper lung lobe was weighed and then dried to achieve a constant weight for 48 h at 60°C. The wet/dry (W/D) weight ratio was

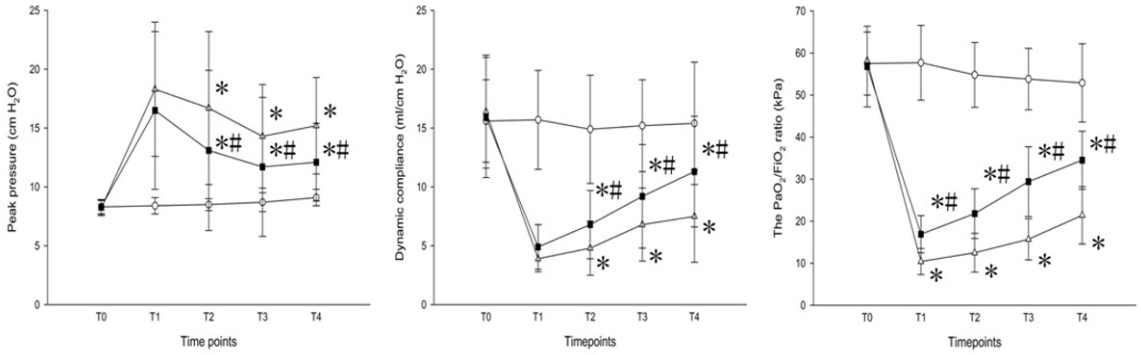

Figure 1. Changes in peak pressure, dynamic compliance, and PaO_2/FiO_2 among the three groups. *P < 0.05 compared with sham group; #P < 0.05 compared with control group (—◇—, sham group; —△—, control group; ■, parecoxib group).

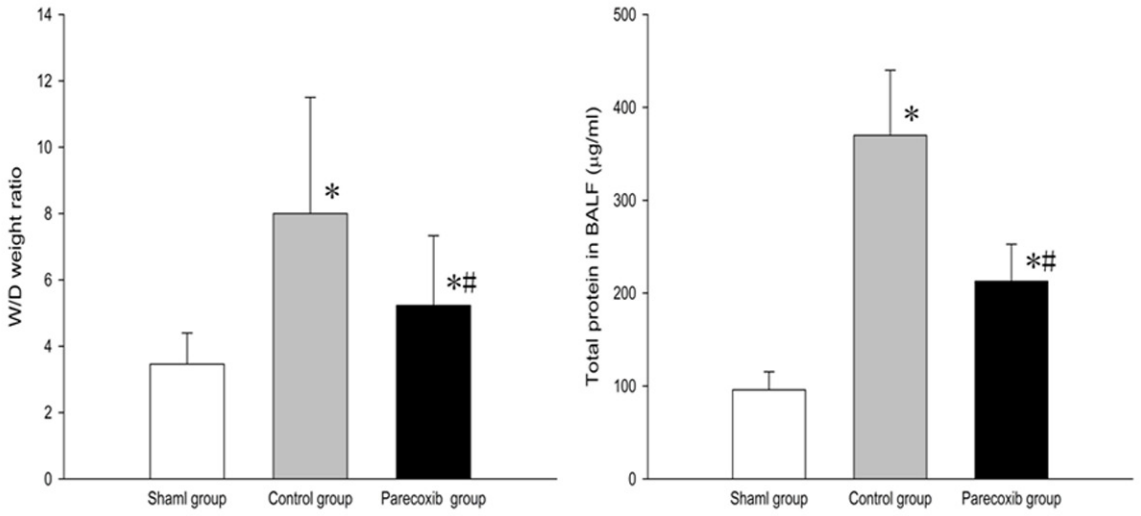

Figure 2. The W/D weight ratio and total protein level in the BALF among the three groups. *P < 0.05 compared with sham group; #P < 0.05 compared with control group (—◇—, sham group; —△—, control group; ■, parecoxib group).

calculated, and the protein concentration in the BALF was measured.

Histopathologic analysis of lung tissue

For histopathologic analysis, the right lower lung lobe was fixed with 10% formalin. The lungs were then embedded in paraffin, and 4-μm sections were stained with hematoxylin and eosin. Two independent pathologists blinded to the experimental groups histologically analyzed the sections with respect to alveolar congestion, edema, neutrophil infiltration of the airspace or vessel wall, hemorrhage, alveolar wall thickness, and hyaline membrane formation.

Western blot analysis

Soluble protein was extracted from the tissue of the right middle lung lobe using lysis buffer containing protein inhibitors. The protein concentration was determined by the Bradford assay, and aliquots of homogenate protein were separated on polyacrylamide gels and transferred onto polyvinylidene fluoride membranes. The membranes were blocked with 5% dry milk and then probed with antibodies to COX-2 (Abcam Biotechnology), followed by incubation with horseradish peroxidase-linked secondary antibodies (Santa Cruz Biotechnology, Santa Cruz, CA, USA). The bands were visualized using enhanced chemiluminescence.

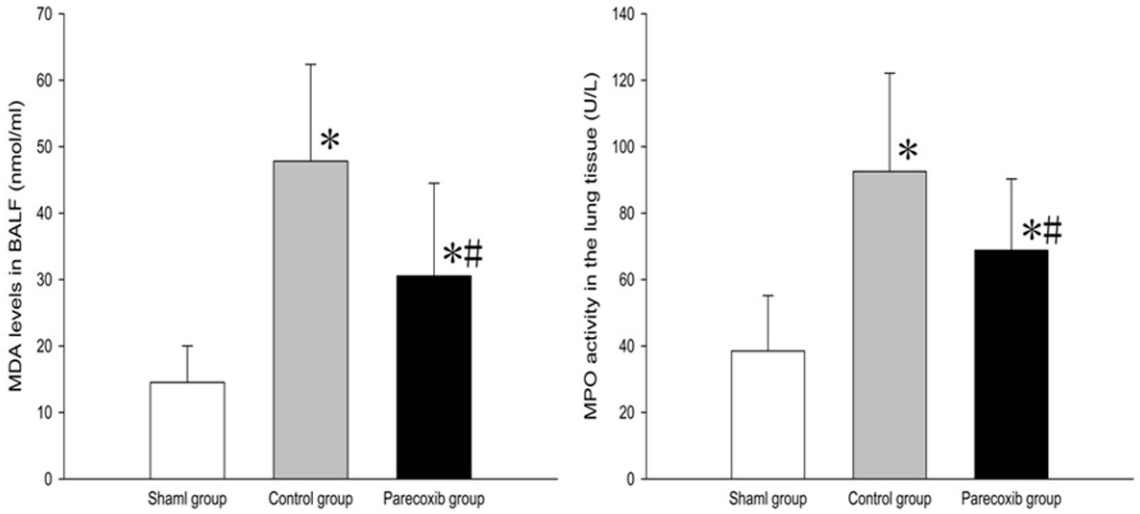

Figure 3. MDA level in BALF and MPO activity in lung tissue among the three groups. *$P < 0.05$ compared with sham group; #$P < 0.05$ compared with control group.

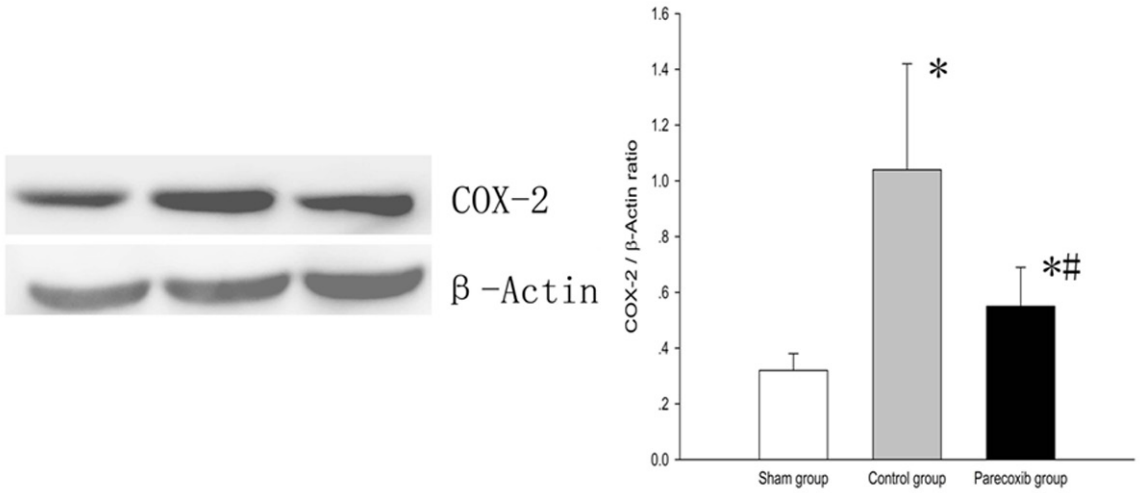

Figure 4. COX-2 expression in lung tissues among the three groups. Densitometry analysis results are shown.

Statistical analysis

All normally distributed data are presented as mean and standard deviation and were analyzed by SPSS version 11.0 statistical software (SPSS, Inc., Chicago, IL, USA). The normally distributed data were analyzed using the unpaired t-test for a single time point or repeated-measures analysis of variance. The non-normally distributed data were analyzed using the Mann–Whitney rank sum test, and histologic data were analyzed with the Wilcoxon U-test. A P value of < 0.05 was considered to be statistically significant.

Results

Parecoxib improves respiratory function in rabbits with meconium-induced ALI

The peak pressure was significantly higher and the dynamic compliance and ratio of the partial pressure of oxygen in arterial blood to the FiO_2 (PaO_2/FiO_2 ratio) were significantly lower after meconium instillation in both the control and parecoxib groups than in the sham group. The peak pressure was significantly lower but the dynamic compliance and PaO_2/FiO_2 ratio were significantly higher in the parecoxib group than in the control group (**Figure 1**).

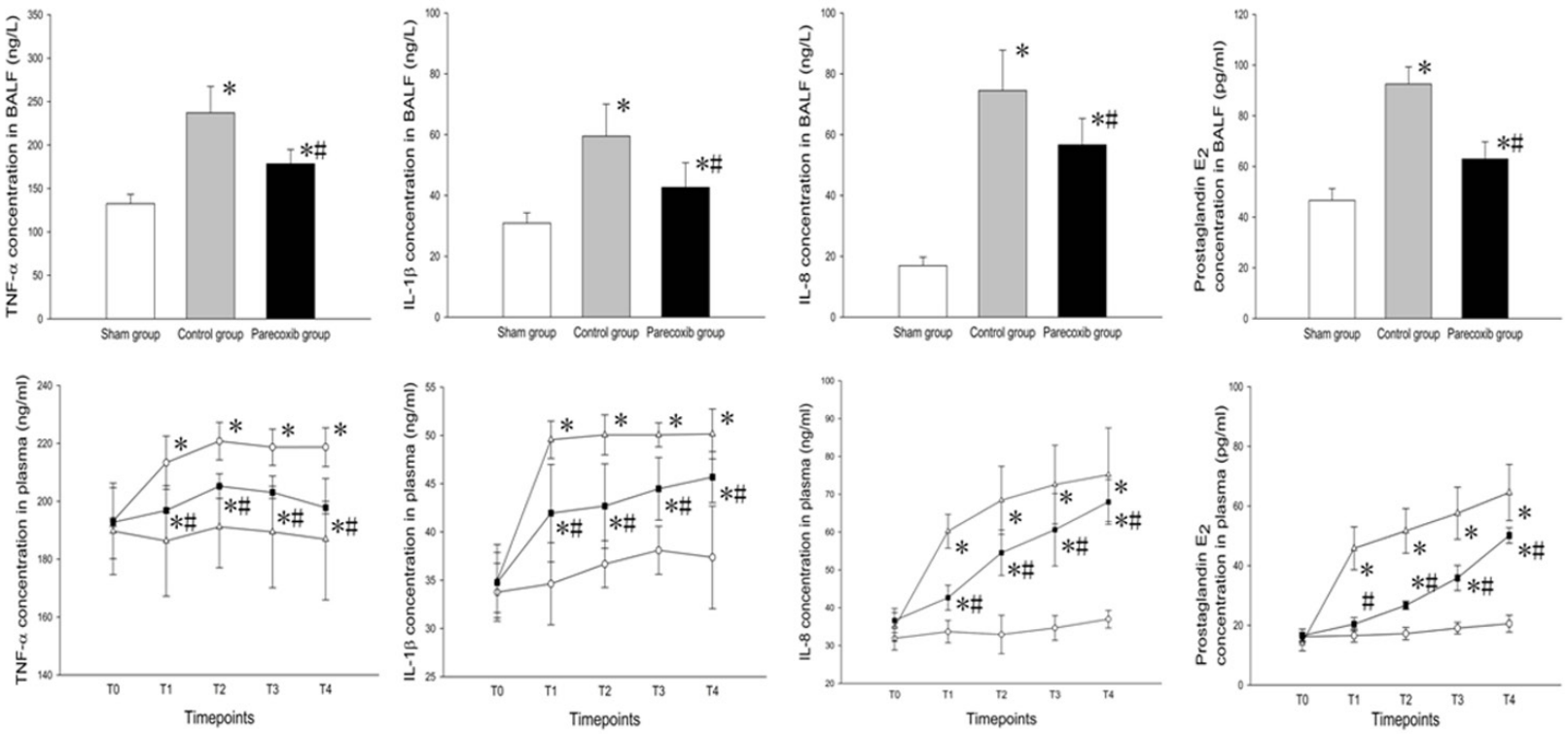

Figure 5. TNF-α, IL-1β, IL-8, and prostaglandin E_2 levels in BALF and plasma among the three groups. *$P < 0.05$ compared with sham group; #$P < 0.05$ compared with control group.

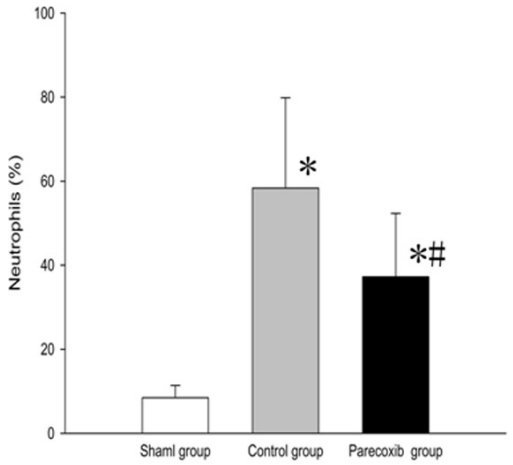

Figure 6. Percentage of neutrophils in BALF among the three groups. *$P < 0.05$ compared with sham group; #$P < 0.05$ compared with control group.

Parecoxib improves alveolocapillary permeability in meconium-induced ALI

The W/D weight ratio and total protein in BALF were significantly higher in the control and parecoxib groups than in the sham group. The W/D weight ratio and total protein level were significantly lower after parecoxib administration than in the control group (**Figure 2**).

Parecoxib inhibits oxygen stress reaction in meconium-induced ALI

We detected the MDA level in the BALF and MPO activity in lung tissue to investigate the effect of parecoxib on oxidative stress in meconium-induced ALI. The MDA and MPO were significantly lower after parecoxib administration (**Figure 3**).

Parecoxib inhibits inflammation in meconium-induced ALI

We detected the TNF-α, IL-1β, IL-8, and prostaglandin E_2 levels in the BALF and serum to evaluate the anti-inflammatory effect of parecoxib on lung injury induced by meconium instillation. All of these levels were significantly higher in the control and parecoxib groups than in the sham group. All of these levels were also significantly lower in the parecoxib group than in the control group (**Figure 5**). Additionally, we calculated the neutrophil ratio in BALF; this ratio was significantly higher in the control group than in the parecoxib group (**Figure 6**). The level of COX-2 expression was significantly lower in the parecoxib group than in the control group (**Figure 4**).

Parecoxib attenuates lung injury in meconium-induced ALI

As shown in **Figure 7**, lung tissue from the sham group showed a normal structure and no histopathologic changes under light microscopy (**Figure 7A**, **7D**). Lung sections obtained from the control group showed characteristic histological changes, including areas of inflammatory infiltration, thickening of the alveolar wall, and pulmonary congestion and hemorrhage (**Figure 7B**, **7E**). However, these meconium-induced pathological changes were significantly attenuated by parecoxib (**Figure 7C**, **7F**).

Discussion

The results of this study indicate that after meconium instillation in rabbits, parecoxib significantly improves lung ventilation and gas exchange, inhibits lung and peripheral inflammation, attenuates lung injury.

The mechanism of meconium-induced lung injury is complex. COX-2 was recently found to be involved in the inflammation associated with meconium-induced lung injury [11]. Both clinical and experimental data suggest that intrapulmonary meconium significantly upregulates lung COX-2 gene expression [9, 10]. COX-2 has been implicated as an important modulator of various pathologic inflammatory conditions through promotion of prostaglandin biosynthesis [12-18], and COX-2 inhibition or gene disruption has been shown to attenuate lung injury [12, 13, 15, 19], Therefore, in this study, we hypothesized that the highly selective COX-2 inhibitor parecoxib can ameliorate the lung injury induced by meconium.

In this study, we analyzed the effect of parecoxib on respiratory function after meconium instillation. Aspirated meconium can result in inflammation, lung edema, and bronchospasm [20]. The combination of bronchospasm and lung edema may increase airway resistance, lead to hypoxemia, and aggravate lung injury [3]. In this study, we found that parecoxib can downregulate airway pressure, upregulate lung compliance, and increase the PaO_2/FiO_2 ratio. This may be associated with a decreased effect of

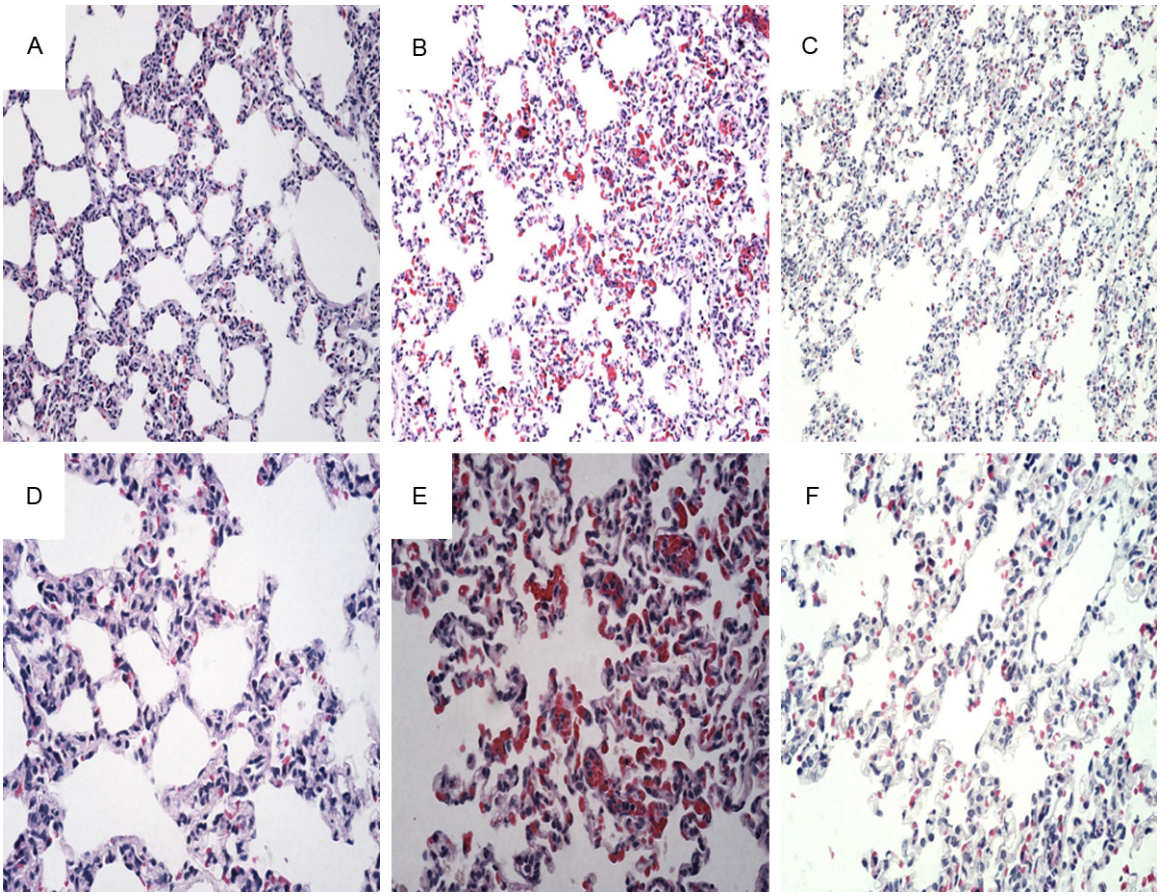

Figure 7. Histopathological analysis of lung tissue among the three groups. A, D. Sham group. B, E. Control group. C, F. Parecoxib group. A-C. ×200. D-F. ×400. The lung tissue in the control group showed thickened alveolar walls, edema, decreased alveolar space, and obvious inflammatory cell infiltration and hemorrhage. Parecoxib significantly decreased the degree of meconium-induced histopathological injury.

parecoxib on lung edema. The W/D weight ratio, protein concentration in BALF, and histological findings in this study suggest that parecoxib can significantly reduce the lung injury, improve the alveolocapillary permeability, and decrease the lung edema induced by meconium. These results are consistent with those of previous studies on the protective effect of COX-2 inhibitors on lung injury [13, 14, 20].

Various studies have revealed that oxidative stress plays an important role in meconium-induced lung injury [2-4, 17, 21, 22]. Kytölä et al. [9] found that meconium upregulates COX-2 expression in lung tissue. In the present study, parecoxib significantly reduced the level of MDA, which is the final product of lipid peroxidation, apparently in directly proportion to the tissue damage caused by reactive oxygen species [23]. Parecoxib significantly decreased the MPO activity and neutrophil count in the BALF, indicating that parecoxib can inhibit the action and infiltration of neutrophils during the development of meconium-induced lung inflammation. These results are consistent with those of a previous study [6].

Inflammation has been demonstrated to play a key role in meconium-induced lung injury [22, 24]. Previous studies have suggested that exposure to meconium can increase production of inflammatory cytokines and lead to lung injury [25-27]. The results of the present study indicate that parecoxib significantly inhibits focal and systemic inflammation. Prostaglandin E_2 is released from epithelial cells in response to various stimuli and can modulate the immune and inflammatory responses [28-33]. In the present study, the prostaglandin E_2 and COX-2 levels were significantly decreased by parecoxib after instillation of meconium. Therefore, we speculated that parecoxib ameliorated the lung

inflammation induced by meconium mainly via inhibition of prostaglandin E_2 and COX-2. The anti-inflammatory effect of parecoxib is also due to inhibition of neutrophil infiltration. The inhibition of MPO activity, which represents the neutrophil count, indicated in this study that parecoxib significantly reduces the recruitment, adhesion, and infiltration of neutrophils. Lindenskov et al. [34] found that the IL-8 level was significantly increased in meconium-instilled lungs, and IL-8 was shown to be an important adhesive molecule for recruitment of neutrophils [35] in meconium-induced lung injury [26]. Therefore, parecoxib also can reduce lung injury via a decrease in the IL-8 level in lung tissue.

Although parecoxib reduced the meconium-induced lung injury in rabbits in the present study, no clinical trials or other studies have fully described the therapeutic effects of parecoxib administration in pediatric patients, particularly neonates. Therefore, application of parecoxib in patients with MAS is limited. Further multicenter clinical trials on the application of parecoxib in neonates are required. However, compared with the severe lung injury and high mortality associated with MAS, the complications of parecoxib in neonates are acceptable.

In conclusion, the results of the present study suggest that parecoxib can improve respiratory function and epithelial permeability, decrease edema, reduce inflammation, and ameliorate lung injury in meconium-induced ALI.

Disclosure of conflict of interest

None.

Address correspondence to: Wen-Zhi Li, Department of Anesthesiology, The Second Affiliated Hospital of The Harbin Medical University, 246 Xuefu Road, Harbin 150081, Heilongjiang Province, China. Tel: +86-0451-86605029; Fax: +86-0451-86605028; E-mail: liaimin999@126.com

References

[1] Dargaville PA, Copnell B; Australian and New Zealand Neonatal Network. The epidemiology of meconium aspiration syndrome: incidence, risk factors, therapies, and outcome. Pediatrics 2006; 117: 1712-21.

[2] Cleary GM and Wiswell TE. Meconium-stained amniotic fluid and the meconium aspiration syndrome. An update. Pediatr Clin North Am 1998; 45: 511-29.

[3] Davey AM, Becker JD and Davis JM. Meconium aspiration syndrome: physiological and inflammatory changes in a newborn piglet model. Pediatr Pulmonol 1993; 16: 101-8.

[4] Craig S, Lopez A, Hoskin D and Markham F. Meconium inhibits phagocytosis and stimulates respiratory burst in alveolar macrophages. Pediatr Res 2005; 57: 813-8.

[5] Mokry J, Mokra D, Antosova M, Bulikova J, Calkovska A and Nosalova G. Dexamethasone alleviates meconium-induced airway hyperresponsiveness and lung inflammation in rabbits. Pediatr Pulmonol 2006; 41: 55-60.

[6] Soukka HR, Ahotupa M, Ruutu M and Kaapa PO. Meconium stimulates neutrophil oxidative burst. Am J Perinatol 2002; 19: 279-84.

[7] Wiswell TE, Gannon CM, Jacob J, Goldsmith L, Szyld E, Weiss K, Schutzman D, Cleary GM, Filipov P, Kurlat I, Caballero CL, Abassi S, Sprague D, Oltorf C and Padula M. Delivery room management of the apparently vigorous meconium-stained neonate: results of the multicenter, international collaborative trial. Pediatrics 2000; 105: 1-7.

[8] Asad A and Bhat R. Pharmacotherapy for meconium aspiration. J Perinatol 2008; 28 Suppl 3: S72-8.

[9] Kytola J, Kaapa P and Uotila P. Meconium aspiration stimulates cyclooxygenase-2 and nitric oxide synthase-2 expression in rat lungs. Pediatr Res 2003; 53: 731-6.

[10] Kytola J, Uotila P and Kaapa P. Meconium stimulates cyclooxygenase-2 expression in rat lungs. Prostaglandins Leukot Essent Fatty Acids 1999; 60: 107-10.

[11] Uotila PJ and Kaapa PO. Cyclooxygenase-2 expression in human monocytes stimulated by meconium. Lancet 1998; 351: 878.

[12] Ethridge RT, Chung DH, Slogoff M, Ehlers RA, Hellmich MR, Rajaraman S, Saito H, Uchida T and Evers BM. Cyclooxygenase-2 gene disruption attenuates the severity of acute pancreatitis and pancreatitis-associated lung injury. Gastroenterology 2002; 123: 1311-22.

[13] Masood A, Yi M, Lau M, Belcastro R, Li J, Kantores C, Pace-Asciak CR, Jankov RP and Tanswell AK. Cyclooxygenase-2 inhibition partially protects against 60% 02 -mediated lung injury in neonatal rats. Pediatr Pulmonol 2014; 49: 991-1002.

[14] Terao Y, Nakamura T, Morooka H and Sumikawa K. Effect of cyclooxygenase-2 inhibitor pretreatment on gas exchange after hydrochloric acid aspiration in rats. J Anesth 2005; 19: 257-9.

[15] Fukunaga K, Kohli P, Bonnans C, Fredenburgh LE and Levy BD. Cyclooxygenase 2 plays a piv-

otal role in the resolution of acute lung injury. J Immunol 2005; 174: 5033-39.
[16] Jinzhou Z, Tao H, Wensheng C, Wen W, Jincheng L, Qin C, Hailong Z, Weiyong L and Dinghua Y. Cyclooxygenase-2 suppresses polymorphonuclear neutrophil apoptosis after acute lung injury. J Trauma 2008; 64: 1055-60.
[17] Li H, Bradbury JA, Dackor RT, Edin ML, Graves JP, DeGraff LM, Wang PM, Bortner CD, Maruoka S, Lih FB, Cook DN, Tomer KB, Jetten AM and Zeldin DC. Cyclooxygenase-2 regulates Th17 cell differentiation during allergic lung inflammation. Am J Respir Crit Care Med 2011; 184: 37-49.
[18] O'Brien G, Shields CJ, Winter DC, Dillon JP, Kirwan WO and Redmond HP. Cyclooxygenase-2 plays a central role in the genesis of pancreatitis and associated lung injury. Hepatobiliary Pancreat Dis Int 2005; 4: 126-9.
[19] Song AM, Bhagat L, Singh VP, Van Acker GG, Steer ML and Saluja AK. Inhibition of cyclooxygenase-2 ameliorates the severity of pancreatitis and associated lung injury. Am J Physiol Gastrointest Liver Physiol 2002; 283: G1166-74.
[20] Mokra D, Drgova A, Mokry J, Bulikova J, Pullmann R, Durdik P, Petraskova M and Calkovska A. Combination of budesonide and aminophylline diminished acute lung injury in animal model of meconium aspiration syndrome. J Physiol Pharmacol 2008; 59 Suppl 6: 461-71.
[21] Castellheim A, Pharo A, Fung M, Saugstad OD and Mollnes TE. Complement C5a is a key mediator of meconium-induced neutrophil activation. Pediatr Res 2005; 57: 242-7.
[22] Mokra D, Drgova A, Pullmann R Sr and Calkovska A. Selective phosphodiesterase 3 inhibitor olprinone attenuates meconium-induced oxidative lung injury. Pulm Pharmacol Ther 2012; 25: 216-22.
[23] Liu KX, Wu WK, He W and Liu CL. Ginkgo biloba extract (EGb 761) attenuates lung injury induced by intestinal ischemia/reperfusion in rats: roles of oxidative stress and nitric oxide. World J Gastroenterol 2007; 13: 299-305.
[24] Vidyasagar D, Lukkarinen H, Kaapa P and Zagariya A. Inflammatory response and apoptosis in newborn lungs after meconium aspiration. Biotechnol Prog 2005; 21: 192-7.
[25] Castellheim A, Lindenskov PH, Pharo A, Fung M, Saugstad OD and Mollnes TE. Meconium is a potent activator of complement in human serum and in piglets. Pediatr Res 2004; 55: 310-8.
[26] de Beaufort AJ, Pelikan DM, Elferink JG and Berger HM. Effect of interleukin 8 in meconium on in-vitro neutrophil chemotaxis. Lancet 1998; 352: 102-5.
[27] Jones CA, Cayabyab RG, Kwong KY, Stotts C, Wong B, Hamdan H, Minoo P and deLemos RA. Undetectable interleukin (IL)-10 and persistent IL-8 expression early in hyaline membrane disease: a possible developmental basis for the predisposition to chronic lung inflammation in preterm newborns. Pediatr Res 1996; 39: 966-75.
[28] Perng DW, Wu YC, Tsai MC, Lin CP, Hsu WH, Perng RP and Lee YC. Neutrophil elastase stimulates human airway epithelial cells to produce PGE2 through activation of p44/42 MAPK and upregulation of cyclooxygenase-2. Am J Physiol Lung Cell Mol Physiol 2003; 285: L925-30.
[29] Tilley SL, Coffman TM and Koller BH. Mixed messages: modulation of inflammation and immune responses by prostaglandins and thromboxanes. J Clin Invest 2001; 108: 15-23.
[30] Vancheri C, Mastruzzo C, Sortino MA and Crimi N. The lung as a privileged site for the beneficial actions of PGE2. Trends Immunol 2004; 25: 40-6.
[31] Montuschi P, Kharitonov SA, Ciabattoni G and Barnes PJ. Exhaled leukotrienes and prostaglandins in COPD. Thorax 2003; 58: 585-588.
[32] N'Guessan PD, Hippenstiel S, Etouem MO, Zahlten J, Beermann W, Lindner D, Opitz B, Witzenrath M, Rosseau S, Suttorp N and Schmeck B. Streptococcus pneumoniae induced p38 MAPK- and NF-kappaB-dependent COX-2 expression in human lung epithelium. Am J Physiol Lung Cell Mol Physiol 2006; 290: L1131-8.
[33] Tai HY, Tam MF, Chou H, Peng HJ, Su SN, Perng DW and Shen HD. Pen ch 13 allergen induces secretion of mediators and degradation of occludin protein of human lung epithelial cells. Allergy 2006; 61: 382-8.
[34] Lindenskov PH, Castellheim A, Aamodt G and Saugstad OD. Meconium induced IL-8 production and intratracheal albumin alleviated lung injury in newborn pigs. Pediatr Res 2005; 57: 371-7.
[35] Yamada T, Minakami H, Matsubara S, Yatsuda T, Kohmura Y and Sato I. Meconium-stained amniotic fluid exhibits chemotactic activity for polymorphonuclear leukocytes in vitro. J Reprod Immunol 2000; 46: 21-30.