

Original Article

Clinicopathological significance of BTF3 expression in cervical cancer

Feng Gao¹, Min Yao², Xiaomeng Wang¹, Hao Wang³, Dawei Wang³, Tao Sun⁴

¹Department of Pathology, The Third Hospital of Hebei Medical University, Shijiazhuang 050051, Hebei Province, P. R. China; ²Department of Biochemistry, Hebei Medical University, Shijiazhuang 050017, Hebei Province, P. R. China; ³Department of Stomatology, The Third Hospital of Hebei Medical University, Shijiazhuang 050051, Hebei Province, P. R. China; ⁴Department of Orthopaedics, The Third Hospital of Hebei Medical University, Shijiazhuang 050051, Hebei Province, P. R. China

Received September 7, 2015; Accepted February 2, 2016; Epub April 15, 2016; Published April 30, 2016

Abstract: Basic transcription factor 3 (BTF3), a general RNA polymerase II transcription factor, is aberrantly expressed in several kinds of malignancies including cervical cancer. Applying immunohistochemistry, we detected BTF3 in cervical cancers (n=87) and normal tissues (n=38), and analyzed its relationships with clinicopathological variables. Our results showed that BTF3 staining significantly increased from normal tissue to cervical cancer. BTF3 expression was increased from worse differentiation to better differentiation (38% vs.72%, P=0.0019). And BTF3 expression was decreased from cervical cancers in stage I and II to those in stage III and IV (76% vs. 37%, P=0.00028). In conclusion, BTF3 overexpression may be an early event in cervical cancer development and could be a useful biomarker for the early stage of cervical cancer.

Keywords: Basic transcription factor 3, cervical cancer, squamous cell carcinoma, immunohistochemistry

Introduction

Basic transcription factor 3 (BTF3), a 27-kD protein, is a general RNA polymerase II transcription factor which is evolutionary conserved and presents in a variety of mammalian cells [1, 2]. Previous studies indicated that BTF3 was not only essential for specific, *in vitro* initiation of transcription, but also biological important during development because mouse embryos, homozygous for a loss of function mutation in the BTF3 gene, died at the early stage of development [3].

Furthermore, aberrant expressions of BTF3 were found in different tumors. For instance, BTF3 expression is associated with enhanced cell proliferation, reduced cell cycle regulation and apoptosis and its silencing decreased colony forming and proliferation of gastric cancer cells [4]. BTF3 overexpression may be an early event in colorectal cancer development and could be a useful biomarker for the early stage of colorectal cancer [5]. BTF3 is overexpressed

in prostate carcinoma [6]. More recently, BTF3 is also found overexpressed in transitional endoplasmic reticulum isolated from dissected liver tumor nodules of aflatoxin B1-treated rats [7].

Cervical cancer is heralded as the third most common cancer of women in the world. Cervical cancer is the first killer of women with neoplasm in most developing countries [8]. Previous studies on BTF3 were focus on adenocarcinoma, however, the expression pattern of BTF3 is still unknown in squamous cell carcinoma. In the present study, applying immunohistochemistry, we examined BTF3 expression in 87 cervical cancer samples and analyzed its relationships with clinicopathological variables.

Materials and methods

Patient samples

Formalin-fixed paraffin-embedded sections consecutively collected from 87 patients with

BTF3 and cervical cancer

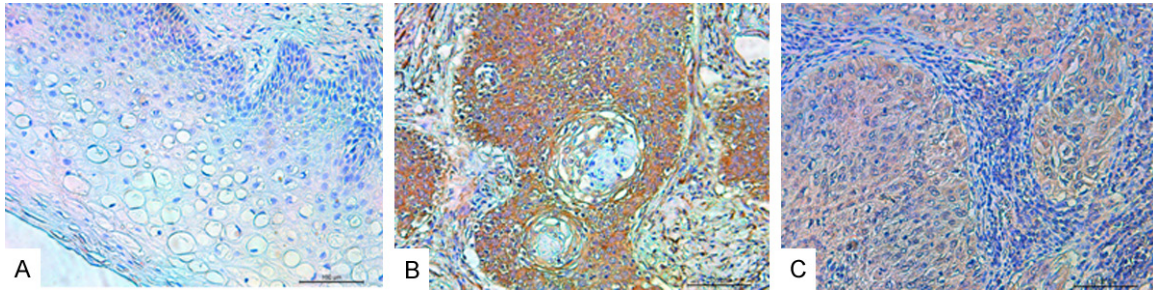


Figure 1. Expression of BTF3 in normal tissue (A, negative), better differentiation cervical cancers (B, strong) and worse differentiation cervical cancers (C, weak).

cervical cancer were used for immunohistochemical staining. The patients underwent surgical resection at the Third Hospital of Hebei Medical University, between 2007 and 2012. Immunohistochemical staining also included adjacent normal tissue specimens (n=38). This study was carried out with medical ethical committee approval, and informed consent in writing was obtained from each patient. The patients' age (range from 32 to 55, mean age 45 years), tumor stage, differentiation were obtained from surgical and pathological records from the hospital. Tumor differentiation was graded as better (including good and moderate tumors) or worse (including poor and undifferentiated tumors).

Immunohistochemical assay

Paraffin-embedded tissue sections (4 μ m) were deparaffinized with xylene and rehydrated in graded ethanol solutions. Endogenous horseradish peroxidase activity was blocked by pre-treatment with 3% H₂O₂ for 10 min at room temperature. Antigen recovery was performed using a microwave. To block nonspecific binding, the sections were incubated at 37°C for 30 min in phosphate buffer saline (PBS) containing 10% goat serum. Finally, the sections were incubated with the mouse monoclonal antibody against BTF3 (1:200, Santa Cruz Biotechnology, Inc., Santa Cruz, CA, USA), overnight at 4°C. On the next day, after incubation with the PV-9000 Polymer Detection System (Zhongshan Golden Bridge Biotechnology, Beijing, China), the sections were stained with 3,3-diaminobenzidine (DAB) and counterstained with hematoxylin. Negative controls were obtained by replacing the primary antibody with PBS.

The sections were microscopically examined and scored independently by two investigators

(Feng Gao and Dawei Wang) without any knowledge of the clinicopathological or biological data. The cytoplasmic staining intensity was scored as negative (<5% positive cells), weak, moderate or strong. The cases with discrepant scoring were re-evaluated individually until both investigators agreed on the scoring. The remaining were re-examined by the two investigators together using a dual-headed microscope in order to reach a consensus score. To avoid artificial effects, areas with necrosis, poor morphology or in the margins of the sections, were not considered.

Statistical analysis

Data were analyzed with SPSS 21.0 (SPSS software, Inc., Armonk, NY). The χ^2 method was used to determine differences of BTF3 expression between normal tissues and cervical cancers, as well as relationships of BTF3 expression in cervical cancers with clinicopathological variables. Two-sided *p* values <0.05 were considered statistically significant.

Results

BTF3 expression in normal tissues and cervical cancers

BTF3 staining was mainly present in the cytoplasm of normal epithelial and tumor cells (**Figure 1**). Because of the clinicopathological similarities, we combined the negative, weak, and moderate cytoplasmic staining intensity samples as weak group and the strong staining intensity samples as strong group for further analyses. The frequency of strong BTF3 staining significantly increased from normal tissues to cervical cancers (29% vs. 59%, *P*=0.0023).

Table 1. BTF3 expression in relation to clinicopathological features

Variable	Cytoplasmic staining		P value
	Weak	Strong	
Age (year)			0.69
>45	14 (39%)	22 (61%)	
≤45	22 (43%)	29 (57%)	
Stage			0.00028
I+II	12 (24%)	37 (76%)	
III+IV	24 (63%)	14 (37%)	
Growth pattern			0.32
Expansive	21 (38%)	35 (63%)	
Infiltrative	15 (48%)	16 (52%)	
Differentiation			0.00198
Better	15 (28%)	38 (72%)	
Worse	21 (62%)	13 (38%)	

BTF3 expression in relation to clinicopathological features

BTF3 expression was related to tumor stage (**Table 1**). Regarding the tumor stage, We combined stage I with II, as well as stage III with IV, and BTF3 expression was decreased from cervical cancers in stage I and II to those in stage III and IV (76% vs. 37%, $P=0.00028$; **Table 1**). BTF3 expression was increased from worse differentiation to better differentiation (38% vs. 72%, $P=0.0019$; **Table 1**). BTF3 expression was not related to age and growth pattern (61% vs. 57%, $P=0.69$; 63% vs. 52%, $P=0.32$ respectively; **Table 1**).

Discussion

Although certain advances have been achieved in the early detection and systemic treatment of cervical cancer, the precise mechanisms underlying cervical carcinogenesis remained elusive. Previous studies have suggested that carcinogenesis is closely associated with the aberrant expression of certain proteins associated with cell signaling regulation. These genetic and molecular events ultimately contribute to the initiation and progression of tumors [8, 9]. Abnormal BTF3 expressions were detected in a variety of mammalian cells [1, 2]. It may be frequently upregulated in cervical cancer, leading to different pathophysiological effects in this malignancy. So in the present study, we found that BTF3 overexpression in cervical cancer was related with differentiation and tumor stage.

We found that BTF3 expressed in the cytoplasm of both squamous cells in normal tissue and cancer cells in cervical cancer. However, the cytoplasmic staining of BTF3 was obviously upregulated in cervical cancers than that in the normal tissues. Possible explanation for this phenomenon was partly because that BTF3 could bind to newly synthesized polypeptide chains that emerged from the ribosome [10], and then was translocated to the nucleus. However, the translocation of BTF3 from the cytoplasm to the nucleus was aberrant when the cervical cancer development and caused the BTF3 storage in the cytoplasm. Further studies are needed to experimentally verify this phenomenon and need to elucidate the underlying mechanism.

In this study, we found that the frequency of BTF3 expression was higher in better differentiation cancers than that in worse differentiation ones. That means BTF3 reduce its function with the increase of malignant degree in cervical cancer. This is totally different from the results of previous study on human brain astrocytomas, also known as glioblastoma multiforme, which showed that the level of BTF3 expression was higher in the high grade astrocytoma than that in the indolent low-grade astrocytomas [11]. In stage I and II cervical cancers, BTF3 reached the peak level, then decreased to stage III and IV cancers. This expression pattern of BTF3 in cervical cancers was similar to that in colorectal cancer [5]. Wang *et al.* [5] also found that BTF3 overexpression may be an early event in colorectal cancer development and could be a useful biomarker for the early stage of colorectal cancer and its overexpression had positive correlations with some tumor-associated genes. So it indicated that overexpression of BTF3 maybe an early event in cervical cancer development, rather than a key role in the progression.

In conclusion, BTF3 overexpression may be an early event in cervical cancer development and could be a useful biomarker for the early stage of cervical cancer.

Acknowledgements

The authors thank Dr. Y.X. Gu for the help in the experiment. This study was supported by grants from the Health Department of Hebei Province, China (Grant No. 20120098).

Disclosure of conflict of interest

None.

Address correspondence to: Dr. Dawei Wang, Department of Stomatology, The Third Hospital of Hebei Medical University, 139 Ziqiang Road, Shijiazhuang 050051, Hebei Province, P. R. China. E-mail: davi6789@163.com

References

- [1] Kusumawidjaja G, Kayed H, Giese N, Bauer A, Erkan M, Giese T, Hoheise JD, Friess H and Kleeff J. Basic transcription factor 3 (BTF3) regulates transcription of tumor-associated genes in pancreatic cancer cells. *Cancer Biol Ther* 2007; 6: 367-376.
- [2] Zheng XM, Black D, Chambon P and Egly JM. Sequencing and expression of complementary DNA for the general transcription factor BTF3. *Nature* 1990; 344: 556-559.
- [3] Deng JM and Behringer RR. An insertional mutation in the BTF3 transcription factor gene leads to an early postimplantation lethality in mice. *Transgenic Res* 1995; 4: 264-269.
- [4] Liu Q, Zhou JP, Li B, Huang ZC, Dong HY, Li GY, Zhou K and Nie SL. Basic transcription factor 3 is involved in gastric cancer development and progression. *World J Gastroenterol* 2013; 19: 4495-4503.
- [5] Wang CJ, Franbergh-Karlson H, Wang DW, Arbman G, Zhang H and Sun XF. Clinicopathological significance of BTF3 expression in colorectal cancer. *Tumour Biol* 2013; 34: 2141-2146.
- [6] Symes AJ, Eilertsen M, Millar M, Nariculam J, Freeman A, Notara M, Feneley MR, Patel HR, Masters JR and Ahmed A. Quantitative analysis of BTF3, HINT1, NDRG1 and ODC1 protein over-expression in human prostate cancer tissue. *PLoS One* 2013; 8: e84295.
- [7] Roy L, Laboissiere S, Abdou E, Thibault G, Hamel N, Taheri M, Boismenu D, Lanoix J, Kearney RE and Paiement J. Proteomic analysis of the transitional endoplasmic reticulum in hepatocellular carcinoma: an organelle perspective on cancer. *Biochim Biophys Acta* 2010; 1804: 1869-1881.
- [8] McGraw SL and Ferrante JM. Update on prevention and screening of cervical cancer. *World J Clin Oncol* 2014; 5: 744-752.
- [9] Sun Y, Zhang R, Zhou S and Ji Y. Overexpression of Notch1 is associated with the progression of cervical cancer. *Oncol Lett* 2015; 9: 2750-2756.
- [10] Rospert S, Dubaquié Y and Gautschi M. Nascent-polypeptide-associated complex. *Cell Mol Life Sci* 2002; 59: 1632-1639.
- [11] Odreman F, Vindigni M, Gonzales ML, Niccolini B, Candiano G, Zanotti B, Skrap M, Pizzolitto S, Stanta G and Vindigni A. Proteomic studies on low- and high-grade human brain astrocytomas. *J Proteome Res* 2005; 4: 698-708.