

Original Article

Effect of hemoperfusion on acute injury induced by acute organic phosphorus pesticide poisoning

Aihua Zhao¹, Ailan Chen¹, Qinglong Guan², Jixue Shi¹

Departments of ¹Emergency Medicine, ²Interventional Radiology, Affiliated Hospital of Taishan Medical University, No. 706, Taishan Street, Tai'an 271000, China

Received January 15, 2016; Accepted April 6, 2016; Epub December 15, 2016; Published December 30, 2016

Abstract: Objective: This study is to investigate the effect of hemoperfusion (HP) on acute lung injury induced by acute organophosphorus pesticide poisoning (AOPP). Methods: A total of 64 cases of patients with AOPP induced acute pulmonary edema from January 2013 to June 2014 were enrolled in this study. The patients were randomly divided into control group (receiving conventional medical treatment) and HP group (receiving medical treatment + hemoperfusion treatment). At the time of 0 h, 24 h, 48 h and 72 h after hospitalization, chest X-ray, blood gas analysis, acetylcholinesterase (AChE) activity assay and percutaneous lung puncture biopsy were performed. Results: As the time went on, general clinical manifestations such as difficulty breathing in HP group was better compared with control group ($P < 0.05$). Chest X-ray showed that pulmonary edema in HP group was less serious than that in control group ($P < 0.05$). Blood gas analysis found that PO_2 in HP group was higher whereas PCO_2 was lower than those in control group ($P < 0.05$). Conclusion: HP treatment could reduce the incidence of acute pulmonary edema and increase the curative rate for AOPP patients.

Keywords: Organophosphorus pesticide poisoning, hemoperfusion, acute pulmonary edema

Introduction

There are many causes of acute poisoning, among which, pesticide poisoning is the most common reason [1]. Organophosphorus pesticide is the most widely used pesticide [2]. Compared to the other pesticides, organophosphorus pesticide has low toxicity to mammals [3]. Thus, it has been applied increasingly in most countries, and as a result, the incidence of acute organophosphorus pesticide poisoning (AOPP) increases greatly. In developing countries, AOPP are quite common among emergency and ICU hospitalized patients [4].

The symptom of AOPP has three consecutive phases: clinical acute cholinergic crisis, intermediate syndrome (IMS) and organophosphorus pesticide induced delayed neuropathy (OPIDN) [5]. AOPP is generally divided into mild, moderate and severe poisoning, and its pathology is mainly due to decreased activity of cholinesterase (AChE) [6]. AChE activity decreasing to 50-70% of the normal value is mild poisoning, and it mainly manifests as headache, dizziness, nausea, vomiting, blurred vision, hydro-

sis, weakness, dizziness, myosis and other M symptoms [7]. AChE activity decreasing to 30-50% of the normal value is moderate poisoning. In addition to M like syndromes, symptoms named N symptoms like muscle tremors, mild dyspnea, abdominal pain, diarrhea, salivation, significantly reduced pupil also can appear [7]. AChE activity decreasing to below 30% of the normal value is defined as severe poisoning and difficult breathing, muscle tremors, needle like miosis, coma, and incontinence may appear [7].

AChE level also have a role in guiding oxime treatment and determining the discharge time of the mild poisoning patients [8]. The more active ingredients the pesticide contains, the higher toxicity it is, and the higher poisoning death rate it will cause [9]. AOPP complicated with acute pulmonary edema is the most common clinical manifestation of AOPP, and its incidence rate is 20%-30% [10]. AOPP complicated with pulmonary edema is easy to be ignored in the early stage, thus leading to respiratory failure. This is also a common cause of AOPP induced death. In this study, the effect of hemo-

perfusion (HP) on acute lung injury induced by AOPP was investigated.

Materials and methods

Patients' data

A total of 64 cases of patients met the diagnostic criteria of AOPP [11] and hospitalized from January 2013 to June 2014 in our hospital were enrolled in this study. Among them 44 cases were found with acute pulmonary edema, accounting for 68.7% of the total case number. In the 44 cases, 24 cases were male and 20 cases were female, aged from 20 years old to 70 years old with the average age of 45 years old. The patients were divided into control group (conventional medical treatment) and hemoperfusion (HP) group (conventional medical treatment + HP treatment) according to random choice. There was no significant difference among patients in the two groups ($P > 0.05$). Prior written and informed consent were obtained from all patients and the study was approved by the ethics review board of Taishan Medical University.

Blood gas analysis

At the time of 0 h, 24 h, 48 h and 72 h of the diagnosis, arterial blood was collected from the left radial artery. Blood gas analysis was performed on an automatic blood gas analyzer (GEM Premier 300, Instrumentation Laboratory, USA). The conditions of PO_2 and PCO_2 at different times in both groups were compared.

AChE activity

Venous blood was collected and serum was isolated by centrifugation. At the time of 0 h, 24 h, 48 h and 72 h of the diagnosis, AChE activity was detected as previously described [12].

Chest X-ray

Once after blood collecting, chest X-ray was performed. Briefly, the patients were in supine position. Kodak Direct View 7500 X-ray machine (Carestream Health) was used. The parameters of 75 kv tube voltage, 150 MA tube current, 40 s time were used.

HE staining

Once chest X-ray was performed, percutaneous lung puncture biopsy was carried out and lung tissues were collected. Then, HE staining was

performed. Briefly, the lung tissue was fixed with 4% formaldehyde and embedded in paraffin. Paraffin-embedded tissue was sliced into 4 μ m sections continuously. Then tissue sections were dewaxed in xylene and rehydrated in graded alcohols. After washing with running water and distilled water, sections were stained with hematoxylin for 3-5 min. After washing again with running water, sections were differentiated with 1% HCl in 70% alcohol. Then sections were stained with eosin for 1-4 min after washing with running water. After dehydration and differentiation in alcohol, sections were mounted and observed under microscopy.

Statistical analysis

All the statistical analyses were performed using SPSS version 13.0 (SPSS Inc, Chicago, IL, USA) for Windows and P value less than 0.05 was considered as statistically significant. The data in each group were firstly examined using normal test and homogeneity of variance test. For the data fitting normal distribution and homogeneity of variance, single factor analysis of variance analysis (ANOVA) was performed for data collected at the same time in different groups and q test was carried out for data collected at different time in the same groups. For the data not met normal distribution and homogeneity of variance, multiple comparison analysis of Dunnett's T3 test was performed.

Results

General condition before treatment

To understand the general condition of the patients before treatment, clinical manifestations were observed. Among the 44 cases of patients, 38 cases were caused by poison intake and local damage including congestion and edema of throat and different degree of mucosa injury was found. The other 6 cases were skin contact poisoning, and mainly manifested as allergic dermatitis. The patients all had different degrees of muscarinic symptoms and consciousness, which were showed as extremely narrowed pupil, muscle tremors, foamy secretion, shortness of breath, double lung wet rales, skin cyanosis and damp. Additionally, some were incontinent patients.

Blood gas analysis results

To understand the condition of the AOPP patients, blood gas analysis was performed. As

Hemoperfusion effect on AOPP

Table 1. Level of PO₂ at different time points in each group

Groups	PO ₂			
	0 h	24 h	48 h	72 h
Control group	57.3 ± 1.6	63.2 ± 1.2*	74.0 ± 1.0*	87.7 ± 0.8*
HP group	62.5 ± 0.4#	78.3 ± 0.5#,*	89.5 ± 0.4#,*	94.5 ± 0.4#,*

Note: Compared with control group at the same time point, **P* < 0.05. Compared with 0 h of the same group, #*P* < 0.05.

Table 2. Level of PCO₂ at different time points in each group

Groups	PCO ₂			
	0 h	24 h	48 h	72 h
Control group	52.3 ± 1.6	43.2 ± 1.2*	34.0 ± 1.0*	27.7 ± 0.8*
HP group	50.5 ± 0.4#	38.3 ± 0.5#,*	30.5 ± 0.4#,*	24.5 ± 0.4#,*

Note: Compared with control group at the same time point, **P* < 0.05. Compared with 0 h of the same group, #*P* < 0.05.

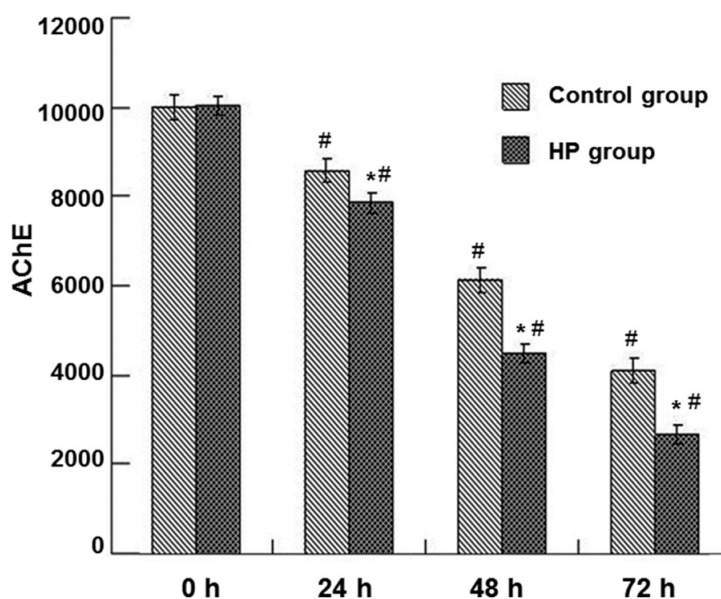


Figure 1. Whole blood AChE activity at different time points in both groups. Compare with control group at the same time point, **P* < 0.05. Compare with 0 h of the same group, #*P* < 0.05.

the time went on, PO₂ (Table 1) gradually increased (*P* < 0.05) whereas PCO₂ (Table 2) decreased (*P* < 0.05) in arterial blood in both groups. At the same time points, compared with the control group, PO₂ content in HP group was significantly higher (*P* < 0.05) while PCO₂ was lower (*P* < 0.05). The result argued that HP treatment had better curative effect than common medical therapy.

AChE activity

AChE activity is a direct index reflecting AOPP condition. To better understand the situation of

the patients, AChE activity in venous blood was detected. As show in Figure 1, AChE activity was gradually decreased in both groups as time went by (*P* < 0.05). And, AChE activity in HP group was lower than that of the control group (*P* < 0.05). The result further suggested that HP had better curative effect than common medical therapy.

Chest X-ray results

To understand the progress of the disease, chest X-ray was performed. Basically, the disease could be divided into three stages according to the development. The first stage was pulmonary congestion, which was showed as pulmonary hilar enlargement, edge blur and increased lung markings (For example, Figure 2, HP group at 72 h). The second stage was pulmonary interstitial edema. Because of the edema in the bronchi and blood vessels, this stage was characterized by the performance of pulmonary hilar enlargement and edge blur. Enlargement of the heart was associated in most of the patients and pleural effusion was found in a small amount of the cases (For example, Figure 2, control group at 0 h). The final stage was alveolar pulmonary edema, which was showed as low density, uniform and blur edge of large and small pieces of shadows, with the internal lung zone the most obvious (For example, Figure 2, HP group at 0 h). In most cases, the three periods existed at the same time. Diffuse irregular shadows were found in most of the cases and a few were unilateral. Edema was significantly absorbed and disappeared after treatment. Together, the results argued that HP could reduce AOPP induced acute pulmonary edema.

HE staining results

In order to observe the lung morphology at different time points, HE staining was performed. As shown in Figure 3, infiltration of inflammatory cells was found in lung tissues at all the

Hemoperfusion effect on AOPP

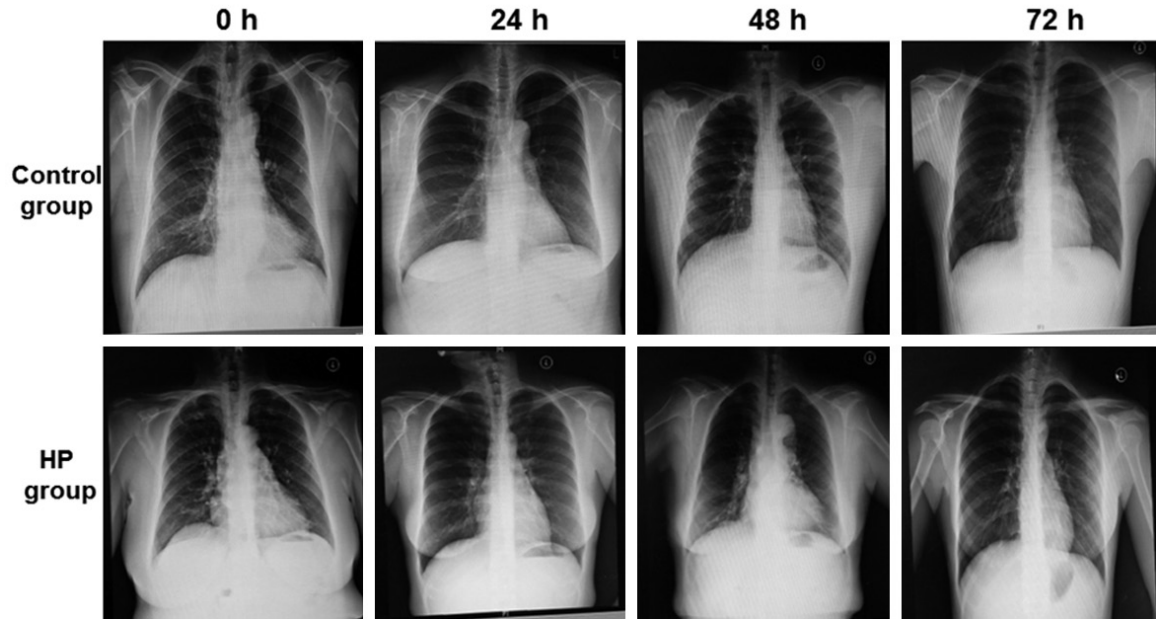


Figure 2. Comparison of X ray radiographs at each time point in both groups. X-ray was performed at 0 h, 24 h, 48 h and 72 h. The representative images of control group were shown in the upper panel. The representative images of HP group were shown in the lower panel.

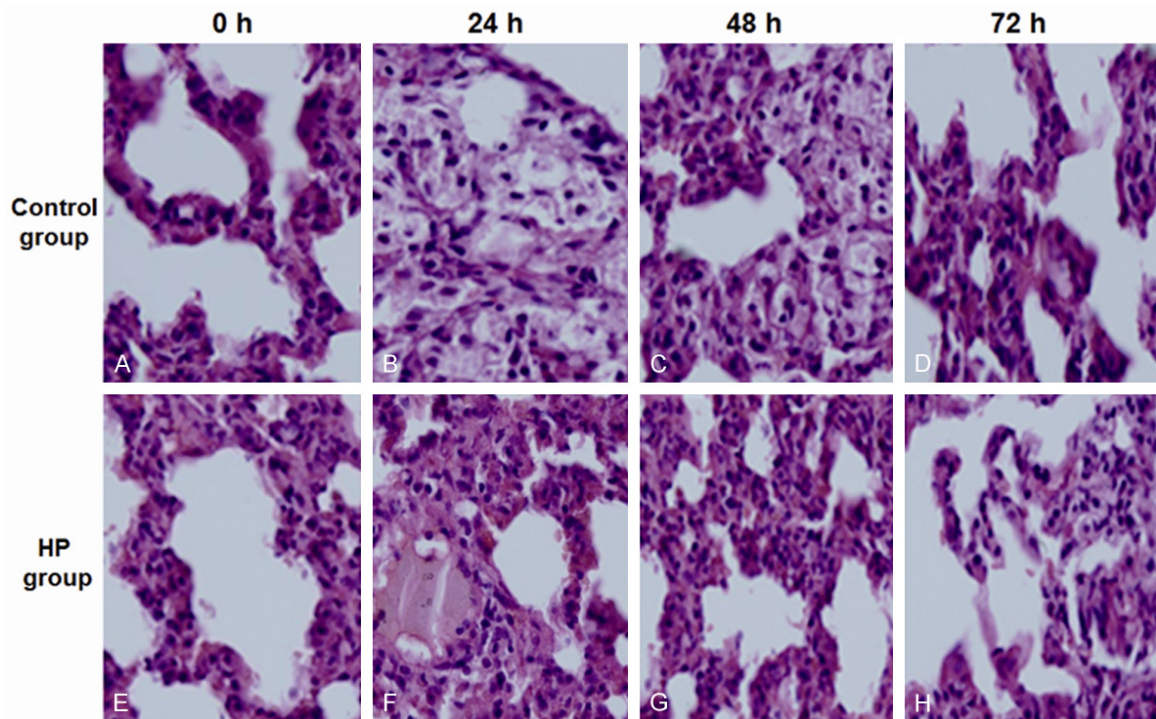


Figure 3. Lung morphology at each time point in both groups (Control group: A, B, C, D; HP group: E, F, G, H). HE staining was performed to observe lung morphology at 0 h, 24 h, 48 h and 72 h. The representative images of control group were shown in the upper panel. The representative images of HP group were shown in the lower panel.

time and neutrophils and macrophages increased most obviously. Alveolar wall was dis-

rupted, alveolar cavity was filled with pink edema fluid and vitreous membranes were par-

tially formed. Diffuse pulmonary hemorrhage and alveolar cavity collapse were found in severe cases. As the time went on, injury degree of the lung tissue in each group gradually reduced. To sum up, the results showed that common medical therapy combined with HP could reduce the inflammatory factors and reduce pulmonary edema.

Discussion

According to previous study, gastrointestinal reaction within 24 h is the main clinical manifestation of poisoning and this situation will further develop into a continuous and multiple organ injury [13]. In addition, it is reported that AOPP can induce nervous system damage by inflammatory reaction [14]. The main mechanisms of AOPP induced acute pulmonary edema are as follows. First, AOPP can cause M receptor hyperactivity, thus leading to a large number of secretions in the respiratory tract and pulmonary edema [11, 13-16]. Second, sympathetic over activity can induce pulmonary venous spasm [17]. As a result, the increased pulmonary capillary pressure may lead to leakage of plasma components in the pulmonary capillaries into the alveolar, resulting in pulmonary ventilation dysfunction eventually. Third, the bronchial mucosa glands are activated by acetylcholine, which leads to increased secretion of mucus. Hence, the lumen is filled with liquid that is hard to be discharged, which further leads to poor ventilation, severe hypoxia, aggravated dyspnea and death [18]. This is a major cause of death in patients with pulmonary edema [19].

The conventional treatment methods of AOPP in clinical are given below. At first, the poison should be removed [20]. For the patients who are mild poisoning or are conscious and can cooperate, poison removal should be carried as soon as possible. Emetic and gastric lavage treatments are the commonly used measures. Secondly, use of atropine is of great importance to AOPP treatment. Atropine is an anticholinergic drug which affects M receptor. It can effectively fight against respiratory failure caused by respiratory inhibition and pulmonary edema [21]. The principles of early application, full dose, reversal and atropinization should be followed. The main purpose of atropine application is to inhibit part of M like symptoms and prevent cardiac arrest. Thirdly, application of

reactivation agent is crucial to deal with AOPP caused early respiratory failure. In the past 50 years, in addition to pyraloxime iodide, only a few kinds of oxime have been used for organic phosphorus poisoning [22]. The mostly used oxime in clinical is pralidoxime chloride, which, can resurrect phosphorylated AChE [23], rapidly hydrolyze the accumulated AChE and get rid of central and respiratory muscle paralysis respiratory failure. Early application, full dose and accurate application of reactivation agent should be taken. In this study, the dosage of pralidoxime chloride was 6-8 g/d, which showed a good effect.

Central and peripheral respiratory tract management should be performed synchronously to treat respiratory failure caused by AOPP. In this study, AChE activity in each group was determined and the result showed that as the time went on, the activity of AChE in blood decreased gradually. In addition, AChE activity decline was higher in HP group than that of the control group. The toxicity caused by increased AChE activity can increase pulmonary capillary permeability and induce acute pulmonary edema [24]. The large amount of respiratory tract secretion can interfere oxygen exchange and alveolar diffusion, as a result, obvious hypoxia and extreme difficulty breathing will occur [25]. In the treatment of patients with severe AOPP complicated with acute pulmonary edema, special attention should be paid to the blood gas analysis, and when it is difficult to correct hypoxemia or there is retention of carbon dioxide, tracheal intubation should be applied as early as possible. Ventilator therapy on early stage not only can timely and effectively treat respiratory failure but also is convenient for airway management. Mechanical ventilation of suction, atomization and humidification should be performed as soon as possible and meanwhile, nursing care should be strengthened.

HP is a blood purification technology to remove the harmful metabolites or exogenous toxins of the body (mainly are non-polarity, low polarity and hydrophobic molecules) [26]. HP is commonly used in the treatment for drug poisoning or toxin poisoning, especially for insoluble or fat soluble drugs and poisons [27]. Studies [28, 29] have confirmed that HP can effectively remove the free components of organic phosphorus or organic phosphorus-AChE complex,

thus reducing the damage from these poisons [30]. In recent years, some small sample clinical studies found that application of HP treatment based on routine medical treatment can significantly improve the success rate and reduce the mortality rate of AOPP [31-34]. HP combined with continuous renal replacement therapy (CRRT) can remove poison and inflammatory medium for patients with severe poisoning. It provides favorable conditions for the follow-up treatment and provides a new method for the clinical treatment of AOPP [35]. In this study, a series of clinical manifestations of the patients in HP group was significantly improved while compared with the control group, which provides evidence for the clinical treatment of AOPP.

Acknowledgements

We greatly appreciate Professor Jixue Shi for his guidance in this study. Meanwhile, we thank the staff from Department of Scientific Research, Affiliated Hospital of Taishan Medical University for their helping.

Disclosure of conflict of interest

None.

Address correspondence to: Dr. Aihua Zhao, Department of Emergency Medicine, Affiliated Hospital of Taishan Medical University, No. 706, Taishan Street, Tai'an 271000, P. R. China. Tel: +86-0538-6237856; Fax: +86-0538-8420042; E-mail: tzah-333@163.com

References

- [1] Senarathna L, Jayamanna SF, Kelly PJ, Buckley NA, Dibley MJ and Dawson AH. Changing epidemiologic patterns of deliberate self poisoning in a rural district of Sri Lanka. *BMC Public Health* 2012; 12: 593.
- [2] Gupta RC. *Toxicology of organophosphate & carbamate compounds*. Academic Press, 2011.
- [3] Bayrami M, Hashemi T, Malekiran AA, Ashayeri H, Faraji F and Abdollahi M. Electroencephalogram, cognitive state, psychological disorders, clinical symptom, and oxidative stress in horticulture farmers exposed to organophosphate pesticides. *Toxicol Ind Health* 2012; 28: 90-96.
- [4] Peter JV, Sudarsan TI and Moran JL. Clinical features of organophosphate poisoning: A review of different classification systems and approaches. *Indian J Crit Care Med* 2014; 18: 735-745.
- [5] Abdollahi M. *Poisoning with anticholinesterase insecticides in Iran. Anticholinesterase pesticides: metabolism, neurotoxicity, and epidemiology*. Hoboken, NJ: Wiley & Sons, Inc 2011; 433-446.
- [6] Wang H and Long C. Effect of N receptor antagonism on the prevention and treatment of the toxic effects of Che inhibitors. *Chinese Journal of Emergency Medicine* 2004; 13: 719-720.
- [7] Zhao D. The identification and treatment of atropine overdose of organic phosphorus pesticide poisoning. *Chinese Journal of Internal Medicine* 1998; 27: 639-640.
- [8] Drossman DA. The functional gastrointestinal disorders and the Rome II process. *Gut* 1999; 45 Suppl 2: II1-5.
- [9] Peter JV and Cherian AM. Organic insecticides. *Anaesth Intensive Care* 2000; 28: 11-21.
- [10] Collombet JM. Nerve agent intoxication: recent neuropathophysiological findings and subsequent impact on medical management prospects. *Toxicol Appl Pharmacol* 2011; 255: 229-241.
- [11] Marrs TT, Maynard RL and Sidell F. *Chemical warfare agents: toxicology and treatment*. John Wiley & Sons, 2007.
- [12] Menendez-Helman RJ, Ferreyroa GV, dos Santos Afonso M and Salibian A. Circannual rhythms of acetylcholinesterase (AChE) activity in the freshwater fish *Cnesterodon decemmaculatus*. *Ecotoxicol Environ Saf* 2015; 111: 236-241.
- [13] Hobbiger F. Reactivation of phosphorylated acetylcholinesterase. In: editors. *Cholinesterases and Anticholinesterase Agents*. Springer; 1963. pp. 921-988.
- [14] Moshiri M, Darchini-Maragheh E and Balali-Mood M. Advances in toxicology and medical treatment of chemical warfare nerve agents. *Daru* 2012; 20: 81.
- [15] Hagedorn I, Gundel WH and Schoene K. Reactivation of phosphorylated acetylcholine esterase with oximes: contribution to the study of the reaction course. *Arzneimittelforschung* 1969; 19: 603-606.
- [16] Bismuth C, Inns R and Marrs T. Efficacy, toxicity and clinical use of oximes in anticholinesterase poisoning. BUTTERWORTH-HEINEMANN, STONEHAM, MA(USA). 1992. 1992.
- [17] Wei J. Treatment for acute organophosphorus pesticide poisoning complicated with pulmonary edema. *Journal of Clinical and Experimental Medicine* 2006; 5: 821.
- [18] Chen Y. *Standard for diagnosis and treatment of acute poisoning*. Nanjing: Southeast University Press; 2005.

Hemoperfusion effect on AOPP

- [19] Cavailon JM, Fitting C and Adib-Conquy M. Mechanisms of immunodysregulation in sepsis. *Contrib Nephrol* 2004; 144: 76-93.
- [20] Zeng F. Penehyclidine hydrochloride (PQN) instead of atropine for treatment of organophosphorus pesticide poisoning technology. Beijing: Military Medical Science Press; 2004.
- [21] Zhao D. The clinical relationship between the characteristics of Cholinesterase and acute organophosphorus pesticide poisoning. *Chinese Journal of Internal Medicine* 2000; 39: 653-654.
- [22] Eyer F, Meischner V, Kiderlen D, Thiermann H, Worek F, Haberkorn M, Felgenhauer N, Zilker T and Eyer P. Human parathion poisoning. A toxicokinetic analysis. *Toxicol Rev* 2003; 22: 143-163.
- [23] Xu H, Meng W, Chen L, Wen Y and WU C. The Clinical Use of Hemoperfusion in Acute Organophosphorous Insecticides Poisoning. *China Journal of Modern Medicine* 2003; 13: 100-101.
- [24] Wang J. Internal medicine. Beijing: People's Health Publishing House; 2001.
- [25] Qiu Z, Tian Y, Niu W, Shi H, Zhang S and Lin J. Analysis of the respiratory muscle paralysis induced by atropine overdosages in the treatment of pesticide poisoning. *Chinese Journal of Critical Care Medicine* 2005; 25: 183-185.
- [26] Jiang R, SHI X and Liu W. Sequential blood purification treatment of acute severe organophosphorus pesticide poisoning. *Guangdong Medical Journal* 2010; 31: 210-211.
- [27] Yu X and Lu L. Clinical analysis of 31 cases of acute severe organic phosphorus poisoning treated with blood perfusion and hemodialysis. *Chongqing Medical Journal* 2008; 37: 332.
- [28] Shen T. Treatment of severe oral organophosphorus poisoning by blood perfusion. *Chinese Journal of Emergency Medicine* 1997; 6: 229.
- [29] Cheng G and Shang L. Analysis of 23 cases of severe organophosphorus pesticide poisoning treated by blood perfusion. *Shandong Medical Journal* 2000; 3: 3.
- [30] Altintop L, Aygun D, Sahin H, Doganay Z, Guven H, Bek Y and Akpolat T. In acute organophosphate poisoning, the efficacy of hemoperfusion on clinical status and mortality. *J Intensive Care Med* 2005; 20: 346-350.
- [31] Xie H, Chen H, Sun J, Chang J and Ye H. Blood flow for treating 82 cases of severe acute organophosphorus pesticide poisoning. *Chinese Critical Care Medicine* 2005; 17: 610.
- [32] Liu Y and Xu J. Experience of blood flow in the treatment of severe acute organophosphorus pesticide poisoning. *Chinese Journal of Blood Purification* 2007; 6: 229-230.
- [33] Run L and Zhang Y. Analysis of 50 cases of severe acute organophosphorus pesticide poisoning patients treated with blood flow. *Journal of Chinese Medical Research* 2006; 6: 1038-1039.
- [34] Zong K, Mao W and Wang S. Research of blood flow in the treatment of severe acute organophosphorus pesticide poisoning. *Chinese Journal of Clinical Medicine* 2006; 5: 329-330.
- [35] Cao X, Li M, Liu S, Qiu L and Jiang Z. Clinical analysis of early tracheal intubation for acute organophosphorus pesticide poisoning patients with respiratory failure. *Sichuan Medical Journal* 2008; 29: 974-976.