

Original Article

Efficacy and safety of video-assisted thoracic surgery and median sternotomy in the treatment of thymoma-associated myasthenia gravis

Zhi-Feng He¹, Yuan-Bo Wu¹, Di Lu¹, Hai-Zhen Ni²

¹Department of Thoracic and Cardiovascular Surgery, The First Affiliated Hospital of Wenzhou Medical University, Wenzhou 325000, P. R. China; ²Department of Vascular Surgery, The First Affiliated Hospital of Wenzhou Medical University, Wenzhou 325000, P. R. China

Received February 18, 2016; Accepted May 15, 2016; Epub November 15, 2016; Published November 30, 2016

Abstract: Objective: Our study aims to explore the efficacy and safety of video-assisted thoracic surgery (VATS) and median sternotomy in the treatment of thymoma-associated myasthenia gravis (MG). Methods: The clinical data of 73 patients with thymoma-associated MG from January 2004 to January 2010 in our hospital were analyzed retrospectively. The clinical curative effect, postoperative MG crisis and quality of life of patients with thymoma-associated MG after treated by VATS and median sternotomy were compared. Results: Patients with thymoma-associated MG after treated by VATS and median sternotomy both obtained well curative effects. The intraoperative bleeding volume, postoperative thoracic drainage time, postoperative hospitalization time and intensive care unit (ICU) monitoring time in the VATS group were shorter than that in the median sternotomy group (all $P < 0.05$). The quantitative myasthenia gravis (QMG) score and 15-item myasthenia gravis quality of life scale (MG-QOL15) score of the two groups were significantly improved compared with that before operation (all $P < 0.05$). With the growth of postoperative time, Δ QMG score and Δ MG-QOL15 score were first increased and then decreased in two groups. One year after operation in the VATS group, Δ QMG score and Δ MG-QOL15 score were significantly higher than that in the median sternotomy group (all $P < 0.05$). The occurrence rate of complications especially postoperative MG crisis were significantly higher ($P < 0.05$) while the 5-year mortality rate was slightly higher ($P > 0.05$) in the median sternotomy when compared to that in the VATS group. Conclusion: VATS is more secure than the median sternotomy in patients with thymoma-associated MG; it can also reduce the occurrence of postoperative MG crisis.

Keywords: Thymoma, myasthenia gravis, thymoma-associated myasthenia gravis, video-assisted thoracic surgery, median sternotomy, quantitative myasthenia gravis, 15-item myasthenia gravis quality of life scale, curative effect

Introduction

Thymomas are defined as rare tumors which arising from thymic epithelial cells, with an incidence of 0.15 cases for 100,000 persons annually [1]. Thymomas consist of World Health Organization (WHO) type A, AB, B1, B2, B3, as well as rare other histological subtypes [2]. Thymomas are rare with the age of less than 25 years old but show a wide age distribution (<10 to >80 years old) with no major sex predilection [3]. The most commonly seen anatomic site is in the anterior mediastinum, while in some rare instances, thymomas might also arise in the neck, lung, and pleura [4]. It was estimated that approximately 30%~50% of thymomas patients

would also have myasthenia gravis (MG), an autoimmune disease with the characteristics of dysfunctional neuromuscular junctions which were targeted by pathogenic autoantibodies to acetylcholine receptor (AChR) [5]. MG is by far the most common of all the disorders in thymomas, as 24.5%~40% of thymoma patients develop MG, while 15%~20% of MG patients have a thymoma [6, 7]. Differs from those of non-thymomatous MG, the clinical features of thymoma-associated MG include a more severe involvement of MG, the expansion of other autoimmune diseases, and MG relapse attaching to thymoma recurrence [8]. The preferred treatment for thymoma-associated MG remains controversial, and the recognized options for

Comparison of VATS and median sternotomy

surgical intervention are median sternotomy together with video-assisted thoracic surgery (VATS) [9].

Median sternotomy, also known as trans-sternal (TS) thymectomy, is considered to be the “gold standard” method to thymoma for decades, based on the reason that median sternotomy can identify and manage large tumors and local invasion intraoperatively [10]. Generally, median sternotomy is capable of completely resect the thymus, tumor, thymic cervical extensions, as well as the surrounding perithymic fat [11]. Increasingly, minimally VATS has replaced median sternotomy, and gain much acceptance as an effective and technically sound treatment for the early stage thymoma [12]. It was demonstrated that VATS showed superior perioperative outcomes, including decreased incidence of pneumonia, arrhythmias, pain and lower levels of inflammatory markers when compared with conventional thoracotomy [13]. Studies have found that these two approaches (median sternotomy and VATS) result in similar remission rates, as assessed by pharmacological remission, rates of complete stable remission, or minimal manifestations [14, 15]. Other studies were, in contrary, restricted by the short time of follow-up, sole inclusion of early stage tumors, as well as failure to compare the median sternotomy and VATS [16, 17]. Indeed, a recent study stressed that VATS thymectomy for thymoma-associated MG was a safe method technically, but the effectiveness of VATS was hard to determine for the lack of sufficient data, especially in the long run [18]. Therefore, it remains uncertainty whether VATS would be preferable than median sternotomy in patients with thymoma-associated MG. Consequently, the present feasibility study aims to compare the efficacy and safety of median sternotomy and VATS for the treatment of thymoma-associated MG.

Material and methods

Ethnic statements

The study was approved by the Institutional Review Boards of, the First Affiliated Hospital of Wenzhou Medical University. Written informed consent was obtained from each eligible participant and the study was performed in accordance with the Declaration of Helsinki [19].

Subjects

The clinical data of 73 patients with thymoma-associated MG from January 2004 to January 2010 in our hospital were analyzed retrospectively, including 39 patients with VATS and 34 patients undergoing median sternotomy. In the VATS group, there were 39 patients (27 males and 12 females) who aged from 17~54 years old with mean age of (36.5±7.9) years old and the disease course of 15 day to 5 year. The clinical manifestations according to Myasthenia Gravis Foundation of America (MGFA) classification were divided into type I (n = 8), type IIa (n = 12), type IIb (n = 5), type IIIa (n = 7), type IIIb (n = 4), type IVa (n = 2), and type IV b (n = 1). Computed tomography (CT) examination was performed in all patients before operation, and the mass size in anterior and superior mediastinum was 1.2 cm×1.6 cm~4.2 cm×5.7 cm, and the body of mass located on the left side in 4 cases, on the right or middle in 35 cases. In the median sternotomy group, there were 34 patients (19 males and 15 females) who aged from 18~57 years old with mean age of (38.3±7.8) years old and the disease course of 22 day to 5 year. The MGFA typing was listed as follows: type I (n = 5), type IIa (n = 13), type IIb (n = 7), type IIIa (n = 3), type IIIb (n = 4), and type IVa (n = 2). CT examination in all patients before operation showed that the mass size in anterior and superior mediastinum was 1.6 cm×2.4 cm~4.2 cm×10.5 cm. Generally, the maximum diameter of the mass >6 cm or the mass infiltrated into the surrounding organs or blood vessels in imaging, TS extended thymectomy were adopted. Two groups of patients before operation took prednisone orally (10~30 mg/d). The inclusion criteria: (1) two groups of patients before operation had chest radiograph and chest CT or MRI, which prompted an anterior mediastinal mass, with the clinical manifestations of diplopia, ptosis, ocular muscle weakness, limb weakness, chewing weakness, difficulty swallowing, etc.; (2) there were no pre-operative MG crisis; (3) the monitoring data of medical history, physical examination, surgical procedure and before and after operation of all patients and follow-up data were complete. The corresponding exclusion criteria: (1) patients who refused to be followed-up; (2) in the first 3 months of treatment, patients who had used the hormones or immunosuppressive agents, or suffered from other autoimmune diseases;

Comparison of VATS and median sternotomy

(3) the diagnosis of clinical MG was not clear, and they could not rule out the Lambert-Eaton syndrome, botulinum toxin, muscular dystrophy and other diseases.

Diagnostic criteria

The diagnostic criteria of patients with thymoma-associated MG [20]: (1) typical symptoms of MG: muscle fatigue test was positive; serum anti-acetylcholine receptor antibody titer was increased; and anticholinesterase agents test was positive. (2) The chest radiograph and chest CT or MRI prompted an anterior mediastinal mass. MGFA clinical classification: type I: any ocular muscle weakness, may be accompanied by weakness of eye closure, all other muscle strength is normal; type IIa: mainly affecting limb or/and axial muscles, may also have lesser or equal involvement of oropharyngeal muscles; type IIb: mainly affecting oropharyngeal or/and respiratory muscles, may also have lesser or equal involvement of limb or/and axial muscles; type IIIa: mainly affecting limb or/and axial muscles, may also have lesser or equal involvement of oropharyngeal muscles; type IIIb: mainly affecting oropharyngeal or/and respiratory muscles, may also have lesser or equal involvement of limb or/and axial muscles; type IVa: mainly affecting limb and/or axial muscles, may also have lesser or equal involvement of oropharyngeal muscles and type IV b: mainly affecting oropharyngeal or/and respiratory muscles, may also have lesser or equal involvement of limb or/and axial muscles; type V: trachea cannula with or without mechanical-ventilation (except for postoperative routine use). Patient used a feeding tube without intubation made him in type IVb. Masaoka staging was used for thymoma pathology staging [21]: Stage I: macroscopically completely encapsulated and microscopically no capsular invasion; stage II: macroscopic invasion into surrounding fatty tissue or mediastinal pleura, or microscopic invasion into capsule; stage III: macroscopic invasion into neighboring organ, i.e., great vessels, pericardium, or lung; stage IV: pleural or pericardial dissemination or lymph. VAST group before operation: 15 cases in stage I, 13 cases in stage II, 7 cases in stage III and 4 cases in stage IV; median sternotomy group before operation: 5 cases in stage I, 9 cases in stage II, 12 cases in stage III and 8 cases in stage IV.

Imaging examination for thymus gland

Conventional X-ray examination: all patients underwent thymus anteroposterior and lateral X-ray film examination by High kilovoltage (KV) radiography technique (120~125 kVP) and bucky stand (Suzhou AnmaiMedical Instrument Co., Ltd.).

Chest CT scan: The Phillips MX8000 double row helical CT was used for scanning; patients were asked to lay supine with continuous chest scan and stop breathing after inhalation, without contrast enhanced scanning, with the voltage of 120 kv, current of 100 mAs, depth of stratum 10 mm, interval of stratum 10 mm, field of vision (FOV) 350 mm.

Mediastinum MRI inspection: Sigma1.5T superconducting MR machine (American GE company) was used, with routine use of conventional spin echo (SE) and fast spin echo (FSE) sequences.

Surgical treatment

VAST group: patients had general anesthesia with double-lumen endotracheal intubation, and kept 30° left lateral position. Only 2 patients, whose mediastinal mass located at the left side, underwent left thoracic surgery, the rest were all had right thoracic surgery. The observation hole of thoracoscope was located at the fifth intercostal space of midaxillary line, the main operating hole were 3 cm incision at the third or fourth intercostal space of anterior line axillary and the auxiliary operation hole were 1.5 cm incision at the sixth intercostal space of anterior line axillary. The observation hole was placed into the thoracic cavity for probing. The electric coagulation hook started to ionize from the lower pole of the thymus gland in front of the nervusphrenicus, and ionized the thymus and the anterior mediastinal fat tissues to the upper, lower and the opposite side along the pericardial surface. When ionized to the upper pole of the thymus gland, strengthened the protection on the position of internal thoracic vein importing to the superior vena cava. Pulled the thymus, and made sure to expose the left and right brachiocephalic veins on the back of upper pole of the thymus gland. The venae thymicae of the brachiocephalic veins were imported and then were cut by ultrasonic knife. For the short length of venae thymicae and the adhesions between

Comparison of VATS and median sternotomy

Table 1. Clinical data in thymoma-associated MG patients between VATS group and median sternotomy group

Clinical data	VATS group (n = 39)	Median sternotomy group (n = 34)	t/χ ²	P
Age (years old)	36.5±7.9	38.3±7.8	0.977	0.332
Gender			1.389	0.239
Male	27	19		
Female	12	15		
Course of disease (month)	18 (4~28)	12 (4~24)	0.820	0.415
MGFA classification			3.339	0.765
I	8	5		
IIa	12	13		
IIb	5	7		
IIIa	7	3		
IIIb	4	4		
IVa	2	2		
IVb	1	0		
Masaoka staging			8.072	0.045
I	15	5		
II	13	9		
III	7	12		
IV	4	8		

VATS, video-assisted thoracic surgery; MGFA, Myasthenia Gravis Foundation of America.

the venae thymicae and brachiocephalic veins, particular careful attention should be paid to avoid damage to the brachiocephalic veins, which might resulting in an emergent thoracotomy. Finally, dragged downward to pull out the upper pole of the thymus gland with blunt separation method, and completely resected the thymus and the anterior mediastinal fat tissues.

Median sternotomy group: patients had general anesthesia with single-lumen endotracheal intubation and kept dorsal decubitus. The thymus gland was completely resected through the median incision of sternum. The thymus together with the part of the fat tissues of the mediastinum was removed, and the anterior mediastinal fat tissues between the two sides of the nervusphrenicus were cleared. Stopped bleeding for the patients, kept the closed thoracic drainage tube, fixed the sternum with steel wire of size 7, and finally sew up the incision.

Postoperative management

In general, trachea cannula can be removed after anesthesia. If there appeared low oxygen

saturation and weak breathing after operation, the use of ventilator can be extended for several hours or even several days. Acetylcholinesterase inhibitors and hormones were generally used for preoperative dosage. After the operation, 4-quinolones antibiotics should be cautiously used, aminoglycoside and antipyretic analgesics were forbidden to use in order to avoid induced crisis. Patients who abruptly had severe respiratory muscle weakness that cannot maintain the normal ventilation function, with the degree of blood oxygen saturation <90%, arterial blood gas PO₂<60 mmHg and PaCO₂>50 mmHg were diagnosed with crisis. At the onset of crisis, patients were immediately used trachea cannula through the nasal/mouth, or tracheotomy and

ventilator assisted breathing. MG crisis, cholinergic crisis or stubborn crisis can be judged from the following points: (1) the use of cholinesterase inhibitor; (2) pupil size; (3) bowel sound; (4) the respiratory and oral secretions; (5) heart rate and (6) Tensilon test. Further treatment was in accordance with the judgment results. For the circumstances that difficult to judge the type of crisis, patients were treated with dry therapy for 3~5 days, and were started to use cholinesterase inhibitor with a small dose until the condition improved.

Observation indexes

The operative time, postoperative thoracic drainage and intraoperative bleeding volume, occurrence rate of postoperative MG crisis, postoperative hospitalization time and other clinical indicators of patients in two groups were recorded; the preoperative and postoperative quality of life scores and the changes of scores in each time period were also recorded.

Quantitative myasthenia gravis (OMG) score

QMG was applied for objective evaluation of the severity of MG of affected muscle groups [22],

Comparison of VATS and median sternotomy

Table 2. Operation indicators during the perioperative period in VATS group and median sternotomy group ($\bar{x} \pm s$)

Groups	Operative time (min)	Intraoperative bleeding volume (ml)	Postoperative thoracic drainage time (d)	Postoperative hospitalization time (d)	ICU monitoring time (h)
VATS group (n = 39)	149.7±42.3	82.2±40.5	2.7±1.2	7.4±2.3	11.5±4.7
Median sternotomy group (n = 34)	137.4±36.7	156.5±38.8	3.5±1.6	8.7±2.6	25.7±9.7
t	1.317	7.973	2.435	2.267	8.12
P	0.192	<0.001	0.017	0.026	<0.001

VATS, video-assisted thoracic surgery; ICU, intensive care unit.

Table 3. The difference in efficacy between VATS and median sternotomy group [n (%)]

Groups	Complete remission	Partial remission	Stable disease	Progressive disease	Effective rate
VATS group (n = 39)	19 (48.7)	13 (33.3)	4 (10.3)	3 (7.7)	32 (82.0)
Median sternotomy group (n = 34)	14 (41.2)	12 (35.3)	3 (8.8)	5 (14.7)	26 (76.5)

VATS, video-assisted thoracic surgery.

Table 4. QMG score and MG-QOL15 score before and after operation in VATS group and median sternotomy group [$\bar{x} \pm s$ (n)]

Assessment item	QMG score		MG-QOL15 score	
	VATS group	Median sternotomy group	VATS group	Median sternotomy group
Before operation	13.1±7.1 (39)	12.3±7.2 (34)	15.6±5.1 (39)	14.3±5.6 (34)
After operation	11.7±6.9 (39)*	11.4±7.3 (34)*	20.4±5.9 (39)*	18.2±6.5 (34)*
6 months after operation	8.5±6.8 (39)*	8.7±7.6 (34)*	28.2±6.3 (39)*	25.0±6.5 (34)*
1year after operation	5.7±6.0 (39)*	6.4±7.1 (32)*	38.4±6.0 (39)*	33.7±7.5 (32)*
3 years after operation	3.5±4.6 (35)*	3.6±5.2 (29)*	45.1±4.9 (35)*	41.5±7.1 (29)*
5 years after operation	1.4±2.3 (29)*	1.8±3.2 (25)*	48.4±3.1 (29)*	46.8±5.1 (25)*

Note: *refers to $P < 0.05$ when compared with before operation. VATS, video-assisted thoracic surgery, QMG, Quantitative Myasthenia Gravis; MG-QOL15, 15-item myasthenia gravis quality of life scale.

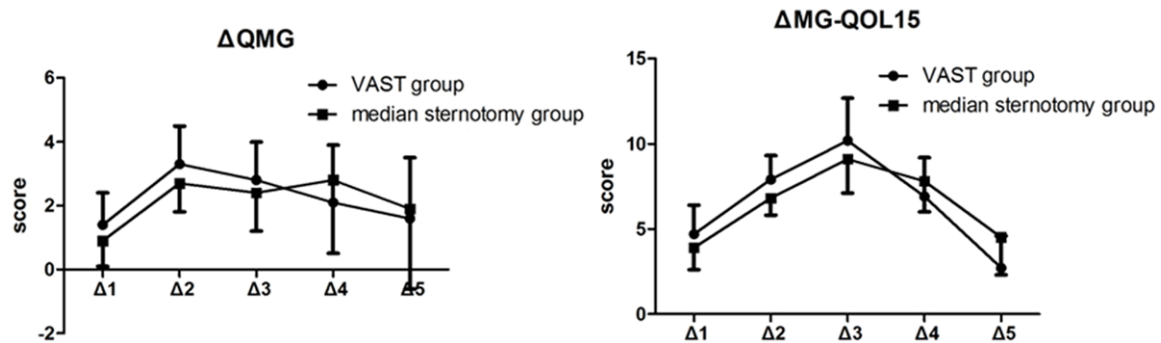


Figure 1. Δ QMG score and Δ MG-QOL15 score before and after operation in VATS and median sternotomy group ($\Delta 1$ refers to the absolute value of the difference after operation and before operation; $\Delta 2$ refers to the absolute value of the difference 6 months after operation and after operation; $\Delta 3$ refers to the absolute value of the difference 1 year after operation and 6 months after operation; $\Delta 4$ refers to the absolute value of the difference 3 years after operation and 1 year after operation; $\Delta 5$ refers to the absolute value of the difference 5 years after operation and 3 years after operation).

and QMG score formulated by MGFA was used for quantitative test of muscle strength of major affected muscles, such as extraocular muscles, facial muscles, bulbar muscles, limb-

bs, head and neck muscles, and respiratory muscle. Four points system was utilized: 0 points represents normal, 1~3 points represent the light, medium and heavy of MG, respective-

Comparison of VATS and median sternotomy

Table 5. Postoperative complications in VATS group and median sternotomy group

Groups	VATS group	Median sternotomy group	χ^2	P
MG crisis	0	6	7.499	0.006
Pulmonary infection	2	4	1.061	0.303
Upper limb disorders	0	2	2.359	0.125
Total	2	12	10.66	0.001

VATS, video-assisted thoracic surgery.

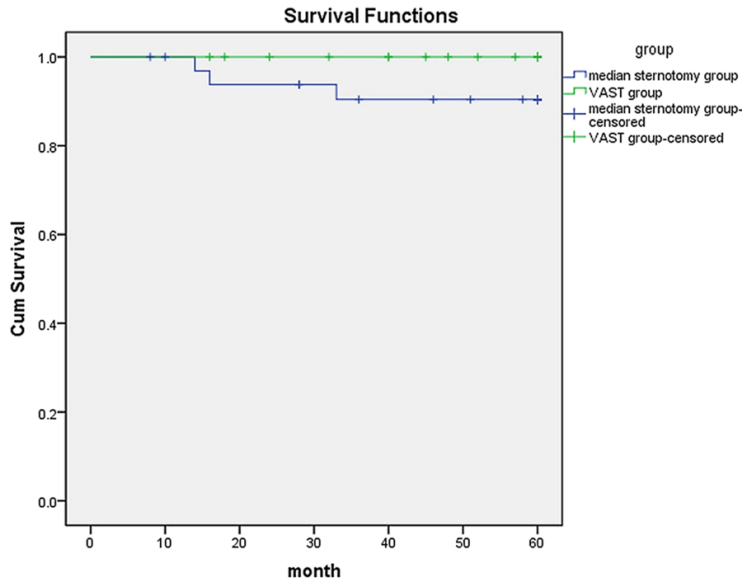


Figure 2. Five-year survival curves of the two groups (The 5-year survival rates of VATS group and median sternotomy group were 100% and 91.2%, respectively, and the survival rate of VATS group was slightly higher than that in median sternotomy group).

ly. The cumulative score of the muscles were regarded as QMG score of a patient, which ranged from 0~39 points.

15-item myasthenia gravis quality of life scale (MG-QOL15)

The items in the MG-QOL15 were selected from the MG-QOL [23]. Burns et al. carried out the steps of factor analysis and the aggregation validity analysis on MG-QOL, and finally selected 15 items, namely, MG-QOL15. It involved three areas: physical, social, and psychological, the 15 items was originated from the 4 areas of activity (9), symptoms (3), general content (1), and psychological (2) in the MG-QOL scale. The answer options were divided into 5 levels, which ranged from 0 points (little)~4 points (complete).

Evaluation criteria of follow-up and clinical effect

Every 6 months, patients were followed-up for one time or had regular return visits, and the data collection was ended in January 31, 2015. The evaluation standards after the treatment of MGFA [22]: complete remission (CR): immunosuppressive drugs and cholinesterase inhibitors were gradually disused after operation, the symptoms of MG were completely disappeared with no aggravation and recurrence during the follow-up period; partial remission (PR): the dosage decreased, the symptoms of MG significantly reduced compared with that before operation and the condition was stable; stable disease (SD): the symptoms were similar to that before operation, the doses of anticholinesterase drugs were less than that before operation or without any changes; progressive disease (PD): aggravated symptoms compared to that before operation regardless of their medication, or similar symptoms but with higher doses of anticholinesterase drugs compared to that before operation.

Effective rate (%) was calculated as follows: CR (%) + PR (%). The condition of the last follow-up before and after the operation was compared to clarify the effect of operation and further determine the CR and effective rate on the basis of the above information.

Statistical analysis

SPSS21.0 statistical software package (SPSS Inc, Chicago, IL) were used for statistical analysis. Measurement data was expressed by mean \pm standard deviation (SD) ($\bar{x} \pm s$) or the median (range interquartile), the two groups were compared using the *t* test, and the three groups were compared using analysis of variance (ANOVA). Count data was expressed by *n* using χ^2 test. Fisher's exact test was utilized if $n < 40$ or $T < 5$. The Kaplan-Meier method was applied

Comparison of VATS and median sternotomy

for the comparisons of postoperative survival rate between two groups. $P < 0.05$ showed significant difference.

Results

Comparison of clinical characteristics

As shown in **Table 1**, there was no significant difference of age, gender, course of disease and MGFA classification (all $P > 0.05$), while Masaoka staging between the two groups showed significant difference ($P < 0.05$).

Operation indicators during the perioperative period

The intraoperative bleeding volume, postoperative thoracic drainage time, postoperative hospitalization time and intensive care unit (ICU) monitoring time in the VATS group were shorter than that in the median sternotomy group (all $P < 0.05$). However, the operative time showed no significant difference between patients in two groups ($P > 0.05$) (**Table 2**).

The difference in efficacy between VATS and median sternotomy

According to the evaluation standards after the treatment of MGFA, the effective rate of VATS group was 82.0% and the median sternotomy group was 76.5% at the sixth month of follow-up after operation for patients between two groups, and there showed no statistical significance between two groups ($P > 0.05$) (**Table 3**).

QMG score and MG-QOL15 score before and after operation

All patients were followed up, 73 cases were followed up for more than 6 months, 71 cases for more than 1 years, 64 cases for more than 3 years and 54 cases for more than 5 years; the 5-year follow-up rate was 74.0%. The QMG score and MG-QOL15 score of the followed-up patients were shown in **Table 4**. The QMG score after operation was significantly lower than that before operation, and it decreased with the extension of time ($P < 0.05$); MG-QOL15 score after operation was markedly higher than that before operation, and it increased with the extension of time ($P < 0.05$). As shown in **Figure 1**, with the growth of postoperative time, Δ QMG score and Δ MG-QOL15 score were first increased and then decreased in two groups.

One year after operation in the VATS group, Δ QMG score and Δ MG-QOL15 score were significantly higher than that in the median sternotomy group (both $P < 0.05$). One year later, the QMG score and MG-QOL15 score in the median sternotomy group were significantly improved.

Postoperative complications

When patients' condition suddenly worsened or improperly treated, the appearance of severe breathing difficulties caused by respiratory muscle weakness or paralysis called MG crisis [24]. In this study, there was no MG crisis in the VATS group while the rate in the median sternotomy group was 17.6% (6/34), and the difference between the two groups was extremely significant ($P = 0.006 < 0.01$). The postoperative complication rate was 5.13% in the VATS group, which was obviously lower than that in the median sternotomy group with the rate of 35.29% ($P = 0.001 < 0.01$) (**Table 5**).

Survival analysis

Seventy-three patients with thymoma-associated MG were followed up for 6~60 months after operation, and the 5-year follow-up rate was 74.0%. In the VATS group, there was no death, 10 cases lost to follow-up within 5 years; in the median sternotomy group, totally 3 cases died (2 cases died of MG attack, 1 case died of recurrence of thymoma) and 6 cases lost to follow-up within 5 years. Survival rates were calculated by Kaplan-Meier method, and 5-year survival rates in the VATS group and median sternotomy group were 100% and 91.2%, respectively, suggesting that the survival rate of VATS group was slightly higher than that in the median sternotomy group, and there showed no significant difference between two groups ($P = 0.054$). The survival curves of the two groups are shown in **Figure 2**.

Discussion

Increasingly, surgical management of thymoma-associated MG is recognized as an effective treatment option, while there is no consensus for which surgical method is first line. Although median sternotomy has been the traditional approach for the treatment of thymoma-associated MG, VATS thymectomy has been in popularity in recent years. Our study aims to compare the efficacy and safety of

Comparison of VATS and median sternotomy

median sternotomy and VATS for thymoma-associated MG, and found that VATS showed superiority in most of the aspects when compared with median sternotomy.

Our study found that patients with thymoma-associated MG after treated by VATS and median sternotomy both obtained well curative effects, while the intraoperative bleeding volume, postoperative thoracic drainage time, postoperative hospitalization time and ICU monitoring time in the VATS group were shorter than that in the median sternotomy group, suggesting VATS thymectomy has great advantages over median sternotomy. Median sternotomy is the most common surgical method for thymoma-associated MG, with the advantages of full exposure, convenient operation and complete movement of thymus gland and the anterior mediastinal fat tissues [15]. However, it is not applicable for these patients for the disadvantages of big wound and scar, poor appearance, slow recovery, deformity of the sternum, or other complications of respiratory and circulatory system dysfunction, pulmonary infection, or arrhythmia [25]. Recently, MG patients with or without thymoma who underwent VATS demonstrating superior results in terms of shorter postoperative hospital time, less blood loss, smaller number of chest tubes, less quantity of drainage, and shorter duration of drainage and a shorter time to return to full activity [26]. Yuan et al. in his study proposed that the heavy wound would lead to more seriously postoperative pain in the median sternotomy, the requirements for more postoperative care delayed patients' return to normal life and work in comparison with VATS group; additionally, less incisions, more accurate dissection and clearer visual field may lead to less blood loss during VATS thymectomy, which could further contribute to less time to recovery [27]. Although VATS had benefits in these patients, there still remains uncertainty for its effectiveness due to the longer operation times and higher operation fee of VATS, as well as other complications including long-term air leakage, vascular injury, diaphragm injury and chylothorax, nervus-phrenicus damage happened during VATS process [27].

Our study also found that Δ QMG score and Δ MG-QOL15 score in the VATS group were significantly higher than that in the median sternotomy group, the occurrence rate of complications especially postoperative MG crisis and

the 5-year mortality rate in the median sternotomy were higher when compared to that in the VATS group, the above results indicated that the improvement rates of symptoms have gradually increased after VATS. The improvement of patients' symptom in VATS group was associated with small interference to the release of inflammatory mediators, less bleeding, less amount of analgesic drugs, rapid recovery and shorter hospital stay, etc. [28]. MG crisis is the most common complications and the main causes of death after GM, and in our study, there were 2 cases of MG crisis in the median sternotomy group and no case was found in the VATS group. The occurrence of MG crisis may be related to the following factors: (1) longer length of incision and big areas of trauma reduce the body's stress response; (2) patients had a history of MG crisis before operation; (3) patients with respiratory dysfunction, especially ventilation dysfunction; (4) surgical trauma and anesthesia influence; (5) improper control of the dose of anticholinesterase agents, etc. [29]. In general, intraoperative blood loss is an important index to evaluate the surgical trauma, and in this study, the blood loss in the VATS group was significantly lower than that in the median sternotomy group, suggesting that the reduction of surgical trauma may be one of the reasons for the low postoperative MG risk. In addition, there is no need to split sternum in VATS process, which maintains the integrity of the thorax and sternum, and has small disturbance on respiratory function of patients, this may be an important reason for the low rate of postoperative MG crisis in VATS group [30].

In conclusion, the results of the current study have suggested that VATS thymectomy is a safe, feasible surgical method that is associated with reduced hospital stay as well as potentially fewer major complications than median sternotomy. Hence, VATS could be considered in preference to the median sternotomy despite its greater operative times. However, for the small number of cases in our study, more data are needed for further study.

Acknowledgements

We would like to acknowledge the reviewers for their helpful comments on this paper.

Disclosure of conflict of interest

None.

Comparison of VATS and median sternotomy

Address correspondence to: Dr. Hai-Zhen Ni, Department of Vascular Surgery, The First Affiliated Hospital of Wenzhou Medical University, No. 2, Fuxue Road, Wenzhou 325000, P. R. China. Tel: +86-15812469196; E-mail: nihaizhen1015@163.com

References

- [1] Holbro A, Jauch A, Lardinois D, Tzankov A, Dirnhof S and Hess C. High prevalence of infections and autoimmunity in patients with thymoma. *Hum Immunol* 2012; 73: 287-290.
- [2] Marchevsky AM, Gupta R, McKenna RJ, Wick M, Moran C, Zakowski MF and Suster S. Evidence-based pathology and the pathologic evaluation of thymomas: The world health organization classification can be simplified into only 3 categories other than thymic carcinoma. *Cancer* 2008; 112: 2780-2788.
- [3] den Bakker MA, Roden AC, Marx A and Marino M. Histologic classification of thymoma: A practical guide for routine cases. *J Thorac Oncol* 2014; 9: S125-130.
- [4] A. MC. Thymoma [m]//encyclopedia of cancer. Heidelberg, Berlin: Springer; 2012. pp. 3685-3686.
- [5] Meriggioli MN and Sanders DB. Autoimmune myasthenia gravis: Emerging clinical and biological heterogeneity. *Lancet Neurol* 2009; 8: 475-490.
- [6] Marx A, Pfister F, Schalke B, Saruhan-Direrkeneli G, Melms A and Strobel P. The different roles of the thymus in the pathogenesis of the various myasthenia gravis subtypes. *Autoimmun Rev* 2013; 12: 875-884.
- [7] Gadalla SM, Rajan A, Pfeiffer R, Kristinsson SY, Bjorkholm M, Landgren O and Giaccone G. A population-based assessment of mortality and morbidity patterns among patients with thymoma. *Int J Cancer* 2011; 128: 2688-2694.
- [8] Marx A, Willcox N, Leite MI, Chuang WY, Schalke B, Nix W and Strobel P. Thymoma and paraneoplastic myasthenia gravis. *Autoimmunity* 2010; 43: 413-427.
- [9] Davenport E and Malthaner RA. The role of surgery in the management of thymoma: A systematic review. *Ann Thorac Surg* 2008; 86: 673-684.
- [10] Pennathur A, Qureshi I, Schuchert MJ, Dhupar R, Ferson PF, Gooding WE, Christie NA, Gilbert S, Shende M, Awais O, Greenberger JS, Landreneau RJ and Luketich JD. Comparison of surgical techniques for early-stage thymoma: Feasibility of minimally invasive thymectomy and comparison with open resection. *J Thorac Cardiovasc Surg* 2011; 141: 694-701.
- [11] Okumura M, Ohta M, Tateyama H, Nakagawa K, Matsumura A, Maeda H, Tada H, Eimoto T, Matsuda H and Masaoka A. The world health organization histologic classification system reflects the oncologic behavior of thymoma: A clinical study of 273 patients. *Cancer* 2002; 94: 624-632.
- [12] Yamamoto K, Ohsumi A, Kojima F, Imanishi N, Matsuoka K, Ueda M and Miyamoto Y. Long-term survival after video-assisted thoracic surgery lobectomy for primary lung cancer. *Ann Thorac Surg* 2010; 89: 353-359.
- [13] Ng CS, Wan IY and Yim AP. Video-assisted thoracic surgery thymectomy: The better approach. *Ann Thorac Surg* 2010; 89: S2135-2141.
- [14] Zahid I, Sharif S, Routledge T and Scarci M. Video-assisted thoracoscopic surgery or transsternal thymectomy in the treatment of myasthenia gravis? *Interact Cardiovasc Thorac Surg* 2011; 12: 40-46.
- [15] Meyer DM, Herbert MA, Sobhani NC, Tavakolian P, Duncan A, Bruns M, Korngut K, Williams J, Prince SL, Huber L, Wolfe GI and Mack MJ. Comparative clinical outcomes of thymectomy for myasthenia gravis performed by extended transsternal and minimally invasive approaches. *Ann Thorac Surg* 2009; 87: 385-390; discussion 390-381.
- [16] Odaka M, Akiba T, Yabe M, Hiramatsu M, Matsudaira H, Hirano J and Morikawa T. Unilateral thoracoscopic subtotal thymectomy for the treatment of stage i and ii thymoma. *Eur J Cardiothorac Surg* 2010; 37: 824-826.
- [17] Takeo S, Tsukamoto S, Kawano D and Katsura M. Outcome of an original video-assisted thoracoscopic extended thymectomy for thymoma. *Ann Thorac Surg* 2011; 92: 2000-2005.
- [18] Odaka M, Akiba T, Mori S, Asano H, Marushima H, Yamashita M, Kamiya N and Morikawa T. Oncological outcomes of thoracoscopic thymectomy for the treatment of stages i-iii thymomas. *Interact Cardiovasc Thorac Surg* 2013; 17: 285-290.
- [19] World Medical Association Inc. Declaration of helsinki. Ethical principles for medical research involving human subjects. *J Indian Med Assoc* 2009; 107: 403-405.
- [20] Chen YP, Wang W, Wang ZK, Dou YK and Wei DN. [the clinical characteristics of patients with thymoma-associated myasthenia gravis]. *Zhonghua Nei Ke Za Zhi* 2012; 51: 623-625.
- [21] Masaoka A, Monden Y, Nakahara K and Tanioaka T. Follow-up study of thymomas with special reference to their clinical stages. *Cancer* 1981; 48: 2485-2492.
- [22] Jaretzki A 3rd, Barohn RJ, Ernstoff RM, Kaminski HJ, Keeseey JC, Penn AS and Sanders DB. Myasthenia gravis: Recommendations for clinical research standards. Task force of the medical scientific advisory board of the myasthenia gravis foundation of america. *Ann Thorac Surg* 2000; 70: 327-334.

Comparison of VATS and median sternotomy

- [23] Burns TM, Conaway MR, Cutter GR, Sanders DB; Muscle Study Group. Less is more, or almost as much: A 15-item quality-of-life instrument for myasthenia gravis. *Muscle Nerve* 2008; 38: 957-963.
- [24] Bramis J, Diamantis T, Tsigris C, Pikoulis E, Papaconstantinou I, Nikolaou A, Leonardou P and Bastounis E. Video-assisted transcervical thymectomy. *Surg Endosc* 2004; 18: 1535-1538.
- [25] Ye B, Tantai JC, Ge XX, Li W, Feng J, Cheng M, Shi JX and Zhao H. Surgical techniques for early-stage thymoma: Video-assisted thoracoscopic thymectomy versus transsternal thymectomy. *J Thorac Cardiovasc Surg* 2014; 147: 1599-1603.
- [26] Yu L, Zhang XJ, Ma S, Li F and Zhang YF. Thoracoscopic thymectomy for myasthenia gravis with and without thymoma: A single-center experience. *Ann Thorac Surg* 2012; 93: 240-244.
- [27] Yuan ZY, Cheng GY, Sun KL, Mao YS, Li J, Wang YG, Wang DL, Gao SG, Xue Q, Huang JF and Mu JW. Comparative study of video-assisted thoracic surgery versus open thymectomy for thymoma in one single center. *J Thorac Dis* 2014; 6: 726-733.
- [28] Manlulu A, Lee TW, Wan I, Law CY, Chang C, Garzon JC and Yim A. Video-assisted thoracic surgery thymectomy for nonthymomatous myasthenia gravis. *Chest* 2005; 128: 3454-3460.
- [29] Watanabe A, Watanabe T, Obama T, Mawatari T, Ohsawa H, Ichimiya Y, Takahashi N, Kusajima K and Abe T. Prognostic factors for myasthenic crisis after transsternal thymectomy in patients with myasthenia gravis. *J Thorac Cardiovasc Surg* 2004; 127: 868-876.
- [30] Lin TS, Tzao C, Lee SC, Wu CY, Shy CJ, Lee CY and Chou MC. Comparison between video-assisted thoracoscopic thymectomy and transternal thymectomy for myasthenia gravis (analysis of 82 cases). *Int Surg* 2005; 90: 36-41.