

Case Report

Reversed vascular nasolabial flap pedicled with superior labial artery: safe and easy method for paranasal and infraorbital reconstruction

Chi Feng^{1*}, Tian Zheng^{1*}, Ping Ji¹, Ping Liu¹, Yong Li¹, Hong-Wei Zhao^{1,2}

¹Department of Oral and Maxillofacial Surgery, The Affiliated Hospital of Stomatology, Chongqing Medical University Chongqing, Chongqing, PR China; ²Chongqing Key Laboratory for Oral Diseases and Biomedical Science, Chongqing, PR China. *Equal contributors.

Received March 27, 2016; Accepted August 19, 2016; Epub November 15, 2016; Published November 30, 2016

Abstract: Objective: To evaluate the clinical effect of reversed nasolabial flap pedicled with superior labial artery used for the reconstruction of paranasal and infraorbital defects. Method: 13 cases of large paranasal and infraorbital defects were reconstructed by the reversed nasolabial flap pedicled with the superior labial artery. In all the patients these defects were resulted by the excision of carcinomas. The disease course ranged from 2 months to 28 years. The size of paranasal and infraorbital defects varied between 20 mm×12 mm and 40 mm×56 mm. All defects were restored by the reversed nasolabial flap pedicled with the superior labial artery. The size of flaps were similar to that of the defects. The donor areas were sutured directly. Result: All flaps completely survived. The incision at the donor and recipient sites healed in the first stage. Flap revision of 4 patients was performed after 6-12 months because of mild swelling at the pedicles of skin flaps. The mean duration of follow-up was 38 (24-60) months. No signs of recurrence and metastasis happened. All patients were satisfied with the function of cataclipsis, appearance, flap texture, and color. No obvious scars were found at donor sites. Full patient satisfaction was achieved both aesthetically and functionally. Conclusion: The reversed nasolabial flap pedicled with the superior labial artery, an optimal repairing method, can be chosen to repair paranasal and infraorbital defect after excision of carcinomas.

Keywords: Nasolabial flap, superior labial artery, paranasal and infraorbital defect, reconstruction

Introduction

Paranasal and infraorbital defects resulting from the neoplastic and traumatic lesions tremendously destroy the facial aesthetics and impair the quality of life [1]. These reconstructions of paranasal and infraorbital defects pose a significant challenge for head and neck surgeons. The traditional forehead flap, when used, not only causes the bloated nose and insufficient tissue for the construction of infraorbital area but also often leaves obvious scars on the donor site. The clinical application of free flaps (eg forearm flap, postauricular flap, etc.) is often limited due to the complicated surgical procedures, the different texture of flap between the donor and receipt site, the scars of donor site and the poor general condition of elderly patients who cannot tolerate the longer

general anesthesia [2, 3]. For the reconstruction of paranasal and infraorbital defects the shortcomings included the insufficient tissue and the angle of rotation [4], inspite of these difficulties, we had reconstructed the penetrated nasal defects with nasolabial skin flap pedicled on the infraorbital vessels [5]. The failure of contralateral nasolabial flap is often due to the insufficient turning radius and the poor unstability of arteriovenous system [6, 7]. The best donor site for repairing the nose and infraorbital defects is the nasolabial flap which is similar in texture to the infraorbital region and rich in blood circulation. Moreover, the wound of the donor site can be directly sutured [8]. But the conventional nasolabial flap, which is often used to repair the alar and apex defect and the moderate-sized oronasal defect, is very difficult to reconstruct the large defect caused by the

Reversed vascular nasolabial flap for paranasal and infraorbital reconstruction

Table 1. The clinical data of 13 oncological cases

S.no	Age/Sex	Diagnosis	Tumor location	Tumor dimension (mm ²)	Treatment done	Defect dimension (mm ²)
1	56/F	BCC	Rt Pn	12×14	We+ RVNLF	20×26
2	63/M	BCC	Lt lo	20×22	We+ RVNLF	28×32
3	72/M	SCC	Lt Pi	30×46	We+ RVNLF	40×56
4	45/M	BCC	Lt Pn	10×16	We+ RVNLF	20×27
5	42/M	BCC	Lt lo	14×18	We+ RVNLF	24×28
6	65/F	BCC	Rt lo	16×22	We+ RVNLF	26×34
7	51/M	BCC	Rt lo	14×27	We+ RVNLF	24×37
8	59/M	SCC	Lt Pn	7×14	We+ RVNLF	16×24
9	65/F	BCC	Lt lo	14×18	We+ RVNLF	25×28
10	78/M	BCC	Rt Pn	8×14	We+ RVNLF	18×24
11	54/F	BCC	Rt lo	12×26	We+ RVNLF	22×35
12	59/M	BCC	Lt Pi	26×36	We+ RVNLF	36×44
13	43/M	BCC	Rt lo	12×20	We+ RVNLF	22×30

SCC-Squamous cell carcinoma, BCC-Basal cell carcinoma, Rt-right, Lt-left, Pn-paranasal, lo-infraorbital, Pi-paranasal and infra-orbital, We-wide excision, RVNLF-reversed vascular nasolabial flap.

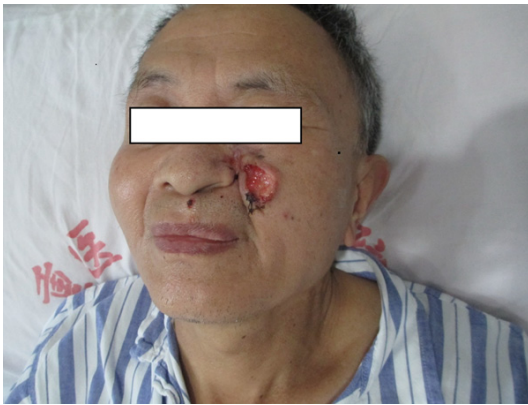

Figure 1. The diagnosis of squamous cell carcinoma was in nasolabial and infraorbital site.

tumor resection [9-14]. To address this challenge, we had recently modified the reversed nasolabial flap pedicled on the superior labial artery to reconstruct the nose and infraorbital defects in 13 cases from September 2006 to May 2015. The specific procedure was described along with the following information.

Material and methods

Patients' data

In the Affiliated Hospital of Stomatology, Chongqing Medical University, from September 2006 to May 2015, 13 consecutive patients with paranasal and infraorbital defects were identified according to the inclusion criteria. Among these patients, a group of 9 men and 4

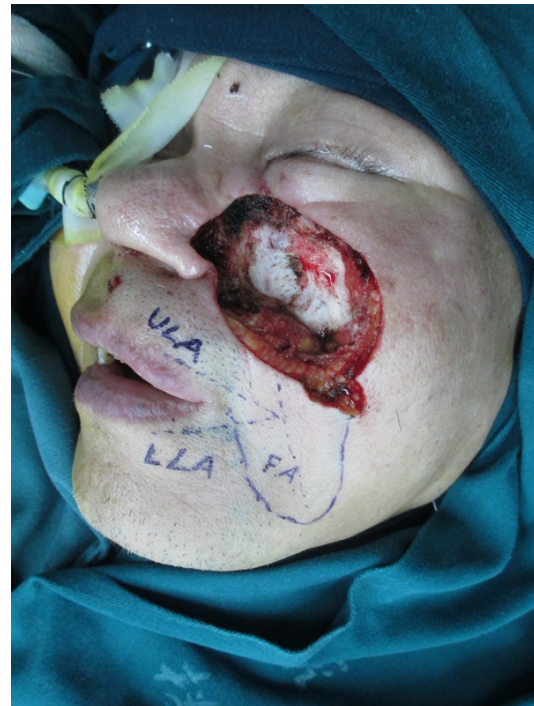

Figure 2. Reversed nasolabial flap pedicled with superior labial artery was designed according to the size of defect. ULA and LLA represent the upper labial artery and lower labial artery respectively.

women with a median age of 57.8 years (range, 42-78 years) were sorted. All the patients were referred for surgical reconstruction after Mohs ablative surgery for basal cell (n=11) or squamous cell (n=2) carcinoma of the skin on the paranasal and infraorbital region. These

Reversed vascular nasolabial flap for paranasal and infraorbital reconstruction

Table 2. The outcomes of flaps and follow-up data for all 13 cases

S.no	Age/Sex	SF	Patient's satisfaction	Second revision	Follow-up (month)	RM
1	56/F	Complete	Better	No	24	No
2	63/M	Complete	Best	No	28	No
3	72/M	Complete	Better	No	60	No
4	45/M	Complete	Good	Need	32	No
5	42/M	Complete	Better	No	4	No
6	65/F	Complete	Good	Need	13	No
7	51/M	Complete	Better	No	28	No
8	59/M	Complete	Good	Need	51	No
9	65/F	Complete	Best	No	32	No
10	78/M	Complete	Good	Need	36	No
11	54/F	Complete	Better	No	15	No
12	59/M	Complete	Best	No	16	No
13	43/M	Complete	Better	No	30	No

SF-survival of flap, RM-recurrence and metastasis.

defects involved the alar and side walls of nose and the infraorbital tissue with a maximum area of 40×56 mm². The mean duration of follow-up was 38 (24-60) months (**Table 1**).

The recipient site of paranasal and infraorbital region

According to the strict tumor-free principle of tumor resection all patients with malignant tumors were operated and the tumor was completely excised at the distance of 0.8-1.0 cm from the tumor margin. Meanwhile, the report of frozen biopsy confirmed the primary tumor had been completely removed and no residual tissue of tumor existed in the tissue, surrounding the primary tumor.

Design and preparation of reversed nasolabial flap

After complete resection, a reversed nasolabial flap pedicled with the superior labial vessels was designed and centered on the nasolabial area proximal to the paranasal and infraorbital defect (**Figure 1**). The shape of the flap was generally consistent with aesthetic subunit of the defect. The limit of flap over defect was not exceeding 5 mm.

The reversed nasolabial flap was then dissected and elevated in the subcutaneous plane above the facial musculature. In some patients,

the flap included some muscles according to the defect volume. The pedicle with a width of 6~8 mm muscle tissue, which is beneficial to ensure the venous return, was raised in the plane between the dermis and periosteum. The aspect ratio of flap in which the size ranges from 2.0 cm×1.2 cm to 4.8 cm×4.0 cm was 4 to 5:1. The drainage was located in the infraorbital space, and the donor site was closed directly.

Postoperative processing

Postoperatively, anticoagulation therapy was administered routinely by dextran for 3 days continuously and the blood circulation of flap was monitored by observing the flap color and the reaction of acupuncture.

This retrospective investigation was done through medical questionnaire and photographic examination by experienced plastic surgeons.

Results

A total of 13 flaps, which were totally performed in 13 patients, completely survived. The most common site for the defect was the paranasal and infraorbital area (**Figure 2**). Four patients underwent secondary revision to release the fat and clumsy of flap by excising the excessive muscle and fatty tissue, in six to twelve months after the first operation. All the patients were followed up. The average period of follow-up was 28.4 months (range, 4-60 months). The texture and color of reversed nasolabial flap was similar to the tissue of recipient area and the scar of donor site was not obvious and hidden in the nasolabial fold area. During the period of follow-up there were no signs of recurrence and metastasis (**Table 2**).

Typical case

A 72-year-old man, diagnosed with the squamous cell carcinoma on the left paranasal and infraorbital area, came to our attention. In this patient, the defect was left with an area of 40×56 mm². The reversed nasolabial flap pedicled with superior labial vessels, with a size of

Reversed vascular nasolabial flap for paranasal and infraorbital reconstruction

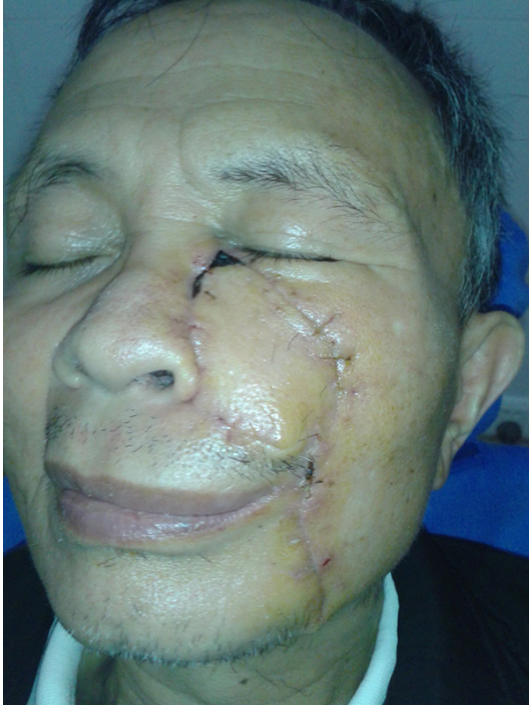

Figure 3. The color and texture of flap was similar to that of adjacent tissue after 1 week when the suture was removed. The function of catacleisis was completely done.

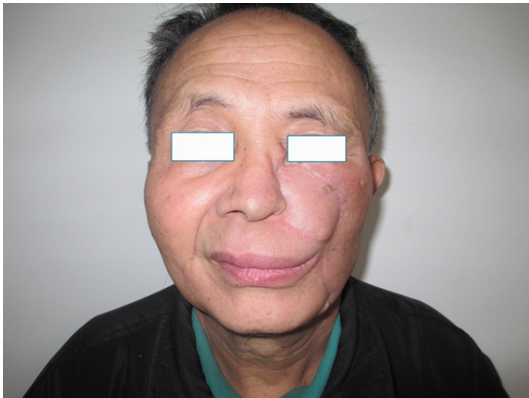

Figure 4. The front view 3 months after the operation.

40×56 mm² and the pedicle length of 2.6 cm, was designed to restore the defect. Frontal view 1 week after the operation indicated that the scar was inconspicuous, no significant change existed in appearance, the eyelids completely closed on their own, and the function of catacleisis was completely done (Figure 3). The patient had a good postoperative recovery without events worthy of notes 3 months post-operatively (Figures 4-6).

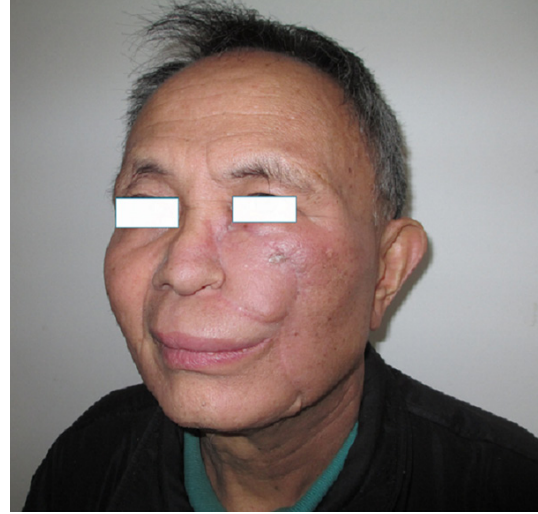

Figure 5. The flap was raised and the image was taken 3 months after the operation.

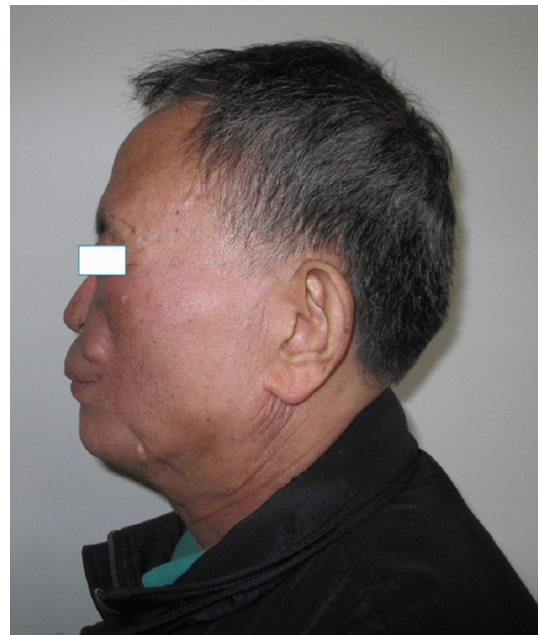


Figure 6. The raised flap was seen through the lateral image taken 3 months after the operation.

Discussion

The construction of paranasal and infraorbital defect is regarded as a great challenge of modern plastic surgery. For this reason various possibilities, such as a composite graft, transposition flaps, and local flaps, were described in the literature [15-17].

Although full-thickness skin grafts or advancement flaps proved useful in reconstruction of

Reversed vascular nasolabial flap for paranasal and infraorbital reconstruction

paranasal and infraorbital defects, their cosmetic outcome was unsatisfactory in most patients. The color, texture of flap, and contour irregularity cause a big problem for grafts as well as donor site morbidity. According to the report of literatures the nasolabial flap, which is supplied by angular artery, lateral nasal artery, facial artery, and infraorbital artery [12, 18], is a simple, effective, and safe flap with a low complication rate. Although other authors had reported the complications (infection, minor or major flap necrosis, wound dehiscence) occurring in a few patients, the nasolabial flap has many advantages such as good cosmetic appearance and covert incision of the donor site and has been used for reconstruction of lower nose and medial cheek defects [15, 19, 20], especially in covering small defects in maxillofacial region [21-24]. For this reason a reversed nasolabial flap, which was pedicled with the superior labial artery, was designed and raised from the nasolabial area. Superior labial artery, a constant branch of the facial artery, is arising above or at the angle of mouth and anastomoses with its counterpart in the middle of the upper lip [25-27]. In nasolabial area, the vein was rarely accompanied closely by the artery of same name. The decision as to whether the axial flap could be designed should be based primarily on the accompanied vein. This was similar to the report of RAN [26]. Without the concomitant vein the pedicle should be designed such that it is surrounded by a size of 6~8 mm muscle tissue so as to guarantee the venous return of flap although the size of surrounding muscle tissue was less than that of RAN [26]. This makes a reverse superior labial artery pedicle possible for elevation of a nasolabial flap. Usually, there is no destruction of muscle and nerve tissue, and because of the central vessels (the artery and the concomitant vein), the scope of rotation is essentially larger. Furthermore, the nasolabial tissue is quite rich so that the morbidity of donor site is negligible. Moreover, the degree of asymmetry is lessened by broad and deep undermining at the donor site [28].

If properly designed, the reversed nasolabial flap pedicled with superior labial vessels can follow the natural contour lines, where the color and texture of skin are ideal for the nasal and infraorbital reconstruction [8]. Moreover, the

scar of the donor site is not obvious and covert, and the length of vessel pedicle is long enough to agilely transfer to the recipient area. As described for the typical case, the nasolabial flap is valuable when there is a combined full thickness defect in the nasal and infraorbital region. The flap is elevated and transposed in a rotation-advancement manner. With adequate flap dimension, an excellent mobility provides sufficient tissue on the distal part of the defect that could ensure the function of catacleisis. Rohrich presented an innovative nasolabial flap for the reconstruction of a simultaneous medial cheek and alar-base nasal defect. In their study the disadvantages of this flap, such as the insufficient tissue and the smaller rotation, could limit the reconstruction of paranasal and infraorbital defects [29]. Especially, the superior labial vessels, which are barely involved in the safe margin of tumor resection, could be usually selected and elevated. Compared with the conventional nasolabial flap, this method is relatively tedious to perform as it takes more time and requires skillful dissection of perforator vessels in our study. However, the method provides an excellent mobility and a wide arc of rotation. Moreover, by having reliable vascularity, a sufficiently large flap could be elevated as long as it permits a donor site to be primarily closed. This pedicle should be considered when the defect is located on the course of lateral nasal artery or angular artery which might be involved in the safety of tumor resection [16, 30, 31]. Although Turan reported that reverse superior labial artery flap had been used in reconstruction of nose and medial cheek defect, we concluded that the arc of rotation and reliability of reversed nasolabial flap pedicled with superior labial artery used for the large paranasal and infraorbital defects is considered superior to angular artery and infraorbital artery-based nasolabial flaps [32]. Therefore, reversed nasolabial flap pedicled with superior labial artery was proved to be a good choice for one-stage reconstruction of the paranasal and infraorbital defects after removal of malignancies in the nasal and infraorbital region.

Acknowledgements

This research was supported by the medical research key project from Chongqing Health Bureau in China (No.2015ZDXM019).

Disclosure of conflict of interest

None.

Address correspondence to: Dr. Hongwei Zhao, Department of Oral and Maxillofacial Surgery, Chongqing Key Laboratory for Oral Diseases and Biomedical Science, College of Stomatology, Chongqing Medical University, 426 Northern Songshi Road, Chongqing 401147, PR China. Tel: +86-23-8886-0097; Fax: +86-23-88860097; E-mail: bradford-westchina@hotmail.com

References

- [1] Sohn WI, Choi JY, Seo BF and Jung SN. Reconstruction of nasal ala with nasolabial perforator flap after cancer removal. *Head Neck Oncol* 2012; 4: 83.
- [2] Qian Y, Zhang Y and Yang J. Reconstruction of nasal subunits with reversed vascularized preauricular and ear composite flap. *Zhongguo Xiu Fu Chong Jian Wai Ke Za Zhi* 2006; 20: 1186-1188.
- [3] Li S, Cao W, Cheng K, Yin C, Qian Y, Cao Y and Chang TS. Microvascular reconstruction of nasal ala using a reversed superficial temporal artery auricular flap. *J Plast Reconstr Aesthet Surg* 2006; 59: 1300-1304.
- [4] Ruiz-Moya A, Lagares-Borrego A; Infante-Cossio P. Propeller facial artery perforator flap as first reconstructive option for nasolabial and perinasal complex defects. *J Plast Reconstr Aesthet Surg* 2015; 68: 457-463.
- [5] Liang CY, Zhao HW, Wang LJ and Li LJ. Reconstruction of penetrated nasal defects with nasolabial skin flap pedicled on the infraorbital vessels. *J Craniofac Surg* 2010; 21: 68-70.
- [6] Gao SH, Feng SM, Chen C, Jiao C, Sun LQ and Zhang WL. A new recipient artery for reconstruction of soft-tissue defects in the lower limb with a free anterolateral thigh flap: the reversed descending branch of the lateral femoral circumflex artery. *Plast Reconstr Surg* 2012; 130: 1059-1065.
- [7] Ponte P, Goulao J and de Almeida JR. Contralateral nasolabial flap for a large nasal defect. *Dermatol Surg* 2009; 35: 675-678.
- [8] Schmidt BL and Dierks EJ. The nasolabial flap. *Oral Maxillofac Surg Clin North Am* 2003; 15: 487-495, v.
- [9] Kearney C, Sheridan A, Vinciullo C and Elliott T. A tunneled and turned-over nasolabial flap for reconstruction of full thickness nasal ala defects. *Dermatol Surg* 2010; 36: 1319-1324.
- [10] Kose R and Okur MI. Reconstruction of the defects in the middle of the nose with subcutaneous pedicled nasolabial island flap: report of two cases. *Kulak Burun Bogaz Ihtis Derg* 2009; 19: 272-276.
- [11] Lazaridis N, Zouloumis L, Venetis G and Karakasis D. The inferiorly and superiorly based nasolabial flap for the reconstruction of moderate-sized oronasal defects. *J Oral Maxillofac Surg* 1998; 56: 1255-1259; discussion 1260.
- [12] Plotner AN and Gloster HM Jr. Combined hinge and nasolabial transposition flap for repair of a full-thickness nasal alar defect. *Dermatol Surg* 2011; 37: 371-374.
- [13] Durbec M, Vertu-Ciolino D, Fuchsmann C and Disant F. Importance of a molding nasolabial flap in the reconstruction of mobile nose defects, a review of 25 cases. *Rev Laryngol Otol Rhinol (Bord)* 2010; 131: 103-106.
- [14] Hosaka Y, Tsukagoshi T, Sasaki E and Yokoyama S. The use of otherwise redundant skin to provide nasal lining in the reconstruction of full-thickness alar defects by nasolabial flap repair. *Br J Plast Surg* 1999; 52: 29-32.
- [15] Turan A, Kul Z, Turkaslan T, Ozyigit T and Ozsoy Z. Reconstruction of lower half defects of the nose with the lateral nasal artery pedicle nasolabial island flap. *Plast Reconstr Surg* 2007; 119: 1767-1772.
- [16] Karsidag S, Ozcan A, Sumer O and Ugurlu K. Single-stage ala nasi reconstruction: lateral nasal artery perforator flap. *J Craniofac Surg* 2010; 21: 1887-1889.
- [17] WLi S, Cao W, Cheng K, Yin C, Qian Y, Cao Y and Chang TS. Microvascular reconstruction of nasal ala using a reversed superficial temporal artery auricular flap. *J Plast Reconstr Aesthet Surg* 2006; 59: 1300-1304.
- [18] Hagan WE and Walker LB. The nasolabial musculocutaneous flap: clinical and anatomical correlations. *Laryngoscope* 1988; 98: 341-346.
- [19] Sohn WI, Choi JY, Seo BF and Jung SN. Reconstruction of nasal ala with nasolabial perforator flap after cancer removal. *Head Neck Oncology* 2012; 4: 83.
- [20] Weathers WM, Wolfswinkel EM, Nguyen H and Thornton JF. Expanded uses for the nasolabial flap. *Semin Plast Surg* 2013; 27: 104-109.
- [21] Abida R and Ayyallil MS. Heterogeneity of Nasolabial Flap-Role in Prevention of Morbidity Associated with Reconstruction of Orofacial Defects. *J Clin Diagn Res* 2015; 9: ZD10-11.
- [22] Kesiktas E, Eser C, Gencel E and Aslaner EE. A useful flap combination in wide and complex defect reconstruction of the medial canthal region: Glabellar rotation and nasolabial V-Y advancement flaps. *Plast Surg (Oakv)* 2015; 23: 113-115.
- [23] Durgun M, Ozakpinar HR, Sari E, Selcuk CT, Seven E and Tellioglu AT. The Versatile Facial Artery Perforator-Based Nasolabial Flap in Mid-

Reversed vascular nasolabial flap for paranasal and infraorbital reconstruction

- face Reconstruction. *J Craniofac Surg* 2015; 26: 1283-1286.
- [24] Bayer J, Duskova M, Horyna P, Haas M and Schwarzmannova K. The interpolation nasolabial flap: the advantageous solution for nasal tip reconstruction in elderly and polymorbid patients. *Acta Chir Plast* 2013; 55: 44-48.
- [25] Chen Y. Dermal pedicled nasolabial flap with subdermal vascular network for repairing nasolabial skin defects. *Zhongguo Xiu Fu Chong Jian Wai Ke Za Zhi* 2011; 25: 1459-1461.
- [26] Ran W, Fan X, Tan Z and Ni S. Clinical application of a retrograde nasolabial fold island flap based on the upper lip artery. *Zhonghua Zheng Xing Wai Ke Za Zhi* 2002; 18: 25-26.
- [27] Le-Quang C. Reversed vascular full-thickness nasolabial flap. *Ann Chir Plast Esthet* 1994; 38: 273-278.
- [28] Ducic Y and Burye M. Nasolabial flap reconstruction of oral cavity defects: A report of 18 cases. *J Oral Maxillofac Surg* 2000; 58: 1104-1108.
- [29] Rohrich RJ and Conrad MH. The superiorly based nasolabial flap for simultaneous alar and cheek reconstruction. *Plast Reconstr Surg* 2001; 108: 1727-1730; quiz 1731.
- [30] Aynehchi BB and Westreich RW. Lateral nasal artery pedicled island flap for repair of nasal alar defects. *Otolaryngol Head Neck Surg* 2012; 146: 382-384.
- [31] Shao Y, Zhang D, Zhao Z, Jin H and Rong L. Reconstruction of large nasal defects with lateral nasal artery pedicled nasolabial flap. *Zhongguo Xiu Fu Chong Jian Wai Ke Za Zhi* 2010; 24: 552-555.
- [32] Turan A, Kostakoglu N and Tuncel U. Reverse Superior Labial Artery Flap in Reconstruction of Nose and Medial Cheek Defects. *Ann Plast Surg* 2015; 74: 418-25.