

## Original Article

# Adjacent level disc degeneration: a prognostic factor for recurrent lumbar disc herniation after transforaminal endoscopic lumbar discectomy in 409 cases

Baoyi Zhou<sup>1\*</sup>, Kun Wang<sup>1\*</sup>, Xin Hong<sup>2</sup>, Yuntao Wang<sup>2</sup>, Suyang Zhuang<sup>2</sup>, Zengxin Gao<sup>2</sup>, Junping Bao<sup>2</sup>, Xiaotao Wu<sup>1,2</sup>

<sup>1</sup>Medical School of Southeast University, Nanjing 210009, Jiangsu, China; <sup>2</sup>Spine Center, Zhongda Hospital, Southeast University, Nanjing 210009, Jiangsu, China. \*Equal contributors.

Received June 3, 2016; Accepted August 8, 2016; Epub November 15, 2016; Published November 30, 2016

**Abstract:** Objective: This study aimed to investigate the prognostic factors for recurrent lumbar disc herniation (rLDH) after transforaminal endoscopic lumbar discectomy (TELD). Methods: A total of 409 patients who underwent TELD from June 2013 to March 2015 were divided into two groups based on recurrence, with 37 patients in the recurrent group and 372 patients in the non-recurrent group. The baseline characteristics (sex, age, smoking, drinking, hypertension, diabetes, work intensity, and postoperative exercises), clinical parameters (durations of symptoms, hospital stay, operation time, preoperative visual analog scale (VAS), and VAS improvement rates) and radiologic parameters (adjacent level disc degeneration) of the two groups were compared. Results: Among all the 409 patients, 13 in the recurrent group (35.1%) exhibited a large annular defect, with a significantly higher incidence than in the non-recurrent group (19.6%). Moreover, 35.1% of the patients in the recurrent group underwent postoperative exercises for paraspinal muscles, which was significantly higher than that in the non-recurrent group (53.8%). Adjacent level disc degeneration was significantly correlated with rLDH after TELD. Multivariate analysis showed that adjacent level disc degeneration, large annular defect and postoperative exercises for paraspinal muscles were significantly related to rLDH after TELD. Conclusion: Adjacent level disc degeneration, large annular defect and postoperative exercises for paraspinal muscles were prognostic factors for rLDH after TELD.

**Keywords:** Transforaminal, endoscopic, lumbar disc herniation, recurrent, degeneration

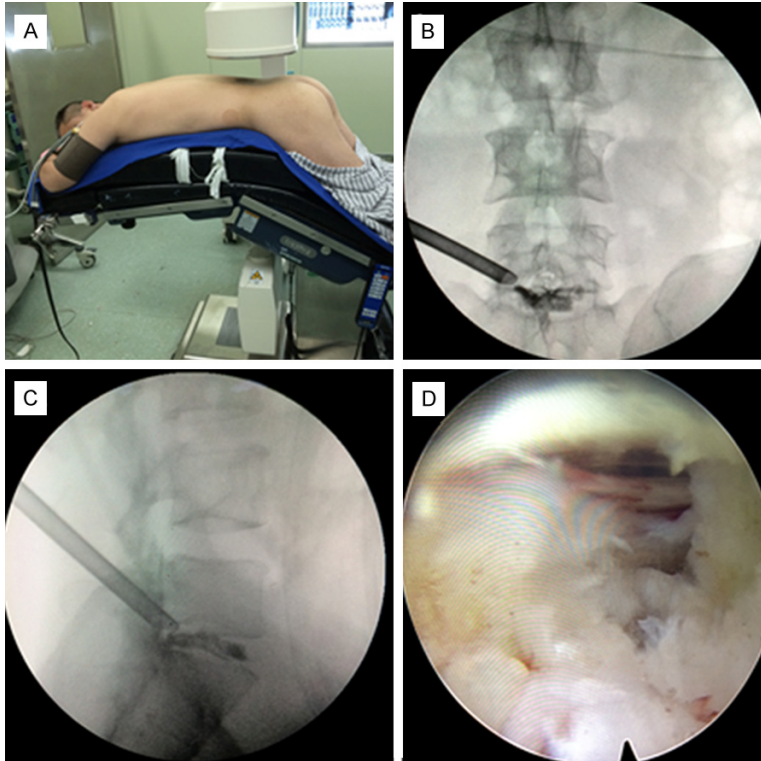
## Introduction

Recurrent lumbar disc herniation (rLDH) is a common disease process, which could be defined as the presence of herniated disc material at the same level, regardless of ipsilateral or contralateral herniation, in a patient who experienced a pain-free interval for at least 6 months after discectomy [1, 2]. rLDH occurs in 5%-15% of cases surgically treated for primary lumbar disc herniation [2-4]. A major cause of rLDH after discectomy is that the annular rent does not seal completely, thereby allowing the remains to be continually exposed to mechanical intradiscal pressure changes [5]. The prognostic factors for rLDH after conventional discectomy and microendoscopic discectomy (MED), such as disc degeneration, smoking, obesity, disc herniation type, age, sex, large

annular defect, and undergoing a traumatic event were investigated in numerous studies [2, 6-8].

Transforaminal endoscopic lumbar discectomy (TELD) has been widely performed and approved by spinal surgeons for the treatment of LDH in recent years [9-12]. Numerous studies have determined the recurrence rate of LDH to evaluate the clinical outcomes of TELD. Yeung [11] reported a recurrence rate of 5% in 307 consecutive patients with a follow-up time of 1 to 1.5 years. A prospective, randomized, and controlled study of 200 patients by Ruetten [13], revealed a recurrence rate of 7.8% after 2 years of follow-up. However, these studies did not analyze the prognostic factors for rLDH after TELD. Although previous studies demonstrated that rLDH may be influenced by several

## Recurrent factors after transforaminal endoscopic lumbar discectomy



**Figure 1.** A: Patient is placed in the prone position. B, C: Posteroanterior and lateral radiographs showing placement of the working tube after the injection of amethylene blue and iohexol. D: Intraoperative view in transforaminal approach.

factors, including sex, smoking, herniated disc generation, only a few studies considered adjacent level disc generation as a potential factor. From June 2013 to March 2015, 409 consecutive patients with a single-level lumbar disc herniation underwent TELD at our spinal center and were followed up for more than 1 year. In this study, we investigated whether the prognostic factors, such as adjacent level disc degeneration, being male, large annular defect, occupation and postoperative sports exercises, are associated with rLDH after TELD.

### Materials and methods

#### Study subjects

Formal consent was not required for this type of study. A total of 409 patients, who underwent TELD in our spine center between June 2013 and March 2015, were included in our study. The 409 patients with single-level LDH were divided into two groups, namely, the recurrent group (37 patients) and the non-recurrent group (372 patients). We compared the base-

line characteristics (sex, age, smoking, drinking, hypertension, diabetes, work intensity, and postoperative exercises), clinical parameters (durations of symptoms, hospital stay, operation time, preoperative visual analog scale (VAS), and VAS improvement rates) and radiologic parameters (adjacent level disc degeneration) of the two groups.

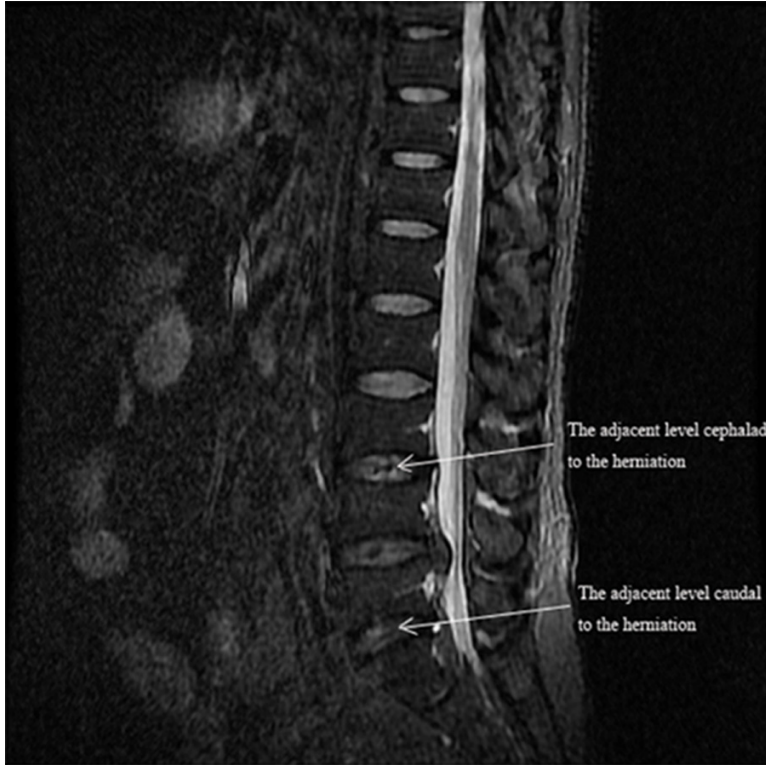#### Surgical techniques

Before surgery, a patient was placed in the prone position on a radiolucent table (**Figure 1A**). A C-arm radiograph was used to confirm the surgical disc. After routine disinfection, the skin and subcutaneous tissue of the patient were infiltrated with local anesthesia (1% lidocaine). The anesthetic was titrated to allow the patient to communicate with the surgeon throughout the procedure. The entry point was generally 10-14 cm from

the midline, and a long 18-gauge spinal needle was inserted from the entry point toward the midline, and in the anterior-posterior view, under intermittent fluoroscopic guidance. A guide wire was inserted into the disc; A mixed solution of amethylene blue and iohexol was injected via the puncture needle. Subsequently, the dilator and working cannula were inserted into the foramen under fluoroscopic guidance (**Figure 1B, 1C**). An endoscopic rongeur was used to remove the blue-stained degenerated nucleus, which was pathologically examined. The pulsation of the dural tube and nerve root was confirmed and used to indicate decompression (**Figure 1D**). Hemostasis was performed with bipolar diathermy. The endoscope was removed after no active bleeding was confirmed, and then one-point stitch was performed.

#### Measurements of variables

Lumbar magnetic resonance imaging was performed on all the 409 patients within one month before TELD. The degree of adjacent



**Figure 2.** A patient's T2 weighted magnetic resonance imaging, paramedial sagittal image showing adjacent level degeneration. Index level with herniated disc is L4/L5. Cephalad level graded as Pfirrmann 3. Caudal level graded as Pfirrmann 4.

level disc degeneration was assessed on T2-weighted sagittal sequences according to the original Pfirrmann grading scale. The adjacent levels cephalad and caudal to the herniation were graded in the cases of L3/4 and L4/5 levels (**Figure 2**), whereas only the cephalad disc was graded in the L5/S1 level. The size of annular defect after discectomy was checked by comparing it with a number-1 Penfield probe (6 mm) in the process of TELD. We defined annular defect >6 mm as a large annular defect. Preoperative radiating pain was assessed according to VAS. Postoperative exercises level was classified according to whether patients would exercise paraspinal muscles for at least half an hour every day after TELD.

#### Statistical analysis

The mean  $\pm$  SD was determined for the continuous variables, and the frequencies and percentages were determined for the categorical variables. We performed univariate analyses for baseline characteristics, clinical and radiologic parameters using unpaired Student's

*t*-test and the chi-square test. All the analyses were performed using the Statistical Package for the Social Sciences (SPSS for Windows, version 19.0 Inc.; Chicago, IL, USA), and statistical significance was accepted for  $P < 0.05$ .

#### Results

The baseline characteristics of the 409 cases, including the mean  $\pm$  SD and frequencies, are shown in **Table 1**. The mean ages of the recurrent and non-recurrent groups were 42.7 and 46.3 years old, respectively. The patients' durations of symptoms before TELD were 36.7 and 35.9 months respectively in the recurrent and non-recurrent groups, respectively. Postoperative exercise for paraspinal muscles was shown to be a prognostic factor for rLDH after TELD.

The clinical and radiologic parameters are presented in **Table 2**. Hospital stay, operation time, preoperative VAS and VAS improvement rates were not significantly different between the recurrent group and non-recurrent group. However, 13 patients exhibited a large annular defect in the recurrent group (35.1%), and a significantly higher incidence than that in the non-recurrent group (19.6%). Adjacent level disc degenerations of 409 patients were summarized, and a significant difference was observed between the two groups.

All the variables with a *P*-value not higher than 0.4 in the univariate analysis were included in the multiple logistic regression model (**Table 3**). The multiple logistic regression model showed that adjacent level disc degeneration, large annular defect and postoperative exercises for paraspinal muscles were prognostic factors for rLDH after TELD.

#### Discussion

Similar to pain relief [14] and life quality improvement [15], the recurrence rate of LDH

## Recurrent factors after transforaminal endoscopic lumbar discectomy

**Table 1.** Baseline characteristics of patients in each group

	Recurrent group (n=37)	Non-recurrent group (n=372)	P-value
Sex (male:female)	20:17	220:152	0.549
Mean age (y)	42.7±15.9	46.3±15.4	0.517
Mean durations of symptoms (months)	36.7±47.8	35.9±54.9	0.919
Smoking (+):(-)	7:30 (18.9%)	98:274 (26.3%)	0.324*
Drinking (+):(-)	5:32 (13.5%)	61:311 (16.4%)	0.649
Hypertension (+):(-)	8:29 (21.6%)	80:292 (21.5%)	0.987
Diabetes (+):(-)	2:35 (5.4%)	21:351 (5.6%)	0.952
Work intensity (high):(low)	20:17 (54.1%)	209:163 (56.2%)	0.804
Postoperative exercises (+):(-)	13:24 (35.1%)	200:172 (53.8%)	0.031**

\*P<0.4; \*\*P<0.05.

**Table 2.** Clinical and radiologic parameters of patients in each group

	Recurrent group (n=37)	Non-recurrent group (n=372)	P-value
Hospital stay (d)	7.8±2.9	7.6±3.2	0.972
Operation time (min)	92.3±36.4	96.4±28.6	0.155*
Preoperative VAS	7.8±0.9	8.0±1.0	0.335*
VAS improvement rate (%)	74.4±10.0	73.9±9.1	0.359*
Disc herniation level (L3/4:L4/5:L5/S1)	1:21:15	18:186:168	0.672
Grades of adjacent level disc degeneration (1:2:3:4:5)	1:7:12:14:25	3:142:127:176:128	0.005**
Annular defect Large size (≥6 mm):small size (<6 mm)	13:24 (35.1%)	73:299 (19.6%)	0.027**

\*P<0.4; \*\*P<0.05. VAS: visual analog scale.

**Table 3.** Predictors for rLDH using multivariate logistic regression analysis

Variables	OR	95% CI	P-value
Smoking	0.687	0.284-1.658	0.403
Postoperative exercises	0.415	0.199-0.865	0.019
Operation time	1.005	0.993-1.017	0.392
Preoperative VAS	1.312	0.891-1.931	0.168
VAS improvement rate	0.223	0.003-15.457	0.488
Adjacent level disc degeneration	0.576	0.422-0.841	0.003
Large annular defect (≥6 mm)	2.365	1.115-5.014	0.025

VAS: visual analog scale.

is an important parameter to evaluate the efficiency of different surgical procedures for discectomy. Certain discectomy techniques were suitable for particular patients. The prognostic factors for rLDH after different surgical procedures were inconsistent. Thus, this study investigated the prognostic factors for rLDH after TELD.

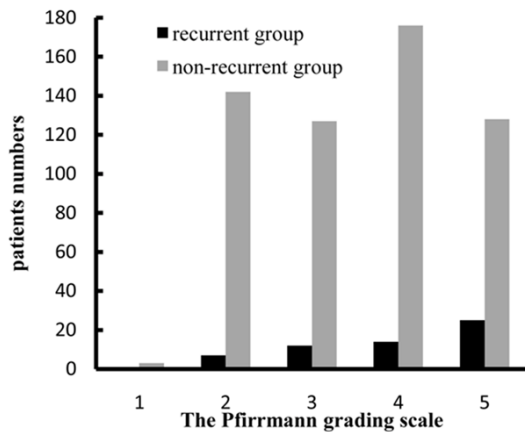
Disc degeneration was reported as a prognostic factor for rLDH [4, 16]. Kim et al [17] and Hasegawa et al [18] reported that moderate

disc degeneration (grades III, IV, V, and VI according to the modified Pfirrmann scale), which indicated a degenerative disc with a preserved disc height, is a prognostic factor for rLDH. Briseno et al [19] investigated the influence of adjacent level disc degeneration on the clinical outcomes after discectomy, and their results revealed no significant effect no significant effect on functional or pain relief outcomes. However, few studies reported the relationship between adjacent level disc degeneration

and rLDH. In the present study, as we hypothesized, higher grades of adjacent level disc degeneration could increase the recurrent rate of rLDH. (Figure 3) Adjacent level disc degeneration may raise the pressure on the operative level disc, thereby accelerating the degeneration rate of the operative level disc and leading to its recurrence.

Largeannular defect (>6 mm) was determined as a prognostic factor for rLDH after conventional open lumbar discectomy [6] and MED

## Recurrent factors after transforaminal endoscopic lumbar discectomy



**Figure 3.** Adjacent level disc degeneration of the recurrent group and non-recurrent group according to the Pfirrmann grading scale.

[17]. Thermal annuloplasty for the annulus fibrosus was performed with MED and TELD, which indicated that large annular defects should play the same role in the recurrence of LDH. A large annular defect would delay the healing process of the annulus fibrosus treated by thermal annuloplasty, so it can increase the recurrence rate of the remaining intervertebral disc material [20]. In the present study, a large annular defect was also the prognostic factor for rLDH.

Postoperative exercises for paraspinal muscles are recommended by surgeons to rehabilitate patients who undergo lumbar discectomy [21-23]. Patients without activity restrictions and those who exercise their exercises for paraspinal muscles immediately after lumbar discectomy regain normal function without increasing the rates of rLDH or other complications [24, 25]. In the present study, postoperative exercises for paraspinal muscles were associated with rLDH, which indicated that postoperative exercises for paraspinal muscles may reduce the recurrence of rLDH. Some studies have focused on the optimal components of early multimodal rehabilitation after lumbar discectomy and the timing of rehabilitation, but no consistent postoperative strategy has been carried out [26]. Nonetheless, postoperative exercises for paraspinal muscles are necessary to prevent rLDH.

Although this study carried out the independent evaluation of baseline characteristics, perioperative parameters, postoperative data

collection, and radiologic parameters, some limitations should be acknowledged. First, some potential factors that were not recognized should have been controlled to obtain more statistically meaningful results. Second, the patients included in our study underwent surgery in different periods and the proficiency of surgeons varied, TELD is a developing surgical technique, so the surgeons' influence on rLDH could not be eliminated. Third, this study was retrospective. In the future, a prospective controlled study will be conducted to prove our conclusion.

### Conclusion

Overall, TELD is an effective and safe procedure for lumbar disc herniation. In this study, we showed that adjacent level disc degeneration, large annular defect and postoperative exercises for paraspinal muscles were prognostic factors for rLDH after TELD.

### Acknowledgements

The work was supported by the Science and Technology Department of Jiangsu Province, China (BL2013031). We would like to acknowledge Dr. Suyang Zhuang, Dr. Zengxin Gao, Dr. Yuntao Wang, Dr. Zanli Jiang, and Dr. Shaocong Zhang for their tremendous contributions to this manuscript.

### Disclosure of conflict of interest

None.

**Address correspondence to:** Dr. Xiaotao Wu, Medical School of Southeast University; Spine Center, Zhongda Hospital, Southeast University, Nanjing 210009, Jiangsu, China. E-mail: wuxiaotao@med-mail.com.cn

### References

- [1] Mobbs RJ, Newcombe RL, Chandran KN. Lumbar discectomy and the diabetic patient: incidence and outcome. *J Clin Neurosci* 2001; 8: 10-13.
- [2] Suk KS, Lee HM, Moon SH, Kim NH. Recurrent lumbar disc herniation-Results of operative management. *Spine* 2001; 26: 672-676.
- [3] Swartz KR, Trost GR. Recurrent lumbar disc herniation. *Neurosurg Focus* 2003; 15: E10.
- [4] Kim KT, Park SW, Kim YB. Disc Height and Segmental Motion as Prognostic factors for

## Recurrent factors after transforaminal endoscopic lumbar discectomy

- Recurrent Lumbar Disc Herniation. *Spine* 2009; 34: 2674-2678.
- [5] Kim HS and Park JY. Comparative Assessment of Different Percutaneous Endoscopic Interlaminar Lumbar Discectomy (PEID) Techniques. *Pain Physician* 2013; 16: 359-367.
- [6] Carragee EJ, Han MY, Suen PW, Kim D. Clinical outcomes after lumbar discectomy for sciatica: The effects of fragment type and annular competence. *J Bone Joint Surg Am* 2003; 85-A: 102-108.
- [7] Cinotti G, Roysam GS, Eisenstein SM, Postacchini F. Ipsilateral recurrent lumbar disc herniation-A prospective, controlled study. *J Bone Joint Surg Br* 1998; 80: 825-832.
- [8] Kim JM, Lee SH, Ahn Y, Yoon DH, Lee CD, Lim ST. Recurrence after successful percutaneous endoscopic lumbar discectomy. *Minim Invasive Neurosurg* 2007; 50: 82-85.
- [9] Hoogland T, Schubert M, Miklitz B, Ramirez A. Transforaminal posterolateral endoscopic discectomy with or without the combination of a low-dose chymopapain: A prospective randomized study in 280 consecutive cases. *Spine* 2006; 31: E890-E897.
- [10] Lee DY and Lee SH. Learning curve for percutaneous endoscopic lumbar discectomy. *Neurol Med Chir* 2008; 48: 383-388.
- [11] Yeung AT and Tsou PM. Posterolateral endoscopic excision for lumbar disc herniation-Surgical technique, outcome, and complications in 307 consecutive cases. *Spine* 2002; 27: 722-731.
- [12] Ahn Y, Lee SH, Park WM, Lee HY, Shin SW, Kang HY. Percutaneous endoscopic lumbar discectomy for recurrent disc herniation: Surgical technique, outcome, and prognostic factors of 43 consecutive cases. *Spine* 2004; 29: E326-E332.
- [13] Ruetten S, Komp M, Merk H, Godolias G. Recurrent Lumbar Disc Herniation After Conventional Discectomy A Prospective, Randomized Study Comparing Full-endoscopic Interlaminar and Transforaminal Versus Microsurgical Revision. *J Spinal Disord Tech* 2009; 22: 122-129.
- [14] Wang K, Hong X, Zhou BY, Bao JP, Xie XH, Wang F, Wu XT. Evaluation of transforaminal endoscopic lumbar discectomy in the treatment of lumbar disc herniation. *Int Orthop* 2015; 39: 1599-1604.
- [15] Stienen MN, Joswig H, Smoll NR, Tessitore E, Schaller K, Hildebrandt G, Gautschi OP. Short- and long-term effects of smoking on pain and health-related quality of life after non-instrumented lumbar spine surgery. *Clin Neurol Neurosurg* 2016; 142: 87-92.
- [16] Dora C, Schmid MR, Elfering A, Zanetti M, Hodler J, Boos N. Lumbar disc herniation: do MR imaging findings predict recurrence after surgical discectomy? *Radiology* 2005; 235: 562-567.
- [17] Kim KT, Lee DH, Cho DC, Sung JK, Kim YB. Preoperative Prognostic factors for Recurrent Lumbar Disc Herniation in L5-S1. *J Spinal Disord Tech* 2009; 28: E571-E577.
- [18] Hasegawa K, Kitahara K, Hara T, Takano K, Shimoda H, Homma T. Evaluation of lumbar segmental instability in degenerative diseases by using a new intraoperative measurement system. *J Neurosurg Spine* 2016; 8: 255-262.
- [19] Briseno MR, Phukan RD, Leonard DA, Herzog TL, Cho CH, Schwab JH, Wood KB, Bono CM, Cha TD. The influence of adjacent level disc disease on discectomy outcomes. *Eur Spine J* 2016; 25: 230-234.
- [20] Carragee EJ, Spinnickie AO, Alamin TF, Paragioudakis S. A prospective controlled study of limited versus subtotal posterior discectomy: Short-term outcomes in patients with herniated lumbar intervertebral discs and large posterior annular defect. *Spine* 2006; 31: 653-657.
- [21] Oosterhuis T, Costa LO, Maher CG, de Vet HC, van Tulder MW, Ostelo RW. Rehabilitation after lumbar disc surgery. *Cochrane Database Syst Rev* 2014; 3: 1-105.
- [22] Williamson E, White L and Rushton A. A survey of post-operative management for patients following first time lumbar discectomy. *Eur Spine J* 2007; 16: 795-802.
- [23] McGregor AH, Dicken B, Jamrozik K. National audit of post-operative management in spinal surgery. *BMC Musculoskelet Disord* 2006; 7: 47.
- [24] Carragee EJ, Helms E, Osullivan GS. Are post-operative activity restrictions necessary after posterior lumbar discectomy? A prospective study of outcomes in 50 consecutive cases. *Spine* 1996; 21: 1893-1897.
- [25] Carragee EJ, Han MY, Yang B, Kim DH, Kraemer H, Billys J. Activity restrictions after posterior lumbar discectomy-A prospective study of outcomes in 152 cases with no postoperative restrictions. *Spine* 1999; 24: 2346-2351.
- [26] Hebert JJ, Fritz JM, Thackeray A, Koppenhaver SL, Teyhen D. Early multimodal rehabilitation following lumbar disc surgery: a randomised clinical trial comparing the effects of two exercise programmes on clinical outcome and lumbar multifidus muscle function. *Br J Sports Med* 2015; 49: 100-106.