

Original Article

The healing effect of celosia argentea leaf extract on burn wounds: an *in vivo* and *in vitro* evaluation

Wen-Zhe Guo¹, Hui Di², Ren Bao³, Guo-Hua Chu⁴, Xiao-Hui Tang⁵, Min Feng⁶, Li-Jun Diao⁷, Lu Lu⁸

Departments of ¹Plastic Surgery, ²Neurosurgery, ⁴Orthopaedic Surgery, ⁵Ultrasound, ⁸Anesthesiology, Affiliated Hospital of Hebei University, Shijiazhuang 071000, Hebei, P. R. China; ³Department of Plastic Surgery, Hebei Province Cangzhou Hospital of Integrated Traditional and Western Medicine, Cangzhou 061001, Hebei, P. R. China; ⁶Department of Plastic Surgery, Hebei Province Hospital of Skin Disease Prevention and Treatment, Baoding 071000, Hebei, P. R. China; ⁷Department of Plastic Surgery, The First Central Hospital of Baoding City, Baoding 071028, Hebei, P. R. China

Received July 3, 2016; Accepted September 1, 2016; Epub November 15, 2016; Published November 30, 2016

Abstract: Introduction: *Celosia argentea* (Amaranthaceae; CA), is applied for the management of several conditions including, wounds, haemorrhagic conditions, and gynaecological diseases. Alcoholic and ethyl acetate extracts of the CA leaves, as an ointment formulation (10% w/w), were assessed for the healing efficacy on rat burn wound models and was compared with silver sulfadiazine and *in vitro* cytotoxicity was assessed. Results: The topical treatment with the ointment formulation of CA extracts demonstrated early wound closure in the rats as compared with silver sulfadiazine and control group (21 days vs. 25 days vs. 30 days, respectively; $P < 0.001$). A considerable rise in the content of hexosamine and collagen was observed in the CA fraction applied wounds compared to silver sulfadiazine and control ($P < 0.05$; $P < 0.0001$). Cellular basis of the effect was confirmed by evaluating proliferation of cells and by measuring motility of cells in fibroblasts and keratinocytes cell lines. The data indicated that the extract was well-tolerated without any toxicity at strength of $< 30 \mu\text{g/ml}$ in keratinocytes and $< 3 \mu\text{g/ml}$ in fibroblasts ($P < 0.05$). The CA extract encouraged cellular growth and motility of dermal fibroblast at the concentrations of 0.1-1.0 $\mu\text{g/ml}$. Conclusion: The present study provides a rational pharmacological evidence for the use of CA extract on burn wound healing. This study for the first time compared the healing effect of the CA extract with the marketed formulation, silver sulfadiazine, and the results demonstrated that the herbal extract is more beneficial than the synthetic formulation.

Keywords: *Celosia argentea*, burn wounds, extraction, collagen content, hexosamine content, silver sulfadiazine

Introduction

Burns are one of the most devastating injuries to human health, in terms of disease and lasting disability around the globe, mainly in the developing nations. Burn healing is an intricate process and limited treatment options are available to assist the burn recovery process. The wounds are also susceptible to infection and other complications; 50-75% of deaths in hospitals are reported due to infection of burn wounds [1-4]. To restore interrupted anatomical stability and functional status of the skin, appropriate healing of the burn wound is required. Various aspects play an important role in the healing process of burn wound, including human acidic fibroblast growth factor, angiogenesis, and tissue repair. The sequence of events takes place for the repair of injured tissue, which includes inflammation, prolifera-

tion, and migration of different cell types. The stage of inflammation starts immediately after injury, first with vasoconstriction that favours homeostasis and releases inflammation mediators. Second is a proliferative phase and is characterized by granulation tissue proliferation formed mainly by fibroblast and the angiogenesis process [5-7].

Currently, there are many topical formulations available in the market for the treatment of burn wounds, but there is still a clear lack of effective drugs since most of the formulations available possess antimicrobial properties rather than wound healing effect. Some synthetic formulations, like silver sulfadiazine, have negative performance effect and toxicity on fibroblasts [8, 9]. Even in today's modern medicine era, only 1-3% of synthetic drugs are suggested to be effective on damaged and nor-

Healing effect of celosia argentea leaf extract on burn wounds

mal skin whereas one-third of herbal medicines are used for same indications [10]. Herbal based products can treat burn wound because of their different constituents like flavonoids, oils, alkaloids, saponins, tannins, phenolic compounds and terpenoids. In addition to the easy availability of herbal medicines, these have low cost, possess very few side effects and are generally considered to be safe [11-13].

Celosia argentea (Amaranthaceae; CA), also familiarly called as troublesome weed, is employed in Chinese medication for the management of several conditions including, wounds, ulcers, sores, haemorrhagic conditions, gynaecological diseases, dysentery and dysuria [14-18]. Extracts of CA has been reported to have Anti-DNP IgE production in rats and has also been reported to possess hepatoprotective, antiprotozoal, antimicrobial and hypothermic activities [19-22]. The above-mentioned activities may prevent wound injury from being getting contaminated, but a very little is known about the fact how they support burn wound healing. There are very few publications available which evaluated the effect of CA leaf extract on burn wound therapy, and no publication has compared the effect of CA leaf extract with silver sulfadiazine, a gold standard for the treatment of wound therapy [17, 22]. If the CA leaf extract has wound healing effect, this should be demonstrated by improvement in cellular activities or by improvement of other bioactive factors. This work is aimed to investigate the efficacy and tolerability of the CA extract on burn wound management and compare the efficacy of the extract with a marketed formulation.

Materials and methods

Leaves of *celosia argentea* (CA) Linn. (Amaranthaceae family) were collected from China. The plant species was authenticated by the staff of the Department of Botany, Faculty of Art and Science, Hebei University. To reduce any variations due to climatic conditions and location, the plant material was collected in large quantities at the same time.

Plant material and preparation of extract

About 200 g of powdered leaves (dry) of CA were extracted with absolute ethanol. The ex-

traction process was carried out using a soxhlet apparatus for a time period of 8-10 h. Ethanol was removed under pressure and it yielded an ethanol-free semisolid mass with a yield of 13.0% (w/w). An ointment (10% w/w) was formulated using 10 g of the CA fraction with 100 g of soft white paraffin (soft white; Sigma-Aldrich, Germany). To investigate the extraction ability of other solvent, extraction was carried out by using ethyl acetate (Sigma Chem. Ind., St. Louis, MO, USA). The extraction procedure followed for extraction and drying of ethyl acetate solvent was same as that of ethanol solvent. Additionally, to evaluate any effect of temperature, an alcoholic extract was collected at working temperature and was kept on the shaker for the whole night with 2 changes, and then obtained extract (alcohol-free) was utilised for future experiments. No significant difference in the yield value, efficacy was found in the ethanol and ethyl acetate extracts.

Wound creation, rodent grouping and ointment application

Rats (Albino Wistar strain) with an average weight ranging between 100 and 120 g were utilised as the study model in this work. The experimental rats were housed individually at $26\pm 3^{\circ}\text{C}$ and at a relative humidity of 42-55%, in uniform environmental surroundings, feed with pellet supply and water was provided as required. A total of 18 rats were divided into three cohorts (treatment, standard and control cohort) and these cohorts were employed in the study to investigate the efficacy of the CA fraction and was also compared the efficacy with the marketed formulation treated cohort and untreated cohort in a rat burn wound model. Thirty rodents in each treatment arm were studied, where 5 rodents were assigned for each day 1, 3, 7, 10, 14, 20 and 25 for biochemical examination. After 7 days of thorough monitoring, back of the rats were shaved and an open excision burn wounds were made by a heated metal stick (1.5 cm length and $80-85^{\circ}\text{C}$) with exposure time of twenty seconds under ether anesthesia. With the help of sterilized surgical razorblade, dead skin was removed after approximately 24 hours and this procedure created full-thickness burn lesions. The area of the wound was calculated by tracing the circumference of the raw wound. The rats were allocated to three cohorts (n = 6/cohort). Control cohort (group 1) was soft par-

Healing effect of celosia argentea leaf extract on burn wounds

affin alone while experimental cohort (group 2) was dressed with the 10% formulated CA extract ointment and cohort 3 included animals treated with 1% SSD (silver sulfadiazine, Behvarzan Pharmaceutical, China). In all the studied groups, dressings were changed on alternate days. The area of the injuries of the day 1 was considered as 100% and injury areas on subsequent days were compared with the wound area on the day one. To evaluate any weight changes the rats were weighed on different days. The animals were weighed on the different days after the burn injury. All experimental procedures were approved and conducted in compliance with Ethical Committee and Human Investigational Committee of Hebei Medical University (Shijiazhuang, China).

Measurement of injury contraction

The rate of burn injury reduction was assessed as percentage decrease in injury dimensions at each alternative day. The boundary of the wounds was traced and the area was read graphically to examine the wound contraction on the scheduled days. Representative photograph showing the effect of extract and silver sulfadiazine treatment compared to control group is depicted in **Figure 1** and a representative graph showing average wound contraction is depicted in **Figure 2**.

Histochemical examination

Five animals were sacrificed and the injury zone was washed with normal saline solvent. Formed granulation tissues were removed and then were instantly freezed and preserved. The collected tissues were lyophilized between four and six hours for future biochemical estimations.

Hydroxyproline and hexosamine estimation

The lyophilised granulation tissues were collected on the pre-specified days was hydrolyzed by employing 6 N HCl solution at a temperature of 110°C for twenty hours. Evaporation of granulation tissue was carried out until they were dried and the obtained residue was solubilised in water after hydrolysis. The method described by Woessner was employed to estimate the hydroxyproline content. As per Woessner's method, addition of chloramine-T was performed to carry out oxidization of hydroxy-

proline to pyrrolecarboxylic acid, that subsequently with para-dimethyl-amino benzaldehyde (PDAB) resulted into a complex that was read with the help of spectrometer at 557 nm (Woessner, 1962). To determine the hexosamine content, hydrolysis of obtained granulation tissue was carried out till complete evaporation with the help of 2 N hydrochloric acid at about a temperature of 100°C for six hours. The obtained residue was then solubilised in water. Procedure reported by Elson and Morgan was employed to investigate the hexosamine content. The method involved condensation of hexosamine with acetyl acetone alkaline solvent that eventually formed a pyrrole compound which eventually reacted with para-dimethyl-amino benzaldehyde and the obtained coloured product was read with the help of spectrometer at 530 nm.

Cell proliferation

To carry out this experiment primary human dermal fibroblasts (Hs68), procured from Institute of Cell Biology, Shanghai Institute for Biological Science, China, were grown at 37°C in a 5% carbon dioxide surroundings. To limit aging alterations, fibroblasts were used before to passage 10 [24, 25]. All the required reagents for cellular culture were procured from Life Technologies, Carlsbad, CA, USA. Growth medium utilised contained Dulbecco's modified Eagle's medium which consisted of 1 mM sodium pyruvate, antibiotics 1% of streptomycin and penicillin and 1× MEM nonessential amino acid mixture, 2 mM L-Glutamine and 26 mM sodium carbonate with 10% fetal bovine serum. The cell growth was halted at subconfluence by a similar culture medium with only partial serum environment which consisted of 0.1% dialyzed fetal bovine serum for a time period of 48 hours before to investigations. Human epidermal keratinocytes (HEKn) and all other required culture chemicals were procured from Life Technologies. Keratinocytes were utilized up to passage 4 and the undifferentiated state of the cells was sustained by maintaining calcium strengths below 0.06 mM. EpiLife medium was employed to culture cells, that is devoid of serum but comprises bovine pituitary extract 0.2% (v/v), hydrocortisone 0.18 mg/ml, transferrin 5 mg/ml, bovine insulin 5 mg/ml, and human epidermal growth factor (EGF) 10.2 ng/ml. HEKn cells were growth stopped at 30%

Healing effect of celosia argentea leaf extract on burn wounds

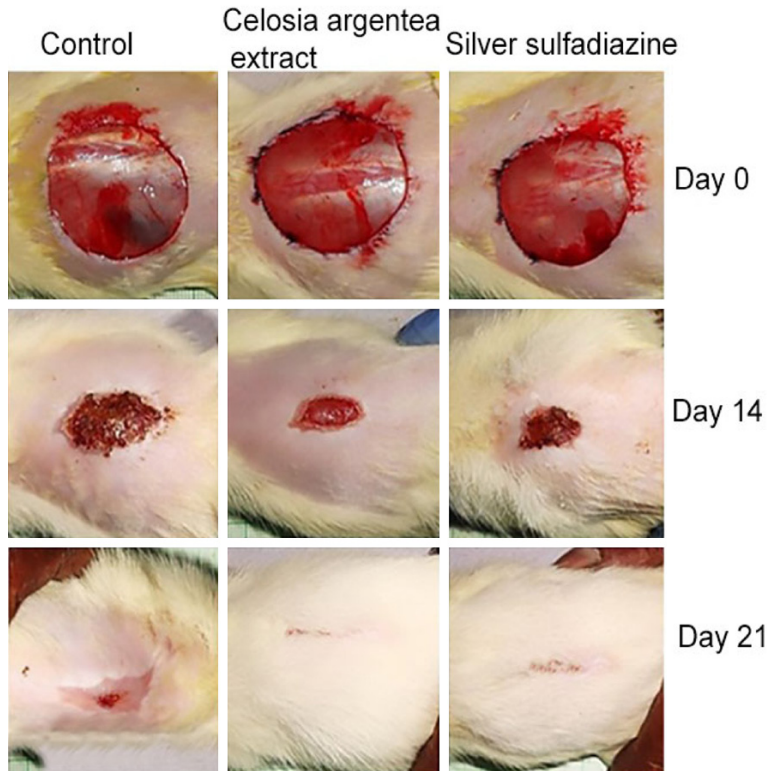


Figure 1. Representative images of burn wound healing pattern in control, CA leaf extract-treated and silver sulfadiazine groups. Healing rates were measured graphically and photographed at regular intervals.

confluence, by the similar culture medium but was deprived of insulin, bovine pituitary extract and EGF for 2 days prior to cure.

Estimation of cell toxicity by methylthiazole tetrazolium (MTT) assay

Cell cytotoxicity test was employed to determine the test range of concentrations to be used for experimental procedures. Cell toxicity was evaluated by the measuring the capability mitochondrial cells to reduce the MTT dye. Growth-arrested cells were treated with the CA fraction at different strengths of 0.1, 0.3, 1.0, 3.0, 10 mg/ml for 72 hours and then these cells were incubated for four hours. After four hours, MMT was removed and formed formazon product was solubilized in 1 ml of acidified isopropanol (IPA) (0.05 M HCl in IPA) and was read at 570 nm spectrophotometrically.

Cell multiplication

Effect of the CA fraction on cell proliferation was estimated by using Counter (model PN9914591; Beckman Coulter). The growth of

the cells was arrested and then was treated with CA extract for 72 hours. Isotone solution was employed for the trypsinization and dilution of the CA extract treated cells and control cells (Beckman Coulter, Hialeah, FL). Enumeration of the cells was made by impedance counting using a Coulter Counter.

Statistical analysis

To measure the mean values of statistical comparisons tukey post-test and ANOVA were employed. Correlation of the variables was assessed by using bivariate correlation analysis. Differences with $P < 0.01$ and $P < 0.005$ were considered statistically significant and all P -values were determined by two-sided tests. The statistical analysis was carried out with SPSS 12.0 software.

Results

The mean weight of rats in all the groups was determined. Mean weight of rats in three groups of CA extract treated, control, and silver sulfadiazine before beginning of the study was 106, 110 and 103 g, and after four days of cure was reduced to 100, 105 and 98 g, respectively. Significant differences were not witnessed in terms of weight loss among the groups. The average weight of animals increased after the 25 day treatment period to 130, 132 and 135 g, respectively.

At the seventh day, wound condition was estimated in all the three groups for precise determination of injury size. After 7, 14, 21, 25 and 30 days of burn injury, burn wounds were assessed and their ratio to day one was estimated. After 25 days, the average size of wound was 4.8, 3.9 and 1.0 cm² in control, silver sulfadiazine and CA-treated groups, respectively. Among CA group, silver sulfadiazine group and the control group existed significant differences ($P < 0.0001$). Among all the three groups of control, silver sulfadiazine and CA treatment, statistical difference was not significant with

Healing effect of celosia argentea leaf extract on burn wounds

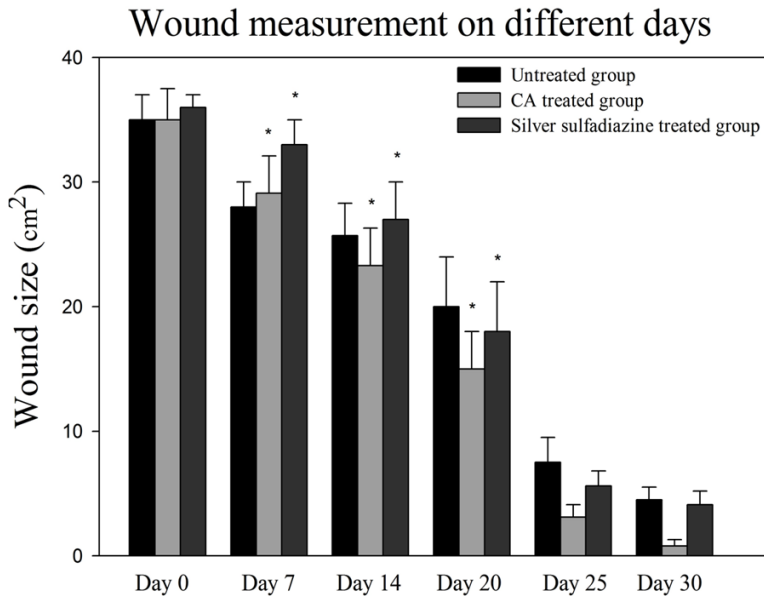


Figure 2. Average wound contraction in each group, measured between 0 and 30 days. * $P < 0.0001$.

respect to the wound size on the 25th day. The final form of the wound after the treatment was linear and dissimilarities were not significant between the CA extract and silver sulfadiazine groups (**Figures 1 and 2**).

Effect of CA extract on dermal wound maturation

For a satisfactory wound healing, restoration of the temporary granulation condition by a matrix which is affluent in hexosamine and new collagens and their subsequent maturation is essential. The increase in the collagen content in the CA extract treated animals as compared to control group would clearly suggest that the extract is promoting collagen synthesis through increased cell division. The content of collagen rose considerably at 11 ± 2 mg/100 mg of dry tissue on the third day in the CA extract cohort when compared to only 7 ± 1 mg/100 mg in untreated groups ($P < 0.0001$) (**Figure 3A**). Similar elevation was observed for hexosamine content for proteoglycan, in the CA extract treated wound. Hexosamine content rose at 0.45 ± 0.03 mg/100 mg of dry tissue on the third day in the CA extract cohort when compared to only 0.25 ± 0.020 mg/100 mg in the control cohort ($P < 0.05$) (**Figure 3B**). In the CA extract treated burn injuries, improved epithelialization, wound contraction and granulation tissue formation was observed when com-

pared to control indicating a rapid and important rise in both hexosamine and collagen content. In the CA extract group, hexosamine and collagen mass reduced slowly during the last days of the treatment indicating the restructuring phase and on a contrary gradual rise in control groups till the last day indicating that it was still in the propagative stage. The absolute content of the indicators was corresponding to that in the control cohort.

Effect on fibroblast and keratinocytes proliferation

To confirm the effect of the *C. argentea* fraction for the improved injury cessation at the cellular level, human primary fibroblasts and keratinocytes were employed. MTT assay was employed for assessing cell metabolic activity. It was found that the CA fraction has not affected the capability of fibroblasts and keratinocytes to reduce the MTT dye (a yellow tetrazole), an indicator of the number of viable cells, until a strength of $30 \mu\text{g/ml}$ in keratinocytes and $3 \mu\text{g/ml}$ in fibroblasts ($P < 0.05$) (**Figure 4A, 4B**). The tested concentrations of CA extract enhanced the motility ($P < 0.05$) (**Figure 5A, 5B**) and fibroblast proliferation ($P < 0.05$) (**Figure 6A, 6B**). After a 72 hour time period, it was observed that at the concentrations of $0.1 \mu\text{g/ml}$ and $3 \mu\text{g/ml}$ the mitogenic effect was greater as compared to mitogenic effect induced by the epidermal growth factor.

To confirm that the cell growth was not due to the carrier, a different plant extract was extracted in the similar way and in that it was observed that it didn't produce any cell multiplication. In addition, the *C. argentea* fraction has not encouraged the propagation of keratinocytes showing that the outcome was cell selective. On keratinocytes, the *C. argentea* fraction did not have any effect, even though there seemed to be a tendency toward improved motility. Cell motility was low but was visible at $0.1 \mu\text{g/ml}$ and $0.3 \mu\text{g/ml}$ and this was improved at $1.0 \mu\text{g/ml}$ prior to decreasing at levels of the

Healing effect of celosia argentea leaf extract on burn wounds

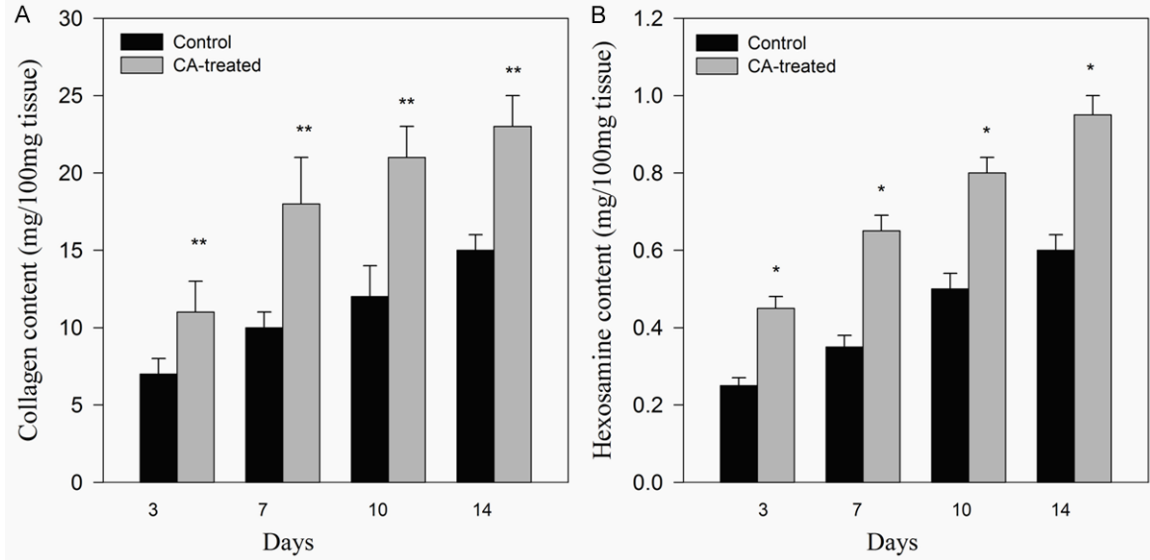


Figure 3. Treatment effect of CA extract on collagen and hexosamine content in granulation tissue on different days of healing. 10 mg of lyophilized granulation tissue were used to estimate hydroxyproline content, from which collagen content was estimated and hexosamine content in control and CA-treated rats on days 3, 7, 10, and 14. A: Collagen content; B: Hexosamine content. **P < 0.0001; *P < 0.05.

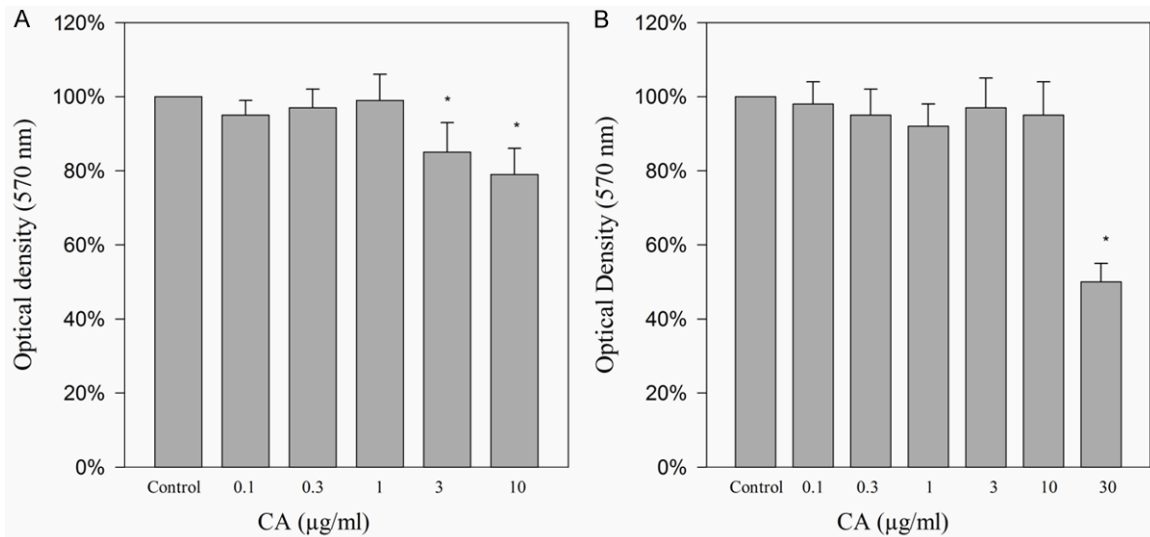


Figure 4. Cytotoxicity of CA on human dermal fibroblast and keratinocytes. A: Fibroblast treated from 0.1 to 10.0 µg/ml (Hs68); B: Keratinocytes treated with 0.1 to 30 µg/ml for 72 hours (HEKn). The values are expressed as percentages normalized to control in mean ± SEM. (n = 3), *P < 0.05.

C. argentea fraction that adversely influenced reduction of MTT dye (Figure 5A, 5B).

Discussion

A wound is an injury to living tissue that may be caused by a cut, blow, burn or other impact, typically one in which the skin is cut or broken. For the restoration of the disturbed functional

status of the skin and disrupted anatomical continuity, proper wound healing is required. The process of wound healing is complex and is characterised by re-epithelialisation, homeostasis, remodelling of the extracellular matrix and granulation tissue formation [1-3, 10, 12, 26]. Generally, the healing process takes place by its own, but factors like infection, ischemia, venous stasis, co-morbid conditions may delay

Healing effect of celosia argentea leaf extract on burn wounds

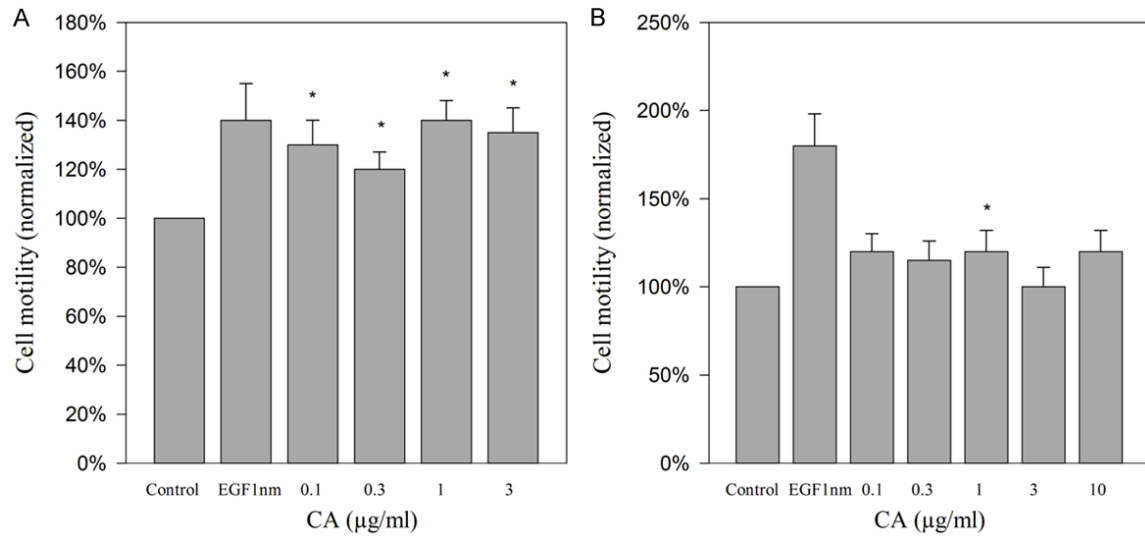


Figure 5. Measurement of cell motility of human dermal fibroblast and keratinocyte after application of CA extract. After 72 hours, cells were treated with CA at concentrations of 0.1, 0.3, 1.0 and 3.0 µg/ml (A) fibroblasts (Hs68) (B) keratinocytes (HEKn). The values are expressed as percentages normalized to control in mean ± SEM. (n = 3), *P < 0.05.

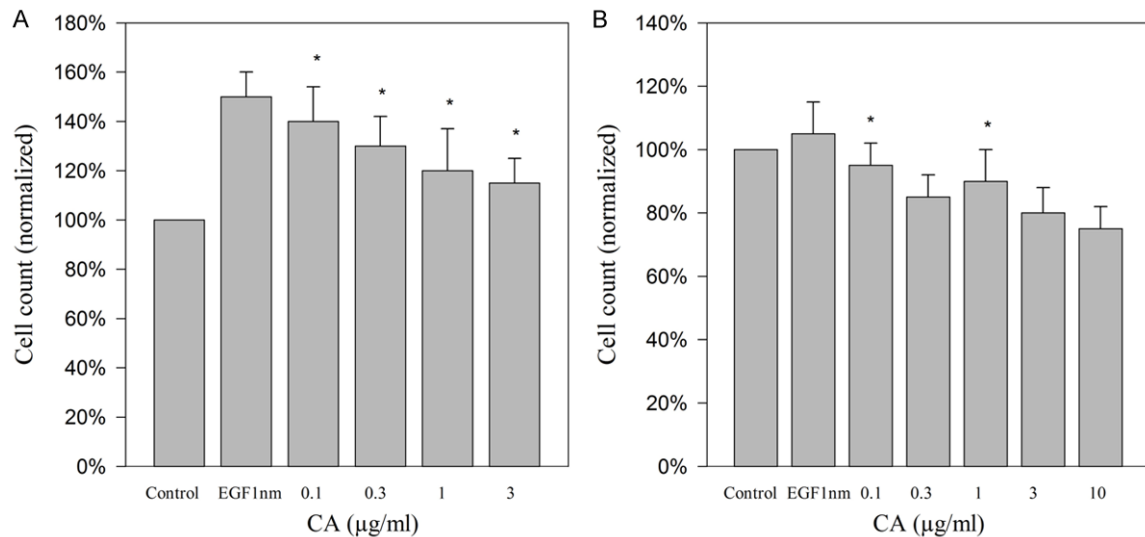


Figure 6. Measurement of cell proliferation of human dermal fibroblast and keratinocyte after application of CA extract. CA extract was applied after 48 hours at a concentration of 0.1 to 10 µg/ml (A) fibroblasts (Hs68) (B) keratinocytes (HEKn). The values are expressed as percentages normalized to control in mean ± SEM. (n = 3), *P < 0.05.

the process. Several plants and plant-derived products had been reported in literature to possess therapeutic capability to encourage burn wound healing. Several publications on celosia argentea have been reported to possess therapeutic efficacy on burn wounds, diarrhoea, antioxidant activity, antitumor and anti-inflammatory [14-18, 26]. In the present study, both macroscopic and microscopical examinations were used to evaluate the effectiveness and safety

of CA leaf extract for the management of burn wound injuries.

Several studies have been reported that the main cause of mortality in patients with widespread burns is infection [12, 16, 17]. For the treatment of these burns and to reduce its related infection, many researchers are working around the world. Currently available treatment options of disinfectants and topical anti-

Healing effect of celosia argentea leaf extract on burn wounds

bacterial agents are good in shielding against infection, but the incidence of skin irritations and sensitive episodes to these medicines decreases the speed of skin rejuvenation and increases the regaining time. Despite advancement in the modern medicine, management of burn is still a challenge and only a few compounds are available which accelerate the healing process. Alternatively, plants and their extracts can be used in the management of burn therapy. Reports showed that herbal medicine are less expensive and has moderate efficacy with no or less toxicity as compared with synthetic drugs. Exploring different plant materials and their extracts for the management of burn therapy is required.

In the present study, CA extract was compared with a marketed formulation, silver sulfadiazine, as the standard treatment for burn wounds in the rat model. The extent of healing with CA extract was superior to silver sulfadiazine and base cream. The healing effect was established in the rat burn wound model, biochemical assay of the wound and *in vitro* studies. Silver sulfadiazine is most commonly used for the topical treatment for burn injury and the antimicrobial efficacy of SSD is possibly the main rationale for the usage of this agent. Although SSD is widely used, its long-lasting application on the burn wound may result in a longer hospitalization. The delay in the dermal fibrosis and re-epithelialization in the SSD may be attributed to its inflammatory effect. Both keratinocytes and fibroblasts are liable to lethal damage when exposed to concentration of silver which are toxic for bacteria. In other words, silver containing products cannot discriminate between healthy cells involved in wound healing and bacteria which caused infection. Our experimental results indicated that wound healing is often observed clinically following the use of silver-containing products. The results indicate that treatment with CA extract could lead to a shorter hospitalization of burned patients compared with SSD.

C. argentea leaves have been used for management of injuries in Chinese and Indian traditional medicine. The outcomes from this work concluded that alcoholic fraction promotes the treatment of injuries caused by burn. The outcome was further supported by injury treatment trial in a rat model, *in vitro* experiments, and biochemical analysis of wound biopsy. The

exact mechanism through which the CA extracts heals burn wounds is a matter of further research. The probable mechanism by which the extract acts and heals burn wounds may be by decreasing inflammatory response, increasing the flow of blood at the site and by reducing infection. The chemical constituents present in the CA extract like celosian, flavonoids, phenolic compounds, and vitamins may promote healing by induction of antioxidant enzymes and scavenging of free radicals. As observed in the present study, the early closure of wounds and reduction of the post burn complications may be attributed to the presence of some chemical constituents present in the alcoholic extract of the CA leaves. Previous publications also confirm the antimicrobial activity of CA extract on burn wounds and thus preventing the inflammation phase because of infection [22].

In the biochemical analysis, it was observed that hydroxyproline content was increased in the CA extract treated animals, which in turn is a reflection of increased cellular proliferation and increased collagen synthesis. The synthesized collagen confers integrity, strength of the tissue matrix and also helps in maintaining homeostasis and epithelialisation at the later phase of healing, thus remodelling of a new extracellular matrix produced. The process of wound healing involves migration of fibroblasts from the edges of wound to the site of wound, proliferate and generate collagen, which is the important component in the extracellular matrix. So, stimulation of the fibroblast and migration of keratinocytes, as confirmed in this study, might have been contributed to the wound healing process. The process of the wound healing pattern in the treated group was mainly because of the phytoconstituents present in the extract that might have the capacity to encourage the initial expression of growth factors or growth factor-like activity [14, 22]. In the present study, we have also carried out the extraction using ethyl extract and it was observed that there was no significant difference between the extracts obtained from ethyl alcohol and ethyl acetate. This provides researchers with an option to select the solvent based on their availability and cost.

The use of a rat wound model for evaluating the effect of the healing potential of the CA extract carries some drawbacks. Rat wound

Healing effect of celosia argentea leaf extract on burn wounds

model does not exactly mimic human skin burn wound model since rats are generally regarded as loose-skinned animals and this allows wound contraction to play an important role in closing rat skin wounds. Humans have tight skin as compared to loose-skinned animals, which makes the comparison difficult. Despite these drawbacks, the use of rats as a research model is popular because of the complete understanding of the rat wound healing obtained from the earlier research.

Conclusion

The topical use of CA extract ointment accelerates the re-epithelialization of burn wound with proper healing process as compared with the marketed product. The experiment confirmed the therapeutic action of the CA leaves extract and was supported by the *in vivo* and *in vitro* data. The results obtained also provide rational pharmacological evidence for the use of the CA extract in the treatment of various types of wounds. Results from this study deliver reasonable pharmacological proof for the use of CA leaves extract for the treatment of burn wounds.

Disclosure of conflict of interest

None.

Address correspondence to: Lu Lu, Department of Anesthesiology, Affiliated Hospital of Hebei University, No. 212, Yuhudong Road, Baoding District, Shijiazhuang 071000, Hebei, P. R. China. Tel: 0086-312-5981818; Fax: 0086-312-5981818; E-mail: 408864292@qq.com

References

- [1] Bahramsoltani R, Farzaei MH, Rahimi R. Medicinal plants and their natural components as future drugs for the treatment of burn wounds: an integrative review. *Arch Dermatol Res* 2014; 306: 601-617.
- [2] Maenthaisong R, Chaikyakunapruk N, Niruntraporn S, Kongkaew C. The efficacy of aloe vera used for burn wound healing: a systematic review. *Burns* 2007; 33: 713-718.
- [3] Heimbach D. Burn patients, then and now. *Burns* 1999; 25: 1-2.
- [4] Mokaddas E, Rotimi VO, Sanyal SC. In vitro activity of piperacillin/tazobactam versus other broad-spectrum antibiotics against nosocomial gram-negative pathogens isolated from burn patients. *J Chemother* 1998; 10: 208-214.
- [5] Hackam DJ, Ford HR. Cellular, biochemical, and clinical aspects of wound healing. *Surg Infect (Larchmt)* 2002; 3: S23-S35.
- [6] Singer AJ, Clark RA. Cutaneous wound healing. *N Engl J Med* 1999; 341: 738-746.
- [7] Werner S, Grose R. Regulation of wound healing by growth factors and cytokines. *Physiol Rev* 2003; 83: 835-870.
- [8] Vloemans AF, Soesman AM, Suijker M, Kreis RW, Middelkoop E. A randomised clinical trial comparing a hydrocolloid-derived dressing and glycerol preserved allograft skin in the management of partial thickness burns. *Burns* 2003; 29: 702-710.
- [9] Atiyeh BS, Costagliola M, Hayek SN, Dibo SA. Effect of silver on burn wound infection control and healing: review of the literature. *Burns* 2007; 33: 139-48.
- [10] Kumar B, Vijayakumar M, Govindarajan R, Pushpangadan P. Ethnopharmacological approaches to wound healing—exploring medicinal plants of India. *J Ethnopharmacol* 2007; 114: 103-113.
- [11] Kimura Y, Sumiyoshi M, Kawahira K, Sakanaka M. Effects of ginseng saponins isolated from Red Ginseng roots on burn wound healing in mice. *Br J Pharmacol* 2006; 148: 860-870.
- [12] Hosseini SV, Tanideh N, Kohanteb J, Ghodrati Z, Mehrabani D, Yarmohammadi H. Comparison between Alpha and silver sulfadiazine ointments in treatment of Pseudomonas infections in 3rd degree burns. *Int J Surg* 2007; 5: 23-26.
- [13] Stipcevic T, Piljac A, Piljac G. Enhanced healing of full-thickness burn wounds using di-rhamnolipid. *Burns* 2006; 32: 24-34.
- [14] Bhakuni DS, Dhar ML, Dhar MM, Dhawan BN, Mehrotra BN. Screening of Indian plants for biological activity. II. *Indian J Exp Biol* 1969; 7: 250-262.
- [15] Hase K, Basnet P, Kadota S, Namba T. Immunostimulating activity of Celosia, an anti-hepatotoxic polysaccharide isolated from Celosia argentea. *Planta Med* 1997; 63: 216-219.
- [16] Sharma P, Vidyasagar G, Singh S, Ghule S, Kumar B. Antidiarrhoeal activity of leaf extract of celosia argentea in experimentally induced diarrhoea in rats. *J Adv Pharm Technol Res* 2010; 1: 41-48.
- [17] Priya KS, Arumugam G, Rathinam B, Wells A, Babu M. Celosia argentea Linn. leaf extract improves wound healing in a rat burn wound model. *Wound Repair Regen* 2004; 12: 618-625.
- [18] Wu Q, Wang Y, Guo M. Triterpenoid saponins from the seeds of Celosia argentea and their anti-inflammatory and antitumor activities. *Chem Pharm Bull (Tokyo)* 2011; 59: 666-671.

Healing effect of celosia argentea leaf extract on burn wounds

- [19] Imaoka K, Ushijima H, Inouye S, Takahashi T, Kojima Y. [Effects of *Celosia argentea* and *Cucurbita moschata* extracts on anti-DNP IgE antibody production in mice]. *Arerugi* 1994; 43: 652-659.
- [20] Hase K, Kadota S, Basnet P, Takahashi T, Namba T. Protective effect of celosian, an acidic polysaccharide, on chemically and immunologically induced liver injuries. *Biol Pharm Bull* 1996; 19: 567-572.
- [21] Wiart C, Mogana S, Khalifah S, Mahan M, Ismail S, Buckle M, Narayana AK, Sulaiman M. Antimicrobial screening of plants used for traditional medicine in the state of Perak, Peninsular Malaysia. *Fitoterapia* 2004; 75: 68-73.
- [22] Gnanamani A, Priya KS, Radhakrishnan N, Babu M. Antibacterial activity of two plant extracts on eight burn pathogens. *J Ethnopharmacol* 2003; 86: 59-61.
- [23] Woessner JF Jr. Catabolism of collagen and non-collagen protein in the rat uterus during post-partum involution. *Biochem J* 1962; 83: 304-314.
- [24] Shiraha H, Gupta K, Drabik K, Wells A. Aging fibroblasts present reduced epidermal growth factor (EGF) responsiveness due to preferential loss of EGF receptors. *J Biol Chem* 2000; 275: 19343-19351.
- [25] Tran KT, Rusu SD, Satish L, Wells A. Aging-related attenuation of EGF receptor signaling is mediated in part by increased protein tyrosine phosphatase activity. *Exp Cell Res* 2003; 289: 359-67.
- [26] Paiva LA, de Alencar Cunha KM, Santos FA, Gramosa NV, Silveira ER, Rao VS. Investigation on the wound healing activity of oleo-resin from *Copaifera langsdorffii* in rats. *Phytother Res* 2002; 16: 737-739.