

Original Article

A novel and precise method for evaluation of chronic subdural hematoma volume

Yuehua Wang¹, Yuchen Li¹, Ying Zhu², Tie Lin¹, Yifei Zhang², Huaizhang Shi¹

¹Department of Neurosurgery, The First Affiliated Hospital of Harbin Medical University, Harbin 150001, China;

²School of Mechatronics Engineering, Harbin Institute of Technology, Harbin 150001, China

Received July 16, 2016; Accepted September 5, 2016; Epub April 15, 2017; Published April 30, 2017

Abstract: This study aimed to establish and validate a new volume estimation method for chronic subdural hematoma (CSDH) based on the shape of CSDH similar to ellipsoid. Forty-six CT scans diagnosed as CSDH were reviewed. Based on the shape of CSDH more close to crescent or ellipsoid, we derived a volume formula, and calculated the hematoma volume by using v (formula), v (2/3sh), v (1/2abc) and v (1/3abc), respectively, with computer-assisted volumetric analysis (CAVA) as gold standard. There are no statistical differences between v (formula) and v (Gold standard) groups (63.42 ± 9.92 vs. 63.42 ± 9.92 , $P > 0.05$), whereas the hematoma volumes of v (2/3sh), v (1/2abc) and v (1/3abc) groups significantly differed from v (formula) or v (Gold standard) group (71.69 ± 13.58 , 81.40 ± 15.59 , and 51.82 ± 9.92 , $P < 0.05$). Besides, there was a significant correlation between v (formula) and v (Gold standard) groups using Pearson coefficient ($r = 0.978$, $P < 0.001$), suggesting that all of the hematoma volumes calculated by v (formula) is close to real volumes. In summary, the present study demonstrated the better validity and accuracy of our formula in estimating subdural hematoma volumes compared with 1/2ABC, 1/3ABC and 2/3Sh formula.

Keywords: Chronic subdural hematomas, hematoma volume, computer-assisted volumetric analysis, new volume estimation method

Introduction

Chronic subdural hematoma (CSDH) is a frequently encountered curable disease in neurosurgical practice, especially in the elderly population [1, 2]. It is characterized by the persistent hematoma by encapsulation in the subdural space which could evoke an inflammatory reaction [3, 4]. Recently, the increasing incidence has underlined the need for a simple and accurate method to determinate the volume of CSDH, as it is essential for the physicians' decisions on a timely and appropriate treatment [5, 6].

Clinically, computer-assisted volumetric analysis (CAVA) has been used as the gold standard, but it is strenuous [7]. Currently, 1/2abc, the other most commonly used method for CSDH volumes, is confirmed to be a simple and effective estimation of hematoma volume [7]. However, the irregular shapes of CSDH makes its accuracy and validity for assessment

of CSDH volumes still questionable [7], as the source of the 1/2abc formula is derivative from the shape of hematoma similar to a sphere, but in fact the shape of CSDH is more close to crescent or ellipsoid [6]. Therefore, a more simple accurate approach for the calculation of CSDH volume is urgently needed. In this study, we aimed to establish and validate a new volume estimation method for CSDH based on the shape of CSDH similar to ellipsoid.

Materials and methods

Patient

A total of 46 patients (mean age 46 ± 12.46) who were diagnosed with chronic subdural hematoma in the Department of Neurosurgery of our hospital from July, 2012 to March, 2015 were included in this study. The computed tomography (CT) scans data of these patients was collected.

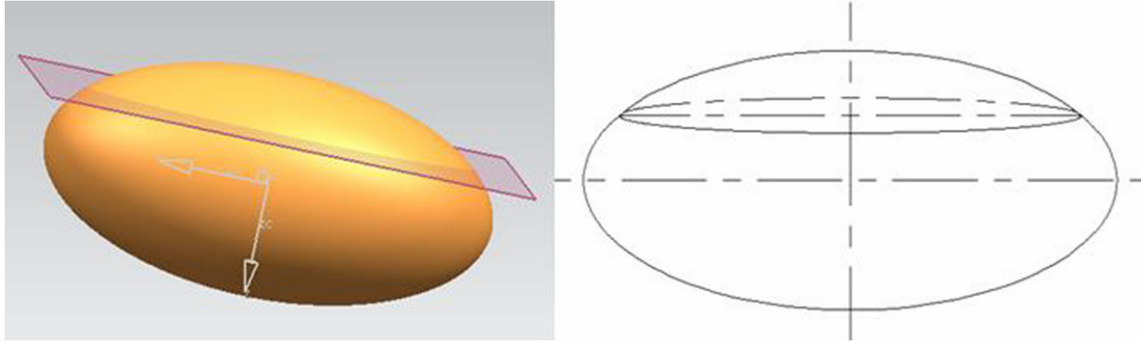


Figure 1. The ellipsoid was being cut in a plane perpendicular to the major axis, with the intercepted part to be the ellipsoid missing.

The formula derivation of ellipsoid missing volume

With a plane to cut a section of ellipsoid and the part of the proceeds of the so-called ellipsoid missing, outer and inner circles are respectively the margins of two ellipsoid missing. Hence, the volume of crescent-shape is equal to the subtractive volume of two ellipsoids missing. The volume of fusiformate is equal to the sum of two ellipsoids missing volume. Here it is the focus on solving the volume of ellipsoid missing: Assuming arbitrary ellipsoid Equation is: $\frac{x^2}{a^2} + \frac{y^2}{b^2} + \frac{z^2}{c^2} \leq 1$, we take two planes on the Z axis and make them perpendicular to the Z axis, that is $z = d$ ($d \in [0, c]$) and $z = c$, and then calculate the volume of ellipsoid between that part of two planes.

Using slicing method, we obtain

$\iiint_D dx dy dz = \int_d^c dz \iint_{Dz} dx dy$, where Dz is the elliptical sections that parallel to the xoy plane,

$$Dz = \left\{ (x, y) \mid \frac{x^2}{a^2} + \frac{y^2}{b^2} \leq 1 - \frac{z^2}{c^2}, d \leq z \leq c \right\},$$

$$\text{that: } Dz = \left\{ (x, y) \mid \frac{x^2}{a^2 \left(1 - \frac{z^2}{c^2}\right)} + \frac{y^2}{b^2 \left(1 - \frac{z^2}{c^2}\right)} \leq 1, d \leq z \leq c \right\}$$

Its area is:

$$S = \pi a \sqrt{1 - \frac{z^2}{c^2}} b \sqrt{1 - \frac{z^2}{c^2}} = \pi ab \left(1 - \frac{z^2}{c^2}\right)$$

So the volume of ellipsoid missing is:

$$\begin{aligned} v &= \int_d^c s dz = \int_d^c \pi ab \left(1 - \frac{z^2}{c^2}\right) dz = \pi ab \int_d^c \left(1 - \frac{z^2}{c^2}\right) dz \\ &= \pi ab \left[z - \frac{z^3}{3c^2} \right] \Big|_d^c = \pi ab \left[\frac{2c}{3} - d + \frac{d^3}{3c^2} \right] \end{aligned}$$

If assuming the height of the ellipsoidal crown is h , then $d = c - h$, into the Equation above that volume of ellipsoid missing is:

$$V = \frac{\pi ab h^2}{c} \left(1 - \frac{h}{3c}\right) \tag{1}$$

The formula derivation of crescent-shaped hematoma volume

As the ellipsoid missing volume would be calculated by the formula $v = \frac{\pi ab h^2}{c} \left(1 - \frac{h}{3c}\right)$, the ellipsoid equation and the height of ellipsoid missing must be known first, hence, the following purpose is to seek the value of a , b , and c .

Any one of ellipsoid is being cut in a plane which is perpendicular to the major axis Z, as shown in **Figure 1**, leaving intercepted part to be the ellipsoid missing.

Then we intercept ellipsoid missing using equidistantly parallel planes parallel to the long axis Z, which is similar to the process of CT scans, and then get different sections of ellipsoid missing, among which there must be a maximum cross-section and sub-section of the ellipsoid missing, as shown in **Figure 2**.

Thereafter we select the maximum cross-section and separate it from the ellipsoid missing for further analysis (**Figure 3**). The maximum cross-section outer margin of the ellipsoid missing is must be an elliptic equations, by measuring then know the largest diameter and wide diameter is a_1 and b_1 , respectively.

Due to the outer margin of the maximum cross-section being elliptic equations, we set the Equation as $\frac{x^2}{b^2} + \frac{y^2}{c^2} = 1$, take $(b-b_1, \frac{a_1}{2})$ into

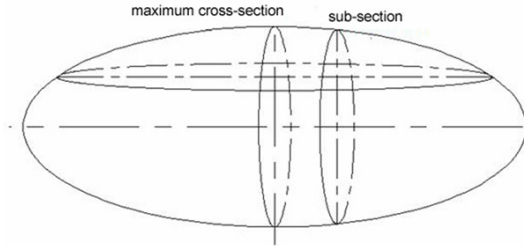


Figure 2. The ellipsoid was intercepted by equidistantly parallel planes parallel to the long axis.

the elliptic Equation $\frac{(b - b_1)^2}{b^2} + \frac{a_1^2}{4c^2} = 1$ (in the model assuming that $b = c$), and then obtain

$$b = c = \frac{4b_1^2 + a_1^2}{8b_1} \quad (2)$$

Similarly, we select the sub-maximum cross-section intercepted from ellipsoid missing, and the outer margin of this section is bound to be an ellipse and on the projection line of point A which is on the outer margin of the sub-maximum cross-section (**Figure 4**).

As shown in **Figure 5**, we take A coordinate point $(b - b_1 + b_2, k)$ into the Equation $\frac{(b - b_1 + b_2)^2}{a^2} + \frac{k^2}{b^2} = 1$, where b_1 and b_2 are the wide diameters of maximum cross-section and sub-maximum cross-section.

$$a = \frac{bk}{\sqrt{b^2 - (b - b_1 + b_2)^2}} \quad (3)$$

Simultaneous Equation 2 and 3 to obtain:

$$a = \frac{k(4b_1^2 + a_1^2)}{4\sqrt{b_1(b_1 - b_2)}(a_1^2 + 4b_1b_2)} \quad (4)$$

The formula of ellipsoid missing volume is

$$V_1 = \frac{\pi abh^2}{c} \left[1 - \frac{h}{3c} \right],$$

where a is the axis of the ellipsoid, h is the height of ellipsoid missing that is b_1 , so, $h = b_1$.

The a , b and c are substituted into the volume formula of ellipsoid missing, get the ellipsoid missing volume of the outer margin:

$$V_1 = \frac{\pi abh^2}{c} \left[1 - \frac{h}{3c} \right] = \frac{\pi kb_1^2(4b_1^2 + 3a_1^2)}{4\sqrt{b_1(b_1 - b_2)}(a_1^2 + 4b_1b_2)}$$

Similarly, the ellipsoid missing volume of inner edge is:

$$V_2 = \frac{\pi abh^2}{c} \left[1 - \frac{h}{3c} \right] = \frac{\pi kb_3^2(4b_3^2 + 3a_1^2)}{4\sqrt{b_3(b_3 - b_4)}(a_1^2 + 4b_3b_4)}$$

Crescent-shaped volume is equal to the volume subtraction between the outer margin to inner edge of ellipsoid missing volume, that is $V = V_1 - V_2$

$$V = \frac{\pi kb_1^2(4b_1^2 + 3a_1^2)}{4\sqrt{b_1(b_1 - b_2)}(a_1^2 + 4b_1b_2)} - \frac{\pi kb_3^2(4b_3^2 + 3a_1^2)}{4\sqrt{b_3(b_3 - b_4)}(a_1^2 + 4b_3b_4)} \quad (5)$$

In the above formula, a_1 is the long axis of the maximum cross-section, b_1 is the outer margin wide shaft of the maximum cross-section, b_2 is the outer margin wide shaft of the sub-section, b_3 is the inner margin wide shaft of the maximum cross-section, b_4 is the inner margin wide shaft of the sub-section, and k is thickness.

Data analysis

The cephalic hematoma imaging was performed by Japanese Toshiba aquilion 64 spiral CT with 5 mm slice thickness to determine the length and width of scheduled slice of hematoma as well as the thickness of hematoma by computer software. Subsequently, the hematoma volume was calculated by using v (formula), $v(2/3sh)$, $v(1/2abc)$ and $v(1/3abc)$, respectively. We considered CAVA as gold standard, during which the hematoma margins were hand-traced by the radiologist on each axial slice. Then the hematoma volume (cm^3) on that particular slice was calculated as the product of the area of the traced hematoma (cm^2) multiplying the corresponding slice thickness (cm). The sum of the volumes on each slice gave the total hematoma volume.

Statistical analyses

The discrepancy of all hematoma volume value and percent deviations from the gold standard were analyzed with one-way analysis of variance (ANOVA; Welch and Brown-Forsythe method), and post hoc pairwise comparisons were performed with Fisher's least significant difference (LSD) test. In addition, correlation coefficients were in turn obtained using Pearson coefficients; then, the effects of different estimated methods on hematoma volumes and percent deviations were respectively analyzed by error bars and box plots. Data were expressed as mean \pm SD, and all statistical analyses were performed using the SPSS 19.0 statistical software (SPSS Inc., IL, USA). A P -value of less than 0.05 was considered statistically significant.

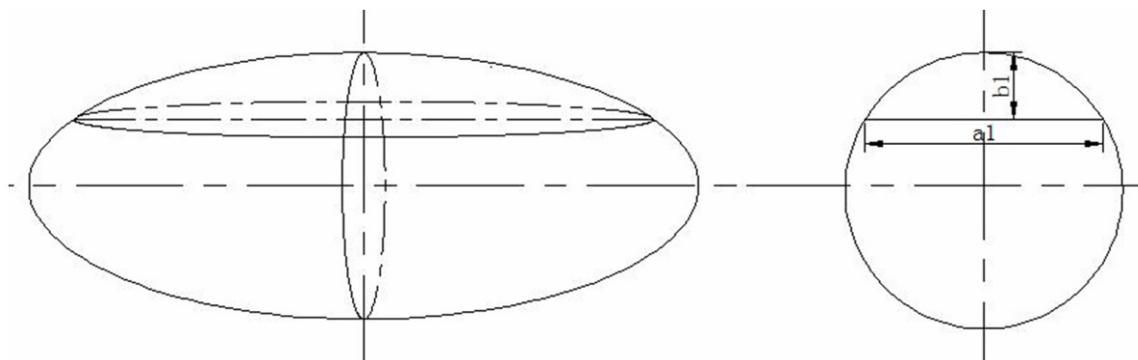


Figure 3. The maximum cross-section image from ellipsoid missing.

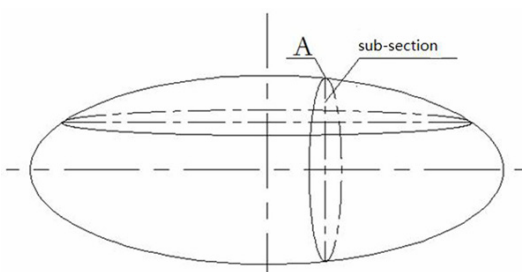


Figure 4. The sub-maximum cross-section intercepted from ellipsoid missing.

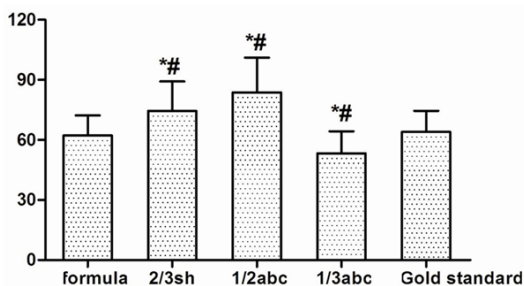


Figure 5. The mean volumes of CSDH by each method were analyzed by one-way analysis of variance. CSDH, chronic subdural hematomas; *, $P < 0.05$ vs. formula; #, $P < 0.05$ vs. Gold standard.

Results

The volumes of CSDH were calculated respectively by the following methods: 1) v (formula), 2) v ($2/3sh$), 3) v ($1/2abc$), 4) v ($1/3abc$), 5) v (Gold standard). The one-way ANOVA results indicated that there are no statistical differences between v (formula) and v (Gold standard) groups (63.42 ± 9.92 vs. 63.42 ± 9.92 , $P > 0.05$, Figure 6), whereas the hematoma volumes of v ($2/3sh$), v ($1/2abc$) and v ($1/3abc$) groups significantly differed from v (formula) or v (Gold standard) group (71.69 ± 13.58 , 81.40

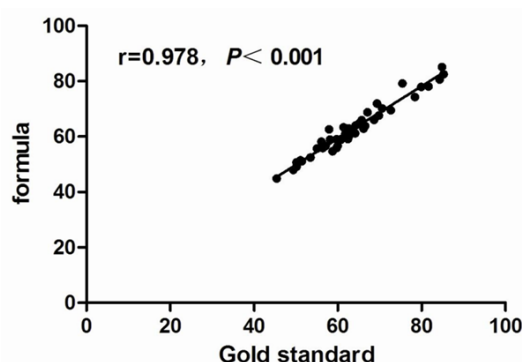


Figure 6. Scatter plot of correlations between v (formula) and v (Gold standard) groups.

± 15.59 , and 51.82 ± 9.92 , $P < 0.05$, Table 1). Besides, there was a significant correlation between v (formula) and v (Gold standard) groups using Pearson coefficient ($r = 0.978$, $P < 0.001$), suggesting that all of the hematoma volumes calculated by v (formula) was close to real volumes.

Discussion

Intracerebral hematoma volume has been validated to be an independent predictor for poor outcome and mortality by early correlative research [8-10]. Precise determination of hematoma volume is also one of the important influence factors for an appropriate treatment in clinical work [11, 12]. Thus, it is necessary for physicians to have a simple reliable method to measure the hematoma volume.

Considering the shape of subdural hematoma was closer to crescent, we found that the calculation method of ellipsoidal missing volume could assess the hematoma volume more precisely. For convenience in clinical

Table 1. Pairwise Comparisons of the mean volumes of CSDH (LSD Test)

Methods (I)	Methods (J)	Mean difference (I-J)	P-value	95% CI
v (formula)	v (2/3sh)	-9.18 ± 2.50	< 0.001	-14.10-4.27
	v (1/2abc)	-18.90 ± 2.50	< 0.001	-23.82-13.98
	v (1/3abc)	10.68 ± 2.50	< 0.001	5.76-15.60
	v (Gold standard)	-0.91 ± 2.50	0.714	-5.83-4.00
v (2/3sh)	v (1/2abc)	-9.71 ± 2.50	< 0.001	-14.63-4.80
	v (1/3abc)	19.87 ± 2.50	< 0.001	14.95-24.78
	v (Gold standard)	8.27 ± 2.50	0.001	3.35-13.19
v (1/2abc)	v (1/3abc)	29.58 ± 2.50	< 0.001	24.66-34.50
	v (Gold standard)	17.98 ± 2.50	< 0.001	13.07-22.90
v (1/3abc)	v (Gold standard)	-11.60 ± 2.50	< 0.001	-16.51-6.68

Data were expressed as mean ± SD. A P-value < 0.05 was considered statistically significant.

work, we derived the formula of crescent (

$$v = \frac{\pi k b_1^2 (4b_1^2 + 3a_1^2)}{4\sqrt{b_1(b_1 - b_2)(a_1^2 + 4b_1 b_2)}} - \frac{\pi k b_3^2 (4b_3^2 + 3a_1^2)}{4\sqrt{b_3(b_3 - b_4)(a_1^2 + 4b_3 b_4)}}$$

), the formula needs length and width of hematoma on adjacent maximum slice. We also simply made a programming to make the calculation briefer that physicians can directly obtain the result by inputting specific measured data in clinical work.

In the present study, we considered CAVA as the gold standard, and calculated the hematoma volume by using v (formula), v (2/3sh), v (1/2abc) and v (1/3abc), respectively. The results showed a similar hematoma volume between v (formula) and v (Gold standard) groups ($P > 0.05$). Besides, a further significant correlation between the two groups ($r = 0.978$, $P < 0.001$) also validated the accuracy of our formula most close to real volumes. This could be explained by the fact that estimation error was more significantly associated with hematoma shape compared with hematoma size [13].

However, the 1/2abc method (81.40 ± 15.59) overestimated the subdural hematoma volume compared with gold standard (63.42 ± 9.92), which was consistent with Huttner *et al* who had also validated that the result obtained from the 1/2abc method measuring irregular shape of hematoma volume was overestimated about 15% and 32% in comparison with actual volume [14]. Despite of its convenience, the method of 1/2abc was theoretically deduced with the assumption that hematoma

was spherical, whereas the shape of some hematoma in particular area was special for its anatomical relationship; especially the subdural hematoma was in a shape similar to comma or camber. In addition, maximum hematoma length and width have been recently confirmed to be not necessarily located on the same slice by Sucu *et al* [6]. Hence, the result obtained from the method of 1/2abc in above situation has discrepancy with actual volume. On the contrary, the method of 1/3ABC was associated with a problem that hematoma volume was underestimated in

many situations [7], as evidenced by a calculated of 51.82 ± 9.92 in comparison with gold standard (63.42 ± 9.92). Although some scholars maintain a viewpoint that the data assessed by means of 2/3sh had no significant difference with gold standard [7], this study did demonstrate an overestimated subdural hematoma volume (71.69 ± 13.58) compared with gold standard (63.42 ± 9.92).

Considering it was too intricate to use our formula for the calculation of subdural hematoma volume directly in clinical practice, it was necessary to develop a formula program so that physicians could obtain the result by only inputting relevant data to the given program. Hence, further study were needed focusing on developing and installed our program in mobile phones, computers or tablet PC etc. Therefore, the computational complexity should not be the obstacles for clinical hematoma volume estimation.

In conclusion, the present study demonstrated the better validity and accuracy of our formula in estimating subdural hematoma volumes compared with 1/2ABC, 1/3ABC and 2/3Sh formula.

Acknowledgements

This study was funded by the Heilongjiang Postdoctoral Science-Research Foundation (NO. LBH-Q12042 to Yuehua Wang).

Disclosure of conflict of interest

None.

A new evaluation method of CSDH

Address correspondence to: Dr. Huaizhang Shi, Department of Neurosurgery, First Affiliated Hospital of Harbin Medical University, No. 23 Youzheng Street, Nangang District, Harbin 15001, Heilongjiang Province, China. Tel: +86-0451-8555090; Fax: +86-0451-85555090; E-mail: huaizhang_shi321@126.com

References

- [1] Regan JM, Worley E, Shelburne C, Pullarkat R and Watson JC. Burr hole washout versus craniotomy for chronic subdural hematoma: patient outcome and cost analysis. *PLoS One* 2015; 10: e0115085.
- [2] Chan DY, Sun TF and Poon WS. Steroid for chronic subdural hematoma? A prospective phase IIB pilot randomized controlled trial on the use of dexamethasone with surgical drainage for the reduction of recurrence with reoperation. *Chinese Neurosurgical Journal* 2015; 1: 2.
- [3] Tang J, Ai J and Macdonald RL. Developing a model of chronic subdural hematoma. *Acta Neurochir Suppl* 2011; 111: 25-9.
- [4] Chon KH, Lee JM, Koh EJ and Choi HY. Independent predictors for recurrence of chronic subdural hematoma. *Acta Neurochirurgica* 2012; 154: 1541-1548.
- [5] ur Rehman R, Noman MA, Ayoob S, Mewat S and Nabi A. Optimum management of chronic subdural hematoma: evaluation of various surgical options for the treatment of chronic subdural hematoma. *Khyber Journal of Medical Sciences* 2015; 7.
- [6] Sucu HK, Gokmen M and Gelal F. The value of XYZ/2 technique compared with computer-assisted volumetric analysis to estimate the volume of chronic subdural hematoma. *Stroke* 2005; 36: 998-1000.
- [7] Zhao KJ, Liu Y, Zhang RY, Wang XQ, Gao C and Shen JK. A precise, simple, convenient and new method for estimation of intracranial hematoma volume-the formula $2/3Sh$. *Neurol Res* 2009; 31: 1031-1036.
- [8] Zurasky J, Aiyagari V, Zazulia A, Shackelford A and Diringer M. Early mortality following spontaneous intracerebral hemorrhage. *Neurology* 2005; 64: 725-727.
- [9] Lim JK, Hwang HS, Cho BM, Lee HK, Ahn SK, Oh SM and Choi SK. Multivariate analysis of risk factors of hematoma expansion in spontaneous intracerebral hemorrhage. *Surg Neurol* 2008; 69: 40-45.
- [10] Juvela S. Risk factors for impaired outcome after spontaneous intracerebral hemorrhage. *Arch Neurol* 1995; 52: 1193-1200.
- [11] Becker K, Baxter A, Cohen W, Bybee H, Tirschwell D, Newell D, Winn H and Longstreth W. Withdrawal of support in intracerebral hemorrhage may lead to self-fulfilling prophecies. *Neurology* 2001; 56: 766-772.
- [12] Broderick JP, Brott TG, Duldner JE, Tomsick T and Huster G. Volume of intracerebral hemorrhage. A powerful and easy-to-use predictor of 30-day mortality. *Stroke* 1993; 24: 987-993.
- [13] Xu X, Chen X, Zhang J, Zheng Y, Sun G, Yu X and Xu B. Comparison of the Tada Formula With Software Slicer Precise and Low-Cost Method for Volume Assessment of Intracerebral Hematoma. *Stroke* 2014; 45: 3433-3435.
- [14] Huttner HB, Steiner T, Hartmann M, Köhrmann M, Juettler E, Mueller S, Wikner J, Meyding-Lamade U, Schramm P and Schwab S. Comparison of ABC/2 estimation technique to computer-assisted planimetric analysis in warfarin-related intracerebral parenchymal hemorrhage. *Stroke* 2006; 37: 404-408.