

Original Article

Treatment of 21 pediatric children with pulmonary artery sling/tracheal stenosis: what kinds of patients can survive to discharge without tracheal intervention?

Xiaoyang Hong, Change Liu, Gengxu Zhou, Yingyue Liu, Hui Wang, Gang Wang, Xiaojuan Zhang, Haitao Gao, Zhichun Feng

Surgical Pediatric Intensive Care Unit, Affiliated Bayi Children's Hospital, PLA Army General Hospital, Southern Medical University, Beijing, China; Beijing Key Laboratory of Pediatric Organ Failure, Beijing, China

Received August 19, 2016; Accepted December 10, 2016; Epub February 15, 2017; Published February 28, 2017

Abstract: Objectives: Most pulmonary artery sling (PA sling) children receive left pulmonary artery (LPA) re-implantation and tracheoplasty simultaneously under cardiopulmonary bypass, but postoperative complications of tracheoplasty remain great challenges. This study aimed to find out what kinds of children can survive under LPA re-implantation without tracheal intervention. Methods: The data of 21 PA sling/tracheal stenosis children with mild, moderate even severe respiratory symptom receiving LPA re-implantation at first surgery in our hospital were reviewed. Complete tracheal ring was confirmed by fiberoptic bronchoscopy in all the children preoperatively. The clinical outcome and the severity of trachea stenosis (tracheal diameter and length) were evaluated, and effectiveness of various managements was analyzed. Results: 21 PA sling/tracheal stenosis children received surgical treatment including LPA re-implantation, tracheoplasty and tracheal stent. 5 children needed intubation and mechanical ventilation for severe respiratory symptoms preoperatively. All children received LPA re-implantation alone at first operation to relieve the trachea compression. For extubation failure, tracheal intervention was employed in 8 children, and 5 children received slide tracheoplasty and one discharged after recovery. The remaining 3 children received tracheal stent implantation, but finally died. The diameter and length of tracheal stenosis was significantly different between the children without tracheal intervention and children who needed tracheal intervention. The diameter of the narrowest trachea in non-tracheal intervention group was significantly wider than that in tracheal intervention group (3.18 ± 0.98 versus 2.31 ± 0.55 , $P=0.036$), and the ratio of stenosis tracheal/total tracheal length (from vocal cords to trachea carina) was statistically different (35.38 ± 14.24 versus 51.00 ± 14.14 , $P=0.024$). Conclusions: PA sling Children/tracheal stenosis undergoing LPA re-implantation without tracheal intervention achieved a good outcome. PA sling/tracheal stenosis children who have the lesser respiratory symptoms and a larger diameter of narrowest trachea, would have higher possibility for surviving to discharge by LPA re-implantation alone.

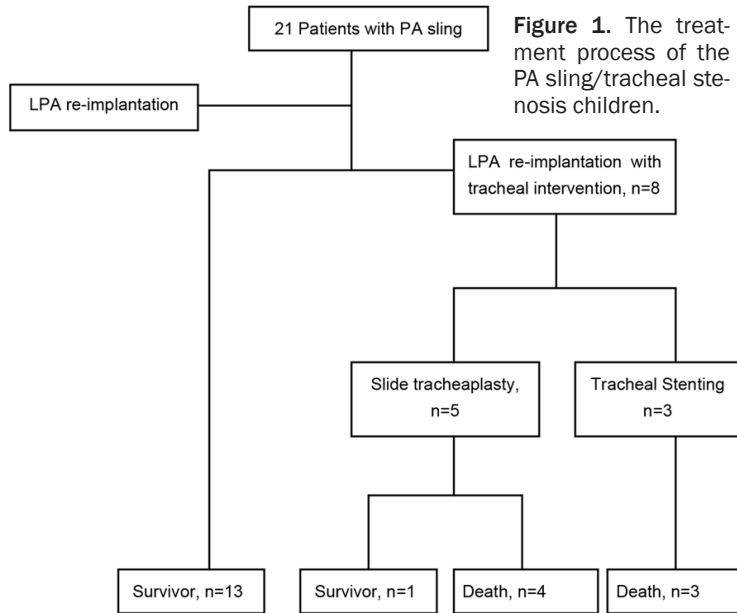
Keywords: Pulmonary artery sling, tracheal stenosis, left pulmonary artery re-implantation

Introduction

Pulmonary artery (PA) sling is a rare and congenital cardiovascular disease, and usually associated with tracheal and/or bronchial stenosis. In PA sling children, the anomalous left PA (LPA) originates from right PA, passes between trachea and esophagus, and finally arrives at the left lung. Complete tracheal rings are found in about 50%-65% of PA sling children, and also refer to as "ring-sling" complexes [1-3]. Because of the compression of anomalous LPA and tracheal stenosis, a number of children present with respiratory symptoms

after birth, such as cough, wheezing, stridor, and even severe respiratory distress resulting in sudden deaths [4, 5]. Since Potts et al [6] for the first time reported the surgery for PA sling in 1954, the prognosis of PA sling in infants has not been significantly improved. It is generally believed that PA sling children with moderate respiratory symptoms or above need surgical treatments. Several techniques have been introduced for tracheal intervention, and slide tracheoplasty may be the best one. Although slide tracheoplasty has been used in PA sling/tracheal stenosis children, tracheal complications still remain a great challenge postopera-

Treatment of pulmonary artery sling/tracheal stenosis



tively. These complications include anastomotic leakage and tracheal granulation. In this study, the outcomes of PA sling children were reviewed aiming to identify what kinds of children can survive under LPA re-implantation alone without tracheoplasty.

Patients and methods

This was a retrospective study, 21 PA sling/tracheal stenosis children who received treatments in our hospital between April 2012 and October 2015 were recruited into this study. The clinical inclusion criteria were: 1) receiving treatments in year 2012 to 2015 (including 2015), 2) complete cartilage trachea rings (O-rings) under fiber bronchoscope preoperatively 3) LPA re-implantation only at first operation. The children were divided into three types according to the clinical respiratory symptoms: mild group (minimal symptoms and a tracheal diameter of about 4-6 mm in infants), moderate group (continuous respiratory symptoms without respiratory distress) and severe group (severe respiratory symptoms with respiratory distress needing mechanical ventilation). The values of stenosis trachea/total trachea length (%) were calculated according to computed tomography (CT) scans. The diagnosis of PA sling/tracheal stenosis and other cardiac abnormalities were based on routine echocardiography and CT. All CT scans were interpreted by a same radiologist in the Department of Pediatric Radiology preoperatively, and the

diameter and length of stenosis trachea were recorded. Complete cartilage trachea rings (O-rings) were confirmed by fiber bronchoscopy in all PA sling children preoperatively.

LPA re-implantation was performed alone to relieve the trachea compression through median sternotomy at first. Cardiopulmonary bypass was employed if there were associated cardiac abnormalities that needed repair or severe hypoxemia after LPA clamping. LPA was taken out between trachea and esophagus, and implanted into the normal site of main PA in front of the trachea. Tracheal intervention included slide tracheoplasty, and tracheal stent implantation

was employed if weaning from ventilation failed after LPA re-implantation (**Figure 1**). Slide tracheoplasty was performed through median sternotomy under cardiopulmonary bypass. Trachea transaction was performed at the midpoint of stenotic segment, and the airway tract was opened in the opposite direction of both ends, followed by re-anastomosis with a “slide” method. The newly formed trachea would be half of the length, double of the diameter, and 1/32 of the resistance [7].

All the children were transferred to PICU postoperatively. Early extubation strategy was employed immediately after anesthesia recovery. The duration of ventilation and PICU stay was recorded. The primary end point was discharge or mortality in hospital.

Continuous variables were expressed as mean \pm standard deviation (SD). Independent continuous variables were compared with 2-tailed independent-samples t test. If the equal variances are not assumed, adjust t test was employed. The categorical data are given as numbers or proportions. Categorical variables were compared with Fisher's Exact Test, if the minimum expected count was < 5 . Non-normality variables were expressed as median ($P_{25} \sim P_{75}$) and compared with 2-tailed nonparametric test. All statistical calculations were performed with SPSS 21.0.

Treatment of pulmonary artery sling/tracheal stenosis

Table 1. The characteristic and comparison factors in non-tracheal and tracheal intervention groups

Characteristic and comparison factor	Non-tracheal intervention (n=13)	Tracheal intervention (n=8)	Z/t	P value
Age (m)	12.00 (6.50~29.00)	6.00 (5.00~10.25)	-1.815	0.070
Gender (Male/female)	7/6	5/3	-	1.000
Weight (kg)	10.49 ± 5.73	7.10 ± 1.64	1.999	0.064
Associated congenital heart defect (Yes/No)	5/8	1/7	-	0.336
Respiratory symptom			-2.259	0.024
Mild	2	0		
Moderate	9	3		
Severe	2	5		
Preoperative ventilation (Yes/No)	2/11	5/3	-	0.056
Stenotic tracheal diameter (mm)	3.18 ± 0.98	2.31 ± 0.55	2.261	0.036
Length of stenosis/total (%)	35.38 ± 14.24	51.00 ± 14.14	2.447	0.024
Cardiopulmonary bypass	2/11	6/2	-	0.018
Duration of ventilation postoperative (h)	1.00 (1.00~96.00)	612.00 (192.00~762.00)	-3.436	0.001
Duration of PICU (d)	2.00 (2.00~8.50)	25.50 (17.00~31.75)	-3.282	0.001
Outcomes				
Survivors/non-survivors	13/0	1/7	-	< 0.001

This study was approved by the Ethics Committee of our Hospital (2012-12-4J). Informed consent was obtained for each subject. Consent to publish has been obtained from the participant to report individual patient data.

Results

In this retrospective study, the data of 21 children with PA sling/tracheal stenosis who received treatments in our hospital were reviewed (**Table 1**). There were 12 boys and 9 girls. The ages at surgery ranged from 1 month to 10 years old. The weights ranged from 2.9 to 16 kg. Four children had concomitant other lung anomalies. Bronchus (right upper lobe bronchus direct from trachea) was found in three children and pulmonary sequestration in another patient. After LPA re-implantation, there were 13 children weaning from ventilation successfully and surviving to discharge without tracheal intervention, which were regarded as the non-tracheal intervention group. The remaining eight children needed a further tracheal intervention for failure of weaning from ventilation repeatedly, and were regarded as the tracheal intervention group. Among these eight children, tracheoplasty was performed in five children and tracheal stent implantation in three children.

Between the non-tracheal intervention group and the tracheal intervention group, there was

no significant difference in age ($P=0.070$), gender (7/6 versus 5/3, $P=1.000$), and weight (10.49 ± 5.73 versus 7.1 ± 1.64 , $P=0.064$). Associated cardiac anomalies were found in six children, five in the non-tracheal intervention group, including one aortopulmonary window, one ventricular septal defect, two atrial septal defects, and 1 patent ductus arteriosus. Another one with patent ductus arteriosus was in the tracheal intervention group. The ratio of associated congenital heart defect was similar between two groups (5/8 versus 1/7, $P=0.111$).

Before LPA re-implantation, two children presented mild respiratory symptoms, moderate symptoms in nine children, and severe symptoms in the remaining two children who needed mechanical ventilation in the non-tracheal intervention group. In another group, three children presented moderate respiratory symptoms, and the remaining five children with severe symptoms required intubation and mechanical ventilation support for respiratory failure. The respiratory symptoms were significantly severer in the tracheal intervention group than that in the non-tracheal intervention group ($P=0.024$). But the ratio of preoperative mechanical ventilation was similar between these two groups (2/11 versus 5/3 $P=0.056$).

According to CT scans, the diameter of the narrowest trachea in the non-tracheal intervention group was wider than that in the tracheal inter-

vention group, which was statistically significant (3.18 ± 0.98 versus 2.31 ± 0.55 , $P=0.036$). The ratio of stenosis tracheal/total tracheal length (from vocal cords to trachea carina) was compared between two groups. It was found that more children with long segment tracheal stenosis in the tracheal intervention group than the non-tracheal intervention group, which was statistically significant (35.38 ± 14.24 versus 51.00 ± 14.14 , $P=0.024$).

During the LPA re-implantation surgeries, two children in the non-tracheal intervention group needed cardiopulmonary bypass (CPB) for repairing heart defect simultaneously. In another group, six children needed CPB for severe hypoxemia after LPA clamping. The utilization of CPB in the tracheal intervention group was significantly higher than the non-tracheal intervention group (6/2 versus 2/11, $P=0.018$). Both durations of PICU and ventilation time post-operatively in the non-tracheal intervention group were significantly shorter than those in the tracheal intervention group (duration of PICU: $P=0.001$, ventilation time post-operative: $P=0.001$). After LPA re-implantation, 13 PA sling children survived to discharge without any more tracheal intervention. Among eight children who needed tracheal intervention after LPA re-implantation, only one children survived to discharge, and the remaining seven children died. Four died of respiratory failure finally due to tracheal anastomotic leakage and anastomotic granulation tissues after tracheoplasty; three children died of respiratory failure after stent implantation (**Figure 1**).

Discussion

21 LPA sling/tracheal stenosis children who received LPA re-implantation were included in this study. 13 children survived to discharge, and eight children needed tracheal intervention due to failure of weaning from mechanical ventilation after LPA re-implantation. Among these children who needed tracheal intervention, seven died of respiratory failure due to tracheal complications. The children in the non-tracheal intervention group showed significantly wider diameter and short segment of the stenosis trachea, and presented with milder respiratory symptoms than those in the tracheal intervention group. After LPA re-implantation, if the children failed to wean from ventilation and needed tracheal intervention, the mortality was sig-

nificantly higher than the children who didn't need tracheal intervention.

PA sling is a rare and congenital cardiovascular disease in children, and often associated with tracheal stenosis and complete tracheal cartilage ring [4, 8]. A large survey in school-aged children in Taiwan [9] showed that the natural incidence of PA sling was about 59 per million in school-aged children. PA sling children can survive to schoolage without any clinical symptoms even in the presence of complete tracheal cartilage ring. According to clinical respiratory symptoms and CT scans, Anton-Pacheco et al [10] found that PA sling could be divided into three types: mild type (minimal symptoms and a tracheal diameter of about 4-6 mm in infants), moderate type (continuous respiratory symptoms without respiratory distress) and severe type (severe respiratory symptoms with respiratory distress needing mechanical ventilation). PA sling children with mild symptoms are frequently treated with conservative strategies in most medical centers due to the concerns of risks of CPB and tracheal complications post-operatively [10-12]. In these study, there were four PA sling children with mild symptoms receiving LPA re-implantation alone for complete cartilage trachea rings and received surgical treatments. Backer et al suggested that if PA sling children exhibited complete tracheal rings, tracheoplasty was required [13]. If PA sling/tracheal stenosis children have associated moderate and above clinical symptoms, LPA re-implantation and tracheoplasty are recommended simultaneously through median sternotomy under CPB [14-19]. Tracheoplasty can treat the tracheal stenosis and ensure adequate ventilation early postoperatively. After slide tracheoplasty was used to treat tracheal stenosis, the clinical outcomes of PA sling/tracheal stenosis children have been remarkably improved in recent decades [11, 18, 20], but the postoperative complications of tracheoplasty remained a great challenge, such as anastomosis leakage, granulation tissue formation and tracheobronchomalacia. Neither tracheal stent implantation nor surgical treatment is an effective measure for the treatment of these tracheal complications [21-23]. Until December 2015, a total of five PA sling children received slide tracheoplasty after LPA re-implantation in our hospital and only one survived to discharge. Two children died of respiratory failure due to granulation tissue growing at the tracheal anas-

tomosis site, although tracheal balloon dilation was employed. Two children died of leakage at the tracheal anastomosis site after tracheoplasty. Three children received tracheal stent implantation after LPA re-implantation, and all of them died of respiratory failure. Tracheal stent implantation was also not an ideal treatment even after LPA re-implantation for PA sling. Tracheal intervention of PA sling showed poor outcomes, which was tried to avoid.

Which kinds of PA sling patients can possibly survive to discharge only by LPA re-implantation without tracheal intervention? The characteristics and comparison factors in the non-tracheal and tracheal intervention groups were reviewed and analyzed. They were similar in age, gender, and body weight. Although more children had congenital heart defects in the non-tracheal intervention group, which needed CPB for repairing heart defects and made LPA re-implantation difficult, but they didn't lead to tracheal intervention.

There was significant difference in clinical factors between the non-tracheal intervention and tracheal intervention groups preoperatively. The children in tracheal intervention group showed severer respiratory symptoms. According to CT findings, significant difference was noted in the diameter of the narrowest trachea and length of stenosis/total (%) between these two groups. The children in non-tracheal intervention group have wider diameter of the trachea and shorter segment of tracheal stenosis. Thus, respiratory symptoms, diameter and segment of trachea stenosis can be reliable indicators for avoiding tracheal intervention and predicted a good outcome in PA sling children. Huang et al also proposed that if PA sling children had a diameter of the trachea < 3 mm, tracheoplasty and LPA re-implantation were needed [24].

Early extubation and non-invasive continuous positive airway pressure were employed in PICU after LPA re-implantation. Even with re-intubation after surgeries, early re-extubation should be tried again. CPB should be avoided as far as possible during LPA re-implantation, which can reduce the tracheal secretions and make postoperative extubation easier. More children in the tracheal intervention group needed CPB during LPA re-implantation due to hypoxemia after LPA clamping, which was

closely related to severe clinical respiratory symptoms and bad situation of trachea.

In this study, 13 PA sling children surviving to discharge did show improved symptoms, even with complete tracheal rings and without any tracheal intervention. No LPA obstruction was observed in any PA children postoperatively. This situation in this article was consistent with some other literature studies [25, 26]. Therefore, it is speculate that the PA sling/tracheal stenosis children who have milder respiratory symptoms, wider diameter and shorter segment of stenosis trachea, would have higher possibilities to survive by LPA re-implantation alone.

Because PA sling is a rare and congenital vascular disease, so only 21 PA sling/tracheal stenosis children were included in this study. The longest follow-up period of survivors receiving LPA re-implantation alone was three years, and thus the long-term outcomes of these children remain unknown.

Conclusions

PA sling/tracheal stenosis children undergoing LPA re-implantation without tracheal intervention achieved a good outcome. PA sling/tracheal stenosis children, who have milder respiratory symptoms and larger diameter of narrowest trachea, would have higher possibility for surviving to discharge by LPA re-implantation alone.

Disclosure of conflict of interest

None.

Address correspondence to: Zhichun Feng, Surgical Pediatric Intensive Care Unit, Affiliated Bayi Children's Hospital, PLA Army General Hospital, Southern Medical University, Beijing, China; Beijing Key Laboratory of Pediatric Organ Failure, Beijing, China. Tel: +861066721190; Fax: +861066721190; E-mail: drfengzc@fmmu.edu.cn

References

- [1] Berdon WE, Baker DH, Wung JT, Chrispin A, Kozlowski K, de Silva M, Bales P and Alford B. Complete cartilage-ring tracheal stenosis associated with anomalous left pulmonary artery: the ring-sling complex. *Radiology* 1984; 152: 57-64.

Treatment of pulmonary artery sling/tracheal stenosis

- [2] Cohen SR and Landing BH. Tracheostenosis and bronchial abnormalities associated with pulmonary artery sling. *Ann Otol Rhinol Laryngol* 1976; 85: 582-590.
- [3] Backer CL, Monge MC, Popescu AR, Eltayeb OM, Rastatter JC and Rigsby CK. Vascular rings. *Semin Pediatr Surg* 2016; 25: 165-175.
- [4] Sade RM, Rosenthal A, Fellows K and Castaneda AR. Pulmonary artery sling. *J Thorac Cardiovasc Surg* 1975; 69: 333-346.
- [5] Hewitt RJ, Butler CR, Maughan EF and Elliott MJ. Congenital tracheobronchial stenosis. *Semin Pediatr Surg* 2016; 25: 144-149.
- [6] Potts WJ, Holinger PH and Rosenblum AH. Anomalous left pulmonary artery causing obstruction to right main bronchus: report of a case. *J Am Med Assoc* 1954; 155: 1409-1411.
- [7] Tsang V, Murday A, Gillbe C and Goldstraw P. Slide tracheoplasty for congenital funnel-shaped tracheal stenosis. *Ann Thorac Surg* 1989; 48: 632-635.
- [8] Javia L, Harris MA and Fuller S. Rings, slings, and other tracheal disorders in the neonate. *Semin Fetal Neonatal Med* 2016; 21: 277-84.
- [9] Yu JM, Liao CP, Ge S, Weng ZC, Hsiung MC, Chang JK and Chen FL. The prevalence and clinical impact of pulmonary artery sling on school-aged children: a large-scale screening study. *Pediatr Pulmonol* 2008; 43: 656-661.
- [10] Anton-Pacheco JL, Cano I, Comas J, Galletti L, Polo L, Garcia A, Lopez M and Cabezali D. Management of congenital tracheal stenosis in infancy. *Eur J Cardiothorac Surg* 2006; 29: 991-996.
- [11] van Son JA, Hambsch J, Haas GS, Schneider P and Mohr FW. Pulmonary artery sling: reimplantation versus antetracheal translocation. *Ann Thorac Surg* 1999; 68: 989-994.
- [12] Hong X, Zhou G, Liu Y, Liu Y, Wang H and Feng Z. Management of pulmonary artery sling with tracheal stenosis: LPA re-implantation without tracheoplasty. *Int J Clin Exp Med* 2015; 8: 2741-2747.
- [13] Backer CL, Russell HM, Kaushal S, Rastatter JC, Rigsby CK and Holinger LD. Pulmonary artery sling: current results with cardiopulmonary bypass. *J Thorac Cardiovasc Surg* 2012; 143: 144-151.
- [14] Yamaguchi M, Oshima Y, Hosokawa Y, Ohashi H, Tsugawa C, Nishijima E and Tsubota N. Concomitant repair of congenital tracheal stenosis and complex cardiac anomaly in small children. *J Thorac Cardiovasc Surg* 1990; 100: 181-187.
- [15] Yamaguchi M, Ohashi H, Hosokawa Y, Oshima Y, Tsugawa C and Kimura K. Surgical treatment of airway obstruction associated with congenital heart disease in infants and small children. *Eur J Cardiothorac Surg* 1991; 5: 479-485.
- [16] Oshima Y, Yamaguchi M, Ohashi H, Yoshimura N, Tanaka T, Oka S, Ogawa K, Nishijima E and Tsugawa C. [Pulmonary artery sling with tracheal stenosis—primary repair in infancy]. *Jpn J Thorac Cardiovasc Surg* 1998; 46: 347-353.
- [17] Oshima Y, Yamaguchi M, Yoshimura N, Ogawa K, Nishijima E and Tsugawa C. Primary repair of pulmonary artery sling with double outlet right ventricle and distal tracheal stenosis. *J Cardiovasc Surg (Torino)* 2002; 43: 849-851.
- [18] Backer CL, Mavroudis C, Gerber ME and Holinger LD. Tracheal surgery in children: an 18-year review of four techniques. *Eur J Cardiothorac Surg* 2001; 19: 777-784.
- [19] Kimura K, Mukohara N, Tsugawa C, Matsumoto Y, Sugimura C, Murata H and Itoh H. Tracheoplasty for congenital stenosis of the entire trachea. *J Pediatr Surg* 1982; 17: 869-871.
- [20] Loukanov T, Sebening C, Springer W, Ulmer H and Hagl S. Simultaneous management of congenital tracheal stenosis and cardiac anomalies in infants. *J Thorac Cardiovasc Surg* 2005; 130: 1537-1541.
- [21] Konstantinov IE, d'Udekem Y and Saxena P. Interposition pericardial flap after slide tracheoplasty in pulmonary artery sling complex. *Ann Thorac Surg* 2010; 89: 289-291.
- [22] Wright CD, Graham BB, Grillo HC, Wain JC and Mathisen DJ. Pediatric tracheal surgery. *Ann Thorac Surg* 2002; 74: 308-313; discussion 314.
- [23] Loeff DS, Filler RM, Vinograd I, Ein SH, Williams WG, Smith CR and Bahoric A. Congenital tracheal stenosis: a review of 22 patients from 1965 to 1987. *J Pediatr Surg* 1988; 23: 744-748.
- [24] Huang SC, Wu ET, Wang CC, Chen SJ, Chen YS, Chang CI, Chiu IS and Wang SS. Surgical management of pulmonary artery sling: trachea diameter and outcomes with or without tracheoplasty. *Pediatr Pulmonol* 2012; 47: 903-908.
- [25] Oshima Y, Yamaguchi M, Yoshimura N, Sato S, Muraji T, Nishijima E and Tsugawa C. Management of pulmonary artery sling associated with tracheal stenosis. *Ann Thorac Surg* 2008; 86: 1334-1338.
- [26] Backer CL, Mavroudis C, Dunham ME and Holinger LD. Pulmonary artery sling: results with median sternotomy, cardiopulmonary bypass, and reimplantation. *Ann Thorac Surg* 1999; 67: 1738-1744; discussion 1744-1735.