

## Case Report

# Alveolar adenoma with the round-shaped mesenchymal cells: a rare case and review of literature

Xiuming Zhang, Yanfeng Bai, Xiaoling Wang, Ke Huang

Department of Pathology, The First Affiliated Hospital, College of Medicine, Zhejiang University, Hangzhou, Zhejiang, China

Received July 30, 2016; Accepted November 22, 2016; Epub February 15, 2017; Published February 28, 2017

**Abstract:** Alveolar adenoma is a rare benign tumor of the lung and is comprised of proliferative type II alveolar epithelium and septal mesenchyma. Up to date, there have been only few reports describing this disease. These tumors are normally found very incidentally during health examination. In this study, one 40-year-old male patient was admitted to our hospital because of repeated cough and expectoration for one month. He was diagnosed with space-occupying lesion that seemed to be malignant. Later the microscopic analysis revealed an alveolar adenoma consisting of round-shaped mesenchymal cells. This patient was health after lobectomy and no recurrence was observed in the follow-up period of 26 months. To our best of knowledge, this is the first report mentioned about alveolar adenoma with round-shaped mesenchymal cells.

**Keywords:** Alveolar adenoma, round-shaped, mesenchymal cells

### Introduction

Alveolar adenomas (AAs) was first described by Yousem and Hochholzer in 1986 [1]. This disease was regarded as a rare benign peripheral lung tumor, and cases with recurrence after resection have not been reported [2-4]. AAs are normally discovered incidentally during chest X-rays exam. AAs are identified based both on macroscopic and microscopic analysis. Macroscopically, AAs are recognized as well-demarcated spongy nodules with different sizes. This tumor may grow in any lobe beneath an intact pleura [5]. Microscopically, AAs represent a distinctive histological phenotype. Tumor contains number of varied-size cystic spaces, which are lined by type II alveolar epithelial cells with cuboidal or "hob nailed" appearance. The interstitial component varies from a thin connective tissue layer resembling normal alveolar septa to markedly thickened alveolar walls with spindle mesenchymal cells [6]. Herein, we reported a rare case of AAs with distinct histological features.

### Case report

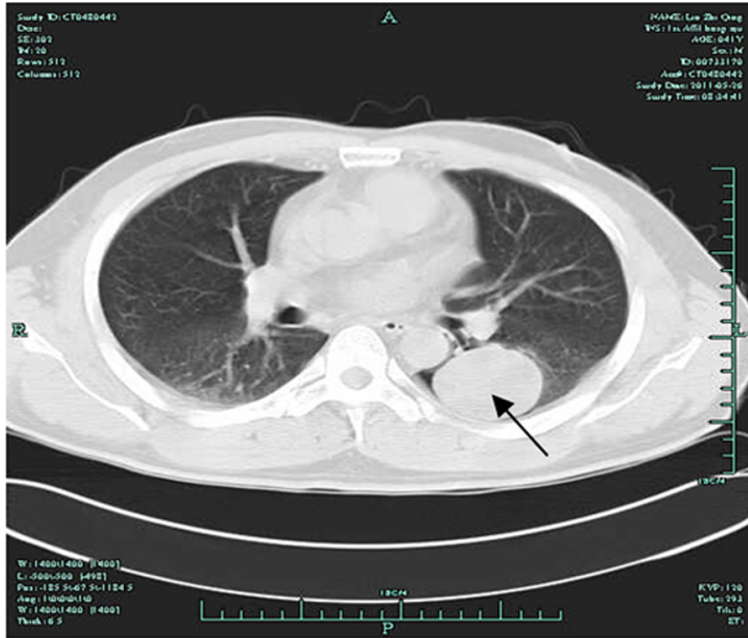
#### *Clinical history*

A 40-year-old male patient was admitted to our hospital because of repeated cough and expecto-

ration for one month. This patient had a medical history of pharyngitis for 20 years. The CT scan revealed a 5.1×4.3-cm mass in the left lower lobe with clear border and uniform density (**Figure 1**). According to the CT scan information, this lesion was considered as a benign tumor. The patient then underwent a left lower lobectomy and tolerated the procedure well without any remarkable post-operative course in the follow-up period of 26 months.

#### *Pathologic findings*

Grossly, the tumor was located in the left lower lobe and had a cystic and solid, gray cut surface and measured 5.2×4.3×4.0-cm in size. Histologically, this tumor was consisted of epithelial and interstitial cells. The epithelial cells were morphological flat, cuboidal and "hobnail" and they lined together to form gland ducts or different sizes of cysts (**Figure 2A**). The cystic spaces were filled with eosinophilic granular material and histiocytes. The interstitial cells were distributing from sparse to exuberant and showed no heterogeneity. In cystic areas, the interstitial cells were mainly spindle-shaped whereas in more solid region, they were round-shaped (**Figure 2B**). Moreover, interstitial cell morphology transition from spindle to round-



**Figure 1.** Computed tomography (CT) scan revealed a mass in the left lower lobe with clear border and uniform density (arrow indicated).

shaped could be observed in focal regions. Besides, nuclear atypia and mitosis of epithelial and stromal cells were rarely observed.

Immunohistochemical stains of tumor sections revealed positive expression of cytokeratin (CK), thyroid transcription factor-1 (TTF-1) (**Figure 3A**), epithelial membrane antigen (EMA), pulmonary surfactant-associated glycoprotein A (SPA) for the epithelial cells. Both interstitial cell types (spindle-shaped and round-shaped) were strongly positive for CD34 (**Figure 3B**) and partially positive for smooth muscle actin (SMA). In addition, the lesion was negative for P53, chromo grain in A (CgA), Syn, human coagulation factor VIII (F8) and CD31. The overall Ki-67 index was lower than 1%.

### Discussion

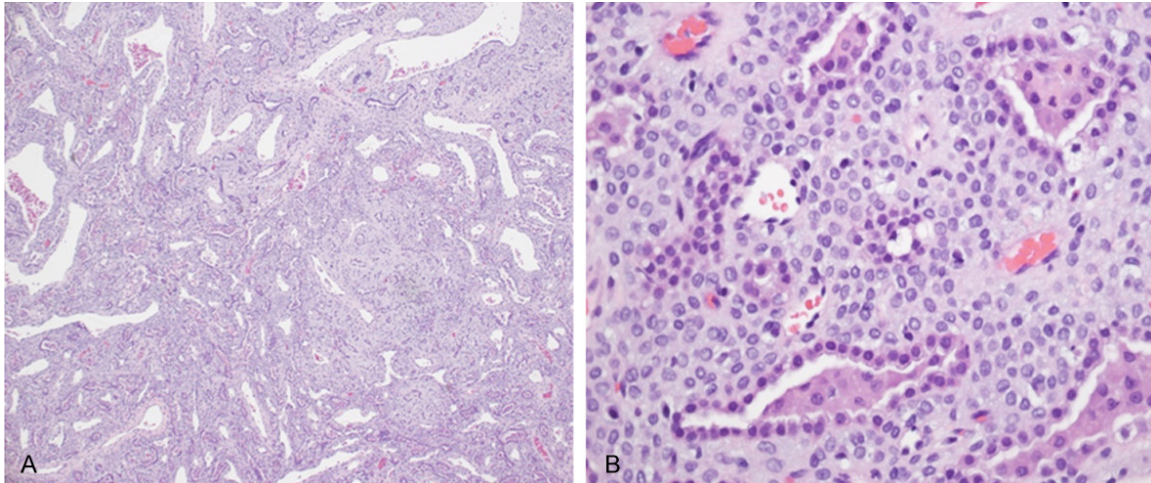
Lung alveolar adenoma is an extremely rare benign neoplasm of undefined histogenesis with unique gross and microscopic features. Up to date, a total of fewer than 40 cases have been reported in English language medical literature [7-9]. This disease is normally found incidentally in asymptomatic patients. There was only one previous report mentioned one AAs patient admitting to the hospital with severe dyspnea [10]. The age range of AAs

patients varied from 34 to 74 years and was with a slight female predominance [11].

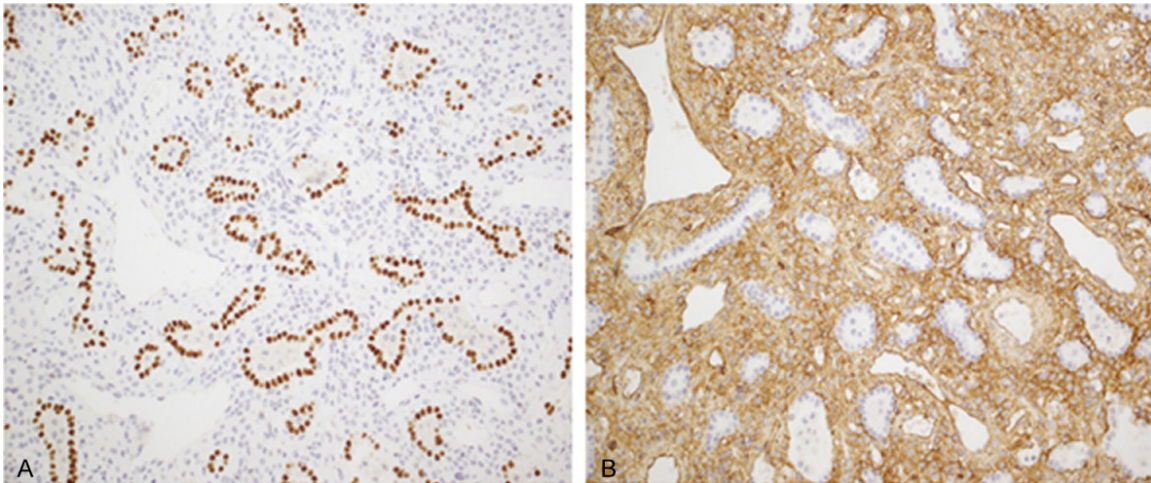
According to the literature, the interstitial cells in reported AAs were all spindle shape. While in this case, the interstitial components were mainly round-shaped cells in certain regions. The morphologic feature of the round interstitial cells was similar to the sclerosing pneumocytoma. This is the first report mentioned about AAs with round-shaped interstitial cells. Part of the tumor lesion showed the typical feature of AAs, big crypts lining by type II alveolar epithelial cells and spindle-shaped interstitial cells. Whereas in more solid area of the tumor, the crypts were getting very small and the majority of the

interstitial cells were round-shaped. Moreover, we also saw transition process from round to spindle-shaped interstitial cells in the lesion. Whether the round-shaped cell represents the early stage of spindle-shaped interstitial cell or it is a new subtype still remains unclear and needs more evidence. The differential diagnoses of AAs are including lymphangioma, atypical adenomatous hyperplasia, pulmonary papillary adenoma and sclerosing pneumocytoma. Lymphangiomas are composed of lining cells that are CK negative and endothelial marker positive. The distinct histopathologic feature of atypical adenomatous hyperplasia is focal proliferation of alveolar cells distributing along the preexisting alveolar framework, whereas AAs lack cellular atypia. Pulmonary papillary adenoma contain a prominent papillary pattern which the papillae are covered by uniform cuboidal to columnar cells and heterogeneous epithelial component, these help to make differential diagnosis. In this case, because of the overlapping of morphological characteristics with sclerosing pneumocytoma, the most difficult is to distinguish with it. Sclerosing pneumocytoma may also form cystic spaces and are consisting of round interstitial cells. The cystic spaces of sclerosing pneumocytoma mainly contain blood but not eosinophilic materials, whereas in this case we can observe

## Alveolar adenoma with the round-shaped mesenchymal cells



**Figure 2.** Histologic findings. A: The epithelial cells form gland ducts or different sizes of cysts (hematoxylin and eosin,  $\times 100$ ). B: The interstitial cells were round-shaped in more solid region (hematoxylin and eosin,  $\times 400$ ).



**Figure 3.** Immunophenotypic findings. A: The epithelial cells showed positivity for TTF-1 (immunohistochemistry  $\times 100$ ). B: The interstitial cells were strongly positive for CD34 (immunohistochemistry  $\times 100$ ).

obvious eosinophilic components. Moreover, interstitial cells of AAs are negative for TTF-1, SPA and EMA, but sclerosing pneumocytoma are positive for these markers.

The curative treatment for AAs is surgical resection [4, 8, 12-13]. AAs usually have an indolent clinical progression and are absent of recurrence or metastasis after complete resection. The above mentioned features indicate that the benign nature of AAs. In this case, in the 26 follow-up months, the health condition of the patient was good and no recurrence or metastasis was reported.

In summary, alveolar adenoma is benign neoplasms and presents distinct characteristics. Based on both histological and immunohistochemical analysis, AAs can be distinguished from other pulmonary diseases such as sclerosing pneumocytoma. Thoracoscopic lobectomy is curative for this disease. To the best of our knowledge, this is the first case report in the literature describing the rare presentation of AAs consisting of round-shaped interstitial cells.

### Disclosure of conflict of interest

None.



## Alveolar adenoma with the round-shaped mesenchymal cells

**Address correspondence to:** Ke Huang, Department of Pathology, The First Affiliated Hospital, College of Medicine, Zhejiang University, No. 79 Qingchun Road, Hangzhou 310003, Zhejiang, China. Tel: +86-13958082289; Fax: +86-571-87236768; E-mail: mandy\_wonderland@hotmail.com

### References

- [1] Yousem SA, Hochholzer L. Alveolar adenoma. *Hum Pathol* 1986; 17: 1066-71.
- [2] Burke LM, Rush WI, Khoor A, Mackay B, Oliveira P, Whitsett JA, Singh G, Turnicky R, Fleming MV, Koss MN, Travis WD. Alveolar adenoma: a histochemical, immunohistochemical, and ultrastructural analysis of 17 cases. *Hum Pathol* 1999; 30: 158-67.
- [3] Cakan A, Samancilar O, Nart D, Cagirici U. Alveolar adenoma: an unusual lung tumor. *Interact Cardiovasc Thorac Surg* 2003; 2: 345-7.
- [4] Sak SD, Koseoglu RD, Demirag F, Akbulut H, Gungor A. Alveolar adenoma of the lung: immunohistochemical and flow cytometric characteristics of two new cases and a review of the literature. *APMIS* 2007; 115: 1443-9.
- [5] Fujimoto K, Müller NL, Sadohara J, Harada H, Hayashi A, Hayabuchi N. Alveolar adenoma of the lung: computed tomography and magnetic resonance imaging findings. *J Thorac Imaging* 2002; 17: 163-6.
- [6] De Rosa N, Maiorino A, De Rosa I, Curcio C, Sellitto C, Amore D. CD34 Expression in the Stromal Cells of Alveolar Adenoma. *Case Rep Med* 2012; 2012: 913517.
- [7] Hartman MS, Epstein DM, Geyer SJ, Keenan RJ. Alveolar adenoma. *Ann Thorac Surg* 2004; 78: 1842-3.
- [8] Nakamura H, Adachi Y, Arai T, Miwa K, Haruki T, Fujioka S, Taniguchi Y. A small alveolar adenoma resected by thoracoscopic surgery. *Ann Thorac Surg* 2009; 87: 956-7.
- [9] Bhavsar T, Uppal G, Travaline JM, Gaughan C, Huang Y, Khurana JS. An unusual case of a microscopic alveolar adenoma coexisting with lung carcinoma: a case report and review of the literature. *J Med Case Rep* 2011; 5: 187.
- [10] Petrella F, Rizzo S, Pelosi G, Borri A, Galetta D, Gasparri R, Solli P, Veronesi G, Spaggiari L. Giant alveolar adenoma causing severe dyspnoea. *J Thorac Oncol* 2010; 5: 1088-90.
- [11] Wang X, Li WQ, Yan HZ, Li YM, He J, Liu HM, Yu HY. Alveolar adenoma combined with multifocal cysts: case report and literature review. *J Int Med Res* 2013; 41: 895-906.
- [12] Wang L, Wang X, Rustam A, Hu J. Alveolar adenoma resected by thoracoscopic surgery. *Ann Thorac Cardiovasc Surg* 2013; 19: 489-491.
- [13] Kondo N, Torii I, Hashimoto M, Takuwa t, Tanaka F, Tsujimura T, Hasegawa S. Alveolar adenoma of the lung: a case report. *Ann Thorac Cardiovasc Surg* 2011; 17: 71-73.