

Case Report

Primary hyperparathyroidism presenting as bilateral femoral shaft fractures with severe bone mineral loss and normocalcemia in a young adult male: a case report

Fan Tang¹, Wenli Zhang¹, Han Luo², Yanling Wang¹, Chongqi Tu¹

Departments of ¹Orthopedics, ²Thyroid & Breast Surgery, West China Hospital, Sichuan University, Chengdu, China

Received September 19, 2015; Accepted December 13, 2015; Epub February 15, 2017; Published February 28, 2017

Abstract: Primary hyperparathyroidism presenting as pathological fractures with severe bone mineral loss and normocalcemia in a young adult male is indeed rare. Furthermore, obtaining the diagnosis and achieving successful treatment for such a patient is challenging. A 25-year-old male suffered bilateral femoral shaft fractures after a low energy injury, due to severe bone mineral loss, in whom total serum calcium level was normal, was eventually diagnosed with primary hyperparathyroidism. Parathyroidectomy was performed, and hypocalcemia ensued. Ten days later, closed intramedullary nailing of both femoral shaft fractures was performed after the serum calcium level had risen to almost normal. Fracture fixation remained challenging because of poor bone quality. At two-year follow-up, his gait was normal and he was quite capable of self-care, working. In conclusion, aggressive treatment of hyperparathyroidism and stabilization of fractures are the key treatment principles of this rare clinical entity. This case report is a helpful reminder for doctors to be suspicious of bilateral femoral shaft fractures with severe bone mineral loss in young adults, and to be aware of normocalcemic primary hyperparathyroidism.

Keywords: Primary hyperparathyroidism, osteoporosis, pathological fracture, normocalcemia, case report

Introduction

Primary hyperparathyroidism (PHPT) is a clinical disorder characterized by an increased level of parathyroid hormone (PTH), which may be caused by an adenoma (solitary or multiple), idiopathic hyperplasia, or parathyroid carcinoma [1]. Current data suggests a prevalence of 1-4/1000 in the general population, most are diagnosed between 50 and 60 years of age and women are twice as likely to be affected as men [2, 3]. The disease has been reported to affect multiple systems including musculo-skeletal system, urinary system, and cardiovascular system [3]. The reported fracture rate in patients with PHPT is 15/1000 person-years compared to 8/1000 in controls [4]. In recent years, normocalcemic PHPT has gradually attracted the attention of many doctors but unanswered questions remain regarding the epidemiology and clinical impact [5]. Management of PHPT patients presenting with severe bone disease is a challenge. However,

cases series of PHPT patients mainly focus on those with old age, pathological fracture, hypercalcemia or delayed fracture union, and seldom highlight any management strategies [6-8]. Here we present a young male patient, in whom clinical suspicion of PHPT was raised by severe bone mineral loss and bilateral femoral shaft pathological fractures, combined with normocalcemia.

Case presentation

A 25-year-old male was admitted to our department with left thigh pain and inability to weight bear after a slip on a step. He described a one year history of left thigh pain for which analgesic was ineffective. Prior to this, he admitted to a history of a left ureteric calculus treated by ultrasonic lithotripsy three years ago, and easy to fatigue and generalized muscle weakness over the last year. Six months before, a low energy injury had led to a fracture of his proximal right femur, which was not investigated as

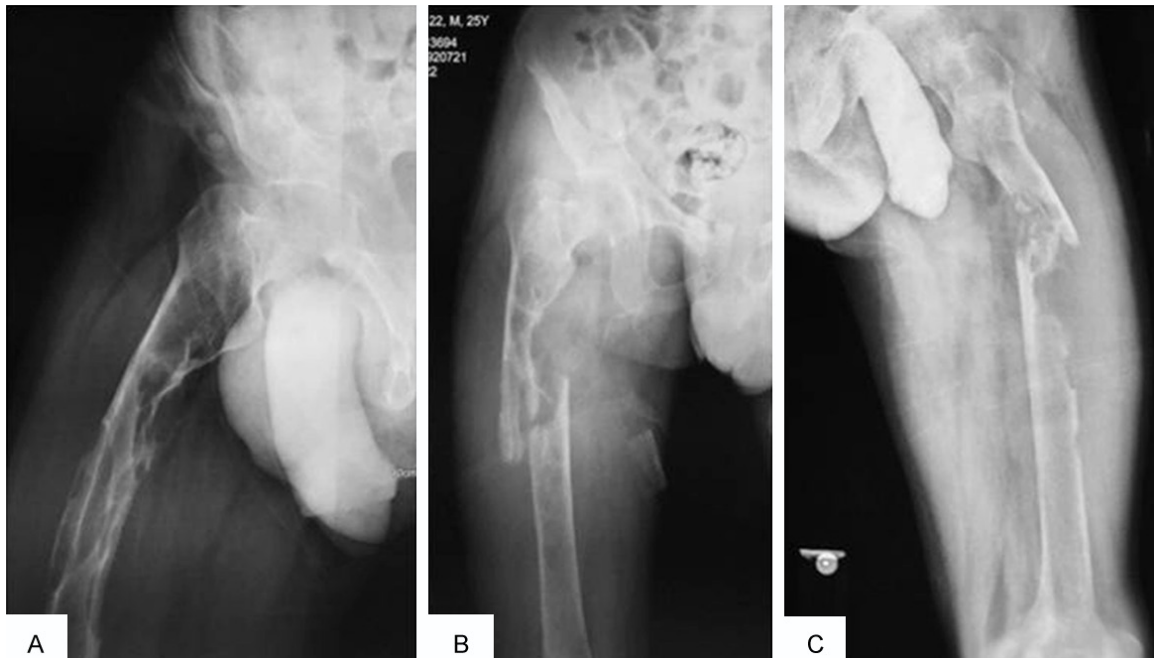

Figure 1. Preoperative radiographs showing severe bone mineral loss and fractures of both femoral shafts. A: X-ray of right femurs showing severe bone mineral loss before pathologic fracture; B: X-ray of right femur showing pathologic fracture; C: X-ray of left femur showing severe bone mineral loss and pathologic fracture.

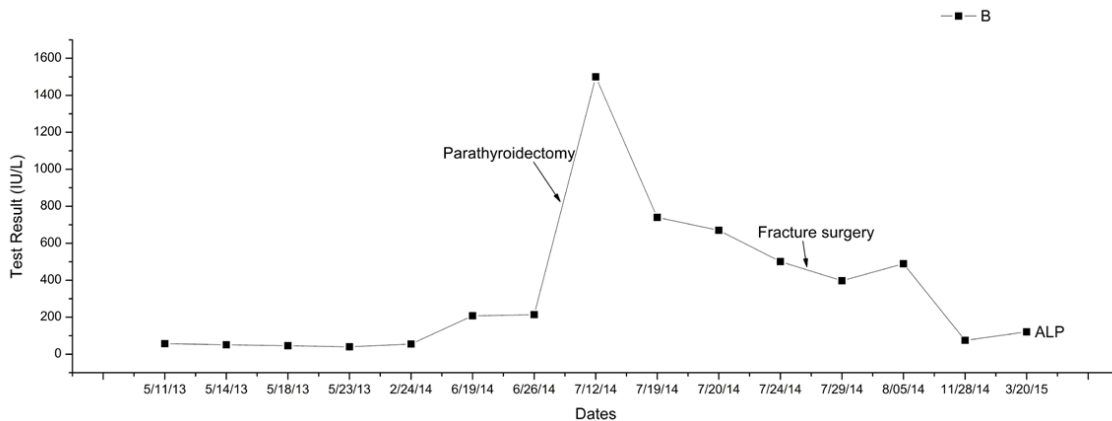


Figure 2. Pre-PTX ALP value was significantly elevated with a maximum level of 1500 (normal: 51-160) IU/L. ALP: alkaline phosphatase. PTX: parathyroidectomy.

pathological fracture and managed conservatively with a fixed orthosis in other hospital, and finally healed with malunion and hip deformity.

Physical examination revealed left thigh swelling and tenderness, while the right hip had deformity and a reduced range of movement. Additionally, a right femur fracture occurred during transport in hospital. Plain radiographs confirmed pathological fractures of both femurs with severe bilateral bone lesions (**Figure 1**). Histotal serum calcium and serum phosphate

were both normal (**Figure 2**). His serum alkaline phosphatase (ALP) was significantly raised with a maximum level during this hospital stay of 1500 (normal: 51-160) IU/L (**Figure 3**). In view of the radiological findings, this was initially felt to be a pathological fracture of metastatic origin. However, a thorough physical examination, head, chest and abdominal computed tomography failed to demonstrate any malignant cause. Similarly, protein electrophoresis, Bence-Jones protein and tumor markers including PSA, CEA, AFP, CA19-9, CA72-4 were normal. Bone scan

Primary hyperparathyroidism and severe bone disease in a young male

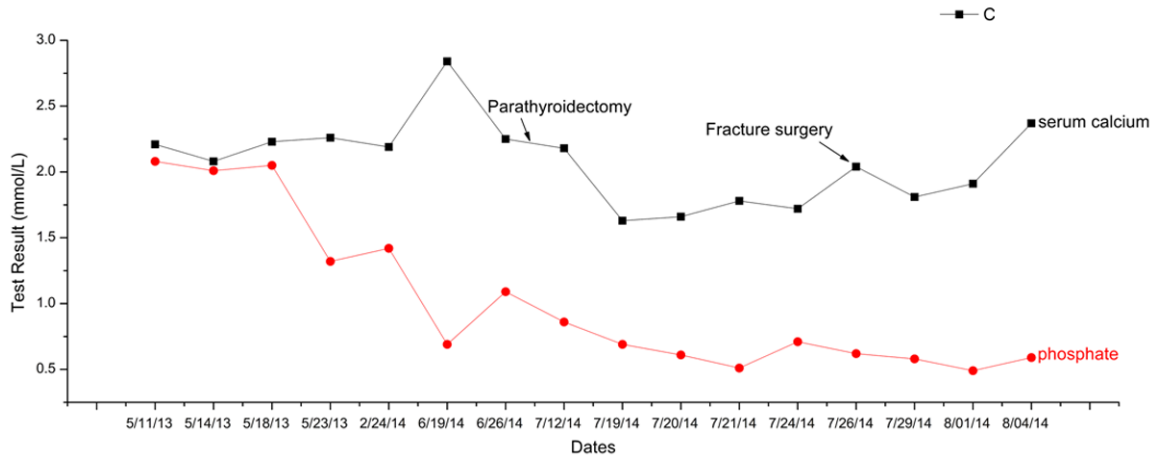


Figure 3. Pre-PTX total serum calcium level (normal: 2.15-2.60 mmol/L) and serum inorganic phosphorus level (normal: 0.8-1.45 mmol/L) were both normal. Serum calcium level decreased after PTX. PTX: parathyroidectomy.

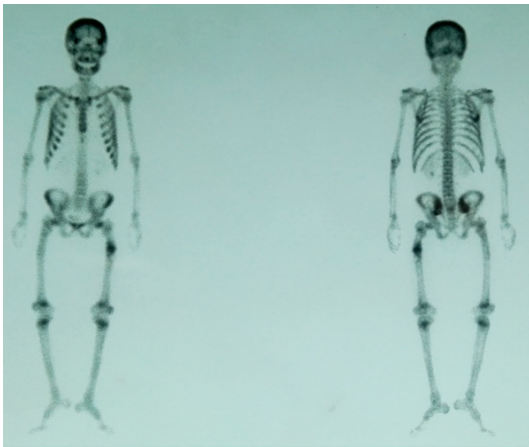


Figure 4. Bone scan suggested an area of increased uptake in his left femoral fracture site.

suggested an area of slightly increased activity in his left femoral fracture site (**Figure 4**). However, the parathyroid hormone was 101.30 pmol/L (1.60-6.90). An ultrasound of the neck, and parathyroid scintigraphy with Tc-99m sestamibi identified an adenoma in the right inferior parathyroid gland. Finally, the diagnosis of PHPT was confirmed.

Surgical management

The patient was transferred to the department of thyroid and breast surgery for further treatment of PHPT after the fracture was temporarily immobilized in our department. Then a parathyroid ectomy was performed, during which the right upper parathyroid gland was observed close to the right lobe of the thyroid gland. Thyroid nodules were present and considered

malignant, so the upper right parathyroid gland and the right lobe of the thyroid isthmus were removed with subtotal laryngectomy. Pathological examination confirmed a benign parathyroid adenoma and benign thyroid nodules. After parathyroid ectomy his total serum calcium decreased to 1.71 mmol/L (**Figure 2**), serum phosphorus decreased to 0.50 mmol/L (0.81-1.45), free triiodothyronine (FT3) decreased to 2.80 pmol/L (3.60-7.50), and the level of free thyroxine (FT4) was normal. Then oral combined with intravenous calcium supplementation was given to this patient. Euthyrox (Merck KGaA, Darmstadt, Germany) 50 µg qd was administered as thyroxine replacement. He was transferred to our department ten days after the parathyroidectomy and wished to achieve early ambulation. So once total serum calcium approached normal, closed reduction and internal fixation using the Proximal Femoral Nail Antirotation (PFNA) (Synthes (Shanghai) Medical Device Trading Co., Ltd) device in both upper femur fractures was performed in a single stage by a senior surgeon (Chongqi Tu). Fracture fixation was challenging because of poor bone quality. The surgery was performed on a traction table and the operative time was three hours. The patient recovered well and was discharged ten days after operation without postoperative complications.

Postoperative follow-up

The patient was asked to continue taking alfacalcidol (Huashan Nantong Pharmaceutical Co., Ltd. Nantong, China) 1 µg qd, caltrate (Pfizer China Health Department) 1.5 g bd and

Primary hyperparathyroidism and severe bone disease in a young male

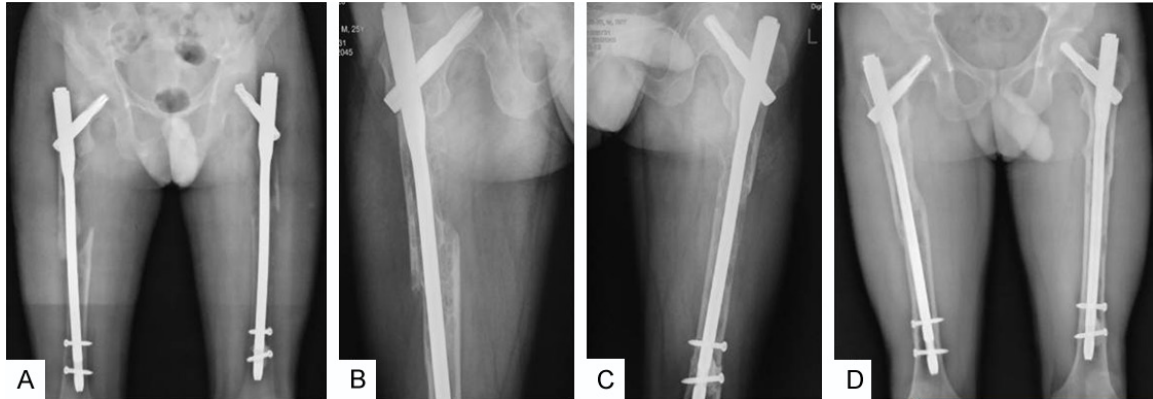


Figure 5. Postoperative radiographs of this patient. A: Three days postoperative anteroposterior and lateral radiographs of both femurs show severely decrease bone mineral; B and C: 16 weeks after orthopedic surgery, radiographs demonstrate obvious callus formation; D: One year after orthopedic surgery, good callus formation and fracture union.

euthyrox 50 µg qd. Follow-up occurred at 1, 2, 3, 6, 9, and 12 months, and every 6 months thereafter. Imaging studies were focused on evaluation of fracture healing and bone mineral density (BMD). Radiological follow-up in fracture clinic demonstrated early callus formation by four weeks. Two-month radiological follow-up in fracture clinic demonstrated callus formation and eventual radiological and clinical union by 16 weeks (**Figure 5**). One year later, radiological follow-up of the femur suggested good callus formation and fracture union (**Figure 5**). The patient was quite capable of self-care and had returned to work at two-year follow-up.

Statistical analysis

Data were analyzed with Origin 8.0 (OriginLab Co., Ltd. Massachusetts, USA). Changes of the level of total serum calcium, serum phosphorus and ALP during the course of diseases were described using descriptive statistics method. Line charts were used to present these changes.

Discussion

Unlike the western world where PHPT is often discovered during routine biochemical screening, diagnosis of PHPT is challenging in China. Many PHPT cases were admitted to an orthopedic department first with an osteolytic lesion, or an urology department due to ureteric calculus. Conventionally, an osteolytic lesion raises suspicion of tumors such as multiple myeloma, osteosarcoma, giant cell tumor, metastatic carcinoma of bone and Langerhans cell histiocytosis. However, for skeletal type PHPT, osteolytic

destruction and bone resorption, osteitis fibrosa cystica, and brown tumors are the three classic lesions. In a patient with an osteolytic lesion, hyperparathyroidism may be easily overlooked. Radiologically, subperiosteal erosions can be seen, particularly in the proximal phalanges, proximal tibia, femoral neck and sacroiliac joints or sometimes the pepper pot skull appearance in PHPT cases [9]. Some auxiliary examinations such as a bone scan, tumor markers, and magnetic resonance imaging were helpful for narrowing the differential diagnosis. In the presence of hypercalcaemia and radiographic evidence of an obvious osteolytic lesion, PHPT should be considered once more common causes such as metastatic deposits have been excluded.

In our case, the normal total serum calcium level increased the difficulty of diagnosing PHPT. The concept of normocalcemic PHPT was first introduced over 50 years ago but was considered controversial because of challenges in the measurement of PTH [10]. A diagnosis of normocalcemic PHPT can be made when PTH levels are elevated, after exclusion of secondary causes, in the presence of consistently normal serum total and ionized calcium levels. Normocalcemic PHPT has similar complications with hypercalcemic PHPT, including nephrolithiasis and osteoporosis. Additionally, TSH levels may be higher despite being within the normal range, and higher low density lipoprotein cholesterol levels are observed compared to patients with hypercalcemic PHPT [11]. Some studies indicated that normocalcemic PHPT patients with osteoporosis develop a mild

Primary hyperparathyroidism and severe bone disease in a young male

but significant BMD improvement in the spine and hip at one year, comparable with that observed in hypercalcemic PHPT, suggesting that parathyroidectomy (PTX) may be beneficial in normocalcemic PHPT [12, 13]. Another study indicated that alendronate/cholecalciferol increases BMD in postmenopausal women with normocalcemic PHPT [14]. The pre-PTX ALP value in our case was relatively high. ALP levels above the median could contribute to the therapeutic decision in normocalcemic PHPT cases. A change in bone turnover markers such as ALP is known to be associated with an improvement in BMD after PTX in classic PHPT [15]. In particular, patients from the total PHPT cohort with ALP above the median were 4.9 times more likely to have a significant BMD gain at the individual level; similarly, patients from the normocalcemic group were 8.4 times more likely to have a BMD gain when their pre-PTX ALP value was above median [13].

Bone mineral loss on plain radiographs was the main feature of our case, but BMD data was not obtained because the bone lesions of this patient were severe and obvious. Osteoporosis from PHPT affects cortical bone more than cancellous bone. Some researchers have demonstrated decreased bone mineral content or density in untreated PHPT [16]. A randomized study demonstrated an increase in spinal and femoral neck BMD in patients who had undergone PTX in contrast to those who had not [17]. However, large study groups are required to demonstrate differences in fracture rates. Serum PTH is elevated in PHPT cases. According to some recent studies, PTH promoted bone metabolism, depending on the dose and duration of administration [18-20]. Continuous low dose administration of PTH can stimulate the trabecular and cortical bone growth, and simultaneously induce bone resorption and hypercalcemia [18]. This may increase bone mineral density and reduce the risk of fragility fractures by means of a comprehensive coupling reconstruction [19]. Intermittent use of PTH or its analogs can increase bone mass and is used clinically for the treatment of osteoporosis. What's more, teriparatide (PTH [1.34]) (Lilly France) has already been approved by the Food and Drug Administration (FDA) of America for the treatment of postmenopausal osteoporosis [20].

Treatment strategies should be considered for a PHPT case with multiple pathological frac-

tures. Orthopedic surgical intervention for osseous pathology in patients with hyperparathyroidism is usually limited to the treatment of pathologic fractures [21, 22]. Overall, pathological fractures and osteolytic lesions because of PHPT can be fixed with surgical curettage, bone grafting, and prophylactic stabilization [23]. Incomplete fractures of weight-bearing bones, especially the femur and tibia, often need orthopedic fixation. Complete fractures often require surgical fixation and stabilization [24]. The case in our study was of bilateral proximal femur shaft complete fractures. So closed reduction and internal fixation with a PFNA was performed. Surgical fixation and stabilization can effectively recover the alignment of the fractures and allow the patient's early ambulation.

Some studies reported that orthopedic surgery was performed before parathyroidectomy [6, 25], and others reported simultaneous procedures [26]. In our opinion, the parathyroidectomy should be performed first and the fracture can be temporarily immobilized in traction before internal fixation, particularly for a patient with a severe bone lesion and hypercalcaemia. Hypercalcemia can influence multiple systems such as cardiovascular or urinary, with potentially life-threatening complications. Patients whose total serum calcium is more than 2.75 mmol/L may present with clinical findings, including volume contraction, muscle weakness, and altered mental status. If total serum calcium was at a high level (>3.75 mmol/L), hypercalcemic crisis may occur and threaten the patient's life [27, 28]. However, after parathyroidectomy, we should be aware of "hungry bone syndrome", and a drug to supplement calcium should be prescribed [29, 30].

Conclusion

PHPT is common in certain populations, especially in postmenopausal women, but our case is particularly rare due to the combination of characteristics including a young adult male patient, severe bone disease, normal serum calcium, and the treatment procedures required. Aggressive treatment of hyperparathyroidism and stabilization of the fractures are the key points of the treatment in this rare clinical entity. We recommend that parathyroidectomy could be performed before orthopedic surgery. Overall, we think this case report is

Primary hyperparathyroidism and severe bone disease in a young male

helpful for doctors, especially in China or other developing countries, to diagnose and treat PHPT and be aware of the diagnostic possibility in young adults, as well as normocalcemic PHPT.

Acknowledgements

We wish to acknowledge funding in support of Wenli Zhang by the Research Fund for the Doctoral Program of Higher Education of China (RFDP) (Grant number 20120181120024). Fan Tang is supported by a scholarship from the China Scholarship Council.

Disclosure of conflict of interest

None.

Address correspondence to: Chongqi Tu, Department of Orthopedics, West China Hospital, Guoxue Xiang #37, Chengdu 610041, Sichuan, China. Tel: +86-189-806-01387; Fax: +86-028-8542-3438; E-mail: tcqbonetumor@163.com

References

- [1] Apple white MK, Schneider DF. Mild primary hyperparathyroidism: a literature review. *Oncologist* 2014; 19: 919-929.
- [2] Khan AA, Bilezikian JP, Potts JT Jr. The diagnosis and management of asymptomatic primary hyperparathyroidism revisited. *J Clin Endocrinol Metab* 2009; 94: 333-334.
- [3] Callender GG, Udelsman R. Surgery for primary hyperparathyroidism. *Cancer* 2014; 120: 3602-3616.
- [4] Vestergaard P, Mollerup CL, Frøkjær VG, Christiansen P, Blichert-Toft M, Mosekilde L. Cohort study of risk of fracture before and after surgery for primary hyperparathyroidism. *BMJ* 2000; 321: 598-602.
- [5] Pawlowska M, Cusano NE. An overview of normocalcemic primary hyperparathyroidism. *Curr Opin Endocrinol Diabetes Obes* 2015; 22: 413-421.
- [6] Khaoula BA, Kaouther BA, Ines C, Sami T, Zakraoui L, Khedher A. An unusual presentation of primary hyperparathyroidism: pathological fracture. *Case Rep Orthop* 2011; 2011: 521578.
- [7] Morgan G, Ganapathi M, Afzal S, Grant AJ. Pathological fractures in primary hyperparathyroidism: a case report highlighting diagnostic difficulties. *Injury* 2002; 33: 288-291.
- [8] Sauvé PS, Suliman IG, Calder JD. Primary hyperparathyroidism presenting as delayed fracture union. *Knee Surg Sports Traumatol Arthrosc* 2009; 17: 551-554.
- [9] Vestergaard P, Mosekilde L. Fractures in patients with primary hyperparathyroidism: nationwide follow-up study of 1201 patients. *World J Surg* 2003; 27: 343-349.
- [10] Silverberg SJ, Bilezikian JP. "Incipient" primary hyperparathyroidism: a "forme fruste" of an old disease. *J Clin Endocrinol Metab* 2003; 88: 5348-5352.
- [11] Tuna MM, Çalıřkan M, Ünal M, Demirci T, Dođan BA, Küçükler K, Özbek M, Berker D, Delibaşı T, Güler S. Normocalcemic hyperparathyroidism is associated with complications similar to those of hypercalcemic hyperparathyroidism. *J Bone Miner Metab* 2016; 34: 331-335.
- [12] Koumakis E, Souberbielle JC, Sarfati E, Meunier M, Maury E, Gallimard E, Borderie D, Kahan A, Cormier C. Bone mineral density evolution after successful parathyroidectomy in patients with normocalcemic primary hyperparathyroidism. *J Clin Endocrinol Metab* 2013; 98: 3213-3220.
- [13] Koumakis E, Souberbielle JC, Payet J, Sarfati E, Borderie D, Kahan A, Cormier C. Individual site-specific bone mineral density gain in normocalcemic primary hyperparathyroidism. *Osteoporos Int* 2014; 25: 1963-1968.
- [14] Cesareo R, Di Stasio E, Vescini F, Campagna G, Cianni R, Pasqualini V, Romitelli F, Grimaldi F, Manfrini S, Palermo A. Effects of alendronate and vitamin D in patients with normocalcemic primary hyperparathyroidism. *Osteoporos Int* 2015; 26: 1295-1302.
- [15] Nakaoka D, Sugimoto T, Kobayashi T. Prediction of bone mass change after parathyroidectomy in patients with primary hyperparathyroidism. *J Clin Endocrinol Metab* 2000; 85: 1901-1907.
- [16] Wishart J, Horowitz M, Need A, Nordin BE. Relationship between forearm and vertebral mineral density in postmenopausal women with primary hyperparathyroidism. *Arch Intern Med* 1990; 150: 1329-1331.
- [17] Rao DS, Phillips ER, Divine GW, Talpos GB. Randomized controlled clinical trial of surgery versus no surgery in patients with mild asymptomatic primary hyperparathyroidism. *J Clin Endocrinol Metab* 2004; 89: 5415-5422.
- [18] Alkhiary YM, Gerstenfeld LC, Krall E, Westmore M, Sato M, Mitlak BH, Einhorn TA. Enhancement of experimental fracture healing by systemic administration of recombinant human parathyroid hormone (PTH 1-34). *J Bone Joint Surg Am* 2005; 87: 731-741.
- [19] Eriksen EF, Keaveny TM, Gallagher ER, Krege JH. Literature review: the effects of teriparatide therapy at the hip in patients with osteoporosis. *Bone* 2014; 67: 246-256.

Primary hyperparathyroidism and severe bone disease in a young male

- [20] Leder BZ, Tsai JN, Uihlein AV, Wallace PM, Lee H, Neer RM, Burnett-Bowie SA. Denosumab and teriparatide transitions in postmenopausal osteoporosis (the DATA-Switch study): extension of a randomised controlled trial. *Lancet* 2015; 386: 1147-1155.
- [21] Di Daniele N, Condò S, Ferrannini M, Bertoli M, Rovella V, Di Renzo L, De Lorenzo A. Brown tumour in a patient with secondary hyperparathyroidism resistant to medical therapy: a case report on successful treatment after subtotal parathyroidectomy. *Int J Endocrinol* 2009; 2009: 827652.
- [22] Verlaan L, van der Wal B, de Maat GJ, Walenkamp G, Nollen-Lopez L, van Ooij A. Primary hyperparathyroidism and pathological fractures: a review. *Acta Orthop Belg* 2007; 73: 300-305.
- [23] Hsieh MC, Ko JY, Eng HL. Pathologic fracture of the distal femur in osteitis fibrosa cystica simulating metastatic disease. *Arch Orthop Trauma Surg* 2004; 124: 498-501.
- [24] Khalil PN, Heining SM, Huss R, Ihrler S, Siebeck M, Hallfeldt K, Euler E, Mutschler W. Natural history and surgical treatment of brown tumor lesions at various sites in refractory primary hyperparathyroidism. *Eur J Med Res* 2007; 12: 222-230.
- [25] Alattas MH, Dimentberg R. Multiple fractures in a 22-year-old man after a simple fall. *J Surg Case Rep* 2015; 2015.
- [26] Singhal S, Johnson CA, Udelsman R. Primary hyperparathyroidism: what every orthopedic surgeon should know. *Orthopedics* 2001; 24: 1003-1009.
- [27] Nash E, Ranka P, Tarigopula G, Rashid T. Primary hyperparathyroidism in pregnancy leading to hypercalcaemic crisis and uraemic encephalopathy. *BMJ Case Rep* 2015; 2015.
- [28] Gurrado A, Piccinni G, Lissidini G, Di Fronzo P, Vittore F, Testini M. Hypercalcaemic crisis due to primary hyperparathyroidism a systematic literature review and case report. *Endokrynol Pol* 2012; 63: 494-502.
- [29] Tachibana S, Sato S, Yokoi T, Nagaishi R, Akehi Y, Yanase T, Yamashita H. Severe hypocalcemia complicated by postsurgical hypoparathyroidism and hungry bone syndrome in a patient with primary hyperparathyroidism, Graves' disease, and acromegaly. *Intern Med* 2012; 51: 1869-1873.
- [30] Corsello SM, Paragliola RM, Locantore P, Ingraudo F, Ricciato MP, Rota CA, Senes P, Pontecorvi A. Post-surgery severe hypocalcemia in primary hyperparathyroidism preoperatively treated with zoledronic acid. *Hormones (Athens)* 2010; 9: 338-342.