

Case Report

Misdiagnosed optochiasmatic cavernous angioma: a case report and literature review

Lichao Sun^{1*}, Rui Liu^{2*}, Kan Xu³, Xianfeng Zhang³, Baofeng Xu³

Departments of ¹Emergency Medicine, ³Neurosurgery, The First Hospital of Jilin University, Changchun, China; ²Department of Endocrinology, China-Japan Union Hospital of Jilin University, Changchun, China. *Co-first authors.

Received November 23, 2016; Accepted December 26, 2016; Epub February 15, 2017; Published February 28, 2017

Abstract: We present a rare case of optochiasmatic cavernous angioma (CA) misdiagnosed as teratoma prior to surgery. A 28-year-old male patient presented with progressive loss of visual acuity and headache. Neuro-ophthalmologic examination revealed left homonymous hemianopsia and decreased visual acuity (right eye 0.6, left eye 0.7). A total resection operation of the lesion was performed via the pterional approach. Pathological examination indicated optochiasmatic CA, also called hemangioma. As shown in our case, optochiasmatic CA may be misdiagnosed due to atypical imaging characteristics. Optochiasmatic CA is a benign brain tumor that may cause severe neurological deficit, such as loss of visual acuity or other cranial nerve damage. The correct diagnosis and complete surgical removal are the treatment of choice for optochiasmatic CA.

Keywords: Optochiasmatic cavernous angioma, teratoma, surgery

Introduction

A cavernous malformation (CM), also known as cavernous angioma (CA) or cavernoma, is a vascular malformation characterized by the presence of sinusoid-like capillary vessels containing blood with very sluggish circulation. It comprises berry-like collections of vascular spaces lined by thin walls devoid of smooth muscle. CAs can occur anywhere in the brain and spinal cord, but have been reported most frequently in the subcortical deep white matter of the frontal and temporal lobes [1]. Extra-axial angiomas are uncommon; the cavernous sinus is one location in which these are found. Here, we present a rare case of CA in the right suprasellar cistern, which was misdiagnosed as teratoma before surgery.

Case report

A 28-year-old male patient presented with progressive loss of visual acuity and headache for 2 months. Neuro-ophthalmologic examination revealed left homonymous hemianopsia and decreased visual acuity (right eye 0.6, left eye 0.7). T1-weighted magnetic resonance imaging

(MRI) revealed a mass with mixed signal located within optic chiasm, containing subacute hemorrhagic component (**Figure 1**). No evident edema was observed around the lesion. A gadolinium-enhanced MRI showed a non-enhancing mass in the same area. The mass was 1.8 cm × 1.7 cm × 1.7 cm, and the first diagnosis was that of a sella area teratoma. The values for pituitary-related hormones were within normal range.

An exploration and resection of the lesion was performed surgically via the pterional approach. A hematoma cavity was noted within the right ophthalmic tract and protruded about 0.5 cm. A tough lesion (1.8 cm × 1.7 cm) with a dark-red surface was encountered during the operation. Both the optic nerve and the optic tract were tightly adherent to this mass. The mass was completely removed following its separation into different parts. A fine artery branch was identified above the tumor, which may originate from the anterior cerebral artery to the anterior perforated substance. Unfortunately, the artery was removed as a result of technical complications. Pathological examination indicated optochiasmatic CA, also called hemangioma, com-

A case of optochiasmatic cavernous angioma

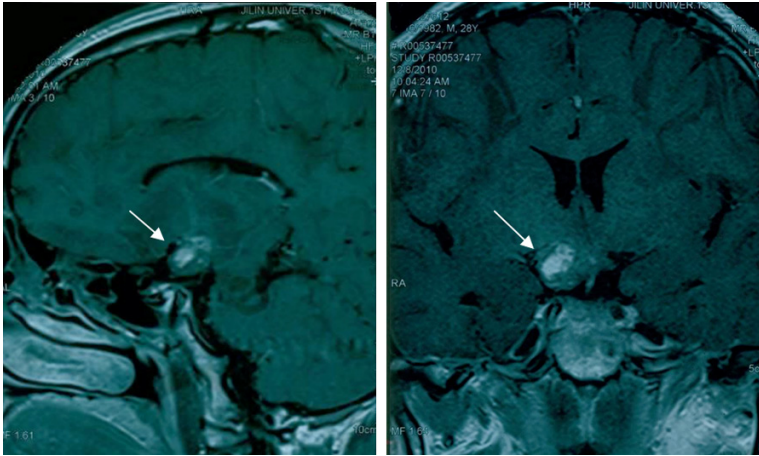


Figure 1. Sagittal and coronal T1-weighted MRI revealed a mass with mixed signal (1.8 cm × 1.7 cm × 1.7 cm) (arrows) located within optic chiasm, containing subacute hemorrhagic component. No evident edema was observed around the lesion.

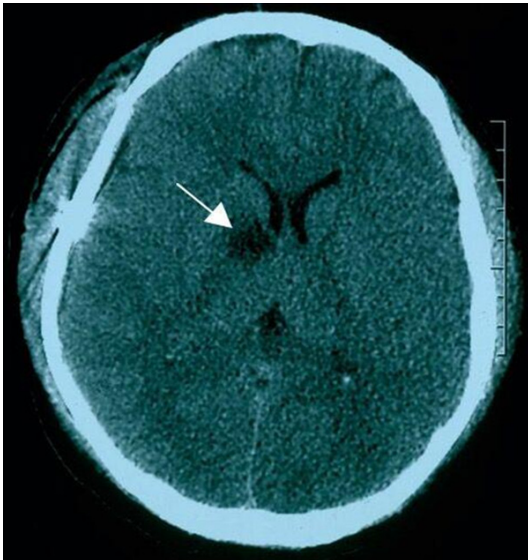


Figure 2. Non contrast axial CT scan (performed 10 days after the surgery) showed no tumor residue other than a region of low density in the right basal ganglion (arrow).

licated by previous hemorrhage and infarction within the tumor tissue.

A computed tomography (CT) brain scan performed 10 days after the surgery showed no tumor residue, other than a region of low density in the right basal ganglion (**Figure 2**). MRI brain scans (performed 12 days and 3 months following surgery) revealed postoperative infarction with hemorrhagic changes in basal ganglion caused by Heubner's artery damage intra-operatively (**Figures 3, 4**).

The patient's visual acuity was improved to near-normal 3 months following the operation, at which time no visual field loss was detected.

Discussion

CAs display characteristics similar to those of neoplasms depending on their size and location. These characteristics include mass effect, the encasement of neurovascular structures and growth during pregnancy. Extra-axial CAs are limited to the dura of the cavernous sinus, and frequently reach a giant size before diagnosis [1]. Although

the tumor is benign, CAs represent a neurological challenge due to high vascularity, their location within the cavernous sinus, and their relationship to the intracavernous internal carotid artery and cranial nerves. Infrequently, CAs can develop within the optic nerve, optic tract, or the optic chiasm [2].

In most conditions, these symptoms are caused by intra-tumor hemorrhage. Cavernous malformations (CMs) arising from the optic nerve and chiasm are extremely rare. Their characteristic clinical symptoms are associated with three main findings: sudden headache, sudden change of visual acuity, and significant visual field change [3]. The case reported here presented with a progressive change of visual acuity and sudden headache. Neuro-ophthalmologic examination revealed left homonymous hemianopsia. We postulated that these symptoms developed due to intra-tumor hemorrhage.

The characteristic findings of CAs are as follows: bone erosion on radiography and CT, homogeneous enhancement on CT, isointensity on T1-weighted MRI, and marked hyperintensity on T2-weighted MRI [4]. As the optic nerve and optic chiasm can be detected using MRI, this is the imaging modality of choice for the identification and follow-up of optochiasmatic CAs [4]. The observed focal heterogeneity occurs because of varying degrees of alteration of blood collected in the lesion at different times. Methemoglobin released following hemorrhage appears as hyperin-

A case of optochiasmatic cavernous angioma

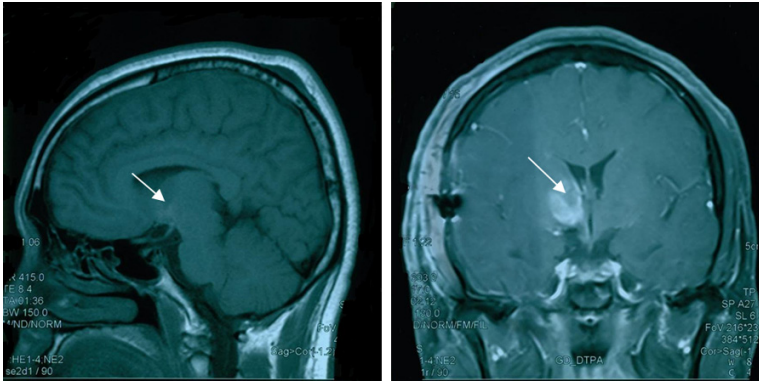


Figure 3. Sagittal and coronal T1 weighted cerebral MRI (performed 12 days after the operation) revealed a post-operative infarction with hemorrhagic changes in basal ganglia caused by Heubner's artery damage intraoperatively (arrows).

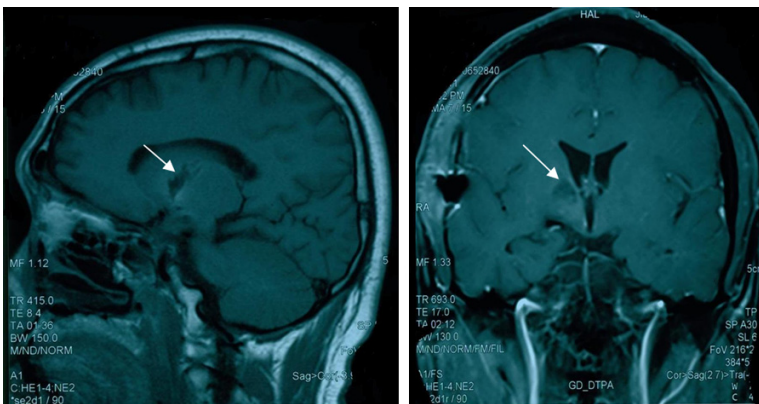


Figure 4. Repeated sagittal and coronal MRI brain scans performed 3 months after the operation showed infarction with hemorrhagic changes in the caudate head region caused by Heubner's artery damage intraoperatively (arrows).

tensity on MRI, while deposits of hemosiderin appear as hypointensity. One of the most important findings of CMs is heterogeneous intensity with marked hypointense rim in T2-weighted images, indicative of presence of different ages of hemorrhage within. Minimal, or no, enhancement is detected on MRI with Gd-DTPA.

Murai Y et al provided an important example of intraoperative indocyanine green video angiography (ICG-VAG) imaging of an unoperated CA, and suggested that the use of ICG-VAG should be evaluated for future application in differential diagnosis based on imaging findings, such as in the present case [5].

Despite advanced diagnostic tools, optochiasmatic CAs are often initially diagnosed and

treated as pituitary adenomas [6]. The differential diagnosis of an optochiasmatic CA includes arteriovenous malformation, aneurysm, optic glioma, craniopharyngioma, other neoplasms, pituitary apoplexy, and infiltrative and inflammatory conditions [7]. Our case was misdiagnosed as sella area teratoma, one kind of germ cell tumor, mostly due to the rare prevalence of CAs and the lack of knowledge concerning this disease entity.

Due to the severe symptoms caused by CAs, complete resections are conducted in most cases [1]. As for radiation therapy, a recent large study has reported good outcomes, with lower morbidity and a significant decrease in the risk of hemorrhage, following the treatment of CAs with radiosurgery [8].

For patients with optochiasmatic cavernous angioma, early surgery is recommended to avoid a permanent loss of visual acuity [7]. In our case, after reviewing the literature, we can find that our patient is a typical case of optochiasmatic CMs. The reason of misdiagnosis may be due to paying too much attention to post-contrast T1-weighted images, which preclude judgment of tumor enhancement or existence of hemorrhagic part. In contrast, T2-weighted images of the patient indicated the probability of the lesion being CM, typically heterogeneous signal intensity inside lined outside with hypointense signals. The primary concerns during surgery were to avoid re-bleeding, to achieve decompression of visual nerves, and to save visual acuity. Exploration and resection of the lesion was performed via the pterional approach. The use of a subfrontal approach has also been reported in literature [4]. In our patient, total resection of the tumor lesion was accomplished and visual acuity was greatly improved. During follow up, no recurrence was reported.

A case of optochiasmatic cavernous angioma

Disclosure of conflict of interest

None.

Address correspondence to: Baofeng Xu, Department of Neurosurgery, The First Hospital of Jilin University, Changchun, China. Tel: +86 1384485-3677; E-mail: xubf@jlu.edu.cn

References

- [1] Jo KW, Kim SD, Chung EY, Park IS. Optochiasmatic cavernous angioma with rapid progression after biopsy despite radiation therapy. *J Korean Neurosurg Soc* 2011; 49: 120-3.
- [2] Muta D, Nishi T, Koga K, Yamashiro S, Fujioka S, Kuratsu J. Cavernous malformation of the optic chiasm: case report. *Br J Neurosurg* 2006; 20: 312-5.
- [3] Lehner M, Fellner FA, Wurm G. Cavernous haemangiomas of the anterior visual pathways. Short review on occasion of an exceptional case. *Acta Neurochir* 2006; 148: 571-8.
- [4] Ozer E, Kalemci O, Yücesoy K, Canda S. Optochiasmatic cavernous angioma: unexpected diagnosis. Case report. *Neurol Med Chir (Tokyo)* 2007; 47: 128-31.
- [5] Murai Y, Adachi K, Koketsu K, Teramoto A. Indocyanine green videoangiography of optic cavernous angioma-case report. *Neurol Med Chir (Tokyo)* 2011; 51: 296-8.
- [6] Chuang CC, Jung SM, Yang JT, Chang CN, Pai PC. Intracellular cavernous hemangioma. *J Clin Neurosci* 2006; 13: 672-5.
- [7] Crocker M, Desouza R, King A, Connor S, Thomas N. Cavernous hemangioma of the optic chiasm: a surgical review. *Skull Base* 2008; 18: 201-12.
- [8] Chung H, Jin H, Dempsey JF, Liu C, Palta J, Suh TS, Kim S. Evaluation of surface and build-up region dose for intensity-modulated radiation therapy in head and neck cancer. *Med Phys* 2005; 32: 2682-9.