

Original Article

Anterior versus posterior surgery for mono-segmental thoracic spinal tuberculosis: selection of the optimal approach and comparison of outcomes

Dai Yuliang, Yawei Li, Bing Wang, Guohua Lv

Department of Spinal Surgery, The Second Xiangya Hospital, Central South University, Changsha 410011, P. R. China

Received January 6, 2017; Accepted April 20, 2017; Epub July 15, 2017; Published July 30, 2017

Abstract: Objective: To compare the clinical outcomes of anterior video-assisted thoracoscopic surgery (VATS) and the posterior-only approach for surgically treating mono-segmental thoracic spinal tuberculosis (TB) in adults. Methods: Between December 2008 and December 2010, we enrolled 52 males and 38 females. Fifty-two patients (mean age, 42.3±11.5 years; range, 22-66 years) in group A underwent anterior debridement, bone grafting, and instrumentation via the VATS approach. Thirty-eight patients (mean age, 43.8±12.0 years; range, 25-68 years) in group B underwent the posterior-only approach. Clinical and radiographic results were analyzed and compared between the two groups, with a minimum 5-year follow-up. Results: Spinal TB was completely cured and the grafted bones were fused within 9 months in all patients. A significant difference between groups was demonstrated in terms of TB lesion location. In group A, the lesion was most commonly located in the mid-thoracic vertebrae, while in group B, it was seen in the upper thoracic vertebrae. The average visual analogue scores for back pain and Japanese Orthopaedic Association and Short Form Health Survey indices were significantly improved between the two groups. The average operative time, blood loss, and hospitalization were significantly greater in group A than in group B. Kyphotic deformity was significantly corrected after surgery; however, the correction rate was higher in group B than in group A. In multivariate analysis, the two influence factors, focus location and kyphosis angle were independently associated with the selection of anterior or posterior surgery preoperatively. Conclusion: The anterior VATS approach can lead to more complete rehabilitation and reduced traumatization; however, the posterior-only approach is preferred for TB lesions located in the proximal thoracic spine, especially when combined with prominent kyphotic deformity.

Keywords: Spinal tuberculosis, video-assisted thoracoscopic surgery, kyphotic deformity, thoracic spine

Introduction

Compared with other bones and joints, the spine is the most common site of tuberculosis (TB) [1, 2] that causes gross destruction of the anterior and middle columns, leading to kyphotic deformities, neurologic deficits, and spinal cord compression. Anterior radical debridement and spinal fusion combined with anti-TB chemotherapy is usually advocated as an effective treatment for thoracic spine TB [3].

In order to reduce surgical trauma and the substantial morbidity that is associated with traditional thoracotomy techniques, video-assisted thoracoscopic surgery (VATS) has been developed for the treatment of thoracic spine TB [4,

5]. Recently, the posterior-only approach, which includes posterior debridement, interbody fusion, and instrumentation, has been reported by several surgeons, and it can be performed in patients with mono-segmental thoracic TB, with excellent outcomes [6-8]. These surgical treatments aim to control and drain the infection, relieve pain, preserve or improve neurologic function, correct kyphosis, and maintain stability with minimal immobilization.

However, the optimal surgical approach for mono-segmental thoracic spine TB is still a matter of debate. The purposes of the present study were to compare the clinical outcome of debridement and bone grafting with internal fixation via the anterior VATS with that via the

Anterior versus posterior surgery for thoracic tuberculosis

Table 1. Preoperative clinical characteristics of the two groups

	Group A (n=52)	Group B (n=38)	P-value
Gender			0.433 ^a
Male	33	21	
Female	19	17	
Age	42.3±11.5	43.8±12.0	0.572 [*]
Focus location			0.002 ^a
T1-T4	7	20	
T5-T9	35	6	
T10-T12	10	12	
Frankel scale (pre-op)			0.229 ^{**}
B	3	2	
C	14	15	
D	19	12	
E	16	9	

^aChi-squared; ^{*}Unpaired T test; ^{**}Mann-Whitney U test.

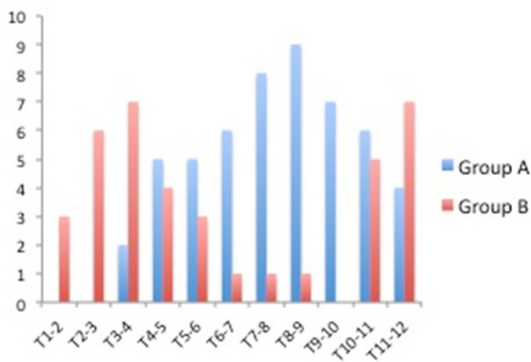


Figure 1. Diseased segments of the two groups.

posterior approach, and to assess the optimal surgical approach for thoracic spine TB in adults.

Materials and methods

Patient population

We studied 52 male and 38 female patients with single vertebra or intervertebral space (mono-segment) thoracic spine TB that was treated in our hospital between December 2008 and December 2010. Fifty-two patients with a mean age of 42.3±11.5 years (range, 22-66 years) in group A underwent anterior debridement, interbody fusion, and instrumentation via the thoracoscopy-assisted mini-open approach. Thirty-eight patients with a mean age of 43.8±12.0 years (range, 25-68 years) in

group B underwent posterior debridement, bone grafting, and instrumentation. The clinical characteristics of the patients in the two groups are listed in **Table 1** and **Figure 1**.

The diagnosis of thoracic spine TB was guided by nonspecific laboratory findings (i.e., anemia, hypoproteinemia, and elevated erythrocyte sedimentation rate [ESR]) and imaging (i.e., spinal radiographic films, computed tomography [CT], and magnetic resonance imaging [MRI] scans). Written informed consent was obtained from all patients, and the study protocol was approved by the Ethics Committee of the Second Xiangya Hospital.

The main indications for surgery in the two groups included the presence of neurological deficits, epidural abscesses compressing the dural sac, large paravertebral abscesses, and spinal deformities [9]. All patients were examined clinically and radiologically preoperatively, postoperatively, and at the final follow-up. X-ray, blood test, ESR, and hepatic function were examined. Clinical outcomes were assessed using the Visual Analogue Scale (VAS), Japanese Orthopaedic Association (JOA) scores, and Short Form (SF)-36; and changes in the degree of kyphotic deformity were recorded. Bone graft fusion was assessed using the radiologic criteria of Bridwell et al [10]. The Frankel scoring system was used to assess the neurological deficits [11].

Preoperative preparation

All patients were clinically diagnosed with TB in the thoracic spine without active pulmonary disease. Patients received the HREZ chemotherapy regimen of isoniazid (300 mg/d), rifampicin (450 mg/d), ethambutol (750 mg/d), and pyrazinamide (1500 mg/d) preoperatively for at least 2 weeks. When the patient's ESR and temperature returned to normal or significantly decreased, and anemia and hypoproteinemia were corrected, surgery was performed.

Surgical technique

In patients in group A, general anesthesia was administered with double-lumen intubation and maintained with single-lung ventilation. The patients were placed in the lateral decubitus position. An initial 10 mm port for the thoracoscope was made in the appropriate intercostal

Anterior versus posterior surgery for thoracic tuberculosis

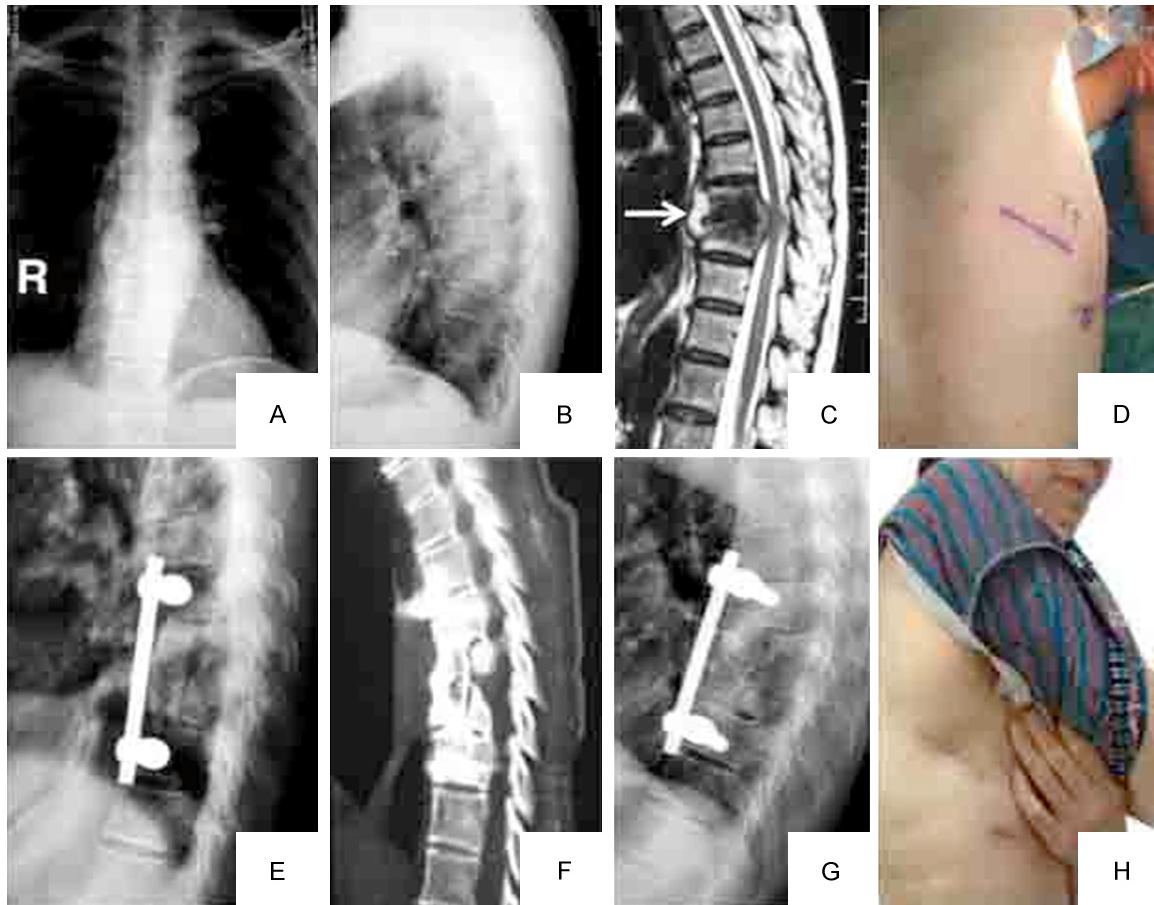


Figure 2. A 53-year-old female with T8-9 tuberculosis underwent thoracoscopic-assisted anterior debridement, iliac bone autograft, and fixation. A, B: Anteroposterior (AP) X-ray shows a paraspinous shadow, and a lateral plain radiograph demonstrates a narrowed disc space at T8-9 and a kyphotic angle of 31.4° ; C: MRI demonstrates vertebral destruction and paravertebral and epidural abscess with compression of the spinal cord (white arrow); D: A 3-4 cm skin incision was made above the target vertebrae, and the patient is in the lateral decubitus position; E: Postoperative lateral plain lateral radiograph shows that there is a normal sagittal alignment of the thoracic spine, and the kyphosis angle measures 15.5° ; F: Computed tomography (CT) scan of the sagittal plane demonstrates a solid fusion at 6-month follow-up; G: Postoperative plain lateral radiograph at final follow-up shows that there was no fixation failure and obvious correction loss. H: Postoperative clinical photograph demonstrates the size of the skin incision.

space near the anterior axillary line. Under thoracoscopic visualization, the levels of diseased vertebrae were identified by inserting needles as markers for lateral fluoroscopy. A 3-4 cm skin incision was made above the target vertebrae to provide a working channel. Thorough debridement was performed to remove necrotic discs, sequestra, infected granulation tissue, and caseous material. Anterior interbody fusion with allogeneic bone and internal fixation were applied via extended manipulating channels (**Figure 2**). A chest tube was placed prior to wound closure.

Patients in group B were placed in the prone position, and general anesthesia was adminis-

tered. Through a posterior midline approach, pedicle screws were inserted into the first two normal vertebral bodies around the lesion. A temporary rod on the mild side of the lesion was stabilized to avoid spinal cord injury induced by instability of the spine during decompression and focal debridement. An extra pleural approach was used to decompress the spinal cord. The TB lesion, including the paravertebrae, collapsed vertebrae, and intervertebral discs, was thoroughly debrided through to healthy bleeding bone. After decompression was completed, an allograft was used for stabilization (**Figure 3**). Finally, standard posterior fusion was performed at all instrumented levels.

Anterior versus posterior surgery for thoracic tuberculosis

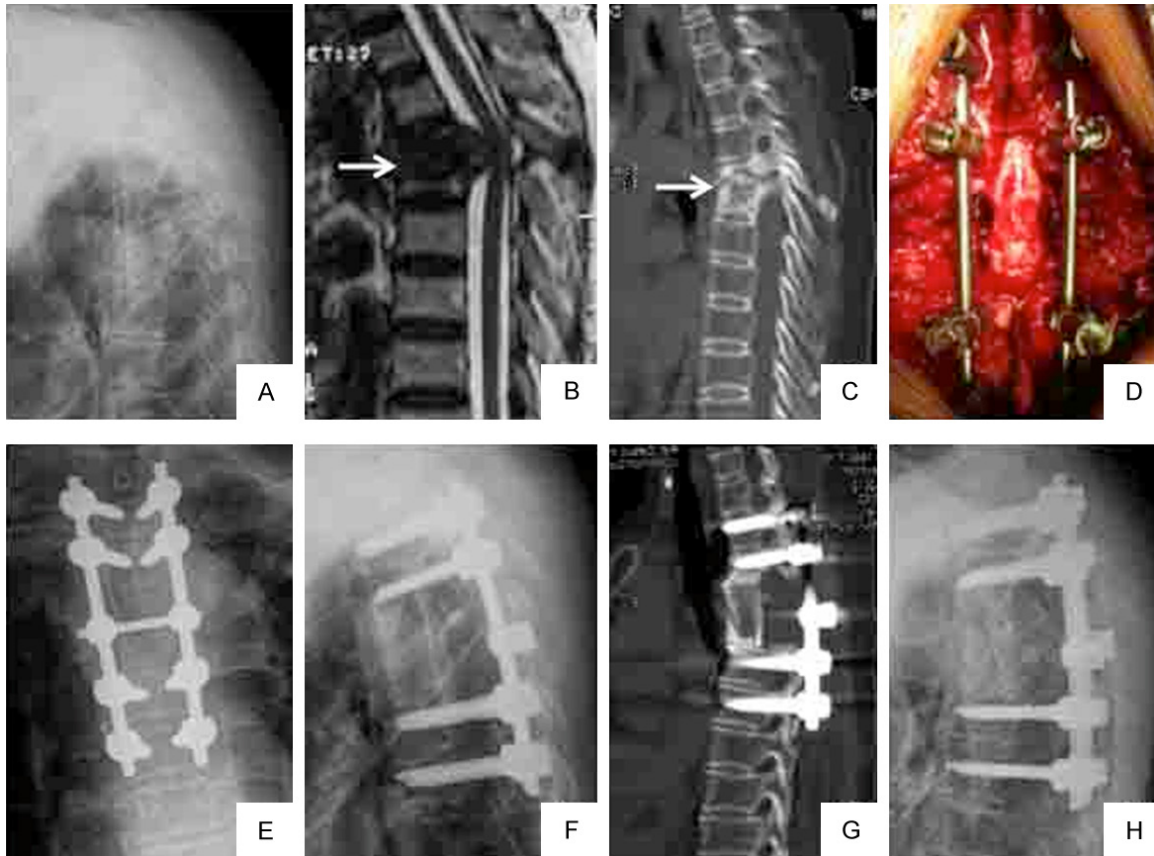


Figure 3. A 45-year-old female with T4 tuberculosis underwent posterior debridement, iliac bone autograft, and medical screw fixation. A: Lateral plain radiograph demonstrated a tuberculous focus at T4 and a kyphotic angle of 42.6°; B, C: Magnetic resonance imaging (MRI) and computed tomography (CT) scan demonstrate vertebral destruction and paravertebral and epidural abscess with compression of the spinal cord (white arrow); D: Intraoperative photograph demonstrates the TB focus was thoroughly debrided via a posterior-only approach. E: Postoperative AP X-ray show that one-stage posterior debridement graft fusion and pedicle screw fixation was performed; F: Lateral plain radiograph show that the postoperative kyphotic angle restored to 18.2°; G: CT scan of the sagittal plane demonstrated solid fusion at 8-month follow-up; H: Postoperative plain lateral radiograph of final follow-up shows that there is no fixation failure and obvious correction loss.

Postoperative care

Resected specimens were used for bacterial culture and pathological diagnosis in both groups. All patients resumed the oral HREZ chemotherapy. Six months later, pyrazinamide was discontinued. Patients received 6-12-month regimens of the HRE chemotherapy (6 HREZ/6-12 HRE). Ambulation in a brace was allowed at 6-8 weeks postoperatively. Radiographs were obtained at 1 week, 3 months, 6 months, 9 months, and every year postoperatively to monitor fusion of the bone graft, loss of correction, and instrumentation failure. If the fusion status could not be determined on a plain radiograph, CT scans were obtained. Routine blood tests were performed, and ESR

and C-reactive protein levels were monitored at regular intervals.

Statistical analysis

All statistical analyses were performed using SPSS, version 19.0 (SPSS Inc., Chicago, IL, USA). The chi-square test was used for nominal categorical variables, the unpaired t-tests and Mann-Whitney U tests were used to analyze the statistical significance between the groups, and paired and unpaired t-test were used to calculate the statistical significance in both groups before and after the interventions, respectively. A multivariable binary logistic regression model, was created to evaluate the influence factors for selection of anterior or

Anterior versus posterior surgery for thoracic tuberculosis

Table 2. Perioperative outcomes and postoperative clinical results

	Group A (n=52)	Group B (n=38)	P-value
Operative time (hr)	2.7±0.9	3.0±0.6	0.263**
Blood loss (ml)	580.9±163.1	960.7±295.4	<0.001**
Hospital stay (d)	13.7±2.1	15.1±2.4	0.002*
Fusion time (mo)	7.1±1.4	7.9±1.8	0.483*
Complications rate (%)	15.4	13.2	0.797 ^a
VAS preoperatively	7.6±1.8	7.8±1.6	0.531*
VAS at the final follow-up	1.6±1.0 [†]	1.9±1.2 [†]	0.505**
JOA preoperatively	11.3±1.1	10.6±1.1	0.422*
JOA at the final follow-up	15.6±2.0 [†]	14.9±3.3 [†]	0.682*
SF-36 PCS preoperatively	34.7±7.2	33.4±6.8	0.336*
SF-36 PCS at the final follow-up	46.2±8.5 [†]	45.8±9.2 [†]	0.615*
SF-36 MCS preoperatively	33.8±12.6	34.4±11.9	0.875**
SF-36 MCS at the final follow-up	47.5±13.7 [†]	46.6±12.1 [†]	0.483**

VAS, Visual Analogue Scale; JOA, Japanese Orthopaedic Association; SF-36, Short-Form 36; PCS, Physical Component Score; MCS, Mental Component Score.

[†]Indicates a statistically significant intragroup difference in the preoperative and postoperative values (VAS: $t_a=26.53$, $P_a<0.001$; $t_b=17.34$, $P_b<0.001$); (JOA: $t_a=25.78$, $P_a<0.001$; $t_b=15.64$, $P_b<0.001$); (SF-36 PCS: $t_a=21.73$, $P_a<0.001$; $t_b=18.65$, $P_b<0.001$); (SF-36 MCS: $t_a=23.58$, $P_a<0.001$; $t_b=19.74$, $P_b<0.001$). ^aChi-squared; *Unpaired t-test; **Mann-Whitney U test; [†]Paired t-test.

posterior surgery. A *p*-value of <0.05 was considered to be statistically significant.

Results

Surgical outcomes

The mean operation time was 2.7±0.9 h in group A and 3.0±0.6 h in group B (*P*=0.263). The amount of blood loss during the surgery was 580.9±163.1 mL in group A and 960.7±295.4 mL in group B (*P*<0.001). The mean hospital stay was 13.7±2.1 days in group A and 15.1±2.4 days in group B (*P*=0.002) (Table 2).

Clinical outcomes

The mean follow-up was 6.2±2.4 y (range: 5.0-7.6 y). No persistence or recurrence was observed. The VAS, JOA, and SF-36 scores were assessed preoperatively, 3 months postoperatively, and at the final follow-up (Figure 4). There were significant differences between the preoperative and postoperative values in the two groups (*P*<0.001), but there were no significant differences between group A and group B at the final follow-up (*P*>0.05) (Table 2). Spinal TB was completely cured, and the grafted bones were fused within 9 months in all patients.

Neurological outcomes

The neurological status improved to normal in 68 patients postoperatively, and 21 patients partially recovered. However, one case in group A deteriorated neurologically immediately after surgery and did not recover at final follow-up. There were significant differences between the pre- and postoperative results in each group ($P_a, P_b<0.05$). The mean improvement of the Frankel grade was 1.08±0.78 in group A and 1.16±0.35 in group B, and there was no difference between the groups (*P*=0.112).

Radiological outcomes

Preoperatively and postoperatively, the kyphosis angles in the groups were not significantly different. However, there was a significant difference between the groups in the angle correction rate (*P*=0.018). During the long-term follow-up, there was a loss of 1.7±1.2° in the kyphosis angle in group A and 1.4±1.1° in group B, but this was not statistically significant (*P*=0.745). However, there were significant differences between the preoperative and postoperative kyphosis angles in both groups ($P_a, P_b<0.001$) (Table 3). All patients demonstrated solid fusion at 6-9 months follow-up.

Complications

Eight patients in group A and 5 patients in group B experienced perioperative complications, and the difference was not statistically significant (*P*=0.797) (Table 2). There were two cases of temporary intercostal neuralgia in group A and one case in group B. The pain was treated by administration of analgesics. There were two cases of superficial wound infection in group B that all healed by the second intervention. Pulmonary complications occurred mainly in group A (five cases), three cases sustained lacerations of the lung parenchyma during the operation, two cases had pulmonary atelectasis, and one case had pleural effusion. Only one case had pneumothorax in group B.

Anterior versus posterior surgery for thoracic tuberculosis

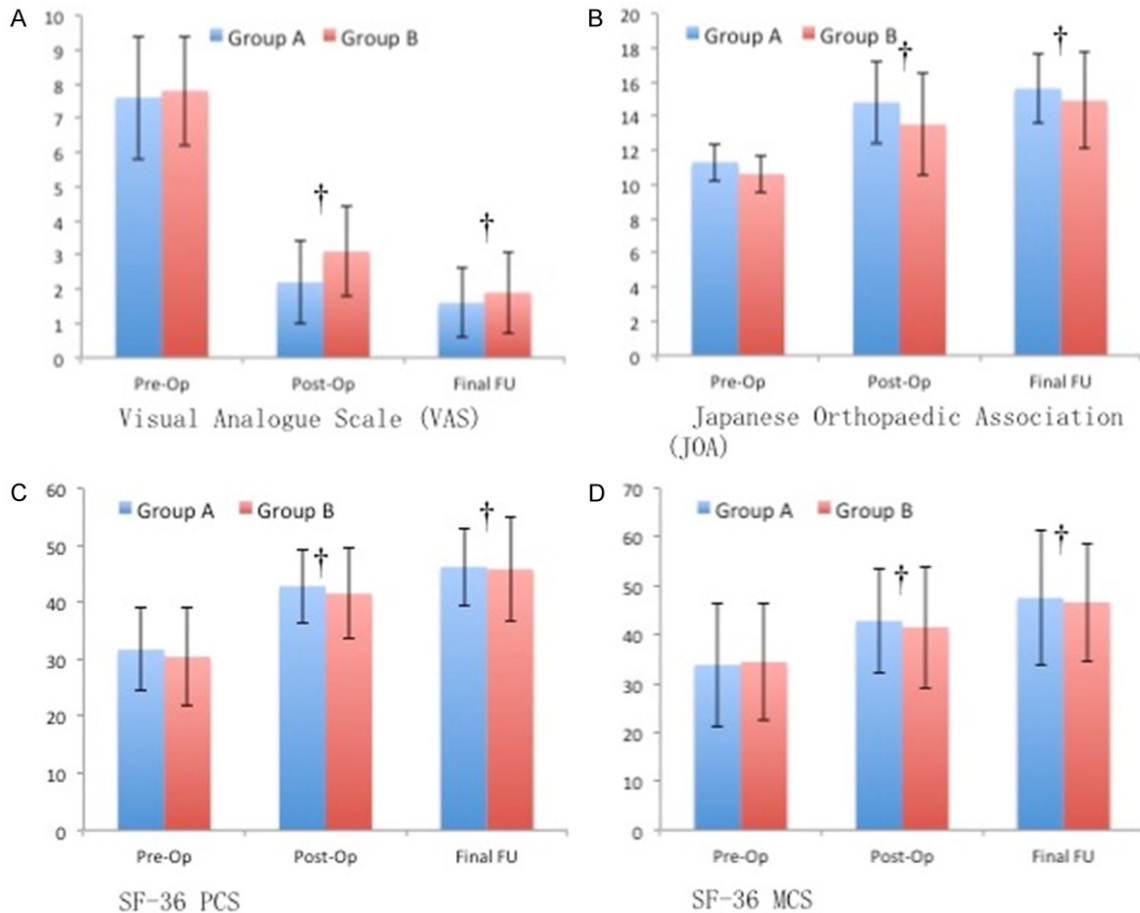


Figure 4. Patient-reported outcome measures: A: VAS, Visual Analogue Scale; B: JOA, Japanese Orthopaedic Association; C: SF-36 PCS, Physical Component Score; D: MCS, Mental Component Score. †Indicates a statistically significant intragroup difference in the preoperative and postoperative values.

These patients with pulmonary complications recovered after treatment with antibiotics, suction, or closed thoracic drainage.

Multivariate analysis

In multivariate analysis, we found only two influence factors were independently associated with for selection of anterior or posterior surgery preoperatively: focus location (odds ratio =3.719; 95% CI: 1.933-188.049; P=0.026) and kyphosis angle (odds ratio =55.86; 95% CI: 2.242-1302.162; P=0.013) (Table 4).

Discussion

In this study, we compared the clinical outcomes of debridement, bone grafting, and internal fixation via the anterior VATS technique with those via the posterior approach and assessed the optimal surgical approach for thoracic spine TB in adults. This is the first

study that we know of to compare the surgical effects and advantages of the anterior and posterior approaches. In this study, the operative time, blood loss, and hospitalization in the two groups showed a significant difference, and the VATS approach was demonstrated to be a less invasive alternative surgery for TB in the thoracic spine compared with the posterior approach. However, more pulmonary complications occurred in the VATS group, although the difference was not significant.

For active spinal TB, surgical procedures still play an important role, although anti-TB chemotherapy is proven to be effective in most cases and has become the mainstay of treatment [12, 13]. In 1960, Hodgson et al [14] first reported the Hong Kong operation to treat spinal TB. Bailey et al [15] also reported satisfactory outcomes in 100 patients who underwent anterior debridement and instrumentation. Because of

Anterior versus posterior surgery for thoracic tuberculosis

Table 3. Radiographic results of the two groups

	Group A (n=52)	Group B (n=38)	P-value
Kyphosis Angle (°)			
Pre-Op	25.4±6.5	32.8±11.9	0.112**
Post-Op	15.7±3.8	14.1±2.6	0.086*
Final follow-up	16.4±4.3†	14.8±2.9†	0.062*
Correction Rate (%)	43.5±16.4	53.0±17.1	0.018**
Correction Loss	1.7±1.2	1.4±1.1	0.745**

† indicates a statistically significant difference intragroup comparing preoperative and postoperative values ($t_a=7.326$, $P_a<0.001$; $t_b=9.275$, $P_b<0.001$). *Unpaired T test; **Mann-Whitney U test; †Paired T test.

Table 4. Multivariate analysis of influence factors for selection of anterior or posterior surgery

	Odds Ratio	95% CI	P value
Gender	10.25	0.61, 113.52	0.147
Age	1.053	0.869, 1.294	0.579
Focus location	3.719	1.933, 188.049	0.026
Frankel scale	1.354	0.129, 14.193	0.801
VAS	0.56	0.02, 12.86	0.258
Kyphosis angle	55.86	2.242, 1302.162	0.013

the advantages of debridement of the lesion and direct decompression of the spinal cord, many surgeons have advocated anterior procedures. However, this open procedure has been associated with substantial morbidity and a long recovery time [16]. Therefore, the VATS technique has been developed for surgical treatment of thoracic TB to overcome the problems associated with formal thoracotomy. Less soft tissue disruption and the safety and efficacy of thoracoscopic surgery have been shown in previous studies [5, 17]. Recently, posterior debridement and bone grafting fusion with instrumentation for treating mono-segmental spinal TB has been reported by more surgeons, and it has achieved satisfactory clinical results [4, 6, 18, 19]. In our series, the VAS, JOA, and SF-36 scores at the final follow-up were obviously improved in the two groups, and both the anterior and posterior approaches obtained satisfactory clinical outcomes. However, the optimal approach for surgical treatment of thoracic spinal TB still remains controversial. High pulmonary complication rates were reported in previous studies on anterior thoracic TB surgeries [4, 20]. The risk of injury to the pulmonary parenchyma, such as lung laceration, atelectasis, pneumonia or empyema, is also a significant concern.

In present study, we found focus location and kyphosis angle were independently associated with the surgical approaches. The posterior-only approach is preferred for TB lesions located in the proximal thoracic spine, especially when combined with prominent kyphotic deformity. Most often, spinal TB lesions that are located in the mid-or lower thoracic spine and accompanied by mild kyphosis can be relatively easy to treat via the anterior approach [4, 17]. Most of the patients in our series whose lesions were located in these regions were surgically treated using the anterior VATS approach, which provides direct visualization of the thoracic spine, including the vessels, nerves, and visceral structures. Furthermore, a direct three-dimensional view considerably facilitates the performance of corpectomy with direct spinal canal decompression, as well as bone graft or cage insertion and placement of anterior instrumentation, and can reduce operative time [21]. However, TB lesions in the upper thoracic spine, located at T1 to T4, are relatively high in position and adjacent to important intrathoracic anatomic structures. These features render thoracoscopic operations difficult, even with a formal thoracotomy, and further increase the operation's risk [22]. Unfortunately, in our study, one patient with a lesion at T3 that was treated via the anterior approach experienced permanent neurological deficit postoperatively. This may be due to an inadequate angle for maneuverability at the apex of the hypokyphosis, causing iatrogenic thoracic spinal cord injury.

Nevertheless, posterior debridement and bone graft fusion with instrumentation should be a suitable procedure for the treatment of upper thoracic spine TB. The posterior-only approach created adequate room for the surgeon to perform resection of the spinous process and unilateral facet joint resection, as well as excision of the adjacent costotransverse joint with a small fragment of the ribs, allowing for posterior decompression, debridement, and strut bone graft on the involved vertebrae under direct visualization of the spinal dura mater. However, the posterior-only approach is limited, because posterior debridement destroys the integrity of the posterior structures and may potentially spread TB, causing infection and fistulas in posterior healthy areas [23], although no persistence or recurrence was observed in our series.

Anterior versus posterior surgery for thoracic tuberculosis

In addition, anterior reconstruction of segmental stability is another issue. The most common reconstructive materials that were used for spinal fusion were autogenous ribs or the iliac crest. However, autogenous bone grafts were considered instead, since the disadvantages included limitations in the quantity of bone available, insufficient structural support, and more operating time and blood loss [10]. Therefore, we adopted fresh-frozen bicortical iliac bone allografts in both groups, and all patients attained bony fusion within 9 months after surgery.

Based on our experience, the selection of the optimal approach for spinal TB should focus on the following points. First, the anterior VATS approach can be a simple, safe practical, and minimally invasive procedure for anterior debridement and reconstruction of thoracic TB. Second, it can easily treat TB in the upper thoracic spine, in which it is difficult and dangerous to perform anterior debridement and fixation. Third, the anterior approach can be avoided in patients with extensive pleural adhesions or other pulmonary diseases, and the VATS approach can decrease pulmonary complications after surgery. Fourth, although mild kyphosis can be successfully corrected by the anterior approach alone, for moderate or severe kyphosis, the anterior approach by itself provides only limited correction. Hence, the posterior trans-pedicle screw fixation is warranted, which supplements stable posterior instrumentation.

This study is limited because it is a retrospective study; therefore, there may have been a subjective selection bias when dividing the groups, which may affect the credibility of our findings.

In conclusion, our study suggested that both approaches are effective and safe choices to treat mono-segmental TB in the thoracic spine. The VATS technique is a more minimally invasive surgical procedure for anterior debridement, bone grafting, and instrumentation, while the posterior approach might be a better surgical treatment for patients with bone destruction and prominent kyphosis.

Disclosure of conflict of interest

None.

Address correspondence to: Dr. Yawei Li, Department of Spinal Surgery, The Second Xiangya Hospital, Central South University, No.139 Renmin Road, Changsha 410011, P. R. China. Tel: +8613-487313862; Fax: +8673185295825; E-mail: liyawei1217@sina.com

References

- [1] Pigrau-Serrallach C and Rodriguez-Pardo D. Bone and joint tuberculosis. *Eur Spine J* 2013; 22 Suppl 4: 556-566.
- [2] Nagashima H, Yamane K, Nishi T, Nanjo Y and Teshima R. Recent trends in spinal infections: retrospective analysis of patients treated during the past 50 years. *Int Orthop* 2010; 34: 395-399.
- [3] Swanson AN, Pappou IP, Cammisa FP and Girardi FP. Chronic infections of the spine: surgical indications and treatments. *Clin Orthop Relat Res* 2006; 444: 100-106.
- [4] Lu G, Wang B, Li J, Liu W and Cheng I. Anterior debridement and reconstruction via thoracoscopy-assisted mini-open approach for the treatment of thoracic spinal tuberculosis: minimum 5-year follow-up. *Eur Spine J* 2012; 21: 463-469.
- [5] Garg N and Vohra R. Minimally invasive surgical approaches in the management of tuberculosis of the thoracic and lumbar spine. *Clin Orthop Relat Res* 2014; 472: 1855-1867.
- [6] Wang Z, Wu Q and Geng G. Anterior debridement and bone grafting with posterior single-segment internal fixation for the treatment of mono-segmental spinal tuberculosis. *Injury* 2013; 44: 253-257.
- [7] Deng Y, Lv G and An HS. En bloc spondylectomy for the treatment of spinal tuberculosis with fixed and sharply angulated kyphotic deformity. *Spine (Phila Pa 1976)* 2009; 34: 2140-2146.
- [8] Jain AK, Dhammi IK, Prashad B, Sinha S and Mishra P. Simultaneous anterior decompression and posterior instrumentation of the tuberculous spine using an anterolateral extra-pleural approach. *J Bone Joint Surg Br* 2008; 90: 1477-1481.
- [9] Pu X, Zhou Q, He Q, Dai F, Xu J, Zhang Z and Branko K. A posterior versus anterior surgical approach in combination with debridement, interbody autografting and instrumentation for thoracic and lumbar tuberculosis. *Int Orthop* 2012; 36: 307-313.
- [10] Bridwell KH, Lenke LG, McEneaney KW, Baldus C and Blanke K. Anterior fresh frozen structural allografts in the thoracic and lumbar spine. Do they work if combined with posterior fusion and instrumentation in adult patients with kyphosis or anterior column defects? *Spine (Phila Pa 1976)* 1995; 20: 1410-1418.

Anterior versus posterior surgery for thoracic tuberculosis

- [11] Davis LA, Warren SA, Reid DC, Oberle K, Saboe LA and Grace MG. Incomplete neural deficits in thoracolumbar and lumbar spine fractures. Reliability of Frankel and Sunnybrook scales. *Spine (Phila Pa 1976)* 1993; 18: 257-263.
- [12] Liu J, Wan L, Long X, Huang S, Dai M and Liu Z. Efficacy and safety of posterior versus combined posterior and anterior approach for the treatment of spinal tuberculosis: a meta-analysis. *World Neurosurg* 2015; 83: 1157-1165.
- [13] Shi J, Tang X, Xu Y, Zhou T, Pan X, Lin H, Mao N, Xu X, Zhao W and Li Y. Single-stage internal fixation for thoracolumbar spinal tuberculosis using 4 different surgical approaches. *J Spinal Disord Tech* 2014; 27: E247-E257.
- [14] Hodgson AR, Stock FE, Fang HS and Ong GB. Anterior spinal fusion. The operative approach and pathological findings in 412 patients with Pott's disease of the spine. *Br J Surg* 1960; 48: 172-178.
- [15] Bailey HL, Gabriel M, Hodgson AR and Shin JS. Tuberculosis of the spine in children. Operative findings and results in one hundred consecutive patients treated by removal of the lesion and anterior grafting. *J Bone Joint Surg Am* 1972; 54: 1633-1657.
- [16] Upadhyay SS, Sell P, Saji MJ, Sell B and Hsu LC. Surgical management of spinal tuberculosis in adults. Hong Kong operation compared with debridement surgery for short and long term outcome of deformity. *Clin Orthop Relat Res* 1994; 173-182.
- [17] Levin R, Matusz D, Hasharoni A, Scharf C, Lonner B and Errico T. Mini-open thoracoscopically assisted thoracotomy versus video-assisted thoracoscopic surgery for anterior release in thoracic scoliosis and kyphosis: a comparison of operative and radiographic results. *Spine J* 2005; 5: 632-638.
- [18] Wang LJ, Zhang HQ, Tang MX, Gao QL, Zhou ZH and Yin XH. Comparison of three surgical approaches for thoracic spinal tuberculosis in adult: minimum 5-year follow-up. *Spine (Phila Pa 1976)* 2017; 42: 808-817.
- [19] Zhong W, Xiong G, Wang B, Lu C, Dai Z and Lv G. Surgical management for thoracic spinal tuberculosis posterior only versus anterior video-assisted thoracoscopic surgery. *PLoS One* 2015; 10: e119759.
- [20] Machino M, Yukawa Y, Ito K, Nakashima H and Kato F. A new thoracic reconstruction technique "transforaminal thoracic interbody fusion": a preliminary report of clinical outcomes. *Spine (Phila Pa 1976)* 2010; 35: E1000-E1005.
- [21] Kossmann T, Jacobi D and Trentz O. The use of a retractor system (SynFrame) for open, minimal invasive reconstruction of the anterior column of the thoracic and lumbar spine. *Eur Spine J* 2001; 10: 396-402.
- [22] Ozdemir HM, Us AK and Ogun T. The role of anterior spinal instrumentation and allograft fibula for the treatment of pott disease. *Spine (Phila Pa 1976)* 2003; 28: 474-479.
- [23] Wang XB, Li J, Lu GH, Wang B, Lu C and Kang YJ. Single-stage posterior instrumentation and anterior debridement for active tuberculosis of the thoracic and lumbar spine with kyphotic deformity. *Int Orthop* 2012; 36: 373-380.