

## Original Article

# Effect and safety of arterial thrombolysis added to solitaire AB stents interventional treatment in acute ischemic stroke

Nan Shi<sup>1</sup>, Lin Zhen<sup>2</sup>, Xin Li<sup>1</sup>, Yakun Wu<sup>1</sup>, Yibin Cao<sup>1</sup>

<sup>1</sup>Department of Neurology, Tangshan Gongren Hospital, Hebei Medical University, Tangshan, Hebei, China; <sup>2</sup>Department of Anesthesiology, The Second Hospital of Tangshan, Tangshan, Hebei, China

Received February 20, 2017; Accepted March 14, 2017; Epub April 15, 2017; Published April 30, 2017

**Abstract:** Objective: To assess the effect and safety of arterial thrombolysis added to solitaire AB stents interventional therapy in the management of acute ischemic stroke. Methods: Between June 2014 and March 2016, we randomly assigned 72 patients with acute ischemic stroke (AIS) treated in our hospital to receive thrombi thrombus and arterial thrombolysis (the control group, n = 36) or solitaire AB stent interventional therapy combined with thrombi thrombus and arterial thrombolysis (the treatment group, n = 36) and by the lot drawing method. The revascularization, the NIHSS scores, cognitive scores and activities of daily living (ADL) scores on day 21 after operation were compared between the two groups. The clinical effect and complications on day 90 postoperatively were also evaluated. Results: The revascularization rate (97.22%, 35/36) was significantly higher in the treatment group versus the control group (80.56%, 29/36) (P = 0.028), and the revascularization period was markedly shorter than that in the control group (P<0.001). The NIHSS score on day 21 after operation was lower in the treatment group than the control group (P<0.001), but the scores of cognition and activities of daily living were higher in the treatment group as compared to the control group (P<0.001). The clinical effect on day 90 postoperatively was significantly improved in the treatment group (P = 0.022), whereas the incidence of complications was significantly different (P = 0.614). Conclusion: Arterial thrombolysis added to neurological interventional therapy shows beneficial effect in patients with acute ischemic stroke and can promote revascularization, thus it is worthy of extensive use in clinical practices.

**Keywords:** Arterial thrombolysis, solitaire AB stent, interventional thrombectomy, acute ischemic stroke

## Introduction

Between 1990 and 2013, the death toll and mortality of stroke in China increased by 47.06% and 23.2% respectively. Stroke has now become China's leading fatal disease [1]. It has not only a high rate of mortality, but also high recurrence and disability. About three-quarters of its survivors present various degrees of hemiplegia and other sequelae. Some patients have even been deprived of a normal life or work. And it is also the primary cause for Disability Adjusted Life Years (DALY) now [2]. Stroke is categorized into ischemic stroke, hemorrhagic stroke and subarachnoid hemorrhage, among which ischemic stroke is the most common. In China, nearly 70% of the patients with stroke have ischemic stroke [3]. Ischemic stroke patients mainly manifest such

symptoms as mouth and nose skew, speech disorders, and hemiplegia. It may cause sequelae if the patients cannot receive timely diagnosis and treatment. Restoring the flow of the occlusive vessels and salvaging the ischemic penumbra is crucial to a successful treatment for ischemic strokes.

Arterial thrombolysis is performed by administering drugs through the artery into the occluded vessel to restore the normal blood supply. Randomized controlled trials show that arterial thrombolysis could improve the neurological outcomes and revascularization [4, 5], so it has been extensively used in the treatment of ischemic stroke. However, arterial thrombolysis is less effective in the stenotic thrombolysis, and prone to cause complications like postoperative hemorrhage [6, 7]. In the recent two

decades, great progress has made in interventional techniques for the management of acute ischemic stroke. As compared with thrombolytic therapy, the interventional techniques have a longer time window, immediately restore the blood flow in the occluded vessels and improve recanalization rates [8]. However, the prognosis of patients remains controversial [9]. In recent years, some studies have focused on the protocol of adding arterial thrombolysis to interventional techniques for the management of acute cerebral ischemia [7, 10]; but its effect remains to be confirmed. Between June 2014 and March 2016, we selected 72 patients with acute ischemic stroke (AIS) treated in our hospital to analyze the effect of arterial thrombolysis added to solitaire AB stent interventional therapy.

### Materials and methods

#### *Subjects*

The subjects were 72 patients with AIS diagnosed and treated in our hospital from June 2014 to March 2016. Inclusion criteria for the patients included: an age of younger than 80 years, significant neurological impairments which gradually became serious and lasted more than 30 minutes, the National Institute of Health stroke scale (NIHSS) scores (8 to 22 points), the time from symptom onset to the therapy within 6 hours (posterior circulation within 24 h), no cerebral hemorrhage or other intracranial diseases as confirmed by CT or MRI; informed consents provided by the patients themselves or their family members; and those with occlusive vessels eligible for endovascular stent placement and stenosis proximal vessels eligible for stent delivery system examined by digital subtraction angiography (DSA). Exclusion criteria: patients with hemorrhagic tendency or past hemorrhagic cerebrovascular diseases; NIHSS scores of at least 22 points, major organ impairments or failure, surgery or trauma within 2 months; preoperative blood pressure of at least 180 mmHg or diastolic blood pressure of at least 110 mmHg. This study was approved by the Hospital Ethics Committee.

#### *Treatment methods*

The patients were randomly assigned into the treatment group (n = 36) or the control group (n

= 36) by the lot drawing method. The patients in the control group were treated with thrombi (Guangxi Wuzhou Pharmaceutical (Group). No. Z20025652) and arterial thrombolysis. The specific procedures were as follows: 500 mg of thrombi were added in 250 ml of 5% glucose solution for intravenous infusion; the DSA was performed to observe the sites and extent of the vessel lesions. The DSA thrombolytic therapy was performed. By the Seldinger technique, the right femoral artery was punctured and into which 6-Fr guide catheter; and heparin was intravenously injected based on the patient's weight. After the systemic heparinization, global cerebral angiography was performed to identify the site of the occluded vessel and the severity of occlusion. The catheter was advanced into the lesion side, during which mechanical thrombolysis was performed supplementary with rotating and pulling the micro-wire and micro-catheter. Urokinase (total amount of 200,000 to 800,000 U; Guangdong Tianpu Biochemical Pharmaceutical Co., No. H2011-3006) was mixed with glucose solution at a ration based on the patients' conditions, and then the mixture was injected slowly into the catheter at 20,000 U/min. After thrombolysis, angiography was performed to confirm the recanalization. The thrombolysis could be repeated for 2-3 times if the recanalization failed. The required total amount of urokinase was 200,000 to 800,000 U, with the maximum no more than 1,500,000 U and the time for thrombolysis procedure no longer than 2 h.

The treatment group was treated with the solitaire AB stents in addition to the treatment for the control group. A micro-catheter carrying a micro-guide wire advanced through the stenotic vessel and went through the lesion artery. The solitaire AB stent was delivered to the stenosis site by the micro-catheter. After the full deployment of the stent was checked by a contrast injection, the stent was released and expanded by the pressure pump; and then the micro-catheter and the stent were removed at the same time. The thrombectomy can be performed repeatedly for several times if necessary.

Patients in the two groups were injected 5000 IU of low molecular weight heparin subcutaneously once daily. They were given clopidogre (75 mg) + atorvastatin (40 mg) + aspirin (100 mg) once a day for 3 to 5 days, with their blood

## Arterial thrombolysis added to solitaire AB stents

**Table 1.** Baseline and clinical characteristics of the treatment group and the control groups

Patient characteristics	Treatment group (n = 36)	Control group (n = 36)	$\chi^2/t$	P
Age	67.4 (8.5)	69.0 (7.8)	0.832	0.408
Gender (Male/Female)	22/14	24/12	0.241	0.624
Smoking (yes/no)	23/13	19/17	0.914	0.339
Drinking (yes/no)	14/22	20/16	2.006	0.157
Past medical history (yes/no)				
High blood pressure	25/11	21/15	0.963	0.326
Diabetes	9/27	5/31	1.419	0.234
Cardiovascular diseases	17/19	10/26	2.904	0.088
Dyslipidemia	15/21	18/18	0.503	0.478
Clinical information				
Initial NIHSS score	16.4±4.8	16.3±4.7	0.536	0.594
Initial cognitive score	7.4±1.2	7.8±1.3	1.357	0.179
Initial activities of daily life score	20.9±5.3	21.1±5.2	0.162	0.872
Lesion side (left/right)	19/17	15/21	2.025	0.155
Onset-admission time (min)	182.7±20.8	191.4±27.8	1.503	0.137
Operating-puncture time (min)	165.3±18.9	172.4±21.8	1.476	0.144

pressure under strict control. On day 3, the patients received 2ATA (1ATA = 760 mmhg) hyperbaric oxygen therapy once an hour a day for 10 days. After the therapy, they were administered long-term oral aspirin at 100 mg per day.

### *Observation indicators and evaluation criteria*

Revascularization: thrombolysis in cerebral infarction (TICI) was used to assess the cerebrovascular recanalization after treatment. TICI is classified into four grades: grade 0 (vascular occlusion); grade I (severe stenosis), grade II (partial recanalization), and grade III (complete recanalization; TICI grade 0 and grade I indicating no recanalization of the cerebral arteries; TICI grade II and grade III indicating cerebral recanalization (reperfusion).

According to the National Institutes of Health Stroke Scale (NIHSS), the patients' neurologic functions were evaluated before, and on day 21 after treatment, respectively. Scoring covered seven aspects of consciousness level, gaze, and upper and lower extremity activities. The higher the score, the more severe the neurological injury was. The cognitive scores of the patients were assessed using the Glasgow Outcome Scale. The three aspects (open-eye response, motor response and language res-

ponse) of the patients were investigated; 15 points, (full mark), indicating a clear consciousness; 12-14 points indicating mild disturbance of consciousness; 9-11 points indicating moderate disturbance; and the points lower than 8 indicating coma. The lower the score, the greater the disturbance of consciousness was. The patients' activities of daily living (ADL) were assessed using the improved Barthel indexes, including the indexes on the following ten activities: eating, bathing, dressing, stool control, urinal control,

use of toilets, transfer of bed and chairs, walking (on the floor, down/up the stairs). The higher the score, the higher the patients' degree of independence.

The clinical effect on day 90 after surgery was evaluated based on the China Stroke Scale (CSS) [11]. The rating is categorized into basic cure, marked efficacy, efficacy, inefficacy, worsening and death. Basic cure is: the score of neurologic deficit severity reduces by 91%-100% compared with that before treatment, Level 0 disability. Marked efficacy: the score of neurologic deficit severity reduces by 46%-90% as compared with that before treatment, Level 1-3 disability. Efficacy: the score of neurologic deficit severity reduces by 18%-45% as compared with that before treatment. Inefficacy or worsening: the score of neurologic deficit severity vary in the range lower than 18% as compared with that before treatment, and even it may increase by more than 18% as compared with that before treatment; and death. The total effective rate equals to basic cure rate, significant efficiency plus efficiency.

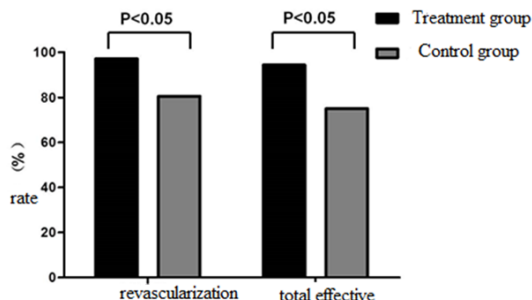
### *Statistical analysis*

The differences between categorical variables were detected using the bilateral  $\chi^2$  test or exact probability method. Continuous variables

**Table 2.** Comparison of recanalization between the two groups

Group	Case	Revascularization rate	Revascularization time (min)
Treatment group	36	35(97.22)	16.5±3.5
Control group	36	28 (80.56)	28.4±6.2
P value		0.028*	<0.001**

Note: \*Fisher exact probability calculation. \*\*Independent sample t-test.



**Figure 1.** The recanalization rate and the total effective rate in the treatment group and the control group.

were expressed as mean ± standard deviation. The mean across groups and the difference before and after treatment between groups were tested using the two-sample independent t-test. Statistically significance level was defined as bilateral  $\alpha = 0.05$ .

## Results

### Basic findings

The baseline and clinical characteristics of the two groups are shown in **Table 1**. There were no significant differences in gender, age, smoking, alcohol consumption, and medical history between the treatment group and the control group. The preoperative NIHSS score, cognitive score and ADL score were 16.4, 7.4 and 20.9, respectively, and the average time of onset-admission and operating-puncture were 182.7 and 165.3 minutes respectively. No significant difference was shown in the clinical characteristics between the two groups ( $P > 0.05$ ).

### Comparison of revascularization

The revascularization rate was higher in the treatment group (97.22%, 35/36) than in the control group (80.56% of, 29/36,  $P = 0.028$ ). The mean revascularization time was 16.5 min,

shorter than that of the control group ( $P < 0.001$ ). The differences were statistically significant (**Table 2; Figure 1**).

### Comparison of NIHSS score, cognitive score and ADL score on day 21 after surgery between the two groups

The NIHSS scores of the treatment group decreased by 10.1 on day 21, but the scores of the cognitive and ADL increased by 6.1 and 22.3, respectively. The improvements in the three indexes were significantly higher than those of the control group ( $P < 0.001$ ) (**Table 3**).

### Comparison of clinical effect of patients between the two groups

Clinical effect of the patients in the two groups on day 90 after treatment is shown in **Table 4**. The rates of basic cure, marked efficacy and efficacy in the treatment group were 61.1%, 16.7% and 16.7%, respectively. The difference in the total effect rate between the treatment group and the control group (94.4% vs 75.0%) was statistically significant ( $P = 0.022$ , **Figure 1**). During treatment and follow-up, one case in the treatment group had intracranial hemorrhage; one had recurrent infarction and one had intracranial hemorrhage in the control group. The difference in the incidence of complications between the two groups (2.8% vs 5.6%) showed no significant difference ( $P = 0.614$ ).

## Discussion

Acute ischemic stroke is one of the major causes of human disability and deaths. The key to a successful treatment is to restore the flow of the occlusive vessels as soon as possible and salvage the ischemic penumbra. Currently, the most extensively used therapy for early recanalization in AIS is intravenous medical thrombolysis, mainly rt-PA andurokinase [12, 13]. The effect of rt-PA intravenous injection within 4.5 h from the ischemic stroke onset has been confirmed. The advantages of intravenous thrombolysis are simple technical devices, convenient and easy operation, relatively smaller trauma, shorter time operation, low costs, and popularity with patients. However, its larger thrombolytic dose and strict time window limitation make only less than 3% of

## Arterial thrombolysis added to solitaire AB stents

**Table 3.** Comparison of the NIHSS score, cognitive score and ADL score before and after treatment between the two groups (n = 36)

Group	NIHSS score			Cognitive score			Daily life score		
	P-T	21-d-p-t	D	P-T	21-d-p-t	D	P-T	21-d-p-t	D
Treatment group	16.4±4.8	5.3±2.6	10.1±3.2	7.4±1.2	13.5±3.6	6.1±1.9	20.9±5.3	43.2±10.6	22.3±6.1
Control group	16.3±4.7	9.6±3.6	6.7±2.1	7.8±1.3	11.7±2.8	3.9±1.1	21.1±5.2	34.2±7.9	13.1±3.4
t			5.330			6.012			7.904
P values			<0.001			<0.001			<0.001

Note: P-T: Pre-treatment; 21-d-p-t: day 21 post-treatment; D: Difference.

**Table 4.** Comparison of clinical effect after treatment between the two groups

Group	Case	Basic cure (%)	Marked efficacy (%)	Efficacy (%)	Inefficacy or worsening (%)	Total efficacy (%)
Treatment group	36	22 (61.1)	6 (16.7)	6 (16.7)	2 (5.6)	94.4
Control group	36	9 (25.0)	8 (22.2)	10 (27.8)	9 (25.0)	75.0
$\chi^2$						5.258
P value						0.022

patients eligible for IV rtPA. In addition, the recanalization rate is low in the patients with large arteries occlusion or severe conditions. Furthermore, the mortality and disability at 90 days after surgery are still high [14]. Therefore, how to improve the rate of revascularization and the effect of thrombolytic therapy has been a hot spot in recent years.

In recent two decades, the endovascular interventional techniques for AIS treatment including arterial thrombolysis, mechanical thrombectomy, and endovascular stent have advanced rapidly. Studies in recent years have shown that arterial thrombolysis enables thrombolytic agents at high concentrations to be directly administered to the sites of the thrombi, thereby increasing the rates of revascularization of large occluded vessels. Randomized trials and Meta-analyses, such as PROACT II and MELT, have demonstrated the effect of arterial thrombolysis in the treatment of AIS [4, 5, and [4, 5, 15]. In the PROACT II trial, arterial thrombolysis alone was associated with a 66.0% revascularization rate, which was significantly higher than that in the placebo group (18%). The improvement in neurological outcomes was also higher than that of the control group. The results of the MELT test are generally similar to those of the PROACT II trials. In our study, the revascularization rate of the control group treated with intravenous bolus injection of thrombi plus urokinase arterial thrombolysis was 80.56%, slightly higher than that of

the PROACT II trial. The results might be attributed to the function of thrombi intravenous injection. The major ingredient of the thrombus is Panax Notoginseng Saponins (PNS), which is extracted from Panax notoginseng (PNS). Its main functions are promoting blood circulation to dissipate blood stasis, dredging the meridian passages, activating qi and relieving pains. Many studies have proved that it can expedite the recovery of neurological functions, improve microcirculation, cerebral ischemia and hypoxia, showing a favorable effect on stroke [16, 17].

It is reported that the revascularization rate of arterial thrombolysis is about 70%, which is still unsatisfactory. In addition, the patients with cerebral artery infarctions tend to be associated with severe atherosclerosis in intracranial large arteries, so arterial thrombosis often recurs after thrombolysis therapy, which may lead to re-occlusion of blood vessels. In recent years, new and effective mechanical techniques recanalizing occluded vessels, especially solitaire AB stent thrombectomy, have developed rapidly, which significantly increases the revascularization rate of large cerebral vessel infarctions. The solitaire AB stent is a second-generation, self-expanding stent embolization device approved by the FDA in 2012. The released stent functionally equals to a stent procedure that allows rapid flow restoration. Its effect and safety are higher than those of the first-generation Merci devices [18]. The Study

on solitaire AB thrombus removal in acute revascularization (STAR study) demonstrated a 79.2% rate of revascularization with a solitaire AB stent and a 57.9% good clinical outcome on day 90 postoperatively [19]. The study published in the *New England Journal of Medicine* in 2015 further showed the advantages of solitaire AB stents [20].

In a recently published EXTEND-IA study, rt-PA intravenous thrombolysis added to solitaire AB stents can significantly improve reperfusion of ischemic stroke in patients caused by proximal cerebral artery occlusion and promote early neurological recovery as compared with rt-PA intravenous thrombolysis alone [21]. Solitaire AB stent added to arterial thrombolysis may help to address the problem of delayed thrombolysis due to prolonged preoperative preparation and to improve revascularization rate and neurological outcomes [7]. In our study, solitaire AB and arterial thrombolysis significantly increased revascularization rate and shortened revascularization time. In addition, the neurological recovery and prognosis of the treatment group on day 21 and 90 postoperatively were significantly better than those of the control group, consistent with those of other studies [22-24], which is further demonstrating the effect of arterial thrombolysis added to intravascular interventional therapy for ischemic brain stroke. Based on the research in China and other countries, China has developed the Guidelines for the Early Management of Patients with Acute Ischemic Stroke Regarding Endovascular Treatment [25]. However, it should be noted that, there are still some defects in solitaire AB stent thrombectomy, including the risk of vascular intima injury which may promote aggravate thrombosis, and the development of thrombosis caused by stent placement of foreign substance in the vessels.

In summary, the clinical effect of solitaire AB stent thrombolysis plus intra-arterial thrombolysis in the treatment of AIS is better than that of intra-arterial thrombolytic therapy alone. Nevertheless, due to the small sample size and short postoperative follow-ups, additional randomized controlled trials with larger sample size are required to address such problem as time-window selection, optimal treatment procedures as well as long-term effect in the management of AIS by arterial thrombolysis plus solitaire AB stent thrombolysis.

### Disclosure of conflict of interest

None.

**Address correspondence to:** Nan Shi, Department of Neurology, Tangshan Gongren Hospital, Hebei Medical University, No. 27 Wenhua Road, Lubei District, Tangshan 063000, Hebei, China. Tel: +86-0315-2305226; E-mail: shinan02th@126.com

### References

- [1] Zhou M, Wang H, Zhu J, Chen W, Wang L, Liu S, Li Y, Liu Y, Yin P, Liu J, Yu S, Tan F, Barber RM, Coates MM, Dicker D, Fraser M, Gonzalez-Medina D, Hamavid H, Hao Y, Hu G, Jiang G, Kan H, Lopez AD, Phillips MR, She J, Vos T, Wan X, Xu G, Yan LL, Yu C, Zhao Y, Zheng Y, Zou X, Naghavi M, Wang Y, Murray CJ, Yang G and Liang X. Cause-specific mortality for 240 causes in China during 1990-2013: a systematic sub-national analysis for the global burden of disease study 2013. *Lancet* 2016; 387: 251-272.
- [2] Cui FF, Yu CH, Nie DW and Zhang GS. Analysis of the trend of disability-adjusted life year and health-adjusted life expectancy in China between 1990 and 2013. *Modern Preventive Medicine* 2016.
- [3] Wang Y, Cui L, Ji X, Dong Q, Zeng J, Zhou Y, Zhao X, Wang C, Liu L, Nguyen-Huynh MN, Claiborne Johnston S, Wong L and Li H. The China national stroke registry for patients with acute cerebrovascular events: design, rationale, and baseline patient characteristics. *Int J Stroke* 2011; 6: 355-361.
- [4] Ogawa A, Mori E, Minematsu K, Taki W, Takahashi A, Nemoto S, Miyamoto S, Sasaki M and Inoue T. Randomized trial of intraarterial infusion of urokinase within 6 hours of middle cerebral artery stroke: the middle cerebral artery embolism local fibrinolytic intervention trial (MELT) Japan. *Stroke* 2007; 38: 2633-2639.
- [5] Furlan A, Higashida R, Wechsler L, Gent M, Rowley H, Kase C, Pessin M, Ahuja A, Callahan F, Clark WM, Silver F and Rivera F. Intra-arterial prourokinase for acute ischemic stroke. The PROACT II study: a randomized controlled trial. Prolase in acute cerebral thromboembolism. *JAMA* 1999; 282: 2003-2011.
- [6] Pfefferkorn T, Mayer TE, Opherck C, Peters N, Straube A, Pfister HW, Holtmannspotter M, Muller-Schunk S, Wiesmann M and Dichgans M. Staged escalation therapy in acute basilar artery occlusion: intravenous thrombolysis and on-demand consecutive endovascular mechanical thrombectomy: preliminary experience in 16 patients. *Stroke* 2008; 39: 1496-1500.

## Arterial thrombolysis added to solitaire AB stents

- [7] Seifert M, Ahlbrecht A, Dohmen C, Spuentrup E, Moeller-Hartmann W. Combined interventional stroke therapy using intracranial stent and local intraarterial thrombolysis (LIT). *Neuroradiology* 2011; 53: 273-82.
- [8] Sussman E, Kellner C, McDowell M, Yang P, Nelson E, Greenberg S, Sahlein D, Lavine S, Meyers P and Connolly ES. Endovascular thrombectomy following acute ischemic stroke: a single-center case series and critical review of the literature. *Brain Sci* 2013; 3: 521-539.
- [9] Kidwell CS, Jahan R and Saver JL. Endovascular treatment for acute ischemic stroke. *N Engl J Med* 2013; 368: 2434-2435.
- [10] Belisle JG, McCollom VE, Tittle TL, Banowetz JM, Handley RA, Andrezik JA and Griggs TS. Intraarterial therapy for acute ischemic strokes. *J Vasc Interv Radiol* 2009; 20: 327-333.
- [11] Clinical neurological deficit score of stroke in patients (1995). *Chinese Journal of Neurology* 1996.
- [12] Wang Y, Wu D, Zhao X, Ma R, Guo X, Wang C, Liu L and Zhao W. Hospital resources for urokinase/recombinant tissue-type plasminogen activator therapy for acute stroke in Beijing. *Surg Neurol* 2009; 72 Suppl 1: S2-7.
- [13] American College of Emergency Physicians Clinical Policies Subcommittee (Writing Committee) on Use of Intravenous tPA for Ischemic Stroke, Brown MD, Burton JH, Nazarian DJ and Promes SB. Clinical policy: use of intravenous tissue plasminogen activator for the management of acute ischemic stroke in the emergency department. *Ann Emerg Med* 2015; 66: 322-333, e331.
- [14] Rha JH and Saver JL. The impact of recanalization on ischemic stroke outcome: a meta-analysis. *Stroke* 2007; 38: 967-973.
- [15] Lee M, Hong KS and Saver JL. Efficacy of intra-arterial fibrinolysis for acute ischemic stroke: meta-analysis of randomized controlled trials. *Stroke* 2010; 41: 932-937.
- [16] Liu JL. Clinical observation on the curative effect of xueshuantong injection in treating stroke. *Journal of Clinical and Rational Drug Application* 2015.
- [17] Shen HB, Weng J. Clinical efficacy of Xueshuantong injection in patients with acute ischemic cerebrovascular disease. *Chinese Modern Doctor* 2015.
- [18] Saver JL, Jahan R, Levy EI, Jovin TG, Baxter B, Nogueira RG, Clark W, Budzik R and Zaidat OO. Solitaire flow restoration device versus the Merci retriever in patients with acute ischemic stroke (SWIFT): a randomised, parallel-group, non-inferiority trial. *Lancet* 2012; 380: 1241-1249.
- [19] Pereira VM, Gralla J, Davalos A, Bonafé A, Castaño C, Chapot R, Liebeskind DS, Nogueira RG, Arnold M, Sztajzel R, Liebig T, Goyal M, Besselmann M, Moreno A, Schroth G. Prospective, multicenter, single-arm study of mechanical thrombectomy using solitaire flow restoration in acute ischemic stroke. *Stroke* 2013; 44: 1-16.
- [20] Saver JL, Goyal M, Bonafe A, Diener HC, Levy EI, Pereira VM, Albers GW, Cognard C, Cohen DJ, Hacke W, Jansen O, Jovin TG, Mattle HP, Nogueira RG, Siddiqui AH, Yavagal DR, Baxter BW, Devlin TG, Lopes DK, Reddy VK, du Mesnil de Rochemont R, Singer OC, Jahan R; SWIFT PRIME Investigators. Stent-retriever thrombectomy after intravenous t-PA vs. t-PA alone in stroke. *N Engl J Med* 2015; 372: 2285-2295.
- [21] Campbell BC, Mitchell PJ, Kleinig TJ, Dewey HM, Churilov L, Yassi N, Yan B, Dowling RJ, Parsons MW, Oxley TJ, Wu TY, Brooks M, Simpson MA, Miteff F, Levi CR, Krause M, Harrington TJ, Faulder KC, Steinfort BS, Priglinger M, Ang T, Scroop R, Barber PA, McGuinness B, Wijeratne T, Phan TG, Chong W, Chandra RV, Bladin CF, Badve M, Rice H, de Villiers L, Ma H, Desmond PM, Donnan GA, Davis SM; EXTEND-IA Investigators. Endovascular therapy for ischemic stroke with perfusion-imaging selection. *N Engl J Med* 2015; 372: 1009-1018.
- [22] Zou WW, Zhao LD, Yang G, Jiang M, Zhao ZQ. The Clinical Effect of Arterial Thrombolysis Combined with Solitaire AB Stent Thrombectomy in Treating Acute Ischemic Stroke. *Journal of Practical Cardiology and Cerebrovascular Diseases* 2012.
- [23] Yang YN, Li T, Sun YQ, Ma XK, Gu Z. Solitaire AB stent mechanical thrombolysis combined with arterial thrombolysis in the treatment of acute ischemic stroke efficacy. *Journal of Anhui Medical Sciences* 2015.
- [24] Cai XJ, Liu HF, Zhong HF, Hou SJ, Lv XJ. Arterial thrombolysis combined with solitaire AB stent for acute ischemic stroke. *Journal of Difficult and Complicated Diseases* 2016.
- [25] Gao F, Xu AD. Chinese Journal of Intravascular Therapy for Acute Ischemic Stroke 2015. *Chinese Journal of Stroke* 2015.