

## Original Article

# Microneedle interventional therapy combined with cervical spine manipulation for cervicogenic dizziness

Qi Xie<sup>1,2\*</sup>, Xin Duan<sup>3,4\*</sup>, Yihua Shi<sup>5</sup>, Xiaoyu Lv<sup>2</sup>, Yuqing Wang<sup>2</sup>, Yan Tao<sup>6</sup>, Lijun Zhong<sup>7</sup>, Jianfeng Sun<sup>2</sup>, Huiyan Lei<sup>8</sup>, Qingshui Yin<sup>1,9</sup>, Junfeng Duan<sup>2</sup>

<sup>1</sup>Southern Medical University, Guangzhou 510515, China; <sup>2</sup>Department of Rehabilitation Medicine, Guangzhou General Hospital of PLA, Guangzhou 510010, China; <sup>3</sup>The First Affiliated Hospital of Sun Yat-Sen University, Guangzhou 510000, China; <sup>4</sup>Washington University in St. Louis, St. Louis, MO 63110, USA; <sup>5</sup>The First Affiliated Hospital of Clinical Medicine of Guangdong Pharmaceutical University, Guangzhou 510006, China; <sup>6</sup>Department of Cardiovascular Surgery, Guangzhou General Hospital of PLA, Guangzhou 510010, China; <sup>7</sup>Department of Pain Treatment, Guangzhou Zhongxing Sports Trauma Hospital, Guangzhou 510010, China; <sup>8</sup>Department of Ultrasonography, Guangzhou General Hospital of PLA, Guangzhou 510010, China; <sup>9</sup>Department of Orthopedics, Guangzhou General Hospital of PLA, Guangzhou 510010, China. \*Equal contributors.

Received March 21, 2017; Accepted September 27, 2017; Epub April 15, 2018; Published April 30, 2018

**Abstract:** The efficacy of drug therapy for cervical spine manipulation is poor, whereas microneedle interventional therapy appears to be effective. The study aimed to further examine the clinical application of microneedle interventional therapy for cervicogenic dizziness. This was a study of patients (18-70 years; cervicogenic dizziness for  $\geq 2$  months) at the General Hospital of Guangzhou Military Command of PLA, China (June 2014 to June 2016). Patients were allocated to a Manipulation-Alone group (Long's bone-setting manipulation 5 times/week for 2 weeks) or Microneedle+Manipulation group (5 manipulations; then 2 sessions of microneedle interventional therapy 2 weeks apart). Primary outcomes were vertigo symptom score and its components (dizziness severity, frequency and duration). Secondary outcomes included neck/shoulder pain severity, headache severity, daily life and work capability, mental and social adaptation score, and vertebral artery color Doppler ultrasound indexes. Adverse events were recorded. Of 102 patients screened, 18 met exclusion criteria and 4 were lost to follow-up. In the Microneedle+Manipulation group (n=40; 18 males;  $48.13 \pm 10.12$  years; disease course,  $11.06 \pm 8.12$  months) 40 had vertigo, 36 cervicodynia, 32 nausea and 18 tinnitus; lesion site was C1/C2 in 22, C2/C3 in 14 and C3/C4 in 8. In the Manipulation-Alone group (n=40; 20 males;  $47.80 \pm 9.33$  years; disease course,  $10.34 \pm 9.58$  months), 40 had vertigo, 37 cervicodynia, 30 nausea and 16 tinnitus; lesion site was C1/C2 in 24, C2/C3 in 14 and C3/C4 in 7. Baseline characteristics were similar between groups. In both groups, vertigo symptom score and scores for dizziness severity, frequency and duration had all improved at 2 weeks and 6 months after therapy (all  $P < 0.001$ ), but efficacy was superior in the Microneedle+Manipulation group ( $P < 0.001$ ). Scores for secondary outcome measures were also higher in both groups at 2 weeks and 6 months after therapy (all  $P < 0.001$ ), with superior increases in the Microneedle+Manipulation group ( $P < 0.001$ ). Improvements in vertebral artery diameter, blood velocity and blood flow at 2 weeks and 6 months after therapy were greater in the Microneedle+Manipulation group (all  $P < 0.05$ ). Adverse events were similar between groups. Microneedle interventional therapy combined with cervical spine manipulation is a safe and effective treatment for cervicogenic dizziness.

**Keywords:** Cervicogenic dizziness, cervical vertigo; acupotomy, manipulation, microneedle interventional therapy

## Introduction

Cervicogenic dizziness is a disease commonly encountered in the neurology clinic, with around half of all patients aged over 50 years with vertigo suffering from this syndrome [1, 2]. The rate in young patients has been rising gradually. Patients with cervicogenic dizziness gener-

ally present with disequilibrium and dizziness associated with neck pain and discomfort, as well as a history of neck injury or lesion [3, 4]. Patients with repeated attacks or a long disease course often suffer from neck cramps and contracture of the muscle and fascia, which in turn aggravates the disequilibrium [5]. Cervical spine manipulation, drugs and physiotherapy

are often used to treat cervicogenic dizziness, but their efficacy is limited.

The deep muscle overlying the upper cervical vertebrae contains an abundance of mechanoreceptors that relay proprioceptive information regarding vertebral joint movement and head orientation; this information integrates with the vestibular and visual systems. In patients with cervical spondylosis, muscle spasm, myofasciitis and synovial entrapment in the uncovertebral joint can cause abnormal proprioception and disturbed nerve impulse transmission to vestibular nuclei [3, 6, 7], creating a feeling of imbalance. Furthermore, cervical degeneration or neck injury can damage the vestibular nuclei or alter sympathetic excitability, resulting in vertebrobasilar artery hemodynamic changes that may contribute to the pathogenesis of cervicogenic dizziness [7-15]. Vertebral artery asymmetry is more common in patients with cervical spondylosis (34%) than in the normal population [16], while vertigo is associated with degenerative osteoarthritic changes and lower vertebral artery blood flow [13]. Segmentally distributed bidirectional sympathetic nerve fibers innervating the cervical vertebra are widely distributed in the joint capsule, posterior longitudinal ligament, annulus fibrosus and dural sac [8, 17, 18]. Stretching or compression of sympathetic nerves by cervical vertebral instability or/and uncovertebral joint hyperplasia could alter vertebral artery hemodynamics, causing dizziness. In view of the above, any method that reduced pathologic stimulation of muscle/joint capsule proprioceptors, sympathetic nerves and the vertebral artery could potentially be an effective therapy.

Posterior longitudinal ligament excision can improve vertigo symptoms in patients with cervical spondylosis [19, 20], indicating that relaxation of the muscle fascia, joint capsule and ligament may be an effective treatment. Spinal manipulation can reduce cervicogenic dizziness [21-24] and improve postural stability, joint positioning and range of motion, muscle tenderness, neck pain, and vertebrobasilar arterial flow [22, 23]. Long's bone-setting manipulation, developed by Profs Long and Wei, is a manipulation therapy based on cervical spine anatomy and biomechanics that is widely used in China and other parts of East Asia [25, 26]. The therapy is tailored to the types of vertebral

joint displacement and rotation identified during examination (including imaging) [27]. The main therapeutic goal is reduction of the displacement to improve posture and physiologic movement. The manipulation involves small forces, minimizing the risks of additional damage to the neck [26-28].

Microneedle interventional therapy has been used to treat cervical spondylosis in some regions of China and East Asia. Prof. Duan has developed an improved acupuncture technique that combines modern orthopedics and soft tissue surgery with traditional Chinese orthopedics [29-31]. Prof. Duan has used microneedle interventional therapy for over 20 years and achieved good efficacy in the treatment of spinal diseases. The benefits of this therapy for cervical spondylosis are thought to arise from relaxation of adhesions, scars and contractures in cervical vertebral soft tissue, recovery of mechanical dynamic equilibrium, improvements in microcirculation and metabolism, clearance of inflammatory mediators, release of analgesic substances (e.g. enkephalin) and relief of pain. Moreover, local effects on the muscle fascia, joint capsule and ligaments may result in the correction of proprioceptive dysfunction in the neck [30, 31] and improvement in vertebrobasilar hemodynamics.

Although microneedle interventional therapy has attracted attention as a novel treatment for cervicogenic dizziness [32, 33], only limited published data are available regarding its efficacy. We hypothesized that the combination of microneedle interventional therapy and cervical spine manipulation would have superior efficacy to spine manipulation alone in the treatment of cervicogenic dizziness. Therefore, we designed and performed a randomized, controlled study to explore the efficacy and safety of microneedle interventional therapy in patients with cervicogenic dizziness.

### Materials and methods

#### *Patients*

Patients diagnosed with cervicogenic dizziness at the Rehabilitation Medicine Department, General Hospital of Guangzhou Military Command of PLA, China were recruited between June 2014 and June 2016.

## Acupotomy for cervicogenic dizziness

The following inclusion criteria were used for enrolment of patients: 1) age 18-70 years; 2) a clinical diagnosis of cervicogenic dizziness using standard criteria (see below) [2, 4]; 3) disease course  $\geq 2$  months; and 4) symptoms, physical examination and X-ray imaging suggested the existence of upper cervical spondylosis. The diagnosis of cervicogenic dizziness [2, 4] was made on the basis of: 1) symptoms of dizziness related to neck movement that were associated with neck pain/discomfort with or without headache, nausea and tinnitus; 2) upper cervical tenderness and a positive head impulse test on physical examination; 3) dysfunction of the atlanto-axial joint and degenerative changes observed by X-ray imaging; and 4) abnormal hemodynamic characteristics in the vertebral artery revealed by ultrasonography or magnetic resonance angiography (MRA).

The following exclusion criteria were applied: 1) vertigo due to other causes such as cerebrovascular accident, cerebral trauma, migraine-associated vertigo and chronic subjective vertigo; 2) tumor, tuberculosis, cervical spine fracture or serious osteoporosis; 3) severe stenosis of the vertebral artery or atheromatous plaque formation in the carotid or vertebral arteries; 4) internal fixation of the spine; 5) atlanto-axial dislocation, atlanto-odontoid congenital malformation or severe spinal instability (ligament loosening, etc.); 6) severe dysfunction of the heart, brain, liver, kidney or coagulation systems; 7) infectious disease or severe dermatosis; or 8) women who were pregnant or in the lactation period. Patients initially enrolled in the study were excluded from the final analysis if they: 1) did not finish the therapy according to the regimen; 2) showed poor adherence to treatment; or 3) withdrew from the study.

The study was approved by the ethics committee of the General Hospital of Guangzhou Military Command of PLA, and all patients provided informed written consent.

### *Study design*

The enrolled patients were randomly allocated to one of two groups: a Microneedle+Manipulation group (to receive a combination of microneedle interventional therapy and 5 sessions of cervical spine manipulation) and a Manipulation-Alone group (to receive 10 sessions of cervical spine manipulation alone).

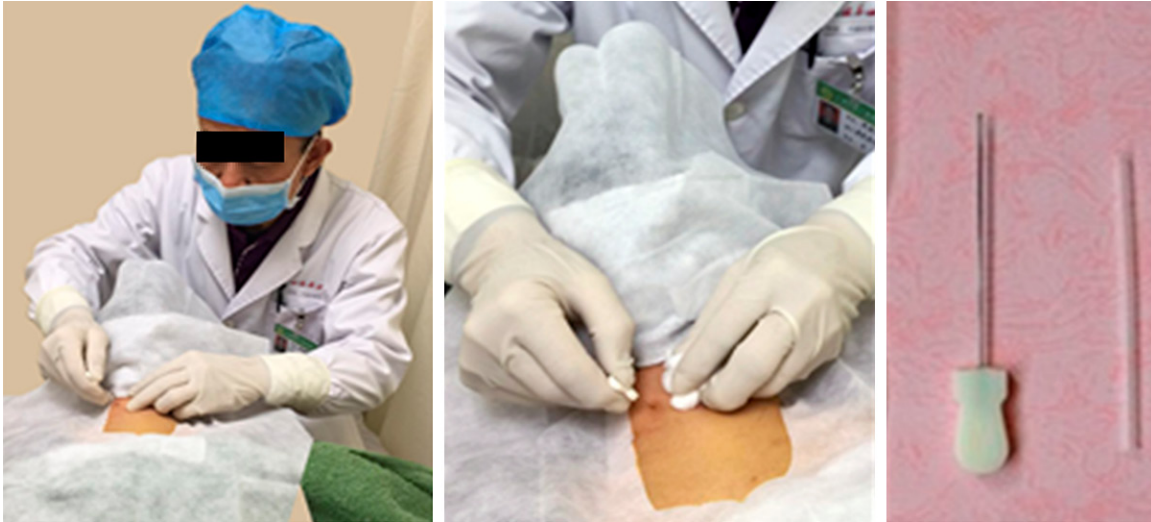Randomization was performed using a random number generator to produce an allocation sequence, and allocation concealment was achieved through the use of sequentially numbered, opaque, sealed envelopes. A member of staff not involved in delivery of the interventions allocated the patients to the two groups. The staff members providing cervical spine manipulation and the evaluators of the outcome measures (see below) were blinded to the grouping of the patients.

### *Interventions*

During the 2-week therapy period, all patients were precluded from receiving any other treatments from medical staff not involved in this study.

### *Manipulation-alone group*

Cervical spine manipulation was carried out by two physiotherapists and one physiatrist, each of whom had at least 5 years' experience. According to Long's bone-setting manipulation [27], the procedure was performed once daily for 25 min, 5 times/week (during weekdays) for 2 weeks. The segment and type of facet joint displacement were determined from the symptoms and results of palpation and X-ray imaging (cervical spine films using various views, including open mouth, anteroposterior, flexion and extension views). Manipulation to reduce the displacement was carried out with low-amplitude spinal adjustments and mobilization. First, the patient was placed in the recumbent position, and the area of the occipital triangle and the neck and shoulder muscle groups were relaxed by manipulation (mainly with the thumb, but also with the palm) for 10 min. Then, manipulation to reduce the displacement was carried out. Long's bone-setting manipulation has 10 methods, and the appropriate methods were selected according to the dislocation position and type. The main methods used were as follows: cervical extension technique for rotational malposition of atlanto-axial articulation; lateral transfer and pressing technique for lateral malposition; cervical flexion-rotation for C3, 4 rotational malposition; and cervical lateral push technique for rotational malposition of the uncovertebral joint. The manipulation was carried out with the minimal force necessary in order to reduce discomfort and any sounds (e.g. clicking or cracking) associated with reduc-



**Figure 1.** Photographs illustrating microneedle interventional therapy. The left and middle panels show insertion of an acupotomy needle during therapy. The right panel shows a no. 4 disposable acupotomy needle (Hanzhang Type I) with an overall length of 100 mm. The needle body is cylindrical (0.6 mm diameter, 80 mm length) and wedge-shaped with a flat, bladed end that has a flush cut edge (0.6 mm). The handle (20 mm length) has a flat calabash-like shape.

tion, as this was thought likely to improve adherence to treatment. After manipulation, the relevant muscles were massaged, and the patients were asked to perform functional activities before the session was considered finished. If malposition of a segment was successfully corrected, further manipulation of this segment was not performed.

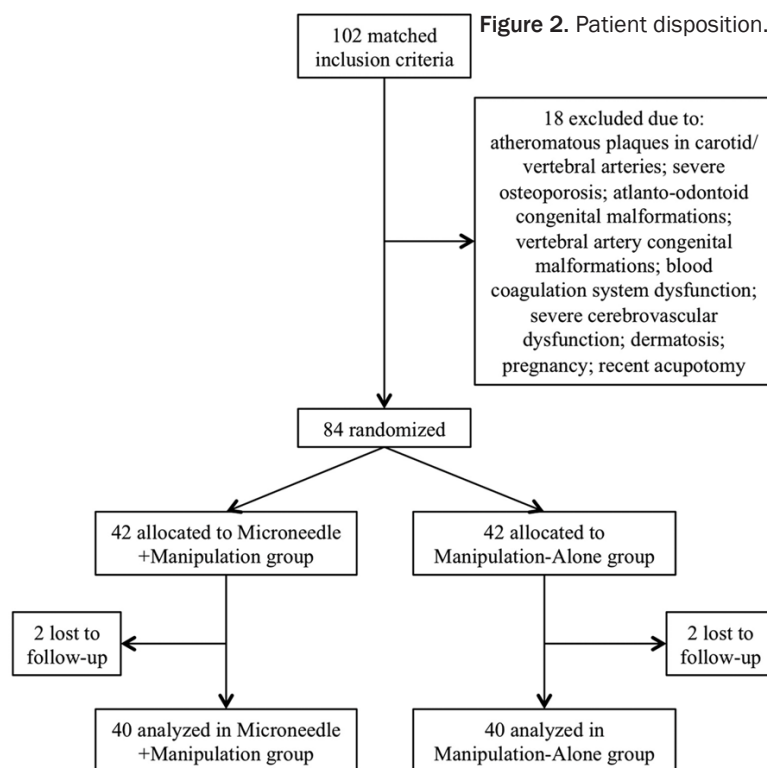
#### *Microneedle+manipulation group*

Cervical spine manipulation therapy was performed by the same staff as those for the Manipulation-Alone group, using the same technique. Cervical spine manipulation was performed once daily for 25 min, for a total of 5 sessions.

Microneedle interventional therapy [30] was performed after the fifth manipulation and again one week later, with each session lasting 10 min (**Figure 1**). The same physician (with several decades of experience in orthopedic surgery and 20 years' experience in rehabilitation medicine) carried out microneedle interventional therapy on all patients in the Microneedle+Manipulation group. The patient was placed in a recumbent position, lidocaine was injected subcutaneously, and pressure was applied to the wound for 30 min to achieve hemostasis. A no. 4 acupotomy needle (Hanzhang Type I, Huaxia Zhendao) was used, with

10-15 entry points/session. The start and end points of the muscle were taken as the main entry points and were marked by gentian violet. After withdrawing the acupotomy needle, pressure was applied using drapes to achieve hemostasis. The following approaches were used. 1) For relaxation of the rectus capitis posterior major muscle, the acupotomy edge ran parallel to the axis of the patient's body from the rectus capitis posterior major and minor muscles: the entry point was vertical and the depth was down to the bone surface; vertical cuts were made for relaxation, with 2-3 cuts made along a horizontal strip. 2) For relaxation of obliquus capitis superior and inferior, the obliquus capitis superior was taken as the entry point, and the acupotomy slid along the bone surface to the posterior tubercle of the transverse process, with 1-2 relaxing cuts made. The acupotomy was vertically inserted to the bone surface one-third of the way along obliquus capitis superior and inferior, and 2-3 vertical and horizontal cuts were made for relaxation. The C2 spinous process from which obliquus capitis inferior arises was taken as the entry point to the spinous process tip, and 1-2 cuts were made alongside the spinous process. 3) For relaxation of the second, third and fourth cervical vertebral spinous processes and transverse processes, the acupotomy needle was inserted vertically to the second, third or fourth

## Acupotomy for cervicogenic dizziness



cervical vertebral spinous process with the acupotomy edge parallel with the patient's body. After the blade had reached the spinous process bone surface, 1-2 cuts were made along the bone surface in the up, down, left and right directions. The C2, C3 and C4 transverse processes were relaxed 5 cm from the neck midline. The entry point was vertical to the bone surface, and the needle was inserted down to the bone surface. A total of 2-3 cuts were made horizontally and vertically along the bone surface.

### Clinical data and outcome measures

The demographic and clinical characteristics of the participants were collected at the initial baseline appointment by means of self-reporting questionnaires, clinical history taking and physical examination.

The primary and secondary outcome measures were evaluated by staff blinded to the patient grouping. The primary outcome measures (recorded at baseline and at 2 weeks and 6 months after therapy) were total vertigo symptom score (scored 0-16) and its component parts, namely: severity of dizziness (scored

0-8), frequency of dizziness (scored 0-4) and duration of each episode of dizziness (scored 0-4) [34]. The secondary outcome measures (recorded at baseline and at 2 weeks and 6 months after therapy) included severity of neck and shoulder pain (scored 0-4), severity of headache (scored 0-2), daily life and work capability (scored 0-4), and mental and social adaptation score (scored 0-4) [34]. For all outcome measures, a higher score indicated lower symptom severity. In addition, Doppler ultrasound examinations (Vivid 7 ultrasound machine with 10L probe; frequency 4-10 MHz; GE Healthcare) of the bilateral vertebral arteries were undertaken before, 2 weeks after and 6 months after therapy

to measure blood vessel diameter, blood velocity (cm/s) and blood flow (mL/min).

### Evaluation of efficacy

Evaluation of treatment efficacy was performed by staff blinded to the patient grouping. As suggested by the 3rd National Summary of the Symposium on Cervical Spine [2], efficacy at 2 weeks after therapy was classified on the basis of improvements in dizziness symptoms, neck pain symptoms and daily life scores, as follows: 1) complete cure: all symptoms (including dizziness and neck pain) had completely disappeared, with normal motion in the cervical vertebra, normal neck rotation, normal 'bow and lean' test, and daily life unaffected; 2) high efficacy: symptoms such as dizziness and neck pain had nearly but not completely disappeared, with normal motion in the cervical vertebra, normal neck rotation, normal 'bow and lean' test, and daily life only slightly affected; 3) moderate efficacy: symptoms such as dizziness and neck pain had improved but still required further therapy, and daily life was also improved but still affected to some degree; or 4) no effect: symptoms and daily life scores showed no improvement.

## Acupotomy for cervicogenic dizziness

**Table 1.** Baseline clinical characteristics of the patients included in the analysis

Characteristic	Microneedle+Manipulation (n = 40)	Manipulation-Alone (n = 40)	P value
Age (years)	48.13±10.12	47.80±9.33	0.8799
Sex (male/female)	18/22	20/20	0.6543
Disease course (months)	11.06±8.12	10.34±9.58	0.7179
Symptom scale scores			
Total score	12.67±2.05	13.27±1.93	0.1816
Total score for dizziness	6.17±1.41	6.51±1.25	0.2573
Dizziness severity	3.66±1.30	3.85±1.35	0.5233
Dizziness frequency	1.31±0.46	1.22±0.62	0.4631
Dizziness duration	1.20±0.57	1.44±0.57	0.0634
Neck and shoulder pain	2.31±0.63	2.31±0.70	1.0000
Headache	1.19±0.31	1.25±0.38	0.4414
Daily life and work	1.63±0.66	1.81±0.69	0.2368
Mental and social adaptation	1.37±0.58	1.39±0.91	0.9070
Lesion site			
C1/C2	22 (55%)	24 (60%)	0.6510
C2/C3	14 (35%)	14 (35%)	1.0000
C3/C4	8 (20%)	7 (17.5%)	0.7745
Comorbidities			
Hypertension	9 (22.5%)	7 (17.5%)	0.5761
Diabetes mellitus	3 (7.5%)	5 (12.5%)	0.7094 <sup>a</sup>
Hyperlipidemia	7 (17.5%)	5 (12.5%)	0.5312
Ultrasound indexes			
Vertebral artery diameter (mm)	3.04±0.31	3.06±0.34	0.8239
Vertebral artery blood velocity (cm/s)	15.91±2.96	15.97±2.82	0.4084
Vertebral artery blood flow (mL/min)	63.42±18.73	64.07±15.68	0.5002

Data presented as mean ± SD or n. <sup>a</sup>Mantel-Haenszel correction.

### Statistical analysis

SPSS13.0 (SPSS Inc., Chicago, IL, USA) was used to analyze the data. Data were analyzed in the intention-to-treat population. Measurement data are expressed as the mean ± standard deviation (SD) while categorical data are expressed as n (%). Baseline clinical characteristics were compared between groups using Student's t-test for normally distributed continuous data or the chi-squared test (with Mantel-Haenszel correction when the minimum expected frequency was < 5) for enumeration data. Comparisons of vertigo symptom scores and neck/shoulder pain scores within groups at different time points and between groups were made using one-way analysis of variance (ANOVA) for repeated measurements; if the Mauchly sphericity test was not met, the Greenhouse-Geisser correction was used. Clinical efficacy at 2 weeks was compared bet-

ween groups using the Chi-square test. Ultrasound data were analyzed using ANOVA for repeated measurement. The occurrence of adverse events was compared between groups using the chi-squared test with Mantel-Haenszel correction (minimum expected frequency < 5). P < 0.05 was considered to indicate a statistically significant difference.

### Results

#### Patient disposition

Patient disposition is shown in **Figure 2**. Of 102 patients initially screened for inclusion, 18 were excluded due to the presence of atherosclerotic plaques in the carotid or vertebral arteries, severe osteoporosis, atlanto-odontoid congenital malformations, vertebral artery congenital malformations, blood coagulation system dysfunction, severe cerebrovascular dys-

## Acupotomy for cervicogenic dizziness

**Table 2.** Comparison of symptom scale scores before and after therapy in the two groups

Assessment scale	Microneedle+Manipulation group (n = 40)			P1	Manipulation-Alone group (n = 40)			P2	P3
	Before therapy	Two weeks after therapy	Six months after therapy		Before therapy	Two weeks after therapy	Six months after therapy		
Total score	12.67±2.05	26.11±2.40	27.87±2.65	<0.001 <sup>a</sup>	13.27±1.93	23.27±2.67	22.72±2.49	<0.001 <sup>b</sup>	<0.001 <sup>b</sup>
Total score for dizziness	6.17±1.41	13.28±1.24	14.74±1.31	<0.001 <sup>a</sup>	6.51±1.25	12.13±2.18	11.61±1.93	<0.001 <sup>b</sup>	<0.001 <sup>b</sup>
Dizziness severity	3.66±1.30	6.95±1.15	7.41±1.13	<0.001 <sup>b</sup>	3.85±1.35	6.22±2.20	5.85±1.21	<0.001 <sup>b</sup>	<0.001 <sup>b</sup>
Dizziness frequency	1.31±0.46	3.51±0.47	3.76±0.46	<0.001 <sup>b</sup>	1.22±0.62	2.89±0.67	2.14±0.56	<0.001 <sup>b</sup>	<0.001 <sup>b</sup>
Dizziness duration	1.20±0.57	3.52±0.61	3.57±0.73	<0.001 <sup>b</sup>	1.44±0.57	3.02±0.63	2.62±1.07	<0.001 <sup>b</sup>	<0.001 <sup>b</sup>
Neck and shoulder pain	2.31±0.63	3.85±0.29	3.88±0.22	<0.001 <sup>a</sup>	2.31±0.7	3.52±0.48	3.48±0.47	<0.001 <sup>a</sup>	<0.001 <sup>b</sup>
Headache	1.19±0.31	1.88±0.27	1.93±0.17	<0.001 <sup>b</sup>	1.25±0.38	1.53±0.24	1.59±0.38	<0.001 <sup>b</sup>	<0.001 <sup>b</sup>
Daily life and work	1.63±0.66	3.75±0.5	3.78±0.33	<0.001 <sup>a</sup>	1.81±0.69	3.18±0.54	3.26±0.61	<0.001 <sup>b</sup>	<0.001 <sup>a</sup>
Psychological and social adaptation	1.37±0.58	3.35±0.58	3.54±0.63	<0.001 <sup>a</sup>	1.39±0.91	2.91±0.61	2.78±0.76	<0.001 <sup>a</sup>	<0.001 <sup>a</sup>

Data presented as mean ± SD. P1: Comparison before and after therapy in the Microneedle+Manipulation group. P2: Comparison before and after therapy in the Manipulation-Alone group. P3: Comparison of therapy efficacy between the Microneedle+Manipulation group and Manipulation-Alone group. <sup>a</sup>ANOVA for repeated measurement, meeting Mauchly sphericity test. <sup>b</sup>ANOVA for repeated measurement, not meeting Mauchly sphericity test and using Greenhouse-Geisser test instead.

## Acupotomy for cervicogenic dizziness

**Table 3.** Comparison of clinical efficacy between the two groups

Efficacy measurement	Microneedle+Manipulation (n = 40)	Manipulation-Alone (n = 40)	P value
Two weeks after therapy			0.0231
Complete cure	33 (82.5%)	21 (52.5%)	
High efficacy	5 (12.5%)	10 (25%)	
Moderate efficacy	1 (2.5%)	7 (17.5%)	
No effect	1 (2.5%)	2 (5%)	
Six months after therapy			0.0035
Complete cure	35 (87.5%)	17 (42.5%)	
High efficacy	4 (10%)	13 (32.5%)	
Moderate efficacy	1 (2.5%)	7 (17.5%)	
No effect	0 (0%)	3 (7.5%)	

function, dermatosis, pregnancy or recent treatment with acupotomy. The remaining 84 patients were randomly divided into the Microneedle+Manipulation and Manipulation-Alone groups (n = 42 each). During therapy, 2 cases from each group were lost to follow-up during the post-intervention phase. Thus, a total of 80 patients, 40 in each group, were included in the final analysis.

### Baseline clinical characteristics

The patients in the Microneedle+Manipulation group included 18 males and 22 females aged 48.13±10.12 years with a disease course of 11.06±8.12 months. Forty patients in the Microneedle+Manipulation group had vertigo, 36 had cervicodynia, 32 had nausea and 18 had tinnitus; the lesion site was C1/C2 in 22 patients, C2/C3 in 14 patients and C3/C4 in 8 patients. The Manipulation-Alone group consisted of 20 males and 20 females aged 47.80±9.33 years with a disease course of 10.34±9.58 months. Forty patients in the Manipulation-Alone group had vertigo, 37 had cervicodynia, 30 had nausea and 16 had tinnitus; there were 24 cases of a C1/C2 lesion, 14 cases of a C2/C3 lesion and 7 cases of a C3/C4 lesion. There were no significant differences between the two groups in any of the baseline clinical characteristics, including scores for severity of dizziness, frequency of dizziness, duration of dizziness, neck and shoulder pain, headache, daily life and work capability, and mental and social adaptation (**Table 1**).

### Primary outcomes

Before therapy, there were no significant differences between the two groups in total dizzi-

ness score or scores for severity of dizziness, frequency of dizziness or duration of dizziness (**Table 1**). However, for both groups there were significant improvements in all of these scores after therapy (all P < 0.001; **Table 2**). Furthermore, the primary outcome measure scores were higher in the Microneedle+Manipulation

group than in the Manipulation-Alone group at both 2 weeks and 6 months after therapy (all P < 0.001; **Table 2**).

### Secondary outcomes

Before therapy, the two groups did not differ significantly with regard to neck and shoulder pain, headache, daily life and work capability, and mental and social adaptation (**Table 1**). Both groups showed significant improvements in all of these scores after therapy (all P < 0.001; **Table 2**). Moreover, the secondary outcome measure scores were higher in the Microneedle+Manipulation group than in the Manipulation-Alone group at 2 weeks and 6 months after therapy (all P < 0.001; **Table 2**).

### Comparison of efficacy

After 2 weeks of therapy, complete cure was achieved in 33/40 patients (82.5%) in the Microneedle+Manipulation group but only 21/40 patients (52.5%) in the Manipulation-Alone group. At 6 months after therapy, the complete cure rate was 35/40 (87.5%) in the Microneedle+Manipulation group but only 17/40 (42.5%) in the Manipulation-Alone group. Clinical efficacy was significantly superior in the Microneedle+Manipulation group than in the Manipulation-Alone group (P < 0.05; **Table 3**).

### Vertebral artery color doppler ultrasound

Before therapy, there were no significant differences between the two groups in vertebral artery diameter, blood velocity or blood flow (**Table 1**). At 2 weeks and 6 months after therapy, there were significant increases in vertebral artery diameter, blood velocity and blood flow

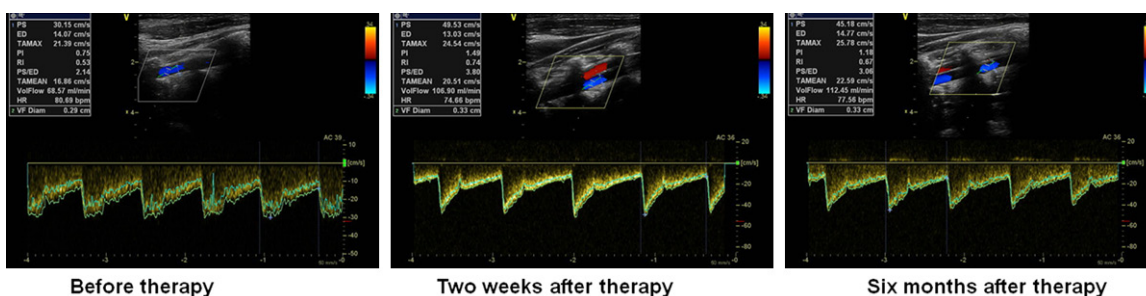


## Acupotomy for cervicogenic dizziness

**Table 4.** Comparison of vertebral artery color Doppler ultrasound indexes (on the affected side) before and after therapy in the two groups

Ultrasound index	Microneedle+Manipulation group (n = 40)			P1	Manipulation-Alone group (n = 40)			P2	P3
	Before therapy	Two weeks after therapy	Six months after therapy		Before therapy	Two weeks after therapy	Six months after therapy		
Diameter (mm)	3.04±0.31	3.41±0.32	3.49±0.36	<0.001 <sup>a</sup>	3.06±0.34	3.30±0.48	3.24±0.47	0.045 <sup>a</sup>	0.043 <sup>a</sup>
Blood velocity (cm/s)	15.91±2.96	18.69±2.93	19.62±3.25	<0.001 <sup>a</sup>	15.97±2.82	17.79±4.45*	16.72±4.82	0.136 <sup>b</sup>	0.016 <sup>b</sup>
Blood flow (ml/min)	63.42±18.73	104.24±25.66	108.28±16.25	<0.001 <sup>a</sup>	64.07±15.68	97.93±18.73	96.27±20.52	<0.001 <sup>a</sup>	0.012 <sup>a</sup>

Data presented as mean ± SD. P1: Comparison before and after therapy in the Microneedle+Manipulation group. P2: Comparison before and after therapy in the Manipulation-Alone group. P3: Comparison of effect between the Microneedle+Manipulation group and Manipulation-Alone group. <sup>a</sup>ANOVA for repeated measurement, meeting Mauchly sphericity test. <sup>b</sup>ANOVA for repeated measurement, not meeting Mauchly sphericity test and using Greenhouse-Geisser test instead. \*: At 2 weeks after therapy, there was significant increase in blood velocity in manipulation-alone group than before therapy. (t-test, P<0.05).



**Figure 3.** Photographs illustrating blood flow of Vertebral artery with Ultrasound before and after treatment in one patient in the Microneedle+Manipulation group. The Left panel show blood flow of Vertebral artery before therapy. (Diameter =0.29 cm, Blood velocity =16.86 cm/s, Blood flow =68.57 ml/min). The Middle panel show blood flow of Vertebral artery two weeks after therapy (Diameter=0.33 cm, Blood velocity =20.51 cm/s, Blood flow =106.90 ml/min). The right panel show blood flow of Vertebral artery six months after therapy (Diameter =0.33 cm, Blood velocity=22.59 cm/s, Blood flow =112.45 ml/min).

in the Microneedle+Manipulation group (all P < 0.05; **Table 4**) (**Figure 3**) and in vessel diameter and blood flow (but not velocity) in the Manipulation-Alone group (P < 0.05; **Table 4**). Notably, the improvements in these ultrasound indexes were superior in the Microneedle+Manipulation group than in the Manipulation-Alone group (all P < 0.05).

### Adverse events

There were no serious adverse events reported during the study. Mild and transient adverse events were reported in a minority of patients in both groups (predominantly aggravation of dizziness/vertigo, neck/shoulder pain and headache) but these subsequently fully resolved (**Table 5**). There were no significant differences between groups in the incidence of adverse events.

### Discussion

The main findings of the present study were that the symptoms of cervicogenic dizziness, including the severity, frequency and duration of dizziness and the severity of associated

headaches, were improved 2 weeks after treatment with either Long's bone-setting manipulation or a combination of microneedle interventional therapy with cervical spine manipulation. Furthermore, the benefits of both treatment methods were maintained at 6 months, suggesting long-term effectiveness. Importantly, the efficacy of microneedle interventional therapy combined with cervical spine manipulation was superior to that of manipulation alone both at 2 weeks and 6 months after therapy. In addition, although both treatment strategies improved vertebral artery hemodynamic parameters (measured using color Doppler ultrasound) at 2 weeks and 6 months, greater improvements were seen in patients receiving microneedle interventional therapy. These data suggest that the combination of microneedle interventional therapy with cervical spine manipulation could be an effective management strategy for achieving long-term alleviation of symptoms in patients with cervicogenic dizziness.

Internationally, standard Western cervical spine manipulation techniques are used to

## Acupotomy for cervicogenic dizziness

**Table 5.** Adverse events in the two groups

Adverse event	Microneedle+ Manipulation (n = 40)	Manipulation- Alone (n = 40)	P value
Aggravation of dizziness/vertigo	4 (10%)	7 (17.5%)	0.5161 <sup>a</sup>
Aggravation of neck/shoulder pain	3 (7.5%)	5 (12.5%)	0.7094 <sup>a</sup>
Aggravation of headache	0	3 (7.5%)	0.2405 <sup>b</sup>
Other	3 (7.5%)	4 (10%)	1.0000 <sup>a</sup>

Note: <sup>a</sup>Mantel Haenszel correction applied; <sup>b</sup>Minimum theoretical frequency < 1, exact probability applied.

treat patients with cervicogenic dizziness. When degeneration occurs, the spine can develop functional segmental instability under physiologic loads [35-37] and exhibit displacement during movement of the centrum. This is thought to be an important pathogenic factor for cervicogenic dizziness, as displacement can lead to secondary inflammation, spasm and mechanical imbalance in the soft tissues surrounding the cervical vertebrae, exerting pressure on sympathetic nerves that stimulates them [38]. This in turn can affect the hemorheology of the vertebral artery and cause damage to proprioceptors. Long's bone-setting manipulation can potentially correct malposition of the uncovertebral joint and pars interarticularis, rebuild the physiologic curvature of the cervical vertebra, enlarge the inner diameter of the transverse foramen (through which the vertebral artery runs), and reduce mechanical pressure on the vertebral plexus, cervical sympathetic trunk and ganglion and sinuvertebral nerves, thereby alleviating abnormal excitation of the sympathetic nerves and contracture of blood vessels and surrounding soft tissue [22, 38, 39].

In this study, microneedle interventional therapy reduced the symptoms of cervicogenic dizziness with greater efficacy than cervical spine manipulation alone. The biomechanical stability of a cervical vertebra arises from endogenous structures (including the vertebral body, intervertebral disc and ligaments) that provide static balance and exogenous structures (mainly the neck muscles) that provide dynamic balance. Mechanical imbalance in the cervical vertebrae will alter the physiologic line of force through the spine and exert abnormal stresses on the attachment sites of the neck muscles, leading to local muscle spasm, swelling and hyperplasia. Chronic aseptic inflammation of

the fascia will increase the pressure in the myofascial sheath, further stimulating sympathetic nerves and resulting in dysfunction of proprioception and vertebral artery blood flow. Damage to the soft tissues surrounding the abnormal site can inhibit successful correction of the displacement by manipulation. Microneedle interven-

tional therapy can potentially overcome this issue by relaxing the soft tissues at various sites, including the cervical vertebral spinous processes, perispinous processes, transverse processes, pars tuberalis, zygapophyseal joint, foramen intervertebrale and muscular fasciae. This in turn can reduce the abnormal excitability of sympathetic nerves, improving the hemorheological status of the vertebral arteries, and correct dysfunction of proprioceptors in the joint capsule, muscle fascia and ligaments. By recovering normal mechanical balance and neurologic function, microneedle interventional therapy can potentially consolidate the benefits of cervical spine manipulation and reduce symptom relapse in patients with cervicogenic dizziness by preventing re-displacement of small joints after reduction. Recently, it was found that acupotomy regulates the levels of b-FGF and CD34 levels in serum and muscle tissue as well as local tissue revascularization [40]. It was found that acupotomy treatments could lower NOS and beta-EP levels in the hypothalamus, spinal cord, and peripheral blood [41]. Furthermore, acupotomy has been reported to reduce back pain and radiating pain and in recovering the kinetic state of soft tissue in patients with a herniated intervertebral disc [42]. It was found that acupotomy is effective to relieve pain and to improve quality of life in patients with degenerative lumbar spinal stenosis [43]. The present study observed that both treatment approaches, but particularly microneedle interventional therapy in combination with cervical spine manipulation, improved hemodynamic parameters in the vertebral arteries, suggesting that this may contribute to the clinical benefits in patients with cervicogenic dizziness. Doppler ultrasound examination can evaluate the hemodynamic changes in the vertebral arteries

with good sensitivity [14, 32] and could potentially be used as a method for evaluating the efficacy of treatments for cervicogenic dizziness.

Although microneedle interventional therapy is a minimally invasive technique, it still possesses invasive characteristics. Pathologically, microneedle interventional therapy can cause the generation of new scars in local tissue; therefore, repeated trauma could result in the formation of a new contracture, which would not be conducive to long-term recovery of cervical spondylosis. For this reason, only 1-3 applications of microneedle interventional therapy are recommended. A key part of delivering this therapy is to accurately identify the therapy site (the attachment and pressure points in the tendon) [44]. During treatment, the obtuse needle is initially inserted rapidly through the skin but is then advanced much more slowly to avoid damage to nerves and blood vessels. Furthermore, dredging and stripping are performed after the needle has reached the bone surface; back and forth motions are not undertaken to avoid damaging the surrounding tissues. Microneedle interventional therapy has good efficacy for cervical spondylosis where the lesion is mainly in the extra spinal soft tissues, but poor efficacy when the lesion is caused by intraspinal factors as it is very difficult to use a microneedle to target lesions within the spinal canal.

The present study has some limitations. First, this was a single-center study, so the findings may not be generalizable to other regions of China or other countries. Second, the patient was not blinded to the treatment method, and this may have introduced bias that potentially influenced the results. Third, the cervical spine manipulation regimens were not the same in the two groups. Fourth, additional groups receiving other treatment modalities (e.g. medications) were not included, so it was not possible to make comparisons with other therapeutic approaches (or combinations of approaches). Fifth, the follow-up period was only 6 months, so conclusions cannot be drawn regarding the longer-term benefits of the treatment methods. Sixth, the potential benefits of functional training and home-based exercises were not examined. Functional recovery training (including target movement and coordination training for

the eye as well as neck and muscle contraction training) during the remission period has gained increasing attention as an approach to improving vestibular disorder in patients with cervical spondylosis [3, 45]. Further studies are required to confirm and extend our observations.

In conclusion, microneedle interventional therapy combined with Long's bone-setting manipulation therapy can significantly improve symptoms and vertebral artery hemodynamic status in patients with cervicogenic dizziness. This combined strategy should be alternative for patients with chronic cervicogenic dizziness.

### Acknowledgements

The study was supported by Guangzhou Science and Technology Key Project (No: 201508020253) and Guangzhou Science and Technology Project (No: 2014Y2-00131). Our experiments comply with the current law of China. We would like to acknowledge Dr. Cenghua Long (General Hospital of Guangzhou Military Command of PLA) for guiding the manipulation treatment. The study was supported by Guangdong Key Laboratory of Orthopaedic Technology and Implant materials and Key Laboratory of Trauma & Tissue Repair of Tropical Area of PLA (General Hospital of Guangzhou Military Command of PLA, Guangzhou, 510010, China.).

### Disclosure of conflict of interest

None.

**Address correspondence to:** Qingshui Yin, Department of Orthopedics, Guangzhou General Hospital of PLA, Guangzhou 510010, China. Tel: +86-18620110099; E-mail: gz\_yqs@126.com; Junfeng Duan and Xiaoyu Lv, Department of Rehabilitation Medicine, Guangzhou General Hospital of PLA, Guangzhou 510010, China. Tel: +86-13609792198; E-mail: junfengduan@163.com (JFD); Tel: +86-13802548805; E-mail: doctor\_max@163.com (XYL)

### References

- [1] Schappert SM. National hospital ambulatory medical care survey: 1992 emergency department summary. *Vital Health Stat* 13 1997; 1-108.
- [2] Li Z, Chen D and Wu D. The third session of the national cervical panel summary. *Chin J Surg* 2008; 46: 1796-1799.

## Acupotomy for cervicogenic dizziness

- [3] Yacovino DA and Hain TC. Clinical characteristics of cervicogenic-related dizziness and vertigo. *Semin Neurol* 2013; 33: 244-255.
- [4] Wrisley DM, Sparto PJ, Whitney SL and Furman JM. Cervicogenic dizziness: a review of diagnosis and treatment. *J Orthop Sports Phys Ther* 2000; 30: 755.
- [5] Morinaka S. Musculoskeletal diseases as a causal factor of cervical vertigo. *Auris Nasus Larynx* 2009; 36: 649.
- [6] Ryan GM and Cope S. Cervical vertigo. *Lancet* 1926; 266: 1355-1359.
- [7] Brandt T and Bronstein AM. Cervical vertigo. *J Neurol Neurosurg Psychiatry* 2001; 71: 8-12.
- [8] Zuo J, Han J, Qiu S, Luan F, Zhu X, Gao H and Chen A. Neural reflex pathway between cervical spinal and sympathetic ganglia in rabbits: implication for pathogenesis of cervical vertigo. *Spine J* 2014; 14: 1005-1009.
- [9] Hong L and Kawaguchi Y. Anterior cervical discectomy and fusion to treat cervical spondylosis with sympathetic symptoms. *J Spinal Disord Tech* 2011; 24: 11-14.
- [10] Wang Z, Wang X, Yuan W and Jiang D. Degenerative pathological irritations to cervical PLL may play a role in presenting sympathetic symptoms. *Med Hypotheses* 2011; 77: 921-923.
- [11] Treleaven J, Jull G and Sterling M. Dizziness and unsteadiness following whiplash injury: characteristic features and relationship with cervical joint position error. *J Rehabil Med* 2003; 35: 36-43.
- [12] Mitchell J. Vertebral artery blood flow velocity changes associated with cervical spine rotation: a meta-analysis of the evidence with implications for professional practice. *J Man Manip Ther* 2013; 17: 46.
- [13] Machaly SA, Senna MK and Sadek AG. Vertigo is associated with advanced degenerative changes in patients with cervical spondylosis. *Clin Rheumatol* 2011; 30: 1527.
- [14] Zhou J, Ziqing LI, Linlin XU, Zhu L. Diagnostic value of measuring the blood flow volume of vertebral artery by color doppler ultrasound in posterior circulation ischemia. *Journal of Clinical Ultrasound in Medicine* 2013; 24: 517-720.
- [15] Acar M, Degirmenci B, Yucel A, Albayrak R, Haktanir A and Yaman M. Comparison of vertebral artery velocity and flow volume measurements for diagnosis of vertebrobasilar insufficiency using color duplex sonography. *Eur J Radiol* 2005; 54: 221-224.
- [16] Endo K, Ichimaru K, Komagata M and Yamamoto K. Cervical vertigo and dizziness after whiplash injury. *Eur Spine J* 2006; 15: 886-890.
- [17] Nathan PW and Smith MC. The location of descending fibres to sympathetic preganglionic vasomotor and sudomotor neurons in man. *J Neurol Neurosurg Psychiatry* 1987; 50: 1253-1262.
- [18] Li J, Gu T, Yang H, Liang L, Jiang DJ, Wang ZC, Yuan W and Wang XW. Sympathetic nerve innervation in cervical posterior longitudinal ligament as a potential causative factor in cervical spondylosis with sympathetic symptoms and preliminary evidence. *Med Hypotheses* 2014; 82: 631-635.
- [19] Li J, Jiang DJ, Wang XW, Yuan W, Liang L and Wang ZC. Mid-term outcomes of anterior cervical fusion for cervical spondylosis with sympathetic symptoms. *Clin Spine Surg* 2016; 29: 255-60.
- [20] Ren L, Guo B, Zhang J, Han Z, Zhang T, Bai Q and Zeng Y. Mid-term efficacy of percutaneous laser disc decompression for treatment of cervical vertigo. *Eur J Orthop Surg Traumatol* 2014; 24: 153-158.
- [21] Reid SA, Rivett DA, Katekar MG and Callister R. Sustained natural apophyseal glides (SNAGs) are an effective treatment for cervicogenic dizziness. *Man Ther* 2008; 13: 357-366.
- [22] Reid SA, Rivett DA, Katekar MG and Callister R. Comparison of mulligan sustained natural apophyseal glides and maitland mobilizations for treatment of cervicogenic dizziness: a randomized controlled trial. *Phys Ther* 2014; 94: 466-476.
- [23] Lystad RP, Bell G, Bonneviensvendsen M and Carter CV. Manual therapy with and without vestibular rehabilitation for cervicogenic dizziness: a systematic review. *Chiropr Man Therap* 2011; 19: 21.
- [24] Humphreys BK and Peterson C. Comparison of outcomes in neck pain patients with and without dizziness undergoing chiropractic treatment: a prospective cohort study with 6 month follow-up. *Chiropr Man Therap* 2013; 21: 3.
- [25] Sun J and Dun J. Clinical observation for 46 patients with cervicogenic dizziness by Long's manipulation. *J Cervicodynia Lumbodynia* 2009; 30: 475-476.
- [26] Yin LH, Shen T and Liang WJ. Clinical research of Long's manipulation in the treatment of cervical vertigo in children. *Chinese Journal of Rehabilitation* 2014; 29: 301-304.
- [27] Wei Z and Yang K. The study and treatment of spinal diseases. The Commercial Press (H.K.) Ltd. 38. 1995.
- [28] Fan DH, Liu G, Wang TC, Huang F, Wang XY, Zeng HW, Zhou FX, Yao GX, Chen XL, Xu RD, Li Y. [Observation on short and long-term effects of cervical spondylotic radiculopathy treated with abdominal acupuncture plus Long's bone-

## Acupotomy for cervicogenic dizziness

- setting manipulation]. *Zhongguo Zhen Jiu* 2010; 30: 909-12.
- [29] Sun GD and Shi B. The clinical research on never root kind of cervical spondylosis cured by three-dimensional needle-knife. *Journal of Clinical Acupuncture & Moxibustion* 2009; 25: 10-12.
- [30] Duan J and Wei Z. *Spinal etiology therapeutics*, people's military medical press (China), pages 137-138. 2011.
- [31] Huang K and Hu X. *Chinese Acupotomy*, The World's Medical Publishing House (Hong Kong), 150-151. 2000.
- [32] Quan W, Zhu H and Zhang X. Clinical effect of acupotomy treatment for Atlanto-axial joint disorder. *Chinese Journal of Traditional Medical Traumatology & Orthopedics* 2007; 22: 1107-1109.
- [33] Yuhong M, Gang Y and Lijuan L. Clinical efficacy observation of cervical vertigo treated with acupotomy and acupoint blockage. *World J Integr Trad West Med* 2015; 10: 1265-1267.
- [34] Wang C and Zhuo D. A preliminary evaluation of symptoms and functions of patients with cervical vertigo. *Chinese Journal of Rehabilitation Medicine* 1998; 13: 245-247.
- [35] Duan JF, Duan X and Ning JZ. Anatomical study of the disease correlated to spine. *Journal of Cervicodynia & Lumbodynia* 2006; 27: 93-94.
- [36] Steilen D, Hauser R, Woldin B and Sawyer S. Chronic neck pain: making the connection between capsular ligament laxity and cervical instability. *Open Orthop J* 2014; 8: 326-345.
- [37] Panjabi MM. The stabilizing system of the spine. Part I. function, dysfunction, adaptation, and enhancement. *J Spinal Disord* 1992; 5: 383-389.
- [38] Yin Q. Research status and facing challenges of spine-related disease. *Chin Orthop J Clin Basic Res* 2014; 6: 69-72.
- [39] Michels T, Lehmann N and Moebus S. Cervical vertigo-cervical pain: an alternative and efficient treatment. *J Altern Complement Med* 2007; 13: 513-518.
- [40] Li XH, Liu NG, Guo CQ, Sun HM, Wu HX, Xu H and Zhang Y. Effects of acupotomy on basic fibroblast growth factor and CD34 levels in rabbits with third lumbar vertebral transverse foramen syndrome. *Genet Mol Res* 2015; 14: 9739-44.
- [41] Guo C, Liu N, Li X, Sun H, Hu B, Lu J, Guo Y, Liang C, Xu H and Wu H. Effect of acupotomy on nitric oxide synthase and beta-endorphin in third lumbar vertebrae transverse process syndrome model rats. *J Tradit Chin Med* 2014; 34: 194-198.
- [42] Kim HJ, Jeon JH and Kim YI. Clinical effect of acupotomy combined with Korean medicine: a case series of a herniated intervertebral disc. *J Acupunct Meridian Stud* 2016; 9: 31-41.
- [43] Yuk D, Sung I, Song D, Kim M and Hong K. Clinical study of lumbar spine stenosis treated by using acupotomy combined with oriental medical treatments. *J Pharmacopuncture* 2013; 16: 46-51.
- [44] Lavelle ED, Lavelle W and Smith HS. Myofascial trigger points. *Anesthesiol Clin* 2007; 25: 841-851.
- [45] Armstrong B, Mcnair P and Taylor D. Head and neck position sense. *Sports Med* 2008; 38: 101-117.