

Original Article

The role and importance of ostomy in the management of recto-vaginal fistula

Ibrahim Tayfun Sahiner*, Murat Kendirci*

Department of General Surgery, Medical Faculty of Hitit University, Erol Olçok Training and Research Hospital, Çorum, Turkey. *Equal contributors.

Received May 22, 2016; Accepted October 5, 2017; Epub October 15, 2017; Published October 30, 2017

Abstract: Background: Although rare, recto-vaginal fistulas (RVF), defined as an abnormal epithelial connection between the rectum and vagina, has a significant adverse consequences in terms of the life quality. The most common etiological factors involve the obstetric causes in developing countries, while cancer surgery and radiotherapy are responsible for the majority of the cases in the developed world. The surgical management encompasses a wide range of procedures from simple interventions to more complex ones. Ostomy represents a therapeutic option aimed at achieving infection control through the deportation of the feces away from the site of fistula, allowing tissue repair and preparation prior to definitive repair. A complete diversion of the feces is essential, with no closure of the ostomy until complete healing. Methods: Six patients with RVF referred to the Erol Olçok Training and Research Hospital, Medical Faculty of Hitit University in 2015-2017 were included and their data were evaluated retrospectively. After detailed information provided to patients, written informed consent obtained. Local Ethics committee approved. Demographic data, type of fistula, comorbid conditions, initial and subsequent surgery with their outcomes were reported. Complete blood counts and routine biochemistry tests were also performed before and after ostomy to assess infectious processes. Results: Patient number one and two had RVF due to RT given for cancer treatment, while patients number four, five and six had RVF after cancer surgery. Patient number three had chronic constipation resulting from paraplegia and the subsequent prolonged pressure on the recto-vaginal septum, giving rise to RVF. Permanent Hartmann colostomy was performed in our patients no 1 and 2, due to the presence of comorbid VVF as well as the presence of cervical cancer, while the same procedure was applied in-patient no 2 due to the presence of lung metastases. In-patient no 3, colostomy was not closed at the discretion of the patient, since she was bed-ridden and the temporary colostomy was able to provide better feces control, although RVF healing occurred. In patients, no 4, 5 and 6, RVF spontaneously healed after temporary ileostomy, with subsequent closure of ileostomy. Conclusions: In these patients, temporary or permanent ostomy may be performed to control infections, to manage fecal discharge in bed-ridden or demented patients, and to prevent complications arising from infections and adhesions of intestines after RT depending on the general wellbeing and life expectancy of the patients. Although the decision to choose permanent ostomy is not an easy task for both the patient and physician, it should be performed after adequate consultation with the patient, when needed.

Keywords: Recto-vaginal fistula, ostomy, radiotherapy

Background

Recto-vaginal fistula (RVF) is defined as the presence of an abnormal epithelial connection between the anterior rectal and posterior vaginal walls [1, 2], leading to the escape of the colonic content into the vagina. Patients generally present with vaginal flatulence and fecal leakage. While RVF is associated mainly with somatic complaints in the early stages, psychological issues also emerge over time leading to a worsening in the quality of life. Co-morbid

vesico-vaginal fistula (VVF) complicates the clinical picture with persistent urinary incontinence and the subsequent treatment-refractory urinary infection, leading to greater therapeutic challenges.

RVFs are classified into two groups based on their size and location. Those between the lower third of rectum and lower half of vagina are termed as low, and those between the middle third and posterior fornix of the vagina are termed as high fistula. In addition, they may be

Rectovaginal fistula management

Table 1. Overall patient characteristics

Patient No.	Age	Etiology	Type of fistula	Comorbid conditions	First surgery	Second surgery	Outcome
1	62	Operated cervical cancer, external RT	High, complex	HT, VVF	Transverse colon loop colostomy and left nephrostomy	Permanent Hartmann colostomy and right nephrostomy	Improved
2	51	Operated cervical cancer, external RT	High, complex	DM, VVF, lung metastasis	Permanent Hartmann colostomy and bilateral nephrostomy	None	Improved
3	74	Chronic irritation (constipation)	Low, complex	HT	Sigmoid loop colostomy	None	Cure
4	45	Operated rectal cancer (LAR)	High, simple	None	Temporary ileostomy	Ileostomy closure	Cure
5	68	Operated rectal cancer (LAR)	High, complex	DM, HT	Temporary ileostomy	Ileostomy closure	Cure
6	65	Operated rectal cancer (LAR)	High, complex	None	Temporary ileostomy	Ileostomy closure	Cure

HT: Hypertension; DM: Diabetes mellitus.

Table 2. Complete blood counts and routine biochemistry tests of the patients

	P 1	P 2	P 3	P 4	P 5	P 6
Preoperative						
WBC (4-10 $10^9/L$)	16	13	18	14	12	12.5
CRP (0-5 mg/L)	63	45	115	82	40	38
ESR (1-20 mm/h)	45	35	60	40	30	42
Procalcitonin (0-0.046 ng/ml)	0.8	0.5	1.3	0.6	0.048	0.6
Prealbumin (17-42 mg/dl)	52	48	55	50	45	46
Postoperative						
WBC (4-10 $10^9/L$)	8	6	9	7	5	8
CRP (0-5 mg/L)	10	12	7	4	5	8
ESR (1-20 mm/h)	15	15	10	5	10	8
Procalcitonin (0-0.046 ng/ml)	0.04	0.03	0.035	0.02	0.01	0.1
Prealbumin (17-42 mg/dl)	18	20	30	22	24	26

WBC: White blood cell, CRP: C reactive protein, ESR: Erythrocyte sedimentation rate, P: Patient.

classified based on their size as small (< 0.5 cm), intermediate (0.5 to 2.5 cm) or large (> 2.5 cm) RVF. While simple fistulas are smaller than 2.5 cm, those greater than 2.5 cm in size comprise the complex RVF [2, 3].

Acquired causes are thought to play a more important role in the development of RVF. Trauma associated with childbirth comprise the majority of the acquired causes of RVF [4, 5]. Also inflammatory bowel disease, or pelvic or anorectal surgery may play an etiological role. Among surgical interventions, RVF risk is particularly high in low anterior resection (LAR) for rectal cancer or ileo-anal anastomosis following colectomy [6]. In addition, external and/or intra-cavitary radiotherapy (RT) given after surgery in ano-rectal or pelvic malignancies increase the risk of RVF. Of these patients receiving RT, 0.3 to 6% have been reported to

develop subsequent RVF [7], most of which are complex in nature. Rate of spontaneous recovery in fistula developing subsequent to RT or cancer surgery is low [1, 5]. A rare cause of RVF is the prolonged pressure on recto-vaginal septum, leading to the development of RVF after necrosis [8].

A number of different therapeutic approaches may be used for the management of RVF depending on patients' condition. One such option is the use of temporary or permanent ostomy. In the treatment of high RVF, temporary ostomy is utilized therapeutically in 25% of the cases, while in the overall population of low RVF, the reported figure is 15% [8]. Although the decision to perform a permanent ostomy is challenging for both the patient and surgeon, it may be indispensable for the management of these patients. Herein, we present six patients with RVF where the indications of ostomy are discussed to emphasize its important role as an effective therapeutic option.

Material and methods

Six patients with RVF referred to the Erol Olçok Training and Research Hospital, Medical Faculty of Hitit University in 2015-2017 were included and their data were evaluated retrospectively. After detailed information provided to patients, written informed consent obtained. Local Ethics committee approved (2017/24).

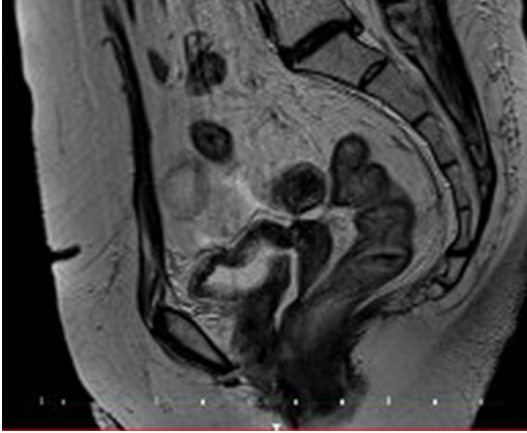


Figure 1. MRI findings of patient 1.

Demographic data, type of fistula, comorbid conditions, initial and subsequent surgery with their outcomes were reported (**Table 1**). Complete blood counts and routine biochemistry tests were also performed before and after ostomy to assess infectious processes (**Table 2**).

Results

These six patients described below:

Patient 1: A 62-year old female patient who had total abdominal hysterectomy and bilateral salpingo-oophorectomy (TAH + BSO) in another center followed by external and intra-cavitary RT. Transverse loop colostomy and left nephrostomy performed due to RVF and left-sided hydro nephrosis occurring after RF. Due to persistence of vaginal flatulence and fecal discharge, she referred to our clinic and consequently diagnosed as having a high complex RVF. Also she was found to have VVF, as documented by an intravenous pyelography (IVP) and cystography (**Figure 1**). A Hartmann colostomy and right nephrostomy were performed.

Patient 2: This 51-year old patient had undergone TAH + BSO in another center due to cervical cancer. She received external RT after surgery, after which she started to have complaints of vaginal flatulence and fecal discharge. She was referred to our unit for further management. RVF and VVF were detected after a diagnostic work-up. Permanent Hartmann colostomy and bilateral nephrostomy were carried out.

Patient 3: A 74 year old, paraplegic (due to lumbar discopathy), bed-ridden patient was

referred to our unit due to vaginal flatulence and fecal discharge. She was subsequently found to have low complex RVF. A sigmoid loop colostomy was performed for transient colonic diversion.

Patient 4: A 45-year old patient underwent LAR due to rectum cancer. Postoperatively, she had vaginal fecal discharge and flatulence and was diagnosed with simple high RVF. A loop ileostomy was performed for transient colonic diversion. Due to spontaneous healing of the RVF, the loop ileostomy was closed after one month.

Patient 5: A 45-year old patient underwent LAR due to rectum cancer. Postoperatively, she had vaginal fecal discharge and flatulence and was diagnosed with simple high RVF. A loop ileostomy was performed for transient colonic diversion. Due to spontaneous healing of the RVF, the loop ileostomy closed after one and a half month.

Patient 6: A 65 years old female underwent LAR due to rectum cancer. Postoperatively, she had vaginal fecal discharge and diagnosed with simple high RVF. A transient loop ileostomy performed for colonic diversion. Due to spontaneous healing of the RVF, the loop ileostomy closed after 8 weeks from surgery.

Discussion

RVF is defined as the presence of an abnormal epithelial connection between the rectum and vagina, and the primary etiological factors for its development include obstetric causes in the developing world, while cancer surgery and radiotherapy represent the leading causes in the developed countries [3, 5, 6]. In the present study, patient no 1 and 2 had RVF due to RT given for cancer treatment, while patients no 4, 5 and 6 had RVF after cancer surgery. Patient no 3 had chronic constipation resulting from paraplegia and the subsequent prolonged pressure on the recto-vaginal septum, giving rise to RVF.

Etiology and type of RVF are a major determinant of the treatment modality to be implemented. Since, increasing recurrence is associated with lower success rate of corrective surgery, adequate attention should be paid to timing of surgery as well as the meticulous surgical technique including proper wound care both before and after surgery for better surgical outcomes.

Rectovaginal fistula management

Before attempting definitive surgery, allowing a time period of approximately 6-months facilitates healing in tissues surrounding the fistula and may improve the results. Generally, a 2 to 3 year period is required before RVF becomes feasible for reconstruction after RT [7]. Also, this period is important for determining whether primary tumor is under control. Thus, during this period, appropriate supportive care should be provided to the patient and the therapeutic steps to be taken should be planned.

The principles of surgical treatment include complete excision of the fistula, followed by the tension-free suturing of opposing vagino-vaginal and recto-rectal tissues [1, 6, 9]. An adequate blood supply to reconstructed tissues is a prerequisite for successful outcomes. The main therapeutic options described in the literature include local repair, tissue transposition, and abdominal interventions [1, 3, 4]. Surgical approach may depend on the location of RVF. Accordingly, while high RVFs generally require an abdominal access, trans-anal and trans-rectal approaches may be used for low RVF. Surgeons involved in the management of these patients commonly practice shifting of a trans-anal mucosal flap [5, 10].

The primary objective of ostomy, a therapeutic modality in these patients, is to divert the feces from fistula site to achieve infection control. Complete diversion of feces is essential in ostomy procedures and ostomy closure should not be performed until complete healing occurs [7]. In patients with complicated RVF after cancer surgery, the choice of permanent ostomy should be based on the general condition and life expectancy of the patient. For the treatment of complex fistula due to RT, the defect may be closed using an adequately vascularized sigmoid colon patch and diversion ostomy may be performed. The reported success rates for this procedure is 95% [7]. Permanent Hartmann colostomy was performed in our patients no 1 and 2, due to the presence of comorbid VVF as well as the presence of cervical cancer, while the same procedure was applied in-patient no 2 due to the presence of lung metastases. Also, definitive surgery was planned after the completion of the recommended 2 to 3 year time period for RVFs due to RT during the follow up of these patients, provided that patients are healthy at the completion of this time window. In-patient no 3, colos-

tomy was not closed at the discretion of the patient, since she was bed-ridden and the temporary colostomy was able to provide better feces control, although RVF healing occurred. In patients, no 4, 5 and 5, RVF spontaneously healed after temporary ileostomy, with subsequent closure of ileostomy.

Temporary or permanent ostomy may be performed in order to prevent complications due to small or large intestine infection and intra-abdominal adhesions that may accompany RVF after RT. None of our patients had intestinal complications due to RT.

Uncontrolled septic foci results in the deterioration of general health in all patients with RVF. Particularly in patients scheduled for definitive therapy, this factor has a negative prognostic impact. In such cases, temporary or permanent ostomy provides a quick amelioration of the septic manifestations and initiates an anabolic process. In all patients presented herein, ostomy resulted in an improvement of infection markers (**Table 2**).

Reported risk factors for RVF include previous abdominal surgery, diabetes mellitus (DM), and hypertension [11]. Comorbid conditions in our cases included HT in-patient no 1, DM in-patient no 2, DM plus HT in-patient no 5, with all patients having a history of previous abdominal surgery, probably leading to increased RVF risk.

Conclusions

Management of patients with RVF poses many challenges for both the patient and the surgeon. An important principle to be followed is not to hasten the therapeutic process and to implement timely and adequate management options. Treatment extended over an adequate period of time increases the likelihood of success. In these patients, temporary or permanent ostomy may be performed to control infections, to manage fecal discharge in bed-ridden or demented patients, and to prevent complications arising from infections and adhesions of intestines after RT depending on the general wellbeing and life expectancy of the patients. Although the decision to choose permanent ostomy is not an easy task for both the patient and physician, it should be performed after adequate consultation with the patient, when needed.

Rectovaginal fistula management

Acknowledgements

No financial support was offered for the preparation of this manuscript. Also, the manuscript, including related data, figures and tables has not been previously published, and the manuscript is not under consideration elsewhere. All authors have read and approved of the manuscript being submitted.

Disclosure of conflict of interest

None.

Abbreviations

DM, Diabetes mellitus; HT, Hypertension; IVP, Intravenous pyelography; LAR, Low anterior resection; TAH + BSO, Hysterectomy and bilateral salphingo-oophorectomy; RT, Radiotherapy; RVF, Recto-vaginal fistula; VVF, Vesico-vaginal fistula.

Address correspondence to: Dr. Ibrahim Tayfun Sahiner, Assistant Professor of Surgery, Department of General Surgery, Hitit University School of Medicine, Bahçelievler Mahallesi, Çamlık Caddesi No. 2, Çorum 19030, Turkey. Tel: +90 364 223 03 00; +905058726576; Fax: +90 364 223 03 23; E-mail: tayfunsahiner@gmail.com

References

- [1] Corte H, Maggiori L, Treton X, Lefevre JH, Ferron M and Panis Y. Rectovaginal fistula: what is the optimal strategy? An analysis of 79 patients undergoing 286 procedures. *Ann Surg* 2015; 262: 855-860; discussion 860-851.
- [2] Devesa JM, Devesa M, Velasco GR, Vicente R, Garcia-Moreno F, Rey A, Lopez-Hervas P, Die J and Molina JM. Benign rectovaginal fistulas: management and results of a personal series. *Tech Coloproctol* 2007; 11: 128-134.
- [3] Lo TS, Huang YH, Dass AK, Karim N and Uy-Patrimonio MC. Rectovaginal fistula: twenty years of rectovaginal repair. *J Obstet Gynaecol Res* 2016; 42: 1361-1368.
- [4] Statescu G, Negura C and Cretiu L. Recto-vaginal fistula of obstetric origin - A surgical solution. *Chirurgia (Bucur)* 2016; 111: 532-534.
- [5] Tozer PJ, Balmforth D, Kayani B, Rahbour G, Hart AL and Phillips RK. Surgical management of rectovaginal fistula in a tertiary referral centre: many techniques are needed. *Colorectal Dis* 2013; 15: 871-877.
- [6] Gaertner WB, Madoff RD, Spencer MP, Mellgren A, Goldberg SM and Lowry AC. Results of combined medical and surgical treatment of recto-vaginal fistula in Crohn's disease. *Colorectal Dis* 2011; 13: 678-683.
- [7] Bricker EM, Johnston WD and Patwardhan RV. Repair of postirradiation damage to colorectum: a progress report. *Ann Surg* 1981; 193: 555-564.
- [8] Kelly J. Vesico-vaginal and recto-vaginal fistulae. *J Obstet Gynaecol* 1998; 18: 249-251.
- [9] Mege D, Frasson M, Maggiori L and Panis Y. Is biological mesh interposition a valid option for complex or recurrent rectovaginal fistula? *Colorectal Dis* 2016; 18: 061-65.
- [10] Chen W, Chen X, Lin G and Qiu H. Successful repair of recurrent rectovaginal fistula by stratified suture using transanal endoscopic microsurgery: a CARE-compliant case report. *Medicine (Baltimore)* 2016; 95: e4600.
- [11] Pinto RA, Peterson TV, Shawki S, Davila GW and Wexner SD. Are there predictors of outcome following rectovaginal fistula repair? *Dis Colon Rectum* 2010; 53: 1240-1247.