

Case Report

Sarcoidosis of mediastinal lymph nodes mimicking distant metastasis of oral squamous cell carcinoma: a case report and review of literature

Tessho Maruyama^{1,2}, Masanao Saio^{3,4}, Akira Arasaki^{1,2}, Toshiyuki Nakasone², Takao Teruya⁵, Shusaku Haranaga⁶, Fumikazu Nimura¹, Toshihiro Kawano², Akira Matayoshi², Naoki Yoshimi³, Yukio Kuniyoshi⁷, Jiro Fujita⁶, Kazuhide Nishihara^{1,2}

Departments of ¹Oral and Maxillofacial Functional Rehabilitation, ⁴Pathology and Oncology, ⁷Thoracic and Cardiovascular Surgery, Graduate School of Medicine, University of the Ryukyus, Nishihara, Okinawa, Japan; Departments of ²Oral and Maxillofacial Surgery, ³Pathology, ⁵Thoracic and Cardiovascular Surgery, University Hospital of the Ryukyus, Nishihara, Okinawa, Japan; ⁶Department of Infectious Diseases, Respiratory and Digestive Medicine (The First Department of Internal Medicine), Graduate School of Medicine, University of the Ryukyus, Nishihara, Okinawa, Japan

Received March 23, 2017; Accepted December 23, 2017; Epub March 15, 2018; Published March 30, 2018

Abstract: Sarcoidosis is a systemic, chronic inflammatory disease with unknown cause and is characterized by formation of epithelioid granulomas in various organs, mainly the lungs and lymphatic system as mediastinal lymph nodes (LNs). Lymphadenopathy is common in sarcoidosis. Subsequent cancer also tends to occur in patients with the disease, and the most frequent is lymphoma and cancer of the lung. Head and neck cancer is uncommon but possible. We report a 70-year-old woman with squamous cell carcinoma (SCC) of the mandibular gingiva concomitant with mediastinal multiple lymphadenopathy, and a medical history of chronic sarcoidosis. Mediastinal LNs showed increased uptake of 2-[¹⁸F]-fluoro-2-deoxy-D-glucose (FDG) with positron emission tomography (PET). Subsequent to lymphadenectomy, the histological diagnosis was lymphadenopathy caused by sarcoidosis. Next, we performed wide local excision of the gingival tumor. During follow-up, a pulmonary lesion was detected by computed tomography at 3 years and 11 months after surgery, and diagnosed as pulmonary sarcoidosis, which had been stable without treatment until now. After follow-up of 5 years, the patient was alive without signs of local recurrence or metastasis. The combination of oral SCC and sarcoidosis of the mediastinal LNs in a sarcoidosis patient has not been previously reported. FDG-PET was not able to distinguish LN metastasis from lymphadenopathy caused by sarcoidosis. In our case, her chronic inflammatory condition with sarcoidosis as well as ill-fitting dentures could have increased the risk of oral cancer. We suggest that clinicians should carefully check for the development of subsequent oral cancer in patients with a past history of sarcoidosis. To avoid inaccurate staging and incorrect therapy, LN biopsy should be promptly performed following a diagnosis of cancer and multiple lymphadenopathies in patients with a history of sarcoidosis. Lymphadenopathy with sarcoidosis patients have malignant potential, especially those who develop subsequent cancer. Misdiagnosis of LN malignancy and sarcoidosis may lead to unnecessary adjuvant therapy or worse prognosis.

Keywords: Sarcoidosis, subsequent cancer, lymphadenopathy, head and neck cancer, oral cavity, distant metastasis, biopsy

Introduction

Sarcoidosis is a systemic, chronic inflammatory disease of unknown cause. The disease is characterized by formation of epithelioid granulomas in various organs; mainly the lungs and lymphatic system, such as the mediastinal

lymph nodes (LNs) [1, 2]. Lymphadenopathy is common in sarcoidosis. The first description of sarcoidosis was by Hutchinson in 1875 [3]. Sarcoidosis is a global disease with a prevalence of 4.7-64 in 100 000 and incidence of 1.0-35.5 in 100 000 annually [1]. Although sarcoidosis is a rare disease, clinicians sometimes

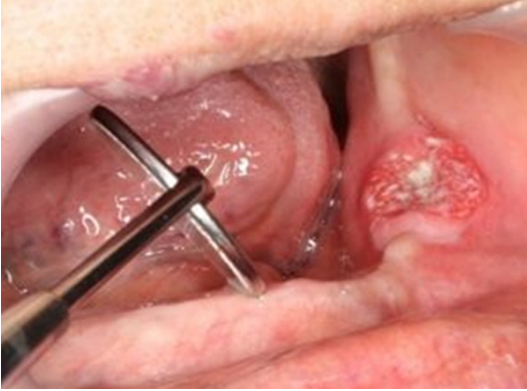

Figure 1. Physical examination revealed an elastic, hard, 2.2×1.1-cm mass with an ulcer of the left mandibular gingiva.

encounter patients with a history of the condition in daily clinical practice [4, 5].

A major complication of sarcoidosis is subsequent cancer, which tends to occur at a high frequency in patients with sarcoidosis [6-22]; most frequently, lymphoma [4, 6, 7, 9, 12, 16, 17, 19, 21] and cancer of the lung [8, 9, 12, 22], skin [4, 6, 9, 13], colorectum [4, 10, 11], kidney [6, 10], and liver [4, 9]. In contrast, head and neck cancer is uncommon [6, 7, 9, 12]. Reports of distant metastases or second primary cancer in patients with head and neck cancer have been increasingly reported owing to recent progress in diagnostic radiography. 2-[¹⁸F]-fluoro-2-deoxy-D-glucose positron emission tomography (FDG-PET) is usually used to identify distant metastases or second primary cancer [23].

We report a patient with synchronous squamous cell carcinoma (SCC) of the mandibular gingiva and multiple mediastinal lymphadenopathy of sarcoidosis. She also had a past history of chronic systemic sarcoidosis of the eye, skin, and liver. We could not establish by FDG-PET whether the lymphadenopathy resulted from malignancy (metastasis or second primary cancer), sarcoidosis, or any other clinical findings.

Case report

Written informed consent was obtained from the patient for publication of this case report. A 70-year-old woman was referred to our hospital for further evaluation of an oral mass. She had a 2-month history of pain involving the oral cav-

ity. Physical examination revealed an elastic, hard, 2.2×1.1-cm mass with an ulcer of the left gingiva (**Figure 1**). There was no lymphadenopathy in the head and neck region. Ten years prior, she was diagnosed as having sarcoidosis of the eye, skin and liver, which remained stable and chronic. Therefore, the lesion received no medical treatment. Her mandibular denture was ill fitting. Adenomatous goiter was diagnosed previously, which was also stable. She had no history of smoking or alcohol consumption. To detect other lesions, contrast-enhanced computed tomography (CT) of the head and neck, chest and liver were performed. CT showed neither invasive bone lesion in the gingival mass nor any lesions in the cervical LNs, lungs, bone, or liver; however, multiple LN swelling was detected in the mediastinal area (**Figure 2A**). The gingival mass was clinically suspicious for cancer, whereas radiographic diagnosis of the mediastinal lesion was sarcoidosis because there was no cervical lymphadenopathy (regional LNs of gingival cancer), and she had a past history of chronic systemic sarcoidosis. Gingival mass biopsy was performed and SCC was confirmed. Upper gastrointestinal examination revealed no abnormalities. Whole-body FDG-PET was used to detect the mediastinal or any other lesions. FDG-PET showed increased FDG uptake in the left mandible [maximum standardized uptake value (SUVmax)=7.6], and the multiple mediastinal and right supraclavicular LNs had SUVmax=4.9 (**Figure 3**). In contrast, no FDG uptake was seen in the cervical or any other LNs. Thus, FDG-PET could not distinguish clearly between cancer metastasis and sarcoidosis. Gingival cancer was treated with neoadjuvant chemotherapy (90 mg total bleomycin plus 300 mg/day uracil/tegafur). A second CT scan after preoperative chemotherapy showed no effect on mediastinal or supraclavicular LN lesions (**Figure 2B**). It was necessary to determine whether the mediastinal lesions were metastases to assign a clinical stage and make a treatment plan.

To diagnose lymphadenopathy, the patient underwent mediastinal LN sampling with video-assisted thoracic surgery. Histopathological findings revealed noncaseating epithelioid granulomas. Advanced fibrosis and scar tissues were also observed but there was no evidence of malignancy (**Figure 4**). Therefore, pathologically, sarcoidosis was suspected.

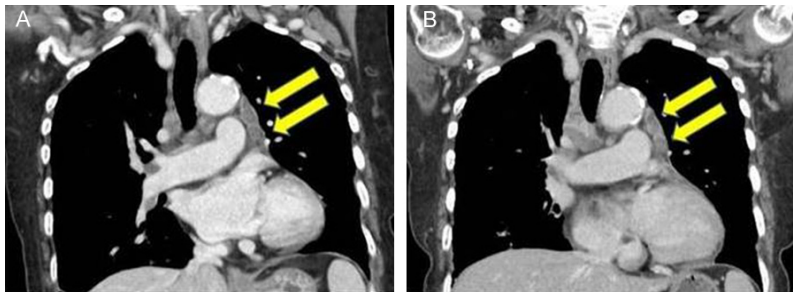


Figure 2. A. Initial CT radiograph (coronal sections) showing involvement of multiple lymph nodes in the mediastinal area (arrows); B. Second CT radiograph performed after completion of chemotherapy before the operation showing no effect on mediastinal LN lesions (arrows).

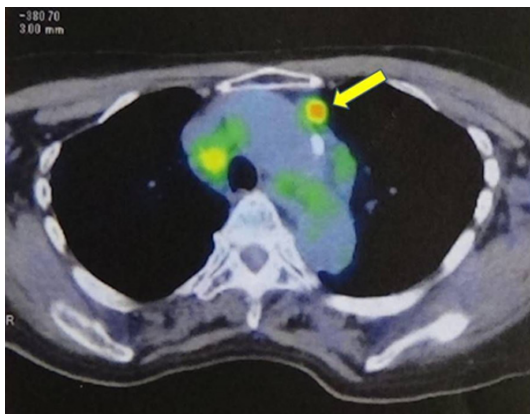


Figure 3. FDG-PET (axial section) for initial staging before treatment showing increased FDG uptake in the multiple mediastinal lymph nodes (SUVmax=4.9) (arrow). In contrast, no FDG uptake was seen in the cervical or any other LNs. FDG-PET did not afford a clear distinction between metastatic lesions and sarcoidosis.

According to the above pathological assessment, we finally diagnosed gingival SCC (T2NOMO, Stage II) (UICC TNM classification 7th edition, 2009). After that, we performed wide local excision of the gingival tumor. Histopathological examination revealed residual SCC after chemotherapy (**Figure 5**). Although chemotherapy for oral cancer was performed, the size of the residual mediastinal and right supraclavicular LNs evaluated by CT remained stable. During follow-up of cancer, a pulmonary lesion was detected by CT at 3 years and 11 months after surgery, which we diagnosed as pulmonary sarcoidosis. We looked at the natural history of the lesion (without therapy), and found that its size had not changed until the time of writing this report. After follow-up of 5 years, the patient was alive and well with no evi-

dence of cancer recurrence or metastatic disease.

Discussion

Through our case, two important clinical issues were found. This combination of lesions, namely oral SCC and sarcoidosis of the mediastinal LNs in a patient with sarcoidosis, has not been reported to date. To avoid inaccurate staging and therapy, we suggest

that LN biopsy should be performed promptly for patients with a history of sarcoidosis, when one encounters cancer and multiple lymphadenopathies.

First, regarding the fact that this combination of lesions has not been reported to date. Some reports state that the risk of upper digestive tract or head and neck cancer increases in sarcoidosis patients [4, 9, 11, 22, 24]. We searched the literature from 1875 to 2016 using PubMed and Google Scholar and found 15 patients with sarcoidosis followed by head and neck cancer, including the current case (**Table 1**) [9, 11, 22, 24-32], but found no report of the same combination with our case. Exclusion criteria were: (1) non-English full text; and (2) diagnosis of cancer preceding or synchronous with the diagnosis of sarcoidosis [4] (including sarcoid-like reaction [33]). We believe that our patient had two risk factors that contributed to development of oral cancer, that is, wearing dentures [34] and past history of sarcoidosis [4, 9, 11, 12, 22, 24]. Both factors are associated with inflammation. We would thus like to describe the potential of oral cancer development in sarcoidosis patients associated with denture use, especially ill-fitting dentures. The meta-analysis of Manoharan and colleagues [35] reports that the use of dentures by itself carries a risk of developing oral cancer (odds ratio: 1.42, 95% confidence interval: 1.01-1.99). Moreover, using ill-fitting dentures increases substantially the risk of oral cancer (odds ratio: 3.90, 95% confidence interval: 2.48-6.13) [35]. Denture use, especially, ill-fitting dentures, can lead to oral mucosal injury with inflammation and ulcer, which is an important risk factor for oral cancer [36, 37]. Furthermore, chronic inflammation is

Sarcoidosis mimicking distant metastasis of oral cancer

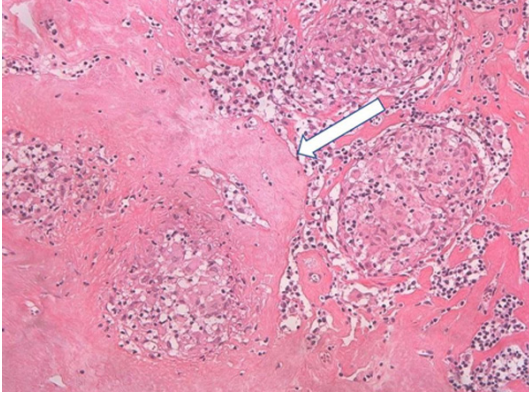


Figure 4. Histopathological examination of mediastinal lymph node specimen for diagnosis before oral cancer treatment to determine whether the lesion was tumor metastasis or another lesion. The lesion showed noncaseating granulomas with epithelioid cells. Extensive fibrosis and scar tissues are also seen; no tumor cells were observed (original magnification, 200×). Histopathology was consistent with lymphadenopathy caused by sarcoidosis.

associated with the development of malignancy [38, 39].

Several mechanisms have been proposed to explain the increased risk of hematological or solid cancer in patients with sarcoidosis [4, 6-12, 26, 28, 33, 40-43]. Sarcoidosis is a chronic inflammatory disease. Subsequent solid cancers have been found in various sites in patients with sarcoidosis [4], such as the lung [8, 9, 12, 22], skin [4, 6, 9, 13], colorectum [4, 10, 11], kidney [6, 10], and liver [4, 9]. Head and neck cancer is uncommon but possible; however, we could not find any report about the additive effect of sarcoidosis and denture use on cancer risk. In fact, our patient had no sarcoid lesion in the oral cavity clinically, and the surrounding gingival cancer mass did not have any sarcoid lesion pathologically, although she had mediastinal lymphadenopathy caused by sarcoidosis. Therefore, our case suggests that there is no direct additive effect of ill-fitting dentures and sarcoidosis, but rather, the two conditions independently affect oral cancer development. Matsubara and colleagues reported a case of gastric cancer, which may have developed during gastric sarcoidosis [44]. The gastric cancer was histologically diagnosed after a 10-year history of the treatment of gastric sarcoidosis [44]. They speculated that the gastric mucosal damage and regeneration,

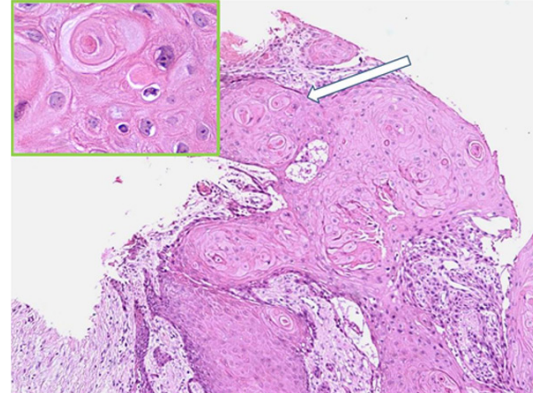


Figure 5. Histopathological findings of surgically resected gingival tumor post-chemotherapy. Atypical squamous epithelium showing cancer pearl formation with irregular infiltration of epithelium into stroma (100×), which showed characteristics of well-differentiated squamous cell carcinoma. Original magnification, 100×, inset 400×. Magnified view of cancer component indicated by arrow, in which irregular nuclei of various sizes and density were observed. These cells also showed features of carcinoma cells. Thus, we diagnosed gingival squamous cell carcinoma (T2N0M0, Stage II).

caused by sarcoidosis chronic inflammation, might be the underlying cause of carcinogenesis [44]. They also suggested that chronic inflammation of sarcoidosis is a putative carcinogenesis mediator in many kinds of tissue including lymph tissue [44].

The second important clinical issue is that, to avoid inaccurate staging and therapy, LN biopsy should be performed promptly without hesitation when one encounters cancer and multiple lymphadenopathies in patients with a history of sarcoidosis. New or enlarging lesions in sarcoidosis patients should be considered for biopsy to distinguish them from coexisting malignant tumor [43, 45]. Like our case, it is important for clinicians to distinguish sarcoidosis from the following four lesions. First, isolated distant metastasis or second primary cancer can occur without cervical LN metastasis in head and neck cancer [46-48]. Second, coexistence of metastatic involvement and sarcoidosis lesion in the same LN has been reported [31, 49, 50]. Third, lymphoma should be looked for because it tends to occur in sarcoidosis patients [4, 6, 7, 9, 12, 16, 17, 19, 21], especially as sarcoidosis-lymphoma syndrome [51]. Fourth, as described above, cancer itself may develop into LN sarcoidosis [44], i.e.,

Sarcoidosis mimicking distant metastasis of oral cancer

Table 1. Summary of published literature related to occurrence of head and neck cancers in known cases of sarcoidosis

Author/references	Age (yr)	Gender	Cancer site	Type of cancer	Site affected by SA	Methods used for diagnosis of SA	Outcome
Pollock & Catalano (1979) [29]	38	M	Parotid gland	Ductal carcinoma	Hilar LN	LN biopsy	NA
Seersholm et al. (1997) [22]	NA	NA	Brain, lip, pharynx	NA	NA	NA	NA
Rømer et al. (1998) [24]	NA	NA	Lip, mouth	NA	NA	NA	NA
Askling et al. (1999) [9]	NA	NA	Nose, mouth, eye	NA	NA	NA	NA
Zimmermann-Belsing et al. (2000) [31]	27	F	Thyroid	Papillary adenocarcinoma	Hilar LN	Transbronchoscopy LN	5 years after medication, alive with chronic SA
Bruins et al. (2007) [27]	35	F	Thyroid	Papillary carcinoma	Skin, lung, thyroid	NA	NA
Shu et al. (2011) [28]	NA	NA	Upper aerodigestive tract, eye, nose, salivary gland, thyroid gland, nervous system	NA	NA	NA	NA
Vorselaars et al. (2013) [30]	54	F	Larynx (Bilateral vocal cords)	SCC	Lung, extra-thoracic LN	NA	6 months after SA treatment, alive with pulmonary SA
Ergin & Nasr (2014) [25]	48	F	Thyroid	Papillary carcinoma	Lung, lacrimal gland, skin	NA	NA
Myint & Chow (2015) [26]	68	F	Thyroid	Papillary carcinoma	Mediastinal LN	Excisional LN biopsy	Alive with no recurrence
Søgaard et al. (2015) [11]	NA	NA	Tonsil, brain	NA	NA	NA	NA
Ungprasert et al. (2017) [32]	NA	NA	NA	NA	NA	NA	NA
	NA	NA	NA	NA	NA	NA	NA
	NA	NA	NA	NA	NA	NA	NA
Present case	70	F	Mandibular gingiva	SCC	Mediastinal LN	VATS	4 years after medication, alive with no recurrence

F, female; LN, lymph node; M, male; NA, not available; SA, sarcoidosis; SCC, Squamous cell carcinoma; VATS, video-assisted thoracic surgery.

Sarcoidosis mimicking distant metastasis of oral cancer

Table 2. Indications for LN biopsy for lymphadenopathy of concomitant subsequent (or suspected) cancer in patients with SA

Clinical scenario where LN biopsy may be particularly helpful	Scenarios where LN biopsy may not be required
When lymphadenopathy develops without regional lymph nodes of cancer, to rule out isolated distant metastatic lesions or a second primary cancer, which can occur without RR. [46-48]	When lymphadenopathy develops without regional lymph nodes of cancer, distant metastasis in the absence of RR is rare.
To rule out coexistence of metastatic involvement and SA lesion in the same LN. [31, 49, 50]	Lymphadenopathy is a typical finding in patients with SA. [2]
To rule out lymphoma (SA-lymphoma syndrome). [4, 6, 7, 9, 12, 16, 17, 19, 21]	Elderly patients or those in poor general condition because of the invasive nature of LN biopsy. [53]
Cancer may develop into LN sarcoidosis. [44]	
To facilitate accurate cancer staging.	
Situations where the differential diagnosis between involvement of SA and malignancy is not straightforward on the basis of clinical and radiological workup (including with FDG-PET or fine-needle aspiration biopsy). [56, 72-74]	
No reliable diagnostic, prognostic or therapeutic biomarkers are currently available. [57]	

LN, lymph node; SA, sarcoidosis; RR, regional recurrence.

lymphadenopathy with sarcoidosis patients have malignant potential, especially those who develop subsequent cancer. Similar kinds of cases (where cancer itself may have developed into sarcoidosis) have been reported [31, 52]. We initially thought that mediastinal lymphadenopathy was caused by sarcoidosis because there was no cervical lymphadenopathy (regional LNs of oral cancer); distant metastasis in the absence of regional LN involvement (NOM1) is rare; and multiple mediastinal lymphadenopathies are typical lesions of sarcoidosis [2]. However, eventually we performed mediastinal lymphadenectomy in our patient because PET revealed marked FDG uptake in the mediastinal LNs. Sarcoidosis can occur anywhere in the body and can mimic benign or malignant tumors [2], as well as recurrence or metastatic lesions in cancer patients [26].

Mediastinal lesion biopsy is considered to be invasive and might place an excessive burden on elderly patients such as ours [53]; however, to diagnose mediastinal sarcoidosis accurately, biopsy with lymphadenectomy has good diagnostic value. Even though sarcoidosis lesions are systemic, swollen mediastinal LNs should be submitted to pathological diagnosis. The presence of malignant LN lesions profoundly influences the treatment options with cancer staging, therefore, accurate detection of LN malignancy is important [54]. Distant metastasis is an important factor in the treatment of head and neck cancer. Commonly, sarcoidosis is diagnosed based on clinical and radiological findings [1, 55]. However, it is difficult to distinguish between involvement of sarcoidosis and malignancy by clinical and radiological examination of lesions, including with FDG-PET, and histological examination with LN biopsy is needed when this association is suspected [56].

No reliable diagnostic, prognostic or therapeutic biomarkers are currently of assistance in managing patients with sarcoidosis [57]. PET revealed marked FDG uptake in the mediastinal lymphadenopathy. FDG-PET has been widely used in cancer management, based on the increased consumption of glucose by malignant cells [58]. However, FDG accumulates not only in malignant tissues, but also in infected and inflammatory tissues, which makes FDG-PET less specific [51]. Thus, benign hypermeta-

bolic lymphadenopathy can imitate malignant disease on PET [59-62]. SUVmax is the most commonly used value to measure metabolic tumor activity in oncological FDG-PET/CT imaging [59]. Kumar and colleagues [63] performed a prospective observational study and reported that an SUVmax cutoff value of 2.5 had low specificity to distinguish between benign and malignant mediastinal lymphadenopathy. They suggested using a cutoff value of 6.2, because the value improved the specificity while maintaining acceptable levels of sensitivity [63]. In our case, it was possible to distinguish sarcoidosis and malignancy using the method of Kumar and colleagues [63]. FDG uptake in the left mandibular SCC and multiple mediastinal LNs had SUVmax=7.6 and 4.9, respectively (**Figure 3**). However, Koo and colleagues [59] reported that the median SUVmax of sarcoidosis LNs was 8.2 (range, 2.2-16.5) in the pathological results of mediastinal and hilar LNs of 152 patients. LNs with SUVmax >4.5 were confirmed as metastases by pathological examination [64]. To date, SUVmax cutoff value is controversial in clinical practice. There are many reports that FDG-PET is not helpful for distinguishing sarcoidosis and malignancy [51, 59, 60, 65]. Furthermore, sarcoidosis and malignancy tend to coexist as mentioned above. Therefore, it is difficult to discriminate between cancer and sarcoidosis with clinical and radiological evaluation, including PET [26, 66].

CT scan may not be useful for distinguishing sarcoidosis and malignancy [55, 60]. In our case, the mediastinal LNs were not affected by neoadjuvant chemotherapy for gingival cancer [54]. After preoperative chemotherapy, the second preoperative CT scan revealed that lymphadenopathy had not shrunk compared with initial CT before chemotherapy. Thus, we initially thought that the LN lesions were not malignant; however, confirming shrinkage or swelling of LNs in response to neoadjuvant chemotherapy is not adequate to diagnose metastasis or sarcoidosis. Sarcoid lesions have been reported after chemotherapy for malignant tumors [67-69]. Chemotherapy also causes fluctuations in serum cytokine levels, and cytokines have an important part to play in granuloma formation such as sarcoidosis [70]. It is not sufficient to distinguish disseminated malignancy from sarcoidosis or sarcoid reactions after antineoplastic therapy with the type of preceding malignan-

cy or antineoplastic therapy, as well as the time after completion of therapy [58]. In magnetic resonance imaging or ultrasound examination, sarcoidosis also mimics malignancy [71].

As already stated, it is difficult to distinguish between involvement of sarcoidosis and malignancy by clinical and radiological examination of lesions, including with FDG-PET, and histological examination with LN biopsy is needed when this association is suspected [56]. Therefore, it needs to be examined histopathologically to make a definitive diagnosis [26, 57]. Fine-needle aspiration biopsy may also be inaccurate [71-73]. Koo and colleagues [59] reported that it is inadequate to distinguish sarcoidosis from the possibility of coexisting cancer via transbronchial needle aspiration. As described above, coexistence of metastatic involvement and sarcoidosis lesions in the same LN has been reported [31, 49, 50]. Because of the potential existence of two lesions, we suggest that not only a part of the LN but also the whole lymph node should be examined histologically. Therefore, to diagnose mediastinal sarcoidosis, biopsy with lymphadenectomy is indicated [72, 74]. As described above, although sarcoidosis is a rare disease, clinicians sometimes encounter patients with a history of the condition in daily clinical practice [4, 5]. It is important to note that sarcoidosis patients tend to develop both lymphadenopathy and subsequent cancer. Clinical scenarios where LN biopsy is justifiable in patients with sarcoidosis and subsequent cancer are summarized in **Table 2**. As indicated in **Table 2**, LN biopsy is suitable.

Combination of the oral SCC and sarcoidosis of the mediastinal LNs in a sarcoidosis patient has not been previously reported. In our case, a chronic inflammatory condition with sarcoidosis and ill-fitting dentures may have increased the risk of oral cancer. Therefore, if patients have a history of sarcoidosis, we should carefully observe the oral region to check on the development of cancer. To avoid inaccurate staging and incorrect therapy, we suggest that LN biopsy should be performed promptly when one encounters subsequent cancer and multiple lymphadenopathies in patients with a history of sarcoidosis. This is important because lymphadenopathy with sarcoidosis patients have malignant potential, especially those who have subsequent cancer. Misdiagnosis of LN

malignancy and sarcoidosis may lead to unnecessary adjuvant therapy or worse prognosis.

Acknowledgements

No funding source supported this case report. We thank the staff of the Division of Endocrinology, Diabetes and Metabolism, Hematology, Rheumatology (Second Department of Medicine), Graduate School of Medicine, University of the Ryukyus (Japan) who contributed to patient diagnosis by excluding malignant lymphoma.

Disclosure of conflict of interest

None.

Address correspondence to: Akira Arasaki, Department of Oral and Maxillofacial Functional Rehabilitation, Graduate School of Medicine, University of the Ryukyus, 207 Uehara, Nishihara, Okinawa 903-0215, Japan. Tel: +81 98 895 1192; Fax: +81 98 895 1431; E-mail: arasaki@med.u-ryukyu.ac.jp

References

- [1] Valeyre D, Prasse A, Nunes H, Uzunhan Y, Brilliet PY and Müller-Quernheim J. Sarcoidosis. *Lancet* 2014; 383: 1155-1167.
- [2] Powell JL, Cunill ES, Gajewski WH and Novotny DB. Sarcoidosis mimicking recurrent endometrial cancer. *Gynecol Oncol* 2005; 99: 770-773.
- [3] Hutchinson JA. *Illustrations of clinical surgery*. Volume 2. London: J. & A. Churchill; 1875.
- [4] Bonifazi M, Bravi F, Gasparini S, La Vecchia C, Gabrielli A, Wells AU and Renzoni EA. Sarcoidosis and cancer risk: systematic review and meta-analysis of observational studies. *Chest* 2015; 147: 778-791.
- [5] Chopra A and Judson MA. How are cancer and connective tissue diseases related to sarcoidosis? *Curr Opin Pulm Med* 2015; 21: 517-524.
- [6] Ji J, Shu X, Li X, Sundquist K, Sundquist J and Hemminki K. Cancer risk in hospitalized sarcoidosis patients: a follow-up study in Sweden. *Ann Oncol* 2009; 20: 1121-1126.
- [7] Brincker H and Wilbek E. The incidence of malignant tumours in patients with respiratory sarcoidosis. *Br J Cancer* 1974; 29: 247-251.
- [8] Yamaguchi M, Odaka M, Hosoda Y, Iwai K and Tachibana T. Excess death of lung cancer among sarcoidosis patients. *Sarcoidosis* 1991; 8: 51-55.
- [9] Askling J, Grunewald J, Eklund A, Hillerdal G and Ekblom A. Increased risk for cancer follow-

Sarcoidosis mimicking distant metastasis of oral cancer

- ing sarcoidosis. *Am J Respir Crit Care Med* 1999; 160: 1668-1672.
- [10] Boffetta P, Rabkin CS and Gridley G. A cohort study of cancer among sarcoidosis patients. *Int J Cancer* 2009; 124: 2697-2700.
- [11] Sogaard KK, Sværke C, Thomsen RW and Nørgaard M. Sarcoidosis and subsequent cancer risk: a Danish nationwide cohort study. *Eur Respir J* 2015; 45: 269-272.
- [12] Brincker H. Coexistence of sarcoidosis and malignant disease: causality or coincidence? *Sarcoidosis* 1989; 6: 31-43.
- [13] Le Jeune I, Gribbin J, West J, Smith C, Cullinan P and Hubbard R. The incidence of cancer in patients with idiopathic pulmonary fibrosis and sarcoidosis in the UK. *Respir Med* 2007; 101: 2534-2540.
- [14] Lower EE, Hawkins HH and Baughman RP. Breast disease in sarcoidosis. *Sarcoidosis Vasc Diffuse Lung Dis* 2001; 18: 301-306.
- [15] Brincker H. The malignancy-sarcoidosis syndrome. *Chest* 1991; 100: 1184.
- [16] Landgren O, Engels EA, Pfeiffer RM, Gridley G, Mellemkjaer L, Olsen JH, Kerstann KF, Wheeler W, Hemminki K, Linet MS and Goldin LR. Autoimmunity and susceptibility to Hodgkin lymphoma: a population-based case-control study in Scandinavia. *J Natl Cancer Inst* 2006; 98: 1321-1330.
- [17] Mellemkjaer L, Pfeiffer RM, Engels EA, Gridley G, Wheeler W, Hemminki K, Olsen JH, Dreyer L, Linet MS, Goldin LR and Landgren O. Autoimmune disease in individuals and close family members and susceptibility to non-Hodgkin's lymphoma. *Arthritis Rheum* 2008; 58: 657-666.
- [18] Kristinsson SY, Landgren O, Sjöberg J, Turesson I, Björkholm M and Goldin LR. Autoimmunity and risk for Hodgkin's lymphoma by subtype. *Haematologica* 2009; 94: 1468-1469.
- [19] Anderson LA and Engels EA. Autoimmune conditions and hairy cell leukemia: an exploratory case-control study. *J Hematol Oncol* 2010; 3: 35.
- [20] Hemminki K, Liu X, Ji J, Försti A, Sundquist J and Sundquist K. Effect of autoimmune diseases on risk and survival in female cancers. *Gynecol Oncol* 2012; 127: 180-185.
- [21] Smedby KE, Hjalgrim H, Askling J, Chang ET, Gregersen H, Porwit-MacDonald A, Sundström C, Akerman M, Melbye M, Glimelius B and Adami HO. Autoimmune and chronic inflammatory disorders and risk of non-Hodgkin lymphoma by subtype. *J Natl Cancer Inst* 2006; 98: 51-60.
- [22] Seersholm N, Vestbo J and Viskum K. Risk of malignant neoplasms in patients with pulmonary sarcoidosis. *Thorax* 1997; 52: 892-894.
- [23] Haerle SK, Schmid DT, Ahmad N, Hany TF and Stoeckli SJ. The value of (18)F-FDG PET/CT for the detection of distant metastases in high-risk patients with head and neck squamous cell carcinoma. *Oral Oncol* 2011; 47: 653-659.
- [24] Rømer FK, Hommelgaard P and Schou G. Sarcoidosis and cancer revisited: a long-term follow-up study of 555 Danish sarcoidosis patients. *Eur Respir J* 1998; 12: 906-912.
- [25] Ergin AB and Nasr CE. Thyroid cancer & sarcoidosis. *Sarcoidosis Vasc Diffuse Lung Dis* 2014; 31: 239-243.
- [26] Myint ZW and Chow RD. Sarcoidosis mimicking metastatic thyroid cancer following radioactive iodine therapy. *J Community Hosp Intern Med Perspect* 2015; 5: 26360.
- [27] Bruins NA, Oswald JE, Morreau H, Kievit J, Pavel S and Smelt AH. Papillary thyroid carcinoma in a patient with sarcoidosis treated with minocycline. *Neth J Med* 2007; 65: 185-187.
- [28] Shu X, Ji J, Sundquist K, Sundquist J and Hemminki K. Survival in cancer patients with previous hospitalization for sarcoidosis: a Swedish population-based cohort study during 1964-2006. *Ann Oncol* 2011; 22: 1427-1434.
- [29] Pollock JL and Catalano E. Metastatic ductal carcinoma of the parotid gland in a patient with sarcoidosis. *Arch Dermatol* 1979; 115: 1098-1099.
- [30] Vorselaars AD, Sjögren EV, van Moorsel CH and Grutters JC. Bilateral vocal cord carcinoma in a sarcoidosis patient during infliximab therapy. *Case Rep Pulmonol* 2013; 2013: 308092.
- [31] Zimmermann-Belsing T, Christensen L, Hansen HS, Kirkegaard J, Blichert-Toft M and Feldt-Rasmussen U. A case of sarcoidosis and sarcoid granuloma, papillary carcinoma, and Graves' disease in the thyroid gland. *Thyroid* 2000; 10: 275-278.
- [32] Ungprasert P, Crowson CS and Matteson EL. Risk of malignancy among patients with sarcoidosis: a population-based cohort study. *Arthritis Care Res (Hoboken)* 2017; 69: 46-50.
- [33] Cohen PR and Kurzrock R. Sarcoidosis and malignancy. *Clin Dermatol* 2007; 25: 326-333.
- [34] Gorsky M and Silverman S. Denture wearing and oral cancer. *J Prosthet Dent* 1984; 52: 164-166.
- [35] Manoharan S, Nagaraja V and Eslick GD. Ill-fitting dentures and oral cancer: a meta-analysis. *Oral Oncol* 2014; 50: 1058-1061.
- [36] Piemonte ED, Lazos JP and Brunotto M. Relationship between chronic trauma of the oral mucosa, oral potentially malignant disorders and oral cancer. *J Oral Pathol Med* 2010; 39: 513-517.
- [37] Kundu JK and Surh YJ. Inflammation: gearing the journey to cancer. *Mutat Res* 2008; 659: 15-30.
- [38] Franks AL and Slansky JE. Multiple associations between a broad spectrum of autoimmune diseases, chronic inflammatory diseases

Sarcoidosis mimicking distant metastasis of oral cancer

- es and cancer. *Anticancer Res* 2012; 32: 1119-1136.
- [39] Tana C, Giamberardino MA, Di Gioacchino M, Mezzetti A and Schiavone C. Immunopathogenesis of sarcoidosis and risk of malignancy: a lost truth? *Int J Immunopathol Pharmacol* 2013; 26: 305-313.
- [40] Beutler BD and Cohen PR. Sarcoidosis in melanoma patients: case report and literature review. *Cancers (Basel)* 2015; 7: 1005-1021.
- [41] Jiao Y, Ning J, Zhao WD, Li YL, Wu HY and Gu KS. Sarcoidosis in gastric cancer at the time of diagnosis: a case report. *Oncol Lett* 2015; 9: 1159-1162.
- [42] Lequoy M, Coriat R, Rouquette A, Mir O, Perkins G, Regnard JF, Brezault C and Chaussade S. Sarcoidosis lung nodules in colorectal cancer follow-up: sarcoidosis or not? *Am J Med* 2013; 26: 642-645.
- [43] Caras WE, Dillard T, Baker T and Pluss J. Coexistence of sarcoidosis and malignancy. *South Med J* 2003; 96: 918-922.
- [44] Matsubara T, Hirahara N, Hyakudomi R, Fujii Y, Kaji S, Taniura T and Tajima Y. Early gastric cancer associated with gastric sarcoidosis. *Int Surg* 2015; 100: 949-953.
- [45] Yamasawa H, Ishii Y and Kitamura S. Concurrency of sarcoidosis and lung cancer. A report of four cases. *Respiration* 2000; 67: 90-93.
- [46] Lim JY, Lim YC, Kim SH, Kim JW, Jeong HM and Choi EC. Predictive factors of isolated distant metastasis after primary definitive surgery without systemic treatment for head and neck squamous cell carcinoma. *Oral Oncol* 2010; 46: 504-508.
- [47] Takes RP, Rinaldo A, Silver CE, Haigentz M Jr, Woolgar JA, Triantafyllou A, Mondin V, Paccagnella D, de Bree R, Shaha AR, Hartl DM and Ferlito A. Distant metastases from head and neck squamous cell carcinoma. Part I. Basic aspects. *Oral Oncol* 2012; 48: 775-779.
- [48] Osaki T, Yoneda K, Yamamoto T, Kimura T, Matuoka H, Sakai H and Ryoke K. Clinical investigation on pulmonary metastasis of head and neck carcinomas. *Oncology* 2000; 59: 196-203.
- [49] Middleton WG, deSouza FM and Gardiner GW. Papillary carcinoma of the thyroid associated with sarcoidosis. *J Otolaryngol* 1985; 14: 241-244.
- [50] Högstedt B. Sarcoid-like lesions (epithelioid cell granulomatosis) of regional lymph nodes in association with carcinoma of the cervix. *Acta Radiol Ther Phys Biol* 1968; 7: 12-16.
- [51] Yudistiro R, Arisaka Y, Tokue A and Nakajima T. Differentiation of sarcoidosis-lymphoma syndrome lesions: a case report on the use of two different positron emission tomography tracers. *BMC Med Imaging* 2016; 16: 1.
- [52] Roth D, West B, Madison J and Cooper D. Gastric carcinoma in a patient with sarcoidosis of the gastrointestinal tract. *Am J Gastroenterol* 1994; 89: 1589-1591.
- [53] Hino H, Murakawa T, Ichinose J, Nagayama K, Nitadori J, Anraku M and Nakajima J. Results of lung cancer surgery for octogenarians. *Ann Thorac Cardiovasc Surg* 2015; 21: 209-216.
- [54] Bekki Y, Kimura Y, Morita M, Zaitu Y, Saeki H, Okamoto T, Oki E, Baba S, Oda Y and Maehara Y. Esophageal cancer associated with bilateral hilar lymphadenopathy caused by sarcoid-like reactions: a report of two cases. *Esophagus* 2015; 12: 322-326.
- [55] Li Z, Li X, Song Z, Liu J, Dong M, Shi T, Ren D, Xu S and Chen J. Sarcoidosis misdiagnosed as malignant tumors: a case report. *World J Surg Oncol* 2015; 12: 333.
- [56] Chen J, Carter R 3rd, Mao D, Tobar A, Sharon E and Greif F. Breast cancer and sarcoidosis: case series and review of the literature. *Breast Care (Basel)* 2015; 10: 137-140.
- [57] Chen ES and Moller DR. Sarcoidosis - scientific progress and clinical challenges. *Nat Rev Rheumatol* 2011; 7: 457-467.
- [58] Inoue K, Goto R, Shimomura H and Fukuda H. FDG-PET/CT of sarcoidosis and sarcoid reactions following antineoplastic treatment. *Springerplus* 2013; 2: 113.
- [59] Koo HJ, Kim MY, Shin SY, Shin S, Kim SS, Lee SW and Choi CM. Evaluation of mediastinal lymph nodes in sarcoidosis, sarcoid reaction, and malignant lymph nodes using CT and FDG-PET/CT. *Medicine (Baltimore)* 2015; 94: e1095.
- [60] Hunt BM, Vallières E, Buduhan G, Aye R and Louie B. Sarcoidosis as a benign cause of lymphadenopathy in cancer patients. *Am J Surg* 2009; 197: 629-632.
- [61] Kiess AP, Wang H, Travis WD and Yahalom J. Sarcoid in cancer patients: clinical characteristics and associated disease status. *Sarcoidosis Vasc Diffuse Lung Dis* 2015; 32: 200-207.
- [62] Akhtari M, Quesada JR, Schwartz MR, Chiang SB and Teh BS. Sarcoidosis presenting as metastatic lymphadenopathy in breast cancer. *Clin Breast Cancer* 2014; 14: e107-e110.
- [63] Kumar A, Dutta R, Kannan U, Kumar R, Khilnani GC and Gupta SD. Evaluation of mediastinal lymph nodes using F-FDG PET-CT scan and its histopathologic correlation. *Ann Thorac Med* 2011; 6: 11-16.
- [64] Matsubara R, Kawano S, Chikui T, Kiyosue T, Goto Y, Hirano M, Jinno T, Nagata T, Oobu K, Abe K and Nakamura S. Clinical significance of combined assessment of the maximum standardized uptake value of F-18 FDG PET with nodal size in the diagnosis of cervical lymph node metastasis of oral squamous cell carcinoma. *Acad Radiol* 2012; 19: 708-717.

Sarcoidosis mimicking distant metastasis of oral cancer

- [65] Haluska P, Luetmer PH, Inwards CY, Afessa B, Shives TC and Ingle JN. Complications of therapy and a diagnostic dilemma case. Case 3. Diagnostic dilemma: sarcoidosis simulating metastatic malignancy. *J Clin Oncol* 2003; 21: 4653-4654.
- [66] Sharma OP and Lamb C. Cancer in interstitial pulmonary fibrosis and sarcoidosis. *Curr Opin Pulm Med* 2003; 9: 398-401.
- [67] Malani AK, Gupta C, Singh J and Rangineni S. A 63-year-old woman with colon cancer and mediastinal lymphadenopathy. *Chest* 2007; 131: 1970-1973.
- [68] Kang SM, Baek JY, Hwangbo B, Kim HY, Lee GK and Lee HS. A case of capecitabine-induced sarcoidosis. *Tuberc Respir Dis (Seoul)* 2012; 72: 318-322.
- [69] Suen JS, Forse MS, Hyland RH and Chan CK. The malignancy-sarcoidosis syndrome. *Chest* 1990; 98: 1300-1302.
- [70] Arana Yi C, McCue P, Rosen M, Machtay M, Axelrod R and Morris GJ. Sarcoidosis mimicking metastatic bone disease in head and neck cancer. *Semin Oncol* 2013; 40: 529-534.
- [71] Vardhanabhuti V, Pang CL, Ninan T, Adams WM, Raju V and Suresh P. Sarcoidosis--the greatest mimic. *Semin Ultrasound CT MR* 2014; 35: 215-224.
- [72] Mapelli P, Mangili G, Picchio M, Rabaiotti E, Gianolli L, Messa C and Candiani M. Sarcoidosis mimicking metastatic gynaecological malignancies: a diagnostic and therapeutic challenge? *Rev Esp Med Nucl Imagen Mol* 2013; 32: 314-317.
- [73] Lebo NL, Raymond F and Odell MJ. Selectively false-positive radionuclide scan in a patient with sarcoidosis and papillary thyroid cancer: a case report and review of the literature. *J Otolaryngol Head Neck Surg* 2015; 44: 18.
- [74] Kaira K, Oriuchi N, Otani Y, Yanagitani N, Sunaga N, Hisada T, Ishizuka T, Endo K and Mori M. Diagnostic usefulness of fluorine-18-alpha-methyltyrosine positron emission tomography in combination with 18F-fluorodeoxyglucose in sarcoidosis patients. *Chest* 2007; 131: 1019-1027.