

## Case Report

# Spermatic cord and hepatic metastasis from transverse colonic mucous adenocarcinoma: a case report and review of the literature

Chao Luo<sup>1\*</sup>, Tingyu Wen<sup>2\*</sup>, Ping Li<sup>1</sup>, Yaqian Peng<sup>3</sup>, Yan Xu<sup>4</sup>, Xingzhi Huang<sup>5</sup>

Departments of <sup>1</sup>Urology, <sup>4</sup>Pathology, <sup>5</sup>Oncology, Pingxiang People's Hospital of Jiangxi Province, Pingxiang, P.R. China; <sup>2</sup>College of Basic Medical Sciences, Gannan Medical University, Ganzhou, P.R. China; <sup>3</sup>Department of Digestive Medicine, PingXiang's Second Hospital of Jiangxi Province, Pingxiang, P.R. China. \*Equal contributors and co-first authors.

Received June 14, 2017; Accepted August 25, 2017; Epub October 15, 2017; Published October 30, 2017

**Abstract:** Metastatic spermatic cord tumor is extremely rare, with <15 cases previously reported in colorectal cancer. Spermatic cord metastases originate in the transverse colon have not been reported in the English literature as determined by a PubMed search. The present study describes an original case of a 67-year-old male patient with spermatic cord and hepatic metastasis from transverse colonic mucous adenocarcinoma. He suffered left radical orchiectomy and abdominal mass resection, and considered it as metastatic mucous adenocarcinoma by immunohistochemical staining. The following enteroscopy was approved this hypothesis, and this patient finally undergo transverse palliative resection and adjuvant chemotherapy. He was still alive with hepatic metastasis after 22 months of follow-up. In conclusion, a metastatic spermatic cord tumor should be considered when the mass is discovered in elderly spermatic cord or scrotum, and also should be confirmed by further examination such as histopathology and endoscopy.

**Keywords:** Colorectal carcinoma, metastatic carcinoma, transverse colon, histopathology, endoscopy

## Introduction

Metastatic carcinoma of the spermatic cord (SC) from colonic mucous adenocarcinoma is extremely rare, with <15 cases reported since Nishimura et al [1] first description in 1983. Several investigators have reported that the most frequent primary tumor metastasizing to the SC is stomach carcinoma [2]. Due the rarity of SC metastatic carcinoma, the present study describes an original case of a patient with SC and hepatic metastasis from transverse colonic mucous adenocarcinoma, and has a systematic review of all the published literature.

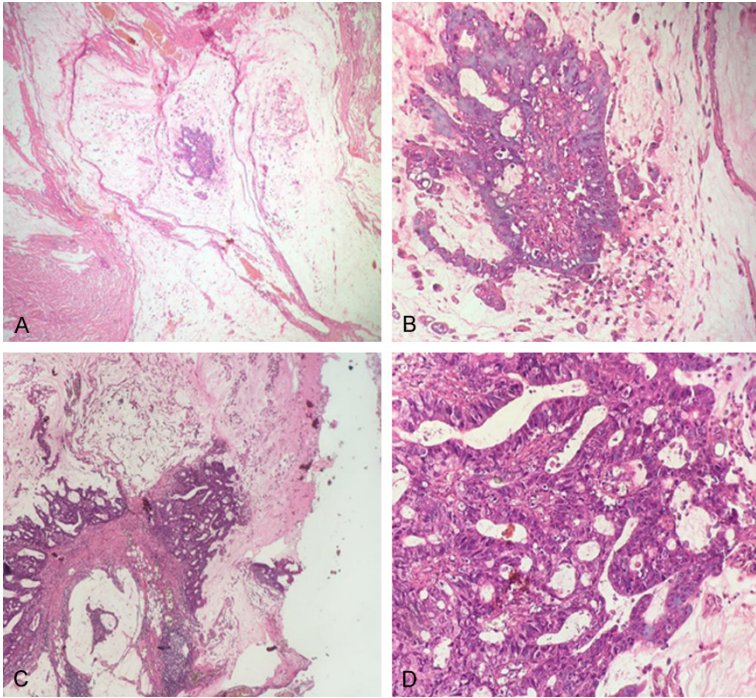
## Case report

A 67 years old male with chief complaint of a one-month history painless mass on the left scrotum was referred to the Pingxiang People's Hospital of Jiangxi Province (Pingxiang, China) on 30, November 2014. Physical examination

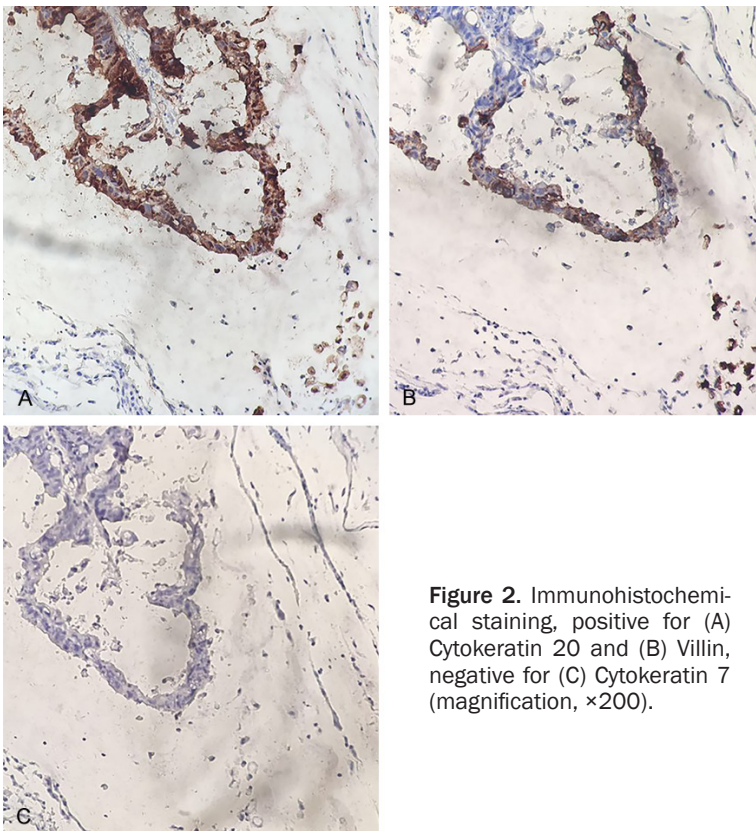
showed a firm, painless mass and visibly enlarged vein in the left scrotum, and no other obvious abnormal signs were discovered in the right scrotum or elsewhere. The patient denied other basic disease such as hypertension, diabetes or genetic disease, but suffered left Bassinis inguinal hernia repair operation in six year ago and left scrotal epidermoid cyst resection in one year ago. Ultrasonic examination was discovered a medium echo clump (25×17×22 mm) from the left deep inguinal ring to testicle. The biopsy of the left spermatic cord considered it as mucinous adenocarcinoma (**Figure 1A, 1B**). Abdominal computed tomography indicated multiple abdominal enlarged lymph nodes.

According to above examinations, left radical orchiectomy and abdominal mass resection were performed on 18, December 2014. During the operation, the elastic-hard tumor was localized in the spermatic cord without an inguinal

## Spermatic cord metastatic mucous adenocarcinoma



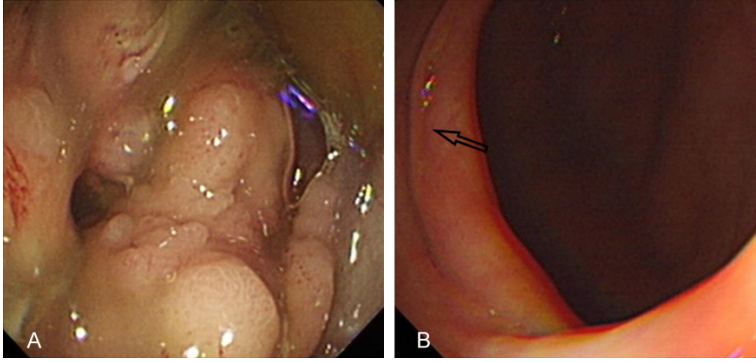
**Figure 1.** Hematoxylin and eosin staining, mucinous adenocarcinoma of spermatic cord (A)  $\times 40$ , (B)  $\times 200$ . Colonic mucinous adenocarcinoma (C)  $\times 40$ , (D)  $\times 200$ .



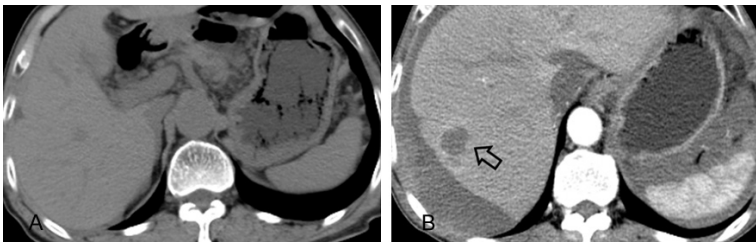
**Figure 2.** Immunohistochemical staining, positive for (A) Cytokeratin 20 and (B) Villin, negative for (C) Cytokeratin 7 (magnification,  $\times 200$ ).

hernia and hernia sac, and some tumors were adhered to the abdominal wall. Then, immunohistochemical staining was positive for epithelial membrane antigen (EMA), cytokeratin (CK)-L, CK-20, Villin, Ki-67 (8%) and negative for CK 7 (-), CK-h (-), S-100 (-), P53 (-) (**Figure 2**). Histological examination of the spermatic cord tumor diagnosed it as left SC mucous adenocarcinoma and infiltrating metastatic peritoneal mucinous adenocarcinoma. Additionally, serum tumor markers including carbohydrate antigen 12-5 (CA12-5) was 179.2 U/ml (normal range: 0-35 U/ml), carcinoembryonic antigen (CEA) was slightly elevated to 3.95 ng/ml (normal range  $< 3.4$  ng/ml). However, the levels of other tumor markers such as  $\beta$ -human chorionic gonadotropin ( $\beta$ -hCG) and alpha fetoprotein (AFP) were in the normal range.

Due to these abnormal features, we considered this as a metastatic tumor. Then, enteroscopy was executed and discovered there was a cauliflower-like tumor occupied 80% of the lumen in the transverse colon (**Figure 3A**). The biopsy diagnosed this as adenocarcinoma. Account for the broad metastasis in peritoneum, omentum, abdomen and mesentery, the palliative resection of transverse colon was performed on 30, December 2014. Immunohistochemical staining demonstrated that transverse colonic tumor were positive for CK20, Villin, Ki-67 (+10%), EMA and negative for CK7. Histological also considered this as mucous adenocarcinoma infiltrated with tra-



**Figure 3.** Colonoscopy, (A) cauliflower-like mass in transverse colon, (B) no tumor recurrence of the bowel after operation for 3 months (arrow).



**Figure 4.** Computed tomography, (A) the normal shape of liver in October 2015, (B) metastatic lesion in the right liver (arrow) in September 2016.

transverse colon and lymph gland of mesentery (Figure 1C, 1D). Finally, this patient was diagnosed as transverse colonic mucous adenocarcinoma with SC metastasis (T4aN2bM0).

After definitely diagnosis, the patient received XELOX chemotherapy (Oxaliplatin and Capecitabine) on 8, February 2015, but the therapy was discontinued after a short period of 2 weeks as the patient developed severe adverse reactions. Computed tomography (Figure 4A) and colonoscopy (Figure 3B) showed that no tumor recurrence were founded, and he did not receive any treatments until 10, September 2016. He went back to our hospital with chief complaint of abdominal distention and fatigue. Abdominal computed tomography discovered amount of seroperitoneum and low density lobes in the right liver (Figure 4B), and hepatic metastasis was diagnosed subsequently. The chemotherapy schedule had been replaced by Raltitrexed and Oxaliplatin. Now, the patient was processed in the third-cycle chemotherapy, and was still alive with hepatic metastasis after 22 months of follow-up.

## Discussion

Globally more than 1 million people get colorectal cancer every year resulting in about 715,000 deaths as of 2010 up from 490,000 in 1990 [3, 4]. It is the third most common type of male's cancer making up about 10.1% of all cases [5]. The most common colon cancer cell type is adenocarcinoma, other rarer types include lymphoma and squamous cell carcinoma. Among colorectal cancer patients, 15-25% will have liver metastases already when the colorectal cancer is discovered, and another 25-50% will develop them in the three years after resection of their primary cancer [6]. However, Spermatic cord metastatic lesion is extremely rare, with <15 cases reported since Nishimura *et al* [1] first description in 1983. The present

study describes an original case of a patient with SC and hepatic metastasis from transverse colonic mucous adenocarcinoma, and has a review of all the published literature.

Dutt *et al* [7] reported there were only two metastatic spermatic cord tumor among 13500 autopsy cases and 641 testicular biopsies, and both of them were originated in gastric. Besides, Algaba *et al* reported the most frequent primary origin of a SC metastasis was the stomach, followed by the prostate, ileum, kidney, and colon [2]. Colonic cancer may be diagnosed by obtaining a sample of the colon during a sigmoidoscopy or colonoscopy, and histological immunohistochemical staining plays a significant role in differential diagnosis of metastatic tumors. In this case, Hematoxylin-eosin staining diagnosed the mucous adenocarcinoma of the spermatic cord. Immunohistochemical staining, positive of CK-20, Villin and negative for CK-7, suggested it likely to be the metastatic tumor from the gastrointestinal tract. Eventually, colonoscopy proved the tumor in transverse colon.

## Spermatic cord metastatic mucous adenocarcinoma

**Table 1.** Review of the literature describing spermatic cord metastasis from colorectal cancer

Study	Year	Primary site	Age (years)	Site	Size (cm)	Histological	Treatment	Prognosis
Nishimura, et al [1]	1983	Cecum	71	Right	NA	NA	Right hemicolectomy Right radical orchiectomy	NA
Melone, et al [9]	1997	Sigmoid	NA	NA	NA	Silent adenocarcinoma	NA	NA
Polychronidis, et al [10]	2002	Sigmoid	63	Left	2.0	NA	NA	NA
Janeiro Pais, et al [11]	2006	Left colon	67	Right	NA	NA	Subtotal left colectomy Right orchiectomy	NA
Shida, et al [12]	2006	Ascending	75	Left	5.0	Poorly differentiated adenocarcinoma	Surgery for ascending colon cancer High left orchiectomy	Died, 6 month(s)
Sharath, et al [13]	2007	Descending	62	Left	NA	NA	Radical inguinal orchidectomy Palliative chemotherapy with rinotecan, fluorouracil, and cetuximab	Alive, 18 month(s)
Galanis, et al [14]	2009	Sigmoid, cecum, ascending	80	Right	NA	Multifocal colonic adenocarcinoma	Right high orchiectomy	Died, postoperation
Ishibashi, et al [15]	2011	Cecum	71	Right	3.8	Well-differentiated adenocarcinoma	Right hemicolectomy Adjuvant chemotherapy (tegafur, gimeracil and oteracil potassium)	No recurrent, 15 month(s)
Al-Ali, et al [16]	2012	Descending	77	Left	NA	NA	Left hemicolectomy High orchiectomy	NA
Hirano, et al [17]	2015	Cecum	68	Right	4.5	Moderately differentiated adenocarcinoma	Right radical hemicolectomy Right radical orchiectomy	No recurrent, 1 year(s)
Jang, et al [18]	2015	Sigmoid, rectum	62	Right	1.0	Mucinous adenocarcinoma	Four rounds of FOLFOX Right orchiectomy FOLFIRI	Died, 3 month(s)
Zhou, et al [19]	2016	Splenic flexure colon	27	Left	NA	Signet-ring cell carcinoma	Radical left hemicolectomy Left radical orchiectomy	No recurrent, 9 month(s)
Present study	2016	Transverse	67	Left	2.5	Mucinous adenocarcinoma	Left radical orchiectomy The palliative resection of transverse colon CapeOX, raltitrexed and oxaliplatin	Alive, 22 month(s)

NA, not available; FOLFOX, Oxaliplatin, Tetrahydrofolic acid and Fluorouracil-5; FOLFIRI, Irinotecan, Calcium folinate and Fluorouracil-5; CapeOX, oxaliplatin and capecitabine.

Spermatic cord metastases could occur by hematogenous, lymphatic and peritoneal trans-colonic spread [8]. In our case, spermatic cord metastases could occur by peritoneal trans-coelomic spread. First, an anatomical change was attributed to Bassni's inguinal hernia repairing operation. Kocijan et al [7] demonstrated that the suture technique used in Bassini's method leads to anatomical changes, including reduction of the surface area of Hesselbach's triangle, through a raised inguinal ligament. Second, we had discovered the omentum infiltrating tumor and enlarged lymph nodes near to the spermatic cord during the orchiectomy.

Furthermore, we performed a literature search of the cases about metastatic spermatic cord tumor originated in colorectal cancer by PubMed from January 1949 to September 2016.

We found that 12 related reports with English abstract and was displayed in **Table 1**. The primary sites of the colorectal tumor metastasizing to the SC were cecum (3 cases), sigmoid (2 cases), descending (2 cases), ascending (1 case), more than two colon related sites (4 cases). The mean age of incidence was 66 years (range: 27 to 80 years). The site of metastasis was six in right-sided and six in left-sided. The tumor diameter of spermatic cord is 1.0-5.0 cm. Except the censored dates, 8 cases received colectomy, 12 cases underwent radical orchiectomy and 4 cases received adjuvant chemotherapy. Moreover, the longest survival time previously reported was 18 months and our case has been alive for 22 months. All of the cases were in accordance with the distant metastasis of colorectal cancer to develop chemotherapy and radiotherapy, but at the same time, as far as possible to remove the

# Spermatic cord metastatic mucous adenocarcinoma

metastatic lesions and primary lesions, even palliative resection [20].

In conclusion, a metastatic spermatic cord tumor should be considered when the mass is discovered in elderly spermatic cord or scrotum, and also should be confirmed by further examination such as histopathology and endoscopy.

## Disclosure of conflict of interest

None.

**Address correspondence to:** Dr Chao Luo, Department of Urology, Pingxiang People's Hospital of Jiangxi Province, 8 Wugongshan Middle Road, Pingxiang 337000, P.R. China. Tel: +86 158079-92990; E-mail: urologylo1225@126.com

## References

- [1] Nishimura K, Yoshimura N, Yamamoto S, Nakagawa T and Miyaoka T. A case of a tumor of the spermatic cord metastatic from cecal cancer. *Hinyokika Kyo* 1983; 29: 907-910.
- [2] Algaba F, Santaularia JM and Villavicencio H. Metastatic tumor of the epididymis and spermatic cord. *European urology* 1983; 9: 56-59.
- [3] Cunningham D, Atkin W, Lenz HJ, Lynch HT, Minsky B, Nordlinger B and Starling N. Colorectal cancer. *Lancet* 2010; 375: 1030-1047.
- [4] Lozano R, Naghavi M and Foreman K. Global and regional mortality from 235 causes of death for 20 age groups in 1990 and 2010: a systematic analysis for the global burden of disease study 2010. *Lancet* 2012; 380: 2095-2128.
- [5] World Health Organization. International Agency for Research on Cancer. GLOBOCAN 2012: Estimated cancer incidence, mortality and prevalence worldwide in 2012. [http://globocan.iarc.fr/Pages/fact\\_sheets\\_population.aspx](http://globocan.iarc.fr/Pages/fact_sheets_population.aspx).
- [6] Hatri VP, Petrelli NJ and Belghiti J. Extending the frontiers of surgical therapy for hepatic colorectal metastases: is there a limit? *J Clin Oncol* 2005; 23: 8490-8499.
- [7] Kocijan R, Sandberg S, Chan YW and Hollinsky C. Anatomical changes after inguinal hernia treatment: a reason for chronic pain and recurrent hernia? *Surg Endosc* 2010; 24: 395-399.
- [8] Dutt N, Bates AW and Baithun SI. Secondary neoplasms of the male genital tract with different patterns of involvement in adults and children. *Histopathology* 2000 37: 323-331.
- [9] Melone F, Olmastroni M, Petacchi D, Bianchi S, Messerini L and Farina U. Metastatic tumor of the spermatic cord from a primary silent colorectal adenocarcinoma. *Minerva Urol Nefrol* 1997; 49: 57-61.
- [10] Polychronidis A, Tsolos C, Sivridis E, Botaitis S and Simopoulos C. Spermatic cord metastasis as an initial manifestation of sigmoid colon carcinoma: report of a case. *Surgery Today* 2002; 32: 376-377.
- [11] Janeiro Pais JM, Busto Castañón L, Barbagelata López A, Diaz-Reixa JP, Romero Selás E, Casas Agudo VP and Gonzalez Martín M. Metastasis of colon adenocarcinoma to the epididymis and spermatic cord. *Arch Esp Urol* 2006; 59: 746-748.
- [12] Shida Y, Miyata Y, Igawa T, Sakai H, Koga S and Kanetake H. A case of metastatic tumor of spermatic cord from ascending colon carcinoma. *Hinyokika Kyo* 2006; 52: 733-735.
- [13] Sharath CV, Paravastu and Batra M. Colonic Carcinoma Masquerading as Scrotal Swelling: a case report and review of literature. *ScientificWorldJournal* 2007; 30: 855-859.
- [14] Galanis I, Chatzimavroudis G, Katsougiannopoulos A, Galanis N, Makris J and Atmatzidis K. Spermatic cord metastasis presenting as strangulated inguinal hernia-first manifestation of multifocal colon adenocarcinoma: a case report. *Cases J* 2009; 2: 61.
- [15] Ishibashi K, Chika N, Miyazaki T, Yokoyama M, Ishida H, Matsuda T, Morozumi M and Yamada T. Spermatic cord metastasis from colon cancer: report of a case. *Surgery Today* 2011; 41: 418-421.
- [16] Al-Ali BM, Augustin H, Popper H and Pummer K. A case of descending colon carcinoma metastasized to left spermatic cord, testis, and epididymis. *Cent European J Urol* 2012; 65: 94-95.
- [17] Hirano D, Ohkawa M, Hasegawa R, Okada N, Ishizuka N and Kusumi Y. Metastatic tumor of the spermatic cord in adults: a case report and review. *Case Rep Urol* 2015; 747261.
- [18] Jang JG, Jeong HY, Kim KS, Park MJ, Lee JS, Kim SS and Kim HY. Metastatic spermatic cord tumor from colorectal cancer. *Ann Coloproctol* 2015; 31: 202-204.
- [19] Zhou XC, Jiang Y. Colonic carcinoma metastatic to the left testis, epididymis & spermatic cord. *Indian J Med Res* 2016; 143: 836-837.
- [20] Adam R, de Gramont A, Figueras J, Kokudo N, Kunstlinger F, Loyer E, Poston G, Rougier P, Rubbia-Brandt L, Sobrero A, Teh C, Tejpar S, Van Cutsem E, Vauthey JN and Pahlman L. Managing synchronous liver metastases from colorectal cancer: a multidisciplinary international consensus. *Cancer Treat Rev* 2015; 41: 729-741.