

## Case Report

# Extramammary Paget's disease of the scrotum: a case report and review of the literature

Riqiang Liu<sup>1</sup>, Xiuwang Wei<sup>2</sup>, Haiming Wei<sup>3</sup>, Bin Hu<sup>2</sup>

Departments of <sup>1</sup>Hepatobiliary and Endocrine Surgery, <sup>2</sup>Urology, <sup>3</sup>Pathology, The People's Hospital of Guangxi Zhuang Autonomous Region, Nanning, Guangxi, People's Republic of China

Received July 19, 2017; Accepted November 1, 2017; Epub December 15, 2017; Published December 30, 2017

**Abstract:** Extramammary Paget's disease (EMPD) is an uncommon cutaneous, intraepithelial adenocarcinoma which is slow-growing and developing in the apocrine gland-bearing areas. We describe the case of EMPD on the scrotum which was discovered in a 77-year-old male previously misdiagnosed and treated as other typical dermatosis. EMPD can often mimic various types of other dermatosis such as eczema or dermatitis. Apart from clinical histology, the laboratory examination is of vital importance for accurate diagnosis. The diagnosis is combined with biopsy and immunohistochemical staining. Wide surgical excision for the treatment of EMPD is considered as the first choice. Long-term follow-up is mandatory in these patients because of the tendency of subsequent recurrence or concurrent malignancy of the disease.

**Keywords:** Paget's disease, extramammary, scrotum neoplasm

## Introduction

The Paget's disease was first described by Paget in 1874, involving the nipple underlying ductal carcinoma of the breast [1]. Then Crocker described the first extramammary Paget's disease (EMPD) of the scrotum and penis in 1889 [2]. EMPD is an extremely rare cutaneous, intraepithelial adenocarcinoma (Since the first case was reported, there are only a few hundreds of reports that have been documented in peer-reviewed literature). It occurs mainly among postmenopausal women beyond 60 years of age. Also it has been reported in male patients, albeit more rarely [3-5]. The disease is usually observed in cutaneous apocrine gland-bearing regions, especially the vulva, perineum, perianal region, scrotum, penis, while it would also affect some less common areas like the axilla, groin, thigh, eyelid, external ear, and umbilicus [3, 6, 7]. Due to the rarity of EMPD and its early atypical and nonspecific symptoms, this tumor represents a diagnostic dilemma, and it is often misdiagnosed as other benign dermatologic diagnosis as eczema or dermatitis, leading to faulty or delay treatment [8]. The diagnosis of EMPD is clinical and must be confirmed by the histopathological examina-

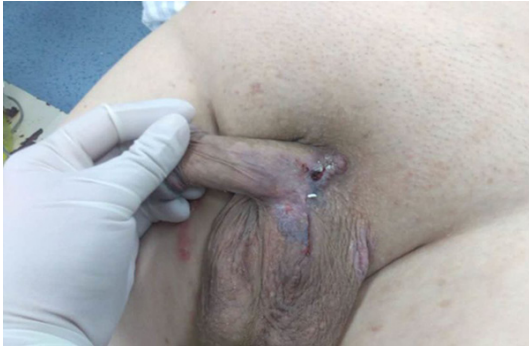tion of a tissue specimen. Some adjuvant treatment has been applied to EPMD such as chemotherapy, radiotherapy, and topical application of imiquimod, 5% cream or cytotoxic agent with 1% 5-fluorouracil cream [9-11]. Nonetheless, radical surgical excision is still the best treatment options.

We describe a case of EMPD affecting the scrotum and initially misdiagnosed as eczema. We also present a review of the relevant literature to gain new insight in the diagnosis of this rare neoplasm.

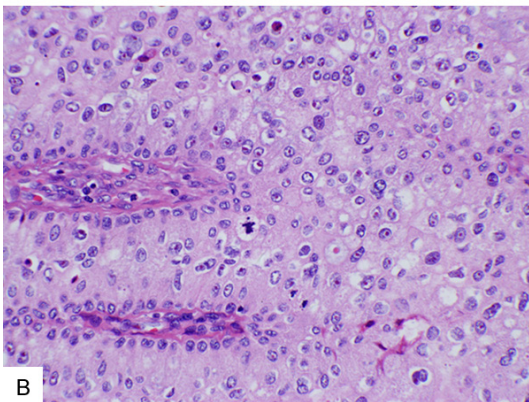
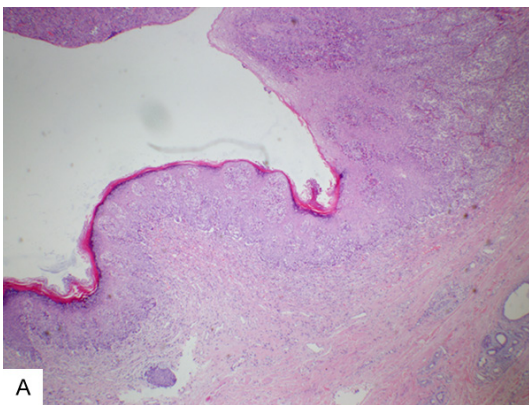
## Case report

A 77-year-old male was referred to our department of urology by a dermatologist, having performed biopsy of local excision of a scrotal lesion with the initial histology reported as EMPD. The patient presented to a 2-year history of recurrent, itchy, eczematous erosion, and indurated patchy lesion on his left side of scrotum prior to presentation to the dermatologist, which had been treated with topical corticosteroids and antibiotics. However, the skin lesion had failed treatment and progressed to an enlarging erosive lesion. Then the dermatolo-

## Misdiagnosed extramammary Paget's disease of the scrotum

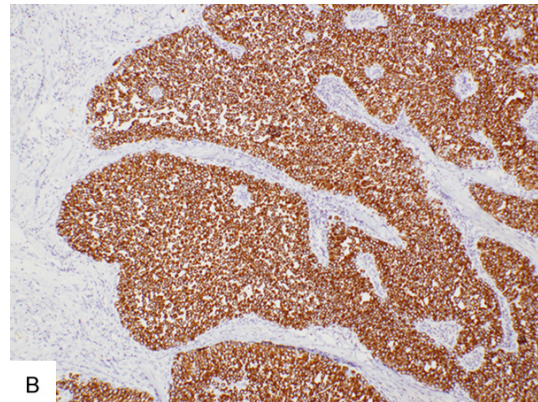
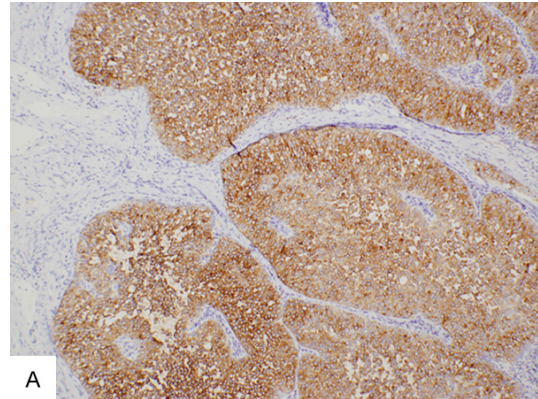


**Figure 1.** Scaly, crusting, erythematous fleshy, exophytic plaque on the left side of the penoscrotal area.



**Figure 2.** Histopathologic findings showed characteristic Paget's cells within the epidermis (A. HE, ×40) and the epidermal cells with hyperchromatic and polymorphic nuclei, intraepithelial gland cells (B. HE, ×400).

gist prompted referral for wide excision. The patient's medical history was unremarkable except for hypertension, cataract, and thoracolumbar fracture, and he denied family history of similar disease. Physical examination revealed a 5 cm erythematous, fleshy, exophytic plaque at the left side of scrotum (**Figure 1**) without



**Figure 3.** Paget's cells highlighted within the basal region of the epidermis. The tumor cells were positive for CEA (A, ×100) and CK7 (B, ×100), respectively.

palpable inguinal lymphadenopathy or other systemic symptoms. There was a less satellite lesion proximal to this.

The patient underwent a wide excision of the skin and satellite lesions with a margin of 3 cm. Frozen-section examination were not carried out during surgery. The skin defect was closure performed with a scrotal flap. Under the light microscopy, H&E stain of the resected specimen showed large, round, pale-staining cells, which is located predominantly in the basal and parabasal layers of the epithelium (**Figure 2**). The immunohistochemical stain was carcinoembryonic antigen (CEA)+, cytokeratin (CK7)+, CK20-, P16+, epithelial membrane antigen (EMA)+. These immunohistochemical appearances were consistent with EMPD of the scrotum (**Figure 3**). However, immunohistochemical staining showed that the margins were positive.

Even though the surgical margins were positive for malignancy, in view of the patient's age and

comorbidities, a decision of wider excision was not made. Radiotherapy with 50 Gy was performed as adjuvant treatment after primary excision. At 6-months follow-up, our patient had no local palpable inguinal lymph nodes or other distant metastasis.

### Discussion

Since the first report of EMPD, the pathogenesis of EMPD has been controversial, and several theories have been proposed. One theory hypothesizes that EMPD arises from the underlying sweat gland adenocarcinoma cells that metastasize to the overlying epidermis [3]. Another theory postulates that EMPD is the result of malignant transformation of pluripotent dermocytes with a common embryological origin [12]. Those researchers supporting the multipotent stem-cell theory also propose that chronic inflammatory skin disease may make a difference in the pathogenesis of EMPD.

EMPD is a rare form of adenocarcinoma that occurs mainly in the elderly. In the early stage of disease, the presentation of lesions is atypical, showing as sharply demarcated, infiltrated, erythematous to gray-white plaques, which are sometimes eczematoid, crusting, papillomatous, scaling, or, rarely, ulcerated [12, 13]. Therefore, EMPD frequently can mimic other dermatosis such as eczematous dermatitis, psoriasis, seborrheic dermatitis, leukoplakia, superficial fungal infection, and Bowen's disease and is often misdiagnosed as diseases mentioned above [14]. Patients often give a protracted history of treatment before the diagnosis of EMPD is confirmed, which is the same as the case with our patient. Thus, according to elder patients with an extended and progressing history of eczematous or erythematous lesions on penoscrotal areas, the diagnosis of EMPD should be suspected.

As it is extremely difficult to distinguish from other dermatoses, the diagnosis of EMPD depends on laboratory examination. On routine hematoxylin-eosin histological section, Paget cells are recognized by the large, round cells and usually characterized by their abundant pale-staining cytoplasm and large nuclei with prominent nucleoli, which are scattered singly or in clusters in the epidermis and/or adnexal epithelium. Besides, a panel of antibodies with CK7, CK20, EMA and GCDFP15 is valuable in

differentiation between EMPD and other diseases, especially morphological features of glandular differentiation are absent [15-17].

On immunohistochemistry, since CK7 is high sensitivity and specificity for EMPD and can significantly underline Paget cells inside the epidermis, pilosebaceous structures, and sweat ducts, CK7 is supposed to be an excellent marker. As a glycoprotein, GCDFP15 typically expressed in apocrine epithelial cells and metaplastic apocrine tissue. In primary EMPD Paget's cells, immunohistochemical stains highlighted GCDFP15+ [18-20]. Furthermore, CK20 has been reported in several studies on primary vulvar EMPD [21-23]. Therefore, besides clinical history, the laboratory examination is of vital importance for the diagnosis.

Due to the limited number of cases reported, no guidelines have been established with regard to the standard treatment for EMPD. Clinically, wide surgical excision is considered as the first choice, which is often extensive, involving large margins and reconstructive surgery [3, 24, 25]. But histological Paget's disease is generally beyond the scope of visible lesion present, causing it difficult to obtain a complete excision. Radiotherapy may be an alternative to surgery for recurrences previously excised when the surgery is not recommended or as adjuvant treatment after surgical excision [26]. Systemic chemotherapy, in combination with radiotherapy, can be used to improve responses and prevent recurrences, or in cases of advanced disease, but the use of systemic chemotherapy, alone, requires further investigation [12]. For its high recurrence rate of 31-61% despite adequate resection, long-term follow-up is needed to exclude recurrence of the disease [27]. The present case underwent local radiotherapy after surgical excision. Our patient is currently free of local recurrence or metastasis at 12 months post-surgery.

In conclusion, EMPD is a rare entity, with histomorphological features that may be confused with other benign dermatologic diagnosis as eczema or dermatitis. Early biopsy is very important to establish a correct diagnosis in patients who fail to respond to conventional topical therapy, and molecular or cytogenetic analysis should be used to confirm the pathological diagnosis. The primary treatment is surgery. Long-term follow-up is mandatory in these



## Misdiagnosed extramammary Paget's disease of the scrotum

patients because of the tendency of subsequent recurrence or concurrent malignancy of the disease. Due to limited experiences, more studies are required to provide the standard guideline for treatment as well as to help reduce the rate of reoccurrence.

### Disclosure of conflict of interest

None.

**Address correspondence to:** Bin Hu, Department of Urology, The People's Hospital of Guangxi Zhuang Autonomous Region, Nanning 530021, Guangxi, People's Republic of China. Tel: +86-13978866989; E-mail: hubinnn@126.com

### References

- [1] Paget J. On disease of mammary areola preceding cancer of mammary gland. *Bartholomew Hosp Rep* 1874; 10: 87-89.
- [2] Crocker HR. Paget's disease affecting the scrotum and penis. *Trans Pathol Soc Lond* 1889; 40: 187-191.
- [3] Kanitakis J. Mammary and extramammary Paget's disease. *J Eur Acad Dermatol Venereol* 2007; 21: 581-590.
- [4] Martin VG, Pelletiere EV, Gress D and Miller AW. Paget's disease in an adolescent arising in a supernumerary nipple. *J Cutan Pathol* 1994; 21: 283-286.
- [5] Ascenso AC, Marques MS and Capita-Mor M. Paget's disease of the nipple. Clinical and pathological review of 109 female patients. *Dermatologica* 1985; 170: 170-179.
- [6] Shepherd V, Davidson EJ and Davies-Humphreys J. Extramammary Paget's disease. *BJOG* 2005; 112: 273-279.
- [7] Sawada Y, Bito T, Kabashima R, Yoshiki R, Hino R, Nakamura M, Shiraishi M and Tokura Y. Ectopic extramammary Paget's disease: case report and literature review. *Acta Derm Venereol* 2010; 90: 502-505.
- [8] Liu HL, Liu DQ, Zhao YQ, Jie YH and Xu LZ. Photodynamic therapy for extramammary Paget's disease: 5 cases report. *Chin J Cancer Res* 2007; 19: 230-232.
- [9] Brown RS, Lankester KJ, McCormack M, Power DA and Spittle MF. Radiotherapy for perianal Paget's disease. *Clin Oncol (R Coll Radiol)* 2002; 14: 272-284.
- [10] Luk NM, Yu KH, Yeung WK, Choi CL and Teo ML. Extramammary Paget's disease: outcome of radiotherapy with curative intent. *Clin Exp Dermatol* 2003; 28: 360-363.
- [11] Berman B, Spencer J, Villa A, Poochareon V and Elgart G. Successful treatment of extramammary Paget's disease of the scrotum with imiquimod 5% cream. *Clin Exp Dermatol* 2003; 28 Suppl 1: 36-38.
- [12] Zollo JD and Zeitouni NC. The Roswell Park Cancer Institute experience with extramammary Paget's disease. *Br J Dermatol* 2000; 142: 59-65.
- [13] Yang WJ, Kim DS, Im YJ, Cho KS, Rha KH, Cho NH and Choi YD. Extramammary Paget's disease of penis and scrotum. *Urology* 2005; 65: 972-975.
- [14] Zhang N, Gong K, Zhang X, Yang Y and Na Y. Extramammary Paget's disease of scrotum-report of 25 cases and literature review. *Urol Oncol* 2010; 28: 28-33.
- [15] Hernandez JM and Copeland EM 3rd. Infiltrating apocrine adenocarcinoma with extramammary pagetoid spread. *Am Surg* 2007; 73: 307-309.
- [16] Tsutsumida A, Yamamoto Y, Minakawa H, Yoshida T, Kokubu I and Sugihara T. Indications for lymph node dissection in the treatment of extramammary Paget's disease. *Dermatol Surg* 2003; 29: 21-24.
- [17] Crowson AN, Magro CM and Mihm MC. Malignant adnexal neoplasms. *Mod Pathol* 2006; 19 Suppl 2: S93-S126.
- [18] Goldblum JR and Hart WR. Perianal Paget's disease: a histologic and immunohistochemical study of 11 cases with and without associated rectal adenocarcinoma. *Am J Surg Pathol* 1998; 22: 170-179.
- [19] Grelck KW, Nowak MA and Doval M. Signet ring cell perianal Paget disease: loss of MUC2 expression and loss of signet ring cell morphology associated with invasive disease. *Am J Dermatopathol* 2011; 33: 616-620.
- [20] Yan D, Dai H, Jin M and Zhao Y. Clinicopathologic characteristics of extramammary Paget's disease of the scrotum associated with sweat gland adenocarcinoma-a clinical retrospective study. *J Chin Med Assoc* 2011; 74: 179-182.
- [21] Shaco-Levy R, Bean SM, Vollmer RT, Papalas JA, Bentley RC, Selim MA and Robboy SJ. Paget disease of the vulva: a histologic study of 56 cases correlating pathologic features and disease course. *Int J Gynecol Pathol* 2010; 29: 69-78.
- [22] Liegl B, Leibl S, Gogg-Kamerer M, Tessaro B, Horn LC and Moinfar F. Mammary and extramammary Paget's disease: an immunohistochemical study of 83 cases. *Histopathology* 2007; 50: 439-447.
- [23] McCluggage WG. Recent developments in vulvovaginal pathology. *Histopathology* 2009; 54: 156-173.
- [24] Raspagliesi F, Fontanelli R, Rossi G, Ditto A, Solima E, Hanozet F and Kusamura S. Photodynamic therapy using a methyl ester of 5-ami-

## Misdiagnosed extramammary Paget's disease of the scrotum

- nolevulinic acid in recurrent Paget's disease of the vulva: a pilot study. *Gynecol Oncol* 2006; 103: 581-586.
- [25] Terlouw A, Blok LJ, Helmerhorst TJ and van Beurden M. Premalignant epithelial disorders of the vulva: squamous vulvar intraepithelial neoplasia, vulvar Paget's disease and melanoma in situ. *Acta Obstet Gynecol Scand* 2010; 89: 741-748.
- [26] Minicozzi A, Borzellino G, Momo R, Steccanella F, Pitoni F and de Manzoni G. Perianal Paget's disease: presentation of six cases and literature review. *Int J Colorectal Dis* 2010; 25: 1-7.
- [27] van Randenborgh H, Paul R, Nahrig J, Egelhof P and Hartung R. Extramammary Paget's disease of penis and scrotum. *J Urol* 2002; 168: 2540-2541.