

## Case Report

# Hybrid surgery in a type B dissecting thoracoabdominal aneurysm along with a renal autotransplantation

Xiaolong Du<sup>1,2</sup>, Aimin Qian<sup>2</sup>, Hongfei Sang<sup>2</sup>, Xiaobin Yu<sup>2</sup>, Xiaoqiang Li<sup>1</sup>

<sup>1</sup>Department of Vascular Surgery, Nanjing Drum Tower Hospital, The Affiliated Hospital of Nanjing University Medical School, Nanjing, China; <sup>2</sup>Department of Vascular Surgery, The Second Affiliated Hospital of Soochow University, Suzhou, China

Received March 28, 2017; Accepted March 6, 2018; Epub May 15, 2018; Published May 30, 2018

**Abstract:** This study describes our experiences of a 42 year-old man with complicated type B dissecting thoracoabdominal aneurysm in conjunction with dissecting aneurysms of bilateral common iliac artery (CIA). Preoperative angiography revealed that visceral arteries including both renal arteries originated from false lumen. To achieve adequate seal and avoid possible postoperative renal dysfunction, renal autotransplantation was performed before endovascular repair. The successful results of our new hybrid endovascular technique suggest the feasibility and efficacy of endovascular aortic repair (EVAR) along with renal autotransplantation.

**Keywords:** Dissecting aneurysm, endovascular treatment, renal transplant

### Introduction

Although conventional medical treatment is preferred for patients with type B aortic dissection, the residual blood flow into the false lumen may lead to aortic aneurysm dilatation [1]. Aneurysm expansion and rupture after stenting have been reported [2]. Endovascular aortic repair (EVAR) has become a treatment of choice for residual dissecting aortic aneurysms. Renal insufficiency is an independent risk factors for long-term outcomes after EVAR procedure. Unfortunately, the anchor zone of the aorta may be too short to allow deployment of the stent grafts, rendering endovascular therapy nearly impossible. In this context, operation of the aortic arch and descending aorta is technically complex. Here, we describe the favorable outcome of a successful hybrid endovascular technique that involved the implantation of multiple stent grafts along with renal autotransplantation.

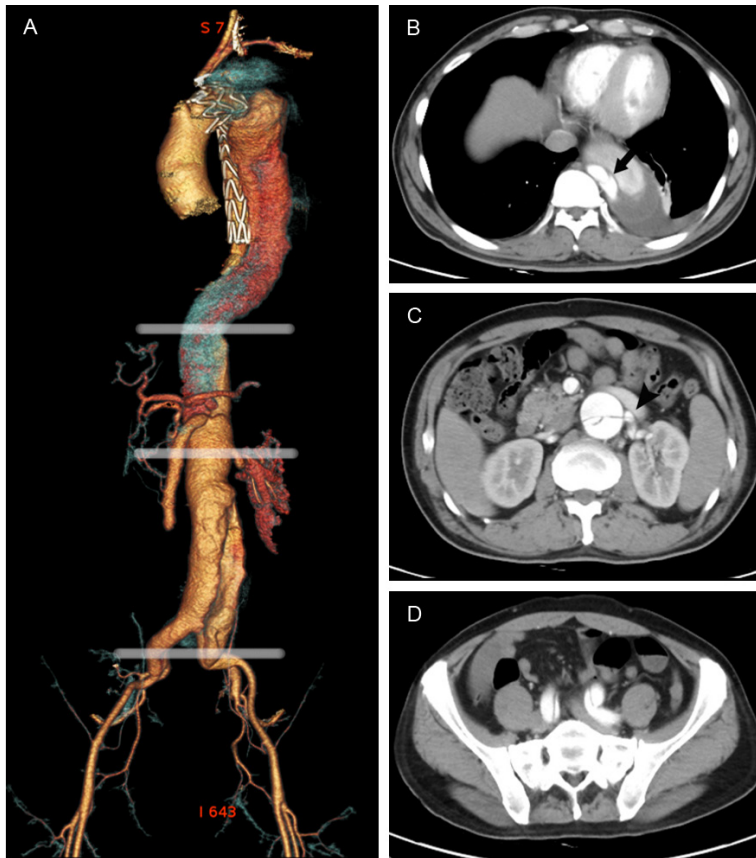
### Case report

A 42-year-old man was diagnosed to have type B aortic dissection and received endovascular aortic repair at local hospital. However, on the follow-up of 2 months, computed tomography angiography (CTA) revealed the false lumen

extended distally to common iliac arteries and both renal arteries, celiac trunk and superior mesenteric artery (SMA) were involved. The maximum diameter of the descending aorta was 70 mm (**Figure 1**).

Owing to possible renal insufficiency, we proposed a renal autotransplantation before endovascular repair. The left kidney was implanted in the right iliac fossa. Next, end-to-side anastomoses to the external iliac vessels were performed. In the second stage, endovascular procedures was performed under general anesthesia. A 28×150 mm stent-graft (Medtronic, CA, USA) was implanted to cover the tear at the level of T12 and a second 28×140 mm stent-graft (Lifetech, Shenzhen, China) to seal the tear in the distal abdominal aorta. Then, two Viabahn grafts (Gore, AZ, USA) sized 6×100 mm and 8×100 mm were placed in right renal artery and SMA, respectively (**Figure 2A**). A final angiography confirmed perfect placement of stent-graft.

A follow-up aorta angiogram at 2 months revealed new tears in CIA and iliac artery aneurysms formation. Because of the symptoms and imaging suggestive of progression of aortic disease, the patient received Viabahn grafts (5×130 mm and 5×80 mm) implantation and



**Figure 1.** Preoperative computed tomography. A. Three-dimensional reconstructed computed tomography gives an overview of aortic dissection. B. The proximal entry tear located at the level of T10 (arrow). C. The aortic dissection involved visceral arteries and left renal artery originated from false lumen (arrowhead). D. The aortic dissection was enlarged to include both common iliac arteries.

coil embolization of false lumen (**Figure 2B**). The patient recovered uneventfully and was discharged 2 weeks after surgery. A 3-month follow-up CTA confirmed a reduction of TAA size and complete thrombosis of the false lumen (**Figure 2D**).

### Discussion

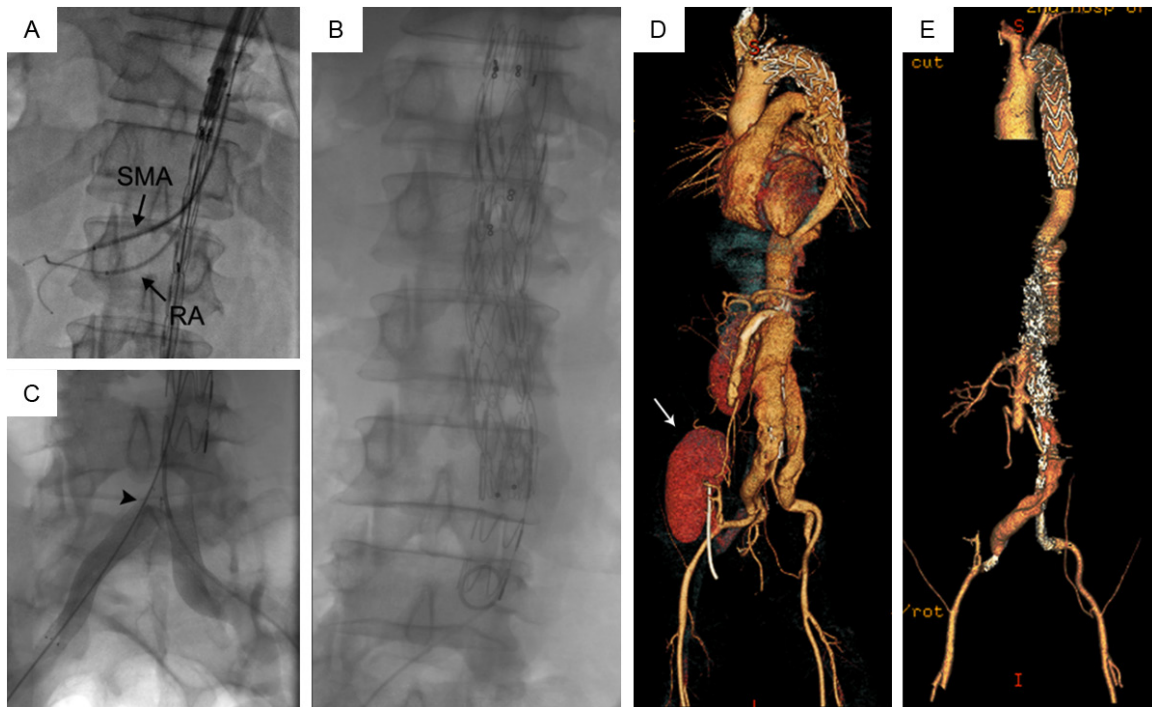
In this case the treatment design was challenging due to the presence of multiple re-entry tears. To achieve adequate seal, renal autotransplantation was scheduled. The technique of renal autotransplantation is similar to that of renal homotransplant and has been summarized on several occasions [3]. Traditionally, a full autotransplantation will be the easiest which carrying the kidney into the iliac fossa, with ureteroneocystostomy for restoration of urinary tract continuity. Considering that exposure of the left renal artery might increase risk

of aneurysm rupture, we occluded the renal artery 4 cm proximal to renal hilus with an atraumatic vascular bulldog clamp. An endoprosthesis was implanted with a covered length of 100 mm in the right renal artery. Reconstruction of renal artery pathways provided specific advantages in such conditions and allowed stent deployment without interference with renal function. Frederike et al reported patency in renal artery stents was 97.4% at 1 year [4]. Some reported that occlusion of stent occurred in 6.8% of cases [5]. Although long-term outcomes of renal artery stent is controversial, the primary advantage of this type is to provide an anatomic configuration conducive to stent grafting.

The main advantage of long lengths of coverage is to occlude multiple re-entries in the descending aorta. In this case, we placed two stent-grafts in the descending aorta with different sizes. The distal stent-graft was mainly

used to promote true lumen expansion and to close descending aorta tears as many as possible. Besides, adequate overlap of stents could maintain long-term success of this junction region. However, the main concern after stent-graft placement was expressed in terms of risks of spinal cord ischemia (SCI) due to the occlusion of important radicular arteries. Patients in such case have a high risk of spinal cord ischemia for relatively long aortic coverage [6]. Blood pressure is maintained above 130/80 mmHg during the perioperative period to keep the spinal cord sufficiently perfused and reduce paraplegia risk.

Besides, endovascular treatment of distal aortic dissecting aneurysms and bilateral common iliac artery aneurysms may present technical challenges for standard EVAR. In case of hip claudication and sexual dysfunction, iliac leg endografts are delivered in a parallel fashion



**Figure 2.** Intraoperative angiogram and reconstructed image during follow-up. A. Release of the RA stent and SMA stent (arrow). B. Angiogram revealing the deployment of stent-graft. C. Iliac artery stents deployed in a parallel fashion (arrowhead). D. The autotransplanted kidney in the right iliac fossa (white arrow). E. Three-dimensional reconstructed computed tomography 3 months later showing the position of covered graft stents and obliteration of the false lumen. LR=left renal.

from aortic bifurcation to distal iliac landing zones, preserving prograde flow to one internal iliac artery. Long-term durability of this type of operation remains a question. However, the obvious advantages are the ability to perform the operation without needing a second laparotomy to re-route the entire visceral segment, circumventing hemodynamic changes from aortic cross-clamping and avoidance of a thoracotomy.

So far, few hybrid thoracoabdominal dissecting aneurysm repair procedures have been reported. Janczak et al [7] have reported a female patient received hybrid approach with an acute type B aortic dissection after having a renal transplant. However, the aortic dissection didn't extend to the proximal of renal artery in this case. To the best of our knowledge, we present here a rare case in which hybrid surgery along with renal autotransplantation was useful with favorable outcome.

**Disclosure of conflict of interest**

None.

**Address correspondence to:** Xiaoqiang Li, Department of Vascular Surgery, Nanjing Drum Tower Hospital, The Affiliated Hospital of Nanjing University Medical School, Nanjing, China. Tel: +86 512 67784869; E-mail: szxgwk123@163.com

**References**

- [1] Tsai TT, Fattori R, Trimarchi S, Isselbacher EM, Myrmet T, Evangelista A, Hutchison S, Sechtem U, Cooper JV and Smith DE. Long-term survival in patients presenting with type B acute aortic dissection: insights from the international registry of acute aortic dissection. *Circulation* 2006; 114: 2226-2231.
- [2] Lazaris AM, Maheras AN and Vasdekis SN. A multilayer stent in the aorta may not seal the aneurysm, thereby leading to rupture. *Journal of Vascular Surgery* 2012; 56: 829-831.
- [3] Ching CB, Tiong HY, Lee UJ, Krishnamurthi V and Goldfarb DA. Renal artery aneurysm treated with ex vivo reconstruction and autotransplantation. *Urology* 2010; 75: 1067-1068.
- [4] Grimme FA, Zeebregts CJ, Verhoeven EL, Bekkema F, Reijnen MM and Tielliu IF. Visceral stent patency in fenestrated stent grafting for abdominal aortic aneurysm repair. *J Vasc Surg* 2014; 59: 298-306.

## Hybrid surgery for complicated dissecting TAA

- [5] Chiesa R, Tshomba Y, Melissano G and Logal-do D. Is hybrid procedure the best treatment option for thoraco-abdominal aortic aneurysm? *Eur J Vasc Endovasc Surg* 2009; 38: 26-34.
- [6] Swee W and Dake MD. Endovascular management of thoracic dissections. *Circulation* 2008; 117: 1460-1473.
- [7] Janczak D, Krajewska M, Garcarek J and Chabowski M. Hybrid approach in an acute type B aortic dissection in a female patient after having a renal transplant. *Exp Clin Transplant* 2014; 12: 156-158.