

Review Article

Efficacy of combined intravitreal anti-vascular endothelial growth factor and photodynamic therapy for non-age related macular degeneration sourced choroidal neovascularization: a systematic review and meta-analysis

Bing Liu^{1*}, Tuo Deng^{2,3,4*}, Jingxiang Zhong¹

¹Department of Ophthalmology, The First Affiliated Hospital of Jinan University, Guangzhou, Guangdong Province, China; ²Department of Urology, Minimally Invasive Surgery Center, The First Affiliated Hospital of Guangzhou Medical University, Guangzhou, China; ³Guangzhou Institute of Urology, Guangzhou, China; ⁴Guangdong Key Laboratory of Urology, Guangzhou, China. *Equal contributors.

Received August 10, 2017; Accepted December 6, 2017; Epub January 15, 2018; Published January 30, 2018

Abstract: Purpose: Our study aimed to explore the efficacy of combined photo dynamic therapy (PDT) and intravitreal anti-vascular endothelial growth factor (VEGF) agents for non-age related macular degeneration (AMD) sourced choroidal neovascularization (CNV) through a meta-analysis. Methods: A literature search on online databases was performed to extract relevant data. Mean differences (MDs) of best-corrected visual acuity (BCVA) changes and numbers of anti-VEGF injections from combined and monotherapy groups were pooled and compared. Results: No significant difference of BCVA changes was discovered between two groups (MD = -0.29, 95% CI, -0.86 to 0.28, $P = 0.32$). However, combined therapy could significantly reduce the number of anti-VEGF injections (MD = -1.08, 95% CI, -1.97 to -1.09, $P = 0.02$). Conclusions: We concluded that combined therapy was not superior to anti-VEGF injections in improving BCVA among patients suffering non-AMD sourced CNV. But combined therapy could decrease the number of anti-VEGF treatments, reduce severe side effects and relieve the burden of younger patients.

Keywords: Anti-vascular endothelial growth factor, photo dynamic therapy, choroidal neovascularization, systematic review, meta-analysis

Introduction

Choroidal neovascularization (CNV) is a common pathological complication of a variety of ocular diseases, especially those related to the posterior segment. With marked neovascularization originating from choriocapillaries and breaking through the Bruch's membrane, CNV could lead to a series of lesions including subretinal and/or intraretinal haemorrhage, leakage and fibrosis [1]. Patients have a relative poor prognosis and are confronted with the risk of blindness, bearing a low quality of life. Although the most common cause for CNV is age-related macular degeneration (AMD) mainly affecting people older than 50 years [2], many young patients with non-AMD sourced CNV suffer more pain and inconvenience owing

to their longer careers and high burden of raising families.

Pathological myopia (PM) is the second CNV cause following AMD, making impacts on young to middle-aged people with the prevalence of 3% in the population approximate 5%-10% developing to CNV [3, 4]. It is worth noting that Asians seem more susceptible to myopic CNV, probably due to some genetic factors and lacking outdoor activities [3]. Idiopathic choroidal neovascularization (ICNV) occupies approximately 17% of CNV [5] without any specific etiologies. Other non-AMD causes include ocular histoplasmosis, angioid streaks (AS), multifocal choroiditis, punctate inner choroidopathy, trauma, ocular tumors and infections [6]. These diseases are considered to share a more favour-

Combined anti-VEGF and PDT for non-AMD sourced CNV

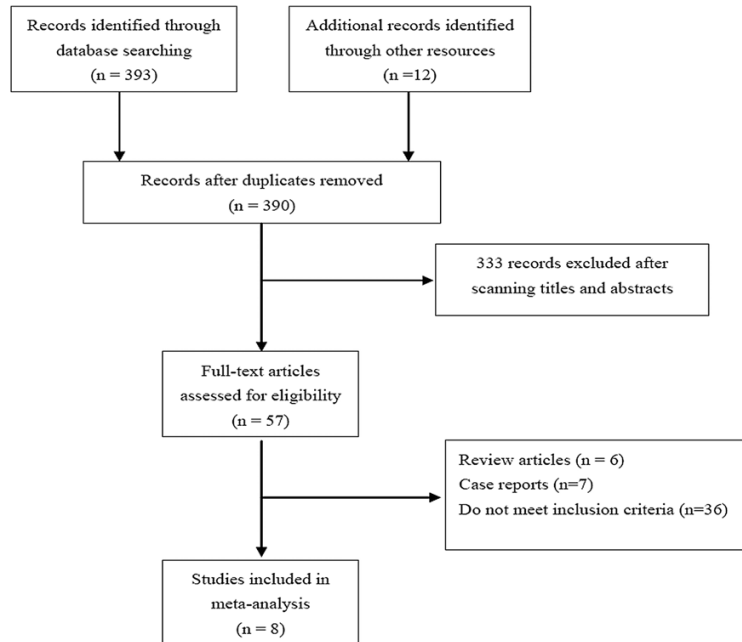


Figure 1. Flow chart of study selection.

able natural course and prognosis of visual acuity compared with AMD [5], however, outcomes vary among different individuals and a progressive CNV could lead to permanent visual loss for a life-long time in young patients [7].

Anti-vascular endothelial growth factor (VEGF) agents have been widely applied and become the first-line treatment for all kinds of CNV. Although no guidelines or protocols existed for standard regimen in treating non-AMD sourced CNV, the efficacy and safety turned out to be satisfactory according to clinical trials [8, 9]. Photodynamic therapy (PDT) was proved not superior to anti-VEGF injections in improving patients' visual acuity, bearing some side effects such as damage of retinal pigment epithelium (RPE) [10]. Nevertheless, combined anti-VEGF and PDT appeared to be applied on patients with persistent or recurrent lesions, bringing an alternative treatment and reducing the number of anti-VEGF injections [11]. A meta-analysis was conducted on the combined therapy for AMD-related CNV, finding a better visual acuity from anti-VEGF plus PDT group compared with anti-VEGF monotherapy [12]. For non-AMD sourced CNVs, treatment protocols and results varied among studies. No summative conclusions existed to prove the efficacy of combined therapy for non-AMD sourced

CNV. Therefore, we aimed to perform a systematic review and meta-analysis focusing on PDT plus anti-VEGF combined therapy on CNV other than AMD causes, and provide more instructions for CNV treatments among younger patients.

Materials and methods

Search strategy and study selection

A comprehensive electronic literature search based on Pubmed, Embase, Cochrane Library, CNKI and VIP databases was performed to confirm studies in English and Chinese and cited references in these studies were also screened. The last search was on May 3rd, 2017. Searching terms were used as follows: “‘PDT’ or ‘photodynamic therapy’” and “‘Ranibizumab’ or ‘Bevacizumab’ or ‘anti vascular endothelial growth factor’ or ‘anti VEGF’” in combination with “‘choroidal neovascularization’ or ‘CNV’”.

Comparatives studies concerning combined intravitreal anti-VEGF agents and PDT met the inclusion criteria of our meta-analysis, in which baseline and follow-up data of best corrected visual acuity (BCVA) or central macular thickness (CMT) could be achieved. Accordingly, animal studies, case reports, conference proceedings, repeated publications, non-published materials, reviews and editorials were excluded.

Comparatives studies concerning combined intravitreal anti-VEGF agents and PDT met the inclusion criteria of our meta-analysis, in which baseline and follow-up data of best corrected visual acuity (BCVA) or central macular thickness (CMT) could be achieved. Accordingly, animal studies, case reports, conference proceedings, repeated publications, non-published materials, reviews and editorials were excluded.

Data extraction and study quality assessment

Two authors screened the literature, assessed the quality of studies and extracted data separately with discrepancies solved by the third reviewer or open discussion. Data from included studies was collected as follows: first author, year of publication, country, ethnicity, study design, therapeutic regimen, sample size, patients' basic information, baseline and follow-up data of BCVA and CMT. Numbers of anti-VEGF injections and PDTs were also extracted with their main adverse events recorded. The level of evidence (LOE) of each study was evalu-

Combined anti-VEGF and PDT for non-AMD sourced CNV

Table 1. Baseline characteristics of included studies

Reference	Country	Race	CNV cause	Design	LOE	No. eyes/ patients	Intervention groups, sample (n)	Follow-up time (mo)	CNV location		Gender (M/F)	Mean age (yr)
									Subfoveal	non-subfoveal		
Rinaldi et al, 2017	Ltaly	Caucasian	PM	RCT	2a	40/40	Group 1: PDT+IVR, 20 Group 2: IVR, 20	12	37	23	26/34	Group 1: 43.6 Group 2: 44.7
Saviano et al, 2016	Ltaly	Caucasian	Myopic CNV	RCT	2a	34/34	Group 1: PDT+IVB, 17 Group 2: IVB, 17	12		NA	8/26	Group 1: 61.7 Group 2: 63
Rishi et al, 2016	India	Asian	Myopic CNV	Retrospective comparative trial	3	79/70	Group 1: PDT+IVB/R, 31 Group 2: IVB/R, 25 Group 3: PDT, 23	54.63±39.46	57	22	37/33	44.08
Chen et al, 2011	USA	Mixed	Mixed※	Retrospective comparative trial	3	23/23	Group 1: PDT+IVR, 6 Group 2: IVR, 17	12		NA	8/15	Group 1: 48.5 Group 2: 52.4
Yoon et al, 2010	Korea	Asian	Myopic CNV	Retrospective comparative trial	3	142/128	Group 1: PDT+IVB/R, 28 Group 2: IVB/R, 63 Group 3: PDT, 51	12	67	75	39/89	Group 1: 45.66 Group 2: 45.19 Group 3: 44.25
Ye et al, 2013	China	Asian	ICNV	RCT	2a	27/27	Group 1: PDT+IVR, 14 Group 2: IVR, 13	12		NA	12/15	Group 1: 31.6 Group 2: 34.5
Huang et al, 2011	China	Asian	ICNV	RCT	2b	46/46	Group 1: PDT+IVB, 24 Group 2: PDT, 22	12		NA	15/31	Group 1: 31.5 Group 2: 30.4
Li et al, 2015	China	Asian	ICNV	RCT	2b	30/30	Group 1: PDT+IVB, 15 Group 2: PDT, 15	3		NA	12/18	24-52

CNV: choroidal neovascularization; LOE: level of evidence; PM: pathological myopia; RCT: randomized controlled trial; PDT: photodynamic therapy; IVR: intravitreal Ranibizumab; IVB: intravitreal Bevacizumab; NA: not available. ※ Myopia: 47.8%, presumed ocular histoplasmosis: 21.7%, angioid streaks: 13%, others: 17.5%.

Combined anti-VEGF and PDT for non-AMD sourced CNV

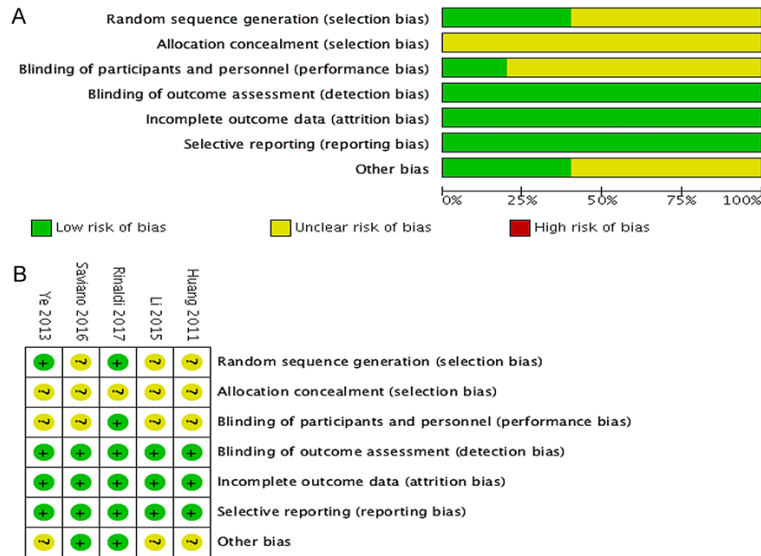

Figure 2. Assessment of bias risk for included RCTs (A: Methodological quality graph: authors' judgments about each methodological quality item presented as percentages across all included studies; B: Methodological quality summary: authors' judgments about each methodological quality item for each included study, "+" low risk of bias; "?" unclear risk of bias; "-" high risk of bias).

ated according to the GRADE system [13] and all RCTs were also assessed by the Cochrane Collaboration Risk of Bias Tool [14].

Statistics analysis

Software RevMan (version 5.3; Cochrane Collaboration, Oxford, UK) was applied to conduct the statistics analysis. Weighted mean differences (WMD) were calculated to compare changes of BCVA and CMT and number of anti-VEGF injections. Standard mean difference (SMD) was used if measuring methods varied in different studies. Subgroup analyses were conducted based on the follow-up time. Heterogeneity test was conducted through the chi-square test with Cochrane Q and I^2 statistic [15]. Significant heterogeneity did not exist if the P -value was greater than 0.1 and $I^2 < 50\%$ and the fixed effect model was applied. Conversely, a random-effect model was used. A two-sided p value < 0.05 was considered to be significant in meta-analysis. Publication bias was also assessed through inverted funnel plot [16].

Result

A total of 398 patients with 421 eyes from 8 comparative studies were included in our sys-

tematic review and the flow chart was shown in **Figure 1**. Among them 5 were randomized controlled trial (RCT)s [17-21] and the other 3 were retrospective comparative studies [22-24]. 4 studies compared combined anti-VEGF and PDT with anti-VEGF monotherapy [17-19, 23], 2 studies concentrated on the efficacy of anti-VEGF and PDT versus PDT alone [20, 21], and other 2 studies divided their patients into combined therapy, anti-VEGF and PDT groups for further comparisons [22, 24]. Except for 2 studies conducted among Caucasians in Italy and 1 in USA, the remaining 6 were all carried out in Asian countries with 4 in China, 1 in Korea and 1 in India. All studies performed anti-VEGF therapies with the

dose of Bevacizumab 0.5 mg/0.05 ml or Ranibizumab 1.25 mg/0.05 ml, and verteporfin was infused 6 mg/m² in PDT. Basic information of these included studies was listed in **Table 1**.

Quality assessments of included studies

Level of evidence (LOE) of all included studies was listed in **Table 1**. The risk of detection, attrition biases and reporting biases of 5 RCTs were relative low according to the Cochrane Collaboration Risk of Bias Tool (**Figure 2A**). In total, 3 studies were in low bias risk and 2 were in moderate bias risk (**Figure 2B**).

Change of best corrected visual acuity

All 8 studies compared BCVA changes between PDT plus anti-VEGF and monotherapy groups. Among 6 studies focusing on the BCVA improvements of combined treatment versus anti-VEGF injection, data from 5 of them was extracted and pooled in **Figure 3A**. No significant advantage was observed in combined group (SMD = -0.29, 95% CI, -0.86 to 0.28, $P = 0.32$). Subgroup analysis in 12 months' follow-up group also indicated no significant differences (SMD = -0.40, 95% CI, -1.12 to 0.31, $P = 0.27$). Significant heterogeneity existed in the cu-

Combined anti-VEGF and PDT for non-AMD sourced CNV

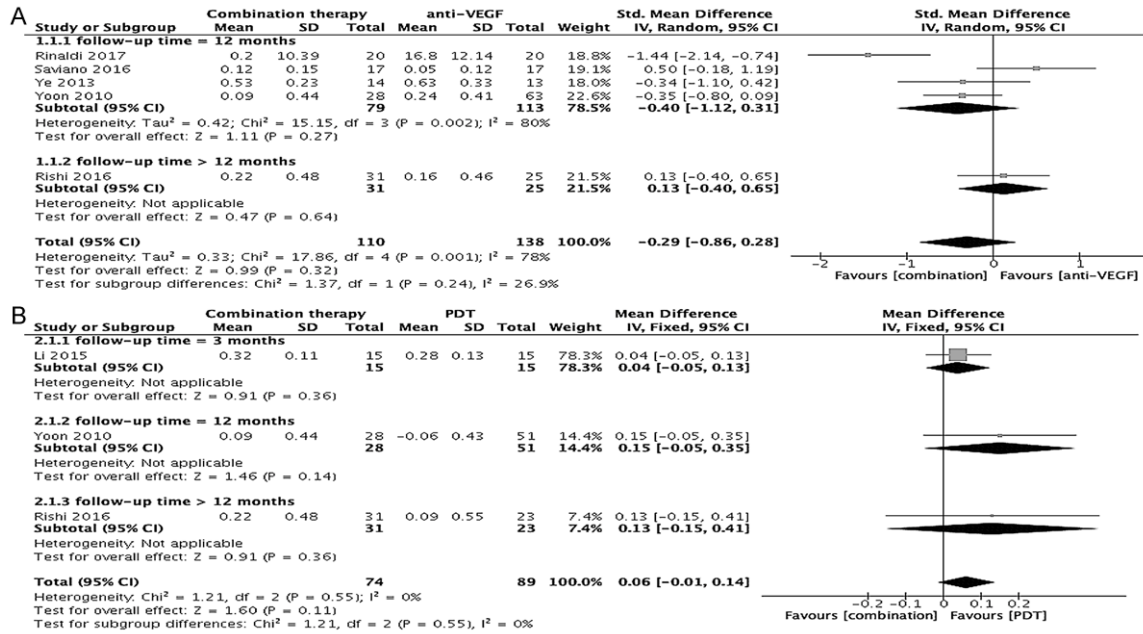


Figure 3. Forest plots of changes of best-corrected visual acuity. (A: Forest plot of change of best-corrected visual acuity between combined and anti-VEGF therapy; B: Forest plot of change of best-corrected visual acuity between combined therapy and PDT).

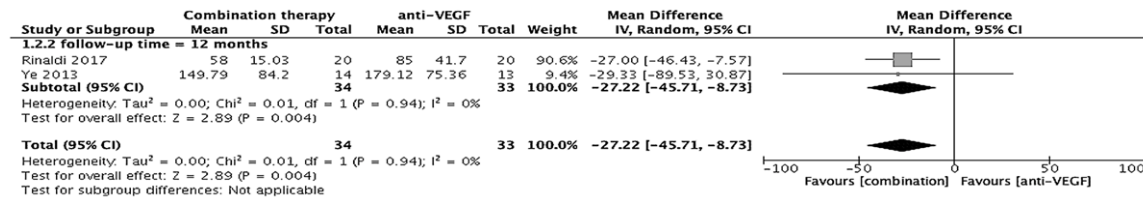


Figure 4. Forest plot of change of central macular thickness between combined and anti-VEGF therapy.

mulative analysis of 5 studies ($I^2 = 78\%$, $P = 0.001$) and subgroup analysis for 4 studies ($I^2 = 80\%$, $P = 0.002$). 4 studies researched the efficacy of combined therapy compared with PDT alone, 3 of which were included in meta-analysis. We found no significant changes in BCVA between two groups (WMD = 0.06, 95% CI, -0.01 to 0.14, $P = 0.11$) and in either subgroup according to follow-up time (Figure 3B). 2 studies applied changes of lines for the description of BCVA at the 12 months' follow-up time [20, 23]. According to their studies, no significant differences were discovered between two groups in the percentage of patients with BCVA increasing ≥ 2 lines, stable in 1 line and decreasing ≥ 2 lines.

Change of central macular thickness

Figure 4 indicated 2 studies comparing changes of CMT between combined therapy and anti-

VEGF groups. Significant more CMT reduces were tested in combined group than anti-VEGF monotherapy (MD = -27.22, 95% CI, -45.17 to -8.73, $P = 0.04$). Li et al found CMT decreased more in combined group in comparison with PDT at the 3-month follow-up time [21].

Number of treatment

Table 2 provided the detailed treatment regimen of all included studies. 5 of them calculated mean number of anti-VEGF injections between combined and monotherapy groups at the 12-month's follow-up. We reached the result that the number of anti-VEGF agents injected in combined group was significantly lower than in monotherapy group (MD = -1.08, 95% CI, -1.97 to -1.09, $P = 0.02$) (Figure 5). Time of PDT was compared in 2 studies focusing on combined therapy versus PDT alone with the data shown in Table 2.

Combined anti-VEGF and PDT for non-AMD sourced CNV

Table 2. Treatment regimens of included studies

Reference	Design	Intervention [※]	Injections of anti-VEGF, n		No. of PDT, n	
			Combined therapy	IVB/R monotherapy	Combined therapy	PDT
Rinaldi et al, 2017	RCT	Group 1: PDT+IVR, 1 IVR injection and after 7 days with PDT Group 2: IVR, 1 IVR at baseline and at week 4 and 8	1.25 ± 2.45	3.35 ± 2.45	NA	
Saviano et al, 2016	RCT	Group 1: PDT+IVB, 1 IVB injection followed by PDT within 7 d Group 2: IVB, 3 monthly IVB injections	1.8 ± 0.11	3.1 ± 0.08	NA	
Rishi et al, 2016	Retrospective comparative trial	Group 1: PDT+IVB/R, anti-VEGF treatment was given within 2 days of PDT Group 2: IVB/R, given as PRN Group 3: PDT, given as PRN		NA	NA	
Chen et al, 2011	Retrospective comparative trial	Group 1: PDT+IVB, 1 IVB injection within 3 days of PDT Group 2: IVB, given as PRN	2 ± 3.66	7.2 ± 3.66	NA	
Yoon et al, 2010	Retrospective comparative trial	Group 1: PDT+IVB/R, anti-VEGF treatment was given within 1 hour of PDT Group 2: IVB/R, given as PRN Group 3: PDT, given as PRN	2.5 ± 1.9	2.2 ± 2.0	1.9 ± 1.3	2.1 ± 1.4
Ye et al, 2013	RCT	Group 1: PDT+IVR, 1 IVR injection was given 7 days after PDT Group 2: IVR, 1 IVR at baseline and at week 4 and 8	1.5 ± 0.7	2.4 ± 1.7	NA	
Huang et al, 2011	RCT	Group 1: PDT+IVB, 1 IVB injection was given 7 days after PDT Group 2: PDT, additional treatments were given in a 3-month interval		NA	1	1.86
Li et al, 2015	RCT	Group 1: PDT+IVR, 1 IVR injection was given 7 days after PDT Group 2: PDT, regimen was unavailable		NA	NA	

VEGF: vascular endothelial growth factor; RCT: randomized controlled trial; PDT: photodynamic therapy; IVR: intravitreal Ranibizumab; IVB: intravitreal Bevacizumab; PRN: pro re nata; NA: not available. ※: All anti-VEGF retreatments were conducted as PRN.

Combined anti-VEGF and PDT for non-AMD sourced CNV

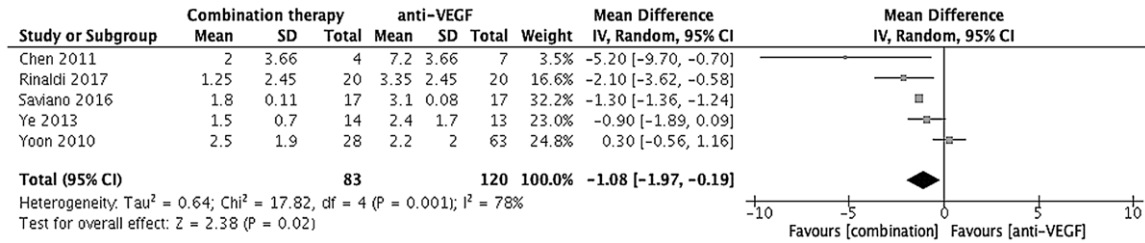


Figure 5. Forest plot of number of anti-vascular endothelial growth factor injections

Table 3. Adverse events reported in included studies

Reference	Intervention groups	Adverse event, n (%)		
		Conjunctival hemorrhage	Choriocapillaris atrophy	Macular scar
Rinaldi F, 2017	Group 1: PDT+IVR Group 2: IVR	Group 1: 4 (20.0) Group 2: 6 (30.0)	Group 1: 14 (70.0) Group 2: 0	NA
Saviano S, 2016	Group 1: PDT+IVB Group 2: IVB	NA		
Rishi P, 2016	Group 1: PDT+IVB/R Group 2: IVB/R Group 3: PDT	NA	Group 1: 2 (6.5) Group 3: 3 (13.0)	40 (50.6)
Chen L, 2011	Group 1: PDT+IV Group 2: IVR	No serious ocular complications were observed		
Yoon JU, 2010	Group 1: PDT+IVB/R Group 2: IVB/R Group 3: PDT	No serious ocular complications were observed		
Ye XX, 2013	Group 1: PDT+IVR Group 2: IVR	Group 1: 0 Group 2: 1 (7.7)	NA	NA
Huang ZJ, 2011	Group 1: PDT+IVB Group 2: PDT	Group 1: 5 (20.8) Group 2: NA	NA	NA
Li TT, 2015	Group 1: PDT+IVB Group 2: PDT	NA		

PDT: photodynamic therapy; IVR: intravitreal Ranibizumab; IVB: intravitreal Bevacizumab; NA: not available.

Adverse events

2 studies reported no severe complications in both combined and monotherapy groups [23, 24]. Most frequent reported adverse events were conjunctival hemorrhage, choriocapillaris atrophy and macular scar (**Table 3**). Rinaldi F et al reported a higher percentage of choriocapillaris atrophy in combined therapy than anti-VEGF alone group [17]. A 50.6% rate of macular scar was found in Rishi et al's studies in their long observation for almost 9 years [22].

Publication bias

The inverted funnel plot did not indicate any publication bias for all results in our meta-analysis.

Discussion

Our systematic review and meta-analysis consisted of 8 comparative studies. To the best of our knowledge, it is the first meta-analysis providing summarized conclusions related to combined PDT and anti-VEGF therapy for non-AMD related CNV. We discovered that patients' BCVA did not increase significantly in combined group versus any monotherapy. Significant decrease of CMT was found in PDT plus anti-VEGF therapy compared with anti-VEGF injections alone. Furthermore, patients in combined therapy group received significant less number of anti-VEGF injections than those with monotherapy.

Treatment of CNV changed from earlier surgical remove, lasers, PDT to recent anti-VEGF therapies. PDT was used to be the mainstream treat-

ment by selectively occluding the leakage from CNV without damaging healthy retina, however, apparent adverse events such as RPE and choriocapillaries atrophy might influence its further efficacy [25]. Therefore, appearance of anti-VEGF drugs has brought about a new and hopeful method targeting to CNV diseases. VEGF plays a dominant role in angiogenesis by promoting the activities of present endothelial cells, causing vascular abnormalities, stimulating neovascularization and increasing the permeability of vascular walls [26]. Subsequently, hemorrhage and edema begin to accumulate in intraretinal or subretinal space, leading to deteriorating of visual acuity and increase of CMT. Bevacizumab is a kind of full-length anti-VEGF-A monoclonal antibody preventing VEGF from combining with its receptors Flt-1 and KDR. Ranibizumab is a selected mutated Fab fragment of a humanized monoclonal antibody, having a relative higher affinity than Bevacizumab [27]. Both of them could not only eliminate active CNV, but also inhibit further neovascularization [28], thus to relieve patients' symptoms and increase their visual acuity.

Unlike AMD-sourced CNV with a standard treatment protocol of anti-VEGF injections, CNV originated from pathological myopia or other sources had no optimal treatments or guidelines yet. In former original studies and reviews concerning the comparison of anti-VEGF and PDT, a variety of them confirmed that anti-VEGF drugs were beneficial on patients with non-AMD sourced CNV, safer and more effective than PDT [28, 29]. Trials of combined therapy conducted by Saviano et al [18], Chen et al [23] and Yoon et al [24] showed no significant differences between PDT plus anti-VEGF and anti-VEGF alone groups, which were consistent with our results. Although applied widely before the occurrence of anti-VEGF agents, PDT could actually upregulate the expression of VEGF and pigment epithelium derived factor, causing a microenvironment of pro-angiogenesis and inhibiting the efficacy [30]. Obvious choriocapillaris atrophy was also observed in groups treated by PDT in several studies [17, 22] and Rinaldi et al reported a higher rate of choriocapillaris atrophy in standard-fluence PDT than reduced-fluence PDT [17]. Therefore, a combination of PDT and anti-VEGF could provide complementary effects. In Huang et al [20] and Li et al [21]'s studies, combined therapy was superior to

PDT alone in BCVA change, however, our cumulative analysis found no significant difference between two groups, probably due to limited number of included studies and samples.

In our meta-analysis, we concluded that the number of anti-VEGF injections were significant less in combined group compared with anti-VEGF monotherapy, which might be an apparent advantage of combined therapy. Repeated intravitreal injections of anti-VEGF agents are necessary according to pro re nata (PRN) frequencies, accompanied with some severe adverse events such as endophthalmitis, which could cause blindness though seldom occurred [31]. Patients with myopic CNVs are more susceptible to retinal rupture and even retinal detachment resulted from peripheral vitreoretinal degeneration. Multiple punctures would cause some traction and then increase this kind of risk, which could be reduced by an extra PDT [18]. Frequent visits to hospital and injections bring about inconvenience to pregnant female patients and those bearing cardiovascular diseases [12, 23]. Moreover, the fewer injections could also reduce the economic burden of patients from the relative high cost of anti-VEGF agents.

Several limitations occurred in our systematic review and meta-analysis. Firstly, only 8 comparative studies were included and 5 of them were RCTs with inadequate samples, influencing the validity of our results. Further RCTs with larger sample size are necessary to provide more accurate evidences for treatment. Secondly, follow-up varied among studies from 3 month to 9 years, causing significant heterogeneity after combining related data. Number of studies in each subgroup was not enough for a more convinced result. Thirdly, patients from 5 studies came from Asian countries and few Caucasians or other races were researched, partly because of the high prevalence of myopia in Asian countries. These above limitations decreased power of evidences to some degree.

Conclusion

We concluded that no significant differences between PDT plus anti-VEGF injections and anti-VEGF monotherapy in improving BCVA among patients suffering non-AMD sourced CNV. However, combined therapy could significantly reduce the number of anti-VEGF treat-

ments, lower the risk of severe side effects and relieve the burden of younger patients. In summary, anti-VEGF drugs have been commonly applied on CNV other than AMD cause, with the assistance of PDT if necessary. Further RCTs with larger samples and in higher quality are still needed to guide normative treating regimens for non-AMD sourced CNVs.

Acknowledgements

This work was supported by grants from Natural Science Foundation (No. 2014A030313359), Science and Technology Planning Project (No. 2015B020226003) of Guangdong Province, China, and China Postdoctoral Science Foundation (No. 2017M612636 and No. 2017M62-2912).

Disclosure of conflict of interest

None.

Address correspondence to: Jingxiang Zhong, Department of Ophthalmology, The First Affiliated Hospital of Jinan University, 613 West Huangpu Road, Guangzhou, Guangdong Province, China. Tel: +86-20-85221206; E-mail: zjx85221206@yeah.net

References

- [1] Wong TY, Ferreira A, Hughes R, Carter G, Mitchell P. Epidemiology and disease burden of pathologic myopia and myopic choroidal neovascularization: an evidence-based systematic review. *Am J Ophthalmol* 2014; 157: 9-25.
- [2] Green WR, Wilson DJ. Choroidal neovascularization. *Ophthalmology* 1986; 93: 1169-1176.
- [3] Hayashi K, Ohno-Matsui K, Shimada N, Moriyama M, Kojima A, Hayashi W, Yasuzumi K, Nagaoka N, Saka N, Yoshida T, Tokoro T, Mochizuki M. Long-term pattern of progression of myopic maculopathy: a natural history study. *Ophthalmology* 2010; 117: 1595-1611.
- [4] Grossniklaus HE, Green WR. Pathologic findings in pathologic myopia. *Retina* 1992; 12: 127-133.
- [5] Cohen SY, Laroche A, Leguen Y, Soubrane G, Coscas GJ. Etiology of choroidal neovascularization in young patients. *Ophthalmology* 1996; 103: 1241-1244.
- [6] Lindblom B, Andersson T. The prognosis of idiopathic choroidal neovascularization in persons younger than 50 years of age. *Ophthalmology* 1998; 105: 1816-1820.
- [7] Kang HM, Koh HJ. Intravitreal anti-vascular endothelial growth factor therapy versus photodynamic therapy for idiopathic choroidal neovascularization. *Am J Ophthalmol* 2013; 155: 713-719.
- [8] Chan WM, Lai TY, Liu DT, Lam DS. Intravitreal bevacizumab (Avastin) for choroidal neovascularization secondary to central serous chorioretinopathy, secondary to punctuate inner choroidopathy, or of idiopathic origin. *Am J Ophthalmol* 2007; 143: 977-983.
- [9] Mandal S, Garg S, Venkatesh P, Mithal C, Vohra R, Mehrotra A. Intravitreal bevacizumab for subfoveal idiopathic choroidal neovascularization. *Arch Ophthalmol* 2007; 125: 1487-1492.
- [10] Postelmans L, Pasteels B, Coquelet P, El Ouardighi H, Verougstraete C, Schmidt-Erfurth U. Severe pigment epithelial alterations in the treatment area following photodynamic therapy for classic choroidal neovascularization in young females. *Am J Ophthalmol* 2004; 138: 803-808.
- [11] Han DP, Mc Allister JT, Weinberg DV, Kim JE, Wirostko WJ. Combined intravitreal anti-VEGF and verteporfin therapy for juxtafoveal and extrafoveal choroidal neovascularization as an alternative to laser photocoagulation. *Eye (Lond)* 2010; 24: 713-716.
- [12] Si JK, Tang K, Bi HS, Guo DD, Guo JG, Du YX, Cui Y, Pan XM, Wen Y, Wang XR. Combination of ranibizumab with photodynamic therapy ranibizumab monotherapy in the treatment of age-related macular degeneration: a systematic review and meta-analysis of randomized controlled trials. *In J Ophthalmol* 2014; 7: 541-549.
- [13] Guyatt GH, Oxman AD, Vist GE, Kunz R, Falck-Ytter Y, Alonso-Coello P, Schünemann HJ; GRADE Working Group. GRADE: an emerging consensus on rating quality of evidence and strength of recommendations. *BMJ* 2008; 336: 924-926.
- [14] Higgins JP, Altman DG, Gøtzsche PC, Jüni P, Moher D, Oxman AD, Savovic J, Schulz KF, Weeks L, Sterne JA; Cochrane Bias Methods Group; Cochrane Statistical Methods Group. The Cochrane Collaboration's tool for assessing risk of bias in randomised trials. *BMJ* 2011; 343: d5928.
- [15] Higgins JP, Thompson SG, Deeks JJ, Altman DG. Measuring inconsistency in meta-analyses. *BMJ* 2003; 327: 557-560.
- [16] Egger M, Davey Smith G, Schneider M, Minder C. Bias in meta-analysis detected by a simple, graphical test. *BMJ* 1997; 315: 629-634.
- [17] Rinaldi M, Semeraro F, Chiosi F, Russo A, Romano MR, Savastano MC, dell'Omo R, Costagliola C. Reduced-fluence verteporfin photodynamic therapy plus ranibizumab for choroidal neovascularization in pathologic myopia. *Graefes Arch Clin Exp Ophthalmol* 2017; 255: 529-539.

Combined anti-VEGF and PDT for non-AMD sourced CNV

- [18] Saviano S, Piermarocchi R, Leon PE, Mangogna A, Zanei A, Cavarzeran Sc F, Tognetto D. Combined therapy with bevacizumab and photodynamic therapy for myopic choroidal neovascularization: a one-year follow-up controlled study. *Int J Ophthalmol* 2014; 18: 335-339.
- [19] Ye XX, Chen ZS, Ding Q, Song YP. Intravitreal ranibizumab injection combined with or without photodynamic therapy for idiopathic choroidal neovascularization: a comparative efficacy study. *Chinese J of Ocu Fundus Dis* 2014; 29: 362-366.
- [20] Huang ZJ, Song YP, Jin ZQ, Chen ZS, Ding Q, Yan M. Photodynamic therapy versus photodynamic therapy associated with intravitreal Bevacizumab injection for central exudative chorioretinopathy: a comparative study. *Chin J Laser Med Surg* 2011; 20: 77-82.
- [21] Li TT, Niu TT. Combined photodynamic and intravitreal Ranibizumab therapy versus photodynamic therapy for idiopathic choroidal neovascularization. *Chin Continuing Med Edu* 2015; 7: 31-33.
- [22] Rishi P, Rishi E, Bhende M, Agarwal V, Vyas CH, Valiveti M, Bhende P, Rao C, Susvar P, Sen P, Raman R, Khetan V, Murali V, Ratra D, Sharma T. Comparison of photodynamic therapy, ranibizumab/bevacizumab or combination in the treatment of myopic choroidal neovascularisation: a 9-year-study from a single centre. *Br J Ophthalmol* 2016; 100: 1337-1340.
- [23] Chen L, Miller JW, Vavvas D, Kim IK. Anti-vascular endothelial growth factor monotherapy versus combination treatment with photodynamic therapy for subfoveal choroidal neovascularization secondary to causes other than age-related macular degeneration. *Retina* 2011; 31: 2078-2083.
- [24] Yoon JU, Byun YJ, Koh HJ. Intravitreal anti-VEGF versus photodynamic therapy with verteporfin for treatment of myopic choroidal neovascularization. *Retina* 2010; 30: 418-424.
- [25] Inoue M, Kadonosono K, Watanabe Y, Sato S, Kobayashi S, Yamane S, Ito R, Arakawa A. Results of 1-year follow-up examinations after intravitreal bevacizumab administration for idiopathic choroidal neovascularization. *Retina* 2010; 30: 733-738.
- [26] Osaadon P, Fagan XJ, Lifshitz T, Levy J. A review of anti-VEGF agents for proliferative diabetic retinopathy. *Eye (Lond)* 2014; 28: 510-520.
- [27] Schauwvlieghe AM, Dijkman G, Hooymans JM, Verbraak FD, Hoyng CB, Dijkgraaf MG, Van Leeuwen R, Vingerling JR, Moll AC, Schlingemann RO. Comparing the effectiveness and costs of Bevacizumab to Ranibizumab in patients with Diabetic Macular Edema: a randomized clinical trial (the BRDME study). *BMC Ophthalmol* 2015; 15: 71.
- [28] Stuart A, Ford JA, Duckworth S, Jones C, Pereira A. Anti-VEGF therapies in the treatment of choroidal neovascularisation secondary to non-age-related macular degeneration: a systematic review. *BMJ Open* 2015; 5: e007746.
- [29] Shi XH, Wei W, Zhang C. Intravitreal ranibizumab therapy versus photodynamic therapy for idiopathic choroidal neovascularization: a comparative study on visual acuity, retinal and choroidal thickness. *Chin Med J (Engl)* 2014; 127: 2279-2285.
- [30] Spaide RF. Rationale for combination therapies for choroidal neovascularization. *Am J Ophthalmol* 2006; 141: 149-156.
- [31] Moshfeghi AA, Rosenfeld PJ, Flynn HW Jr, Schwartz SG, Davis JL, Murray TG, Smiddy WE, Berrocal AM, Dubovy SR, Lee WH, Albin TA, Lalwani GA, Kovach JL, Puliafito CA. Endophthalmitis after intravitreal vascular [corrected] endothelial growth factor antagonists: a six-year experience at a university referral center. *Retina* 2011; 31: 662-668.