

Original Article

Intra- and extramedullary fixation combined with vacuum sealing drainage for selective treatment of open tibial fractures: a retrospective case series

Kai-Kai Tu^{1*}, Hang Li^{2*}, Bing-Li Bai², She-Ji Weng², Zong-Yi Wu², Viraj Boodhun², Zhen-Hua Feng², Liang Cheng², Lei Yang²

¹Department of Orthopedics Surgery, Xiaoshan Traditional Chinese Medical Hospital, Hangzhou, Zhejiang, China;

²Department of Orthopaedic Surgery, The Second Affiliated Hospital and Yuying Children's Hospital of Wenzhou Medical University, Wenzhou, Zhejiang, China. *Equal contributors.

Received May 28, 2017; Accepted January 15, 2018; Epub March 15, 2018; Published March 30, 2018

Abstract: The objective of this study was to introduce a novel method of percutaneous titanium elastic nails augmented by unilateral external fixator (BioEF-TENS system) combined with vacuum sealing drainage (VSD) technique and evaluate the effects in the management of open fractures of tibia. From January 2011 to June 2013, 15 patients (11M/4F) with a mean age of 41.6 years (16-60 years) were treated with this method. According to the Anderson-Gustilo classification, there were 3 cases defined as Gustilo I, 5 as Gustilo II, 3 as Gustilo IIIA, 2 as Gustilo IIIB and 2 as Gustilo IIIC. Follow-up was done at 1, 2, 3 months postoperatively, and then at 2 months intervals, to conduct clinical and radiographic examinations. The mean follow-up period of 15 patients was 18 months. After the VSD was removed, 3 patients needed skin-grafting and 2 case needed flap coverage. The external fixator was removed with a mean time of 23.3 weeks (18-45 weeks), the average union time is 29.8 weeks (21-56 weeks). Delayed union was observed in 3 patients and there was no case with mal-union. There were 3 cases with pin track infection which were treated after external fixator removal. Superficial wound infection was existed in one patient and was cured by intravenous sensitive antibiotics and VSD. No case was observed with decrease ROM or pain of the knee. And only one patient's ankle joint range of movement (ROM) was decreased by 20-25%. The results indicated that the BioEF-TENS system combined with VSD can achieve bone stability at one stage fixation operation, which not only avoids converting fixation but also obtains effective soft tissue protection, which is a novel technique for open fractures of tibia with certain indications and worthy for further research.

Keywords: Titanium elastic nails, external fixator, open tibial fractures, vacuum sealing drainage

Introduction

Open tibial fractures still remain one of the greatest challenges to orthopedic surgeons, together with periosteal stripping make open fractures related complications, such as delayed union, mal-union, nonunion, vascular damage, soft tissue damage, skin loss, compartment syndrome and infection [1, 2]. Damage to the bone causes unstable fracture, even bone defect and the high rate of bone healing complications [3, 4]. Therefore, the operative treatment of an open tibial fracture comprises two important parts: bone and soft tissue. The aim of treatment is ultimately achieving a normally aligned, standard length, united bone wi-

th good soft tissue coverage with absence of infection [5-7].

There are many optional treatments for open tibial fractures, but each of them has its own weakness and remains controversial. Traditional open reduction and internal fixation can achieve satisfactory reduction and stable fixation, while the increasing risk of soft-tissue injury, the high rate of infection and bone healing complications are more likely related [8, 9]. Intramedullary nailing (IMN) is already being recommended as an optional technique for Anderson-Gustilo Grade I or II open tibial fractures [10]. The negative effects such as postoperative knee pain, intramedullary infec-

BioEF-TENs + VSD for open tibial fractures

Table 1. Full demographic data and outcomes

No.	Sex (M/F)	Age (years)	Injury mode	Anderson-Gustilo	OTA	Associated injury	Additional interven	Union time (weeks)	Complication
1	M	25	T	IIIA	41B	HF	-	25	-
2	M	38	T	I	41A	BAT	-	22	PTI
3	M	16	T	I	42A	-	-	21	-
4	M	59	T	II	42B	FF	-	30	PTI
5	F	16	T	II	42A	-	-	26	-
6	M	58	T	IIIA	42B	BAT	SG	28	PTI
7	M	60	T	I	43A	-	-	27	WI
8	F	50	T	IIIB	43C	UDF	-	30	-
9	M	56	F	II	42B	HI	-	26	-
10	M	29	T	IIIC	42B	HI	FC	40	DU
11	M	39	F	IIIA	42C	FF	SG	31	-
12	F	30	T	II	42A	TSR+BAT	-	25	-
13	M	48	T	II	42A	BAT	-	28	AD
14	F	42	T	IIIC	43C	-	FC	56	DU
15	M	58	T	IIIB	42A	-	SG	32	DU

Note: T, traffic accident; F, fall from height; UDF, ulnoradial diaphyses fractures; F, femur fracture; HF, humerus fracture; HI, head injuries; PC, pulmonary contusion; TSR, traumatic splenic; BAT, blunt abdomen trauma; SG, skin-grafting; FC, flap coverage; DU, delayed union; AD, angulation deformity; PTI, pin track infection; WI, Wound infection.

tion, destruction of the endomedullary blood supply and more hidden blood loss also should be taken into consideration [11, 12]. The external fixator (EF) has a defined place in treatment of open tibia fractures especially Gustilo III fractures, for its process being simple, soft-tissue being slightly affected, no periosteal stripping and less blood-supply attenuated at the fracture site [13, 14]. But, delayed union, mal-union, and nonunion remains the intractable complications associated with unilateral external fixator [14-17], which has to undergo a secondary operation to convert it to another rigid internal fixation where the soft tissue damage is controlled [12, 18]. Vacuum sealing drainage (VSD) has proved to be an effective approach for protecting the wound, decreasing infection, prompting granulation growth and accelerating wound healing in the extremities [14, 19-22].

In order to explore a better treatment for open tibial fractures, we develop a novel technique, percutaneous intra- and extramedullary fixation (BioEF-TENs system) [23-26] combined with vacuum sealing drainage (VSD). The purpose of this study is to introduce this BioEF-TENs + VSD technique and evaluate the results of its application in open fractures of tibia.

Materials and methods

Patients

From January 2011 and June 2013, 15 patients (11M/4F) with open tibial fractures were included in this study and treated with titanium elastic nails (Synthes Bettlach Inc., Switzerland) augmented by unilateral external fixator (Orthofix Srl Inc., Italy) combined with vacuum sealing drainage (Wego Newlife Co.Ltd., Shandong, China). The mean age of the patients was 41.6 years (range, 16-60 years). According to the Anderson-Gustilo classification, there were 3 cases defined as Gustilo I, 5 as Gustilo II, 3 as Gustilo IIIA, 2 as Gustilo IIIB and 2 as Gustilo IIIC, with or without concomitant fibula fracture. And the fractures were defined according to the classification of the Orthopedic Trauma Association (OTA), which were presented in **Table 1**. Traffic accident was the most common mode of injury in thirteen patients, and fall from height was only in two cases. Four patients had additional fractures, two ulnoradial diaphysis fractures, one femur fracture, and one humerus fracture. Other organ injuries were presented in seven patients, two cases with head injuries, one with pulmonary contusion and slight pleural effusion, another

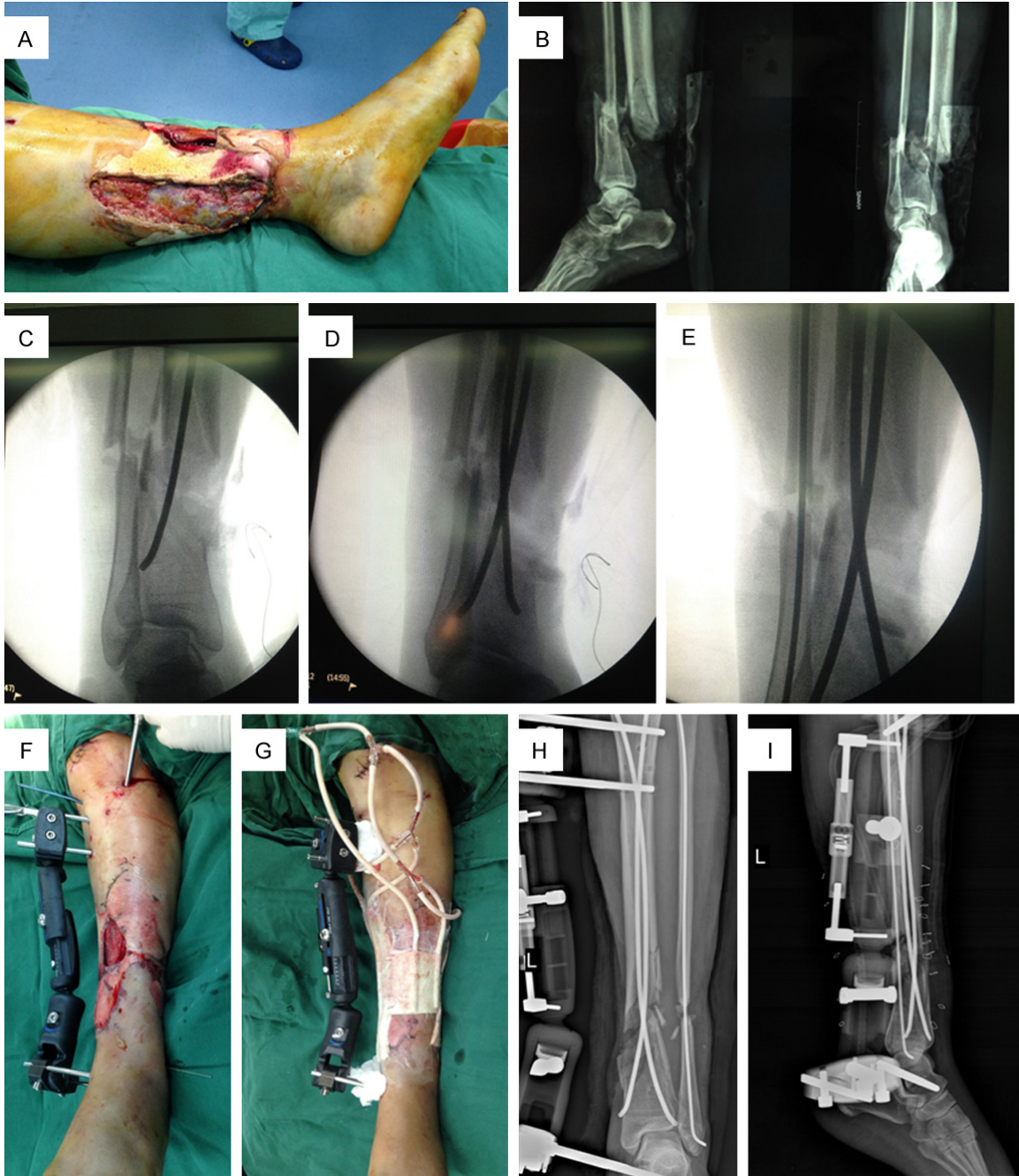

Figure 1. A 50-year-old female with Gustilo IIIB and 43C fracture of the left tibia and fibula, and also sustained an injury of the left femur (A). The X-ray presented a distal tibia and fibula fracture which is not fit for interlocking intramedullary nail because of lock or barrier screws with no enough working length (B). The tibia and fibula fracture was managed by titanium elastic nails and external fixation in sequence (C-F). The photos showed that the vacuum sealing drainage was performed after the fracture was treated with intra- and extramedullary fixation (G). The post-operative X-ray images of this case (H, I).

patient with traumatic splenic rupture and three cases with blunt abdomen trauma. The traumatic splenic rupture case was treated with splenectomy, and the other organ injuries were managed conservatively.

Therapeutic method

All the 15 cases received early antibiotic treatment. Gustilo I and II fractures were treated with cefazolin. Patients with penicillin allergy

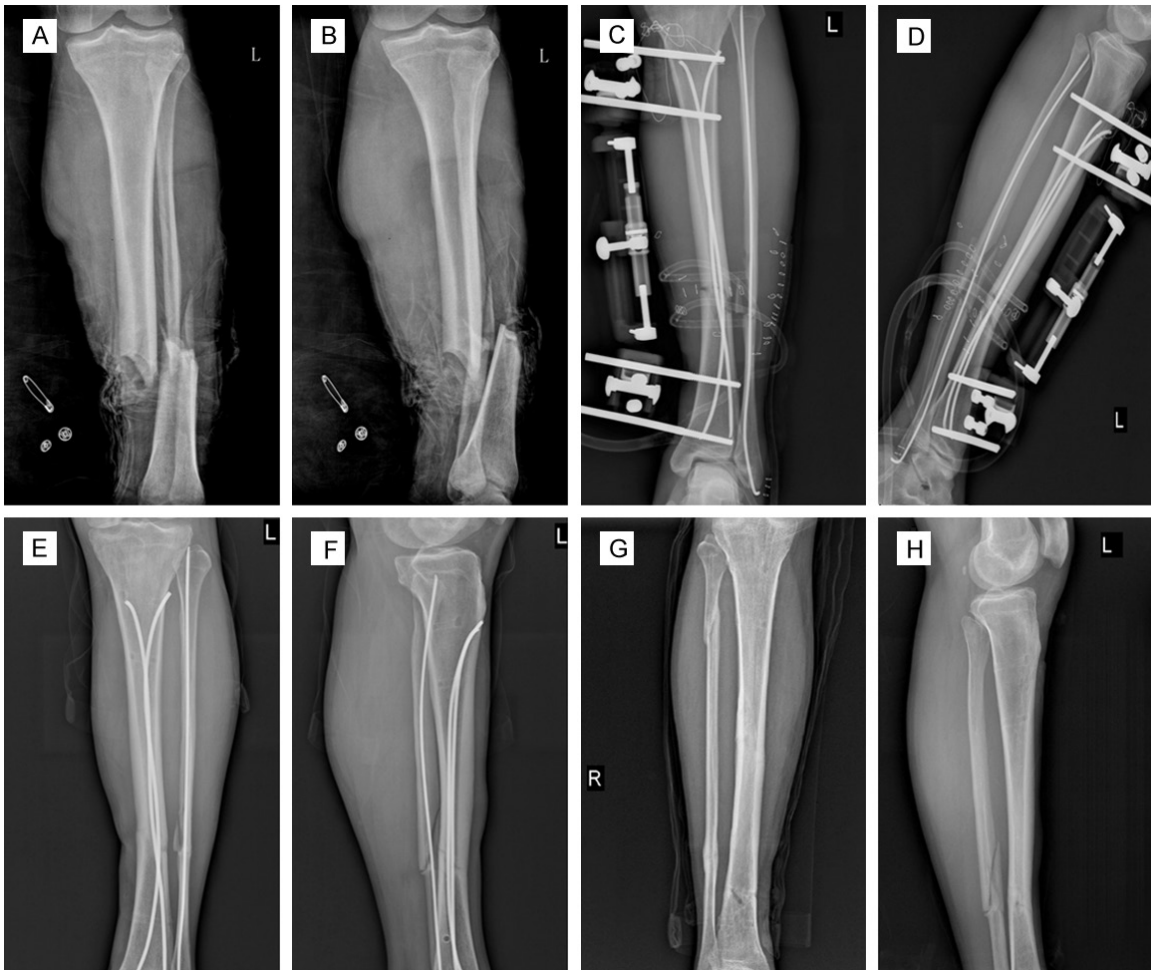


Figure 2. Another Gustilo IIIB,42A tibial and fibular fracture, a 58-year-old male, treated with external fixation combined with titanium elastic nails and vacuum sealing drainage. Preoperative (A, B), early postoperative (C, D), removal of external fixation (E, F), removal of two titanium elastic nails (G, H).

were given clindamycin as substitution for the cefazolin. Gustilo III fractures received both cefazolin and gentamicin due to the high amount of contamination in these wounds. Each protocol employed modern aggressive debridement techniques. All necrotic and devascularized tissues including bone were removed. Multiple irrigation and debridement procedures were performed until the wound was clean and all tissues viable [10]. After that, the preliminary closed reduction was performed under C-arm fluoroscopy. Then, according to the situation of the fibula fracture, we choose whether to fix the fibula fracture with elastic nail before dealing with the tibial fracture or not. Thereafter at lateral and medial of the proximal (anterograde) or distal (retrograde) tibia, a 1-2 cm longitudinal incision was made then the TENs was inserted in an anterograde or retrograde direction according to soft tissue si-

tuation of the enter point positions and distal or proximal occult fracture (**Figure 1A-E**). After this, unilateral orthofix external fixator was installed (**Figure 1F**) [23]. As to open grade IIIC fractures in our study, where the blood vessels needed to be reconstructed as far as possible, they were all done in one-staged microsurgery procedure and included building a soft tissue bed to have a relatively better coverage. After these procedures were done, they were covered with Vacuum Sealing Drainage (VSD) (**Figure 1G**). Skin-grafting was done when healthy granulation tissue was proliferated. Flap coverage was required in certain cases where bone was exposed.

Observation and measurement

Follow-up time was at 1 month, 2 months and 3 months postoperatively, and then at 2 mon-

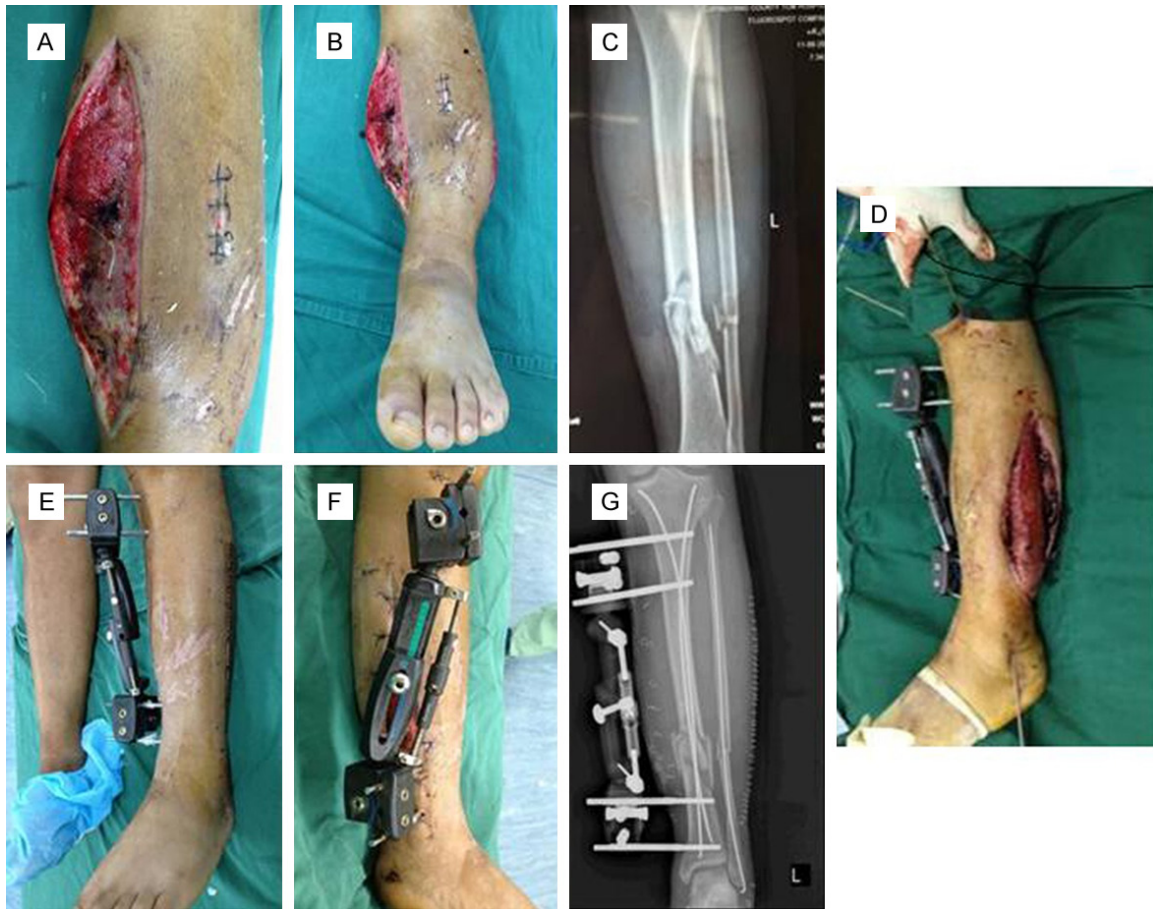

Figure 3. A Gustilo II, 42B fracture occurred osteofascial compartment syndrome with early incision decompression (A-C). The picture presented the fracture was treated with BioEF-TENs system (D). The photos showed that the wound was closed at early stage after dismantling the VSD device (E, F). The postoperative X-ray image of this case (G).

ths intervals, including clinical and radiographic examinations [27]. During the visit, observation of the wound and pin track condition and making sure of the function of the knee and ankle joint were monitored. With callus formed gradually, we loosened compressive blot and removed its rod, and finally removed the external fixator step by step in order to generate dynamisation at fracture site in vitro.

Results

Full demographic data and outcomes are presented in **Table 1**. In this series of 15 patients, the fractures follow-ups were on average 18 months then they were available for final evaluation. Regarding the management of soft tissue, all fractures were covered with Vacuum Sealing Drainage. After the VSD was removed, 3 patients needed skin-grafting and 2 cases

needed flap coverage. All of the graft skin and coverage flaps were successful. There was no case of nonunion or malunion, the average union time was 29.8 weeks (range, 21-56 weeks). There was a case, a 48-year-old male, who sustained a distal comminuted fracture, had a coronal angulation in 5° and sagittal angulation in 4°. Delayed union was observed in 3 patients, whose consolidation of fractures and possibility of full weight-bearing was gained by physiotherapy and drug therapy. The external fixator was removed with a mean time of 23.3 weeks (range, 18-45 weeks). One of the main complications mentioned in this study was pin track infection, which involved 3 cases. Wound infection was present in one patient, without deep infection. The 3 cases of pin track infection were all successfully cured after EF removal. The wound infection was successfully treated with dressing

change, intravenous antibiotics and VSD. In all patients, neither had restricted ROM of knee nor knee pain. While, compared with the contralateral side, one patient's ankle joint range of movement (ROM) was decreased by 20-25%. The case with restricted function in the ankle was a Gustilo IIIB fracture. The typical cases are shown in **Figures 1A-I, 2A-H and 3A-G**.

Discussion

Although traditional plates can achieve satisfactory reduction and stable fixation, there was increasing risk of aggravating soft-tissue injury, possibility of infection and high rate of bone healing complications were more likely related in open tibial fractures. In a systematic review of the literature, Giannoudis et al. [28] reported 492 open tibial fractures treated with plates, union rate ranged from 62% to 95%, time to union ranged from 13 to 42 weeks, reoperation rate ranged from 8% to 69% and a pooled estimate of deep infection rate calculating at 11%. The Gustilo III tibial fractures are often caused by high velocity trauma resulting in great possibility of comminution and instability. Grade III is characterised by a wide spectrum of damage to soft tissue including skin, muscles, even neurovascular tissues and a high degree of contamination. Intramedullary nailing (IMN), with postoperative knee pain, destruction of the endomedullary blood supply, more hidden blood loss and the increasing possibility of intramedullary contamination, is usually not applied in open grade III tibial fractures. Keating et al. [29] reported that reamed nails offered an improved stability of the fracture, but their management carried an increased risk of infection and nonunion as result of disruption of the endosteal blood supply. The external fixator has a defined place in open tibial fractures as we have mentioned. However, the high rate of malunion and nonunion should be taken into consideration due to unstable fixation by unilateral external fixator and usually need a secondary intervention to convert to more rigid fixation. A systematic review of 536 open tibial fractures treated by external fixator showed that union had occurred in 94% at a mean time of 37 weeks, the overall incidence of delayed union after 6 months was 24%, and the rate of mal-union was up to 20% [16].

Therefore, preserving the vulnerable soft tissue envelope and regaining relatively accurate reduction and stable fixation become especially important. Thus, in this study we developed this novel intra- and extra-medullary fixation technique combined with vacuum sealing drainage to deal with open tibial fractures. Although with a small number of patients, the results of our treatment option are encouraging. The novel mixed fixation not only preserves the advantages of single external fixator in open fractures, but also increases the reduction accuracy and enhances the fixation system stability with the additional titanium elastic nails through closed reduction, which contributes to lessen the risk of nonunion and mal-union. Furthermore, gradual dynamization could be achieved following these steps in BioEF-TENS. It is different from Intramedullary nailing which needs to remove the distal locking screws to achieve dynamization with re-operation in vivo. According to clinical and mechanical research, bone healing was enhanced subjected to micro-movement and dynamization [30, 31]. Compared with routine unilateral external fixator, the external fixator was removed earlier with a mean time of 23.3 weeks in this BioEF-TENS system, which finally decreased the rate of pin track infections and facilitated the daily life.

According to the concept of damage control, we should avoid any additional injury caused by the surgical procedure to the soft tissue [32]. Giannoudis et al. [28] reported a pooled estimate of deep infection rate calculating at 11% in their study. The risks of increasing incidence of infection and osteomyelitis which resulted from prolonged open wound exposure were under control in our study. Wound infection was existent in one patient but no deep infection. The two aspects following may expound the reasons.

On one hand, vacuum sealing drainage not only protected the wound, eliminated dead cavity, and prevented infection, but also stimulated healthy granulation tissue proliferation. Thus, it created a biological environment for skin-grafting, reduced postoperative complications, and promoted functional limb recovery [19-22]. On the other hand, this novel fixation method, unlike plates or IM nails, is a percutaneous and minimally invasive surgical tech-

nique, which did not increase further damage to stimulation of the soft tissue at the fracture site, affect soft tissue coverage nor increase the possibility of intramedullary contamination. Even with Gustilo IIIC fractures, these patients' blood vessels can also be reconstructed in one-staged microsurgery procedure with this method.

In conclusion, the percutaneous intra- and extramedullary fixation combined with vacuum sealing drainage technique is suitable for Gustilo I and Gustilo II open tibial fractures, even Gustilo III open tibial fractures, which can achieve bone stability at one stage fixation operation, and not only avoids converting fixation but also obtains effective dynamization in vitro. Hence, the BioEF-TENs system combined with VSD is a novel technique with certain indications and worth to do further research.

Acknowledgements

We would like to acknowledge The Second Affiliated Hospital and Yuying Children's Hospital of Wenzhou Medical University Trauma Orthopaedic Registry for access to their data and cooperation with the research project.

Disclosure of conflict of interest

None.

Address correspondence to: Dr. Lei Yang, Department of Orthopaedic Surgery, The Second Affiliated Hospital and Yuying Children's Hospital of Wenzhou Medical University, Wenzhou, Zhejiang, China. Tel: +86 188-5873-6092; Fax: 86-577-88002823; E-mail: lihtc@163.com

References

- [1] Hull P. The management of open tibial fractures. *Eur J Orthop Surg Traumatol* 2008; 18: 441-7.
- [2] Rajasekaran S. Early versus delayed closure of open fractures. *Injury* 2007; 38: 890-5.
- [3] Rajasekaran S, Naresh Babu J, Dheenadhayan J, Shetty AP, Sundararajan SR, Kumar M, Rajasabapathy S. A score for predicting salvage and outcome in Gustilo type-IIIa and type-IIIB open tibial fractures. *J Bone Joint Surg Br* 2006; 88: 1351-60.
- [4] Sen C, Kocaoglu M, Eralp L, Gulsen M, Cinar M. Compression-distraction in the acute treatment of Grade III open tibia fractures with bone and soft-tissue loss: a report of 24 cases. *J Orthop Trauma* 2004; 18: 150-7.
- [5] Behrens F, Searls K. External fixation of the tibia. Basic concepts and prospective evaluation. *J Bone Joint Surg Br* 1986; 68: 246-54.
- [6] French B, Tornetta P 3rd. High-energy tibial shaft fractures. *Orthop Clin North Am* 2002; 33: 211-30.
- [7] Cross WW, Swiontkowski MF. Treatment principles in the management of open fractures. *Ind J Orthop* 2008; 42: 377-86.
- [8] Im GI, Tae SK. Distal metaphyseal fractures of tibia: a prospective randomized trial of closed reduction and intramedullary nail versus open reduction and plate and screws fixation. *J Trauma* 2005; 59: 1219-1223.
- [9] Hasenboehler E, Rikli D, Babst R. Locking compression plate with minimally invasive plate osteosynthesis in diaphyseal and distal tibial fracture: a retrospective study of 32 patients. *Injury* 2007; 38: 365-370.
- [10] Mundi R, Chaudhry H, Niroopan G, Petrisor B, Bhandari M. Open tibial fractures: updated guideline for management. *JBSJ REVIEWS* 2015; 3: 1-7.
- [11] Nork SE, Schwartz AK, Agel J, Holt SK, Schrick JL, Winquist RA. Intramedullary nailing of distal metaphyseal tibial fractures. *J Bone Joint Surg Am* 2005; 87: 1213-1221.
- [12] Pairon P, Ossendorf C, Kuhn S, Hofmann A, Rommens PM. Intramedullary nailing after external fixation of the femur and tibia: a review of advantages and limits. *Eur J Trauma Emerg Surg* 2015; 41: 25-38.
- [13] Fadel M, Ahmed MA, Al-Dars AM, Maabed MA, Shawki H. Ilizarov external fixation versus plate osteosynthesis in the management of extra-articular fractures of the distal tibia. *International Orthopaedics* 2015; 39: 513-519.
- [14] Liu L, Tan G, Luan FJ, Tang X, Kang PD, Tu CQ, Pei FX. The use of external fixation combined with vacuum sealing drainage to treat open comminuted fractures of tibia in the Wenchuan earthquake. *International Orthopaedics* 2012; 36: 1441-1447.
- [15] Ronga M, Longo UG, Maffulli N. Minimally invasive locked plating of distal tibia fractures is safe and effective. *Clin Orthop Relat Res* 2010; 468: 975-82.
- [16] Giannoudis PV, Papakostidis C, Roberts C. A review of the management of open fractures of the tibia and femur. *J Bone Joint Surg Br* 2006; 88: 281-9.
- [17] Ramos T, Eriksson BI, Karlsson J, Nistor L. Ilizarov external fixation or locked intramedullary nailing in diaphyseal tibial fractures: a randomized, prospective study of 58 consecutive patients. *Arch Orthop Trauma Surg* 2014; 134: 793-802.
- [18] Sigurdson U, Reikeras O, Utvag SE. Conversion of external fixation to definitive intramedullary nailing in experimental tibial fractures. *J Invest Surg* 2010; 23: 142-8.

BioEF-TENs + VSD for open tibial fractures

- [19] Babiak I. Open tibial fractures grade IIIC treated successfully with external fixation, negative-pressure wound therapy and recombinant human bone morphogenetic protein 7. *Int Wound J* 2014; 11: 476-82.
- [20] Liu DS, Sofiadellis F, Ashton M, MacGill K, Webb A. Early soft tissue coverage and negative pressure wound therapy optimises patient outcomes in lower limb trauma. *Injury* 2012; 43: 772-8.
- [21] Stannard JP, Volgas DA, Stewart R, McGwin G Jr, Alonso JE. Negative pressure wound therapy after severe open fractures: a prospective randomized study. *J Orthop Trauma* 2009; 23: 552-7.
- [22] Hou Z, Irgit K, Strohecker KA, Matzko ME, Wingert NC, DeSantis JG, Smith WR. Delayed flap reconstruction with vacuum-assisted closure management of the open IIIB tibial fracture. *J Trauma* 2011; 71: 1705-8.
- [23] Tu KK, Zhou XT, Tao ZS, Chen WK, Huang ZL, Sun T, Zhou Q, Yang L. Minimally invasive surgical technique: percutaneous external fixation combined with titanium elastic nails for selective treatment of tibial fractures. *Injury* 2015; 46: 2428-32.
- [24] Yu Y, Chen WK, Cui W, Zhou YF, Chen H, Yang L. Minimally invasive elastic intramedullary nailing combined with external fixation in the treatment of comminuted closed tibial fractures. *Chin J Orthop Traumatol* 2015; 28: 412-416.
- [25] Chen WK. Percutaneous minimally invasive external fixator combined with elastic stable intramedullary nailing for treatment of serious comminuted tibial fracture: a biomechanical and clinical study [D]. University of Wenzhou medical college, 2013. (In Chinese).
- [26] Lv YX, Chen WK, Cui W, Zhou XT, He XW, Yang L. An intra- and extramedullary mixed fixation technique for tibial fractures. *Zhejiang Medical Journal* 2014; 36: 709-12. (In Chinese).
- [27] Johner R, Wruhs O. Classification of tibial shaft fractures and correlation with results after rigid internal fixation. *Clin Orthop* 1983; 178: 7-25.
- [28] Giannoudis PV, Papakostidis C, Kouvidis G, Kanakaris NK. The role of plating in the operative treatment of severe open tibial fractures: a systematic review. *International Orthopaedics* 2009; 33: 19-26.
- [29] Keating JF, O'Brien PJ, Blachut PA, Meek RN, Broekhuysen HM. Locking intramedullary nailing with and without reaming for open fractures of the tibial shaft. *J Bone Joint Surg Am* 1997; 79: 334-41.
- [30] Kenwright J, Richardson JB, Cunningham JL, White SH, Goodship AE, Adams MA, Magnusson PA, Newman JH. Axial movement and tibial fractures: a controlled randomised trial of treatment. *J Bone Joint Surg Br* 1991; 73: 654-9.
- [31] Egger EL, Gottsauner-Wolf F, Palmer J, Am HT, Chao EY. Effects of axial dynamization on bone healing. *J Trauma* 1993; 34: 185-92.
- [32] Taeger G, Ruchholtz S, Waydhas C, Lewan U, Schmidt B, Nast-Kolb D. Damage control orthopaedics in patients with multiple injuries is effective, time saving and safe. *J Trauma* 2005; 59: 408-15.