

Original Article

Curative effects of combination therapy with 4-in-1 osteosynthesis and surgical techniques against congenital pseudarthrosis of the tibia in children

An Yan, Haibo Mei, Kun Liu, Jin Tang, Jiangyan Wu, Guanghui Zhu

Department of Orthopedics, Hunan Children's Hospital, Changsha, P. R. China

Received September 17, 2017; Accepted March 22, 2018; Epub June 15, 2018; Published June 30, 2018

Abstract: Congenital pseudarthrosis of the tibia (CPT) is a rare disease with a variable history. The treatment of CPT remains especially controversial and difficult. In this study, we investigated the outcomes of 4-in-1 osteosynthesis and combined surgical techniques for CPT, and hypothesized that 4-in-1 osteosynthesis and combined surgical techniques could affect the healing of CPT in children patients. Forty cases of CPT treated with 4-in-1 osteosynthesis and combined surgical techniques during March 2012 to March 2016 were collected. The surgical methods included autogenous iliac bone graft, resection of pseudarthrosis of the tibia and surrounding affected tissues, intramedullary rod and Ilizarov external fixation, union of the tibia and fibula during which 4-in-1 osteosynthesis and wrapped autogenous iliac bone graft were performed simultaneously. After the surgery, lengthening with external fixation was paid attention and patients were instructed to do functional exercises. Ohnishi X-ray grading standard and Malhotra ankle valgus grading method were used for healing evaluation. Lateral distal tibial angle (LDTA), interior distal tibial angle (ADTA) and tibial length were measured. Follow-up was performed during which the patients received X-ray examination every 3 months. Among the 40 cases, 26 cases showed early healing (65.0%), 22 cases showed ankle valgus (55.0%) and 17 cases suffered from refracture (42.5%). The patients with Crawford IV or a family history of neurofibromatosis showed comparatively higher ankle valgus rate and refracture rate. Tibial length inequality was observed in 21 cases (52.5%). In different groups, the incidence of tibial length inequality was 33.3%~100.0%, with an average length of 0.41-1.98 cm. LDTA value was ranged from 79.7° to 96.1° and ADTA value from 78.5° to 90.9°. The ratio of cross-sectional area of healing region was 1.8-3.9 and the average value was 2.7. The patients with Crawford IV or neurofibromatosis showed decreased cross-sectional area of healing region. Taken together, we concluded that the 4-in-1 and combined with the surgical techniques could enlarge the cross-sectional area of healing region of CPT and decrease the refracture rate in children with CPT.

Keywords: 4-in-1 osteosynthesis, surgical techniques, congenital pseudarthrosis of the tibia, early healing, ankle valgus, refracture

Introduction

Congenital pseudarthrosis of the tibia (CPT) is a rare but severe congenital tibial dysplasia that occurs in children population, with congenital anterolateral bowing of the tibia as the biomarker of CPT [1, 2]. So far, the etiology of CPT is still not clear, and the available epidemiological data on patients with CPT are not sufficient. Nevertheless, it is reported that about 55% of the patients of pseudarthrosis and anterolateral bowing are related with neurofibromatosis [3]. Fibrous hamartoma with low osteogenicity and high osteoclastogenicity is also considered as a possible pathology of CPT [4]. The objective of CPT treatment is mainly for

maintenance of long-run bone union, prevention of limb length inequality, mechanical axis deviation as well as pathological fracture [5]. There are mainly three methods of surgical techniques in common use including intramedullary nailing with bone graft, vascularized bone transfer as well as Ilizarov treatment [6]. It is unnecessary to defer surgery for CPT until the child exceeds 3 years of age [7]. However, the therapy effects of the combined surgical techniques in treatment of CPT were not satisfactory due to the unavoidable results of amputation and severe disability [8]. Therefore, it is still necessary to find a novel technique to assist with the surgical techniques applied in CPT treatment.

Application of 4-in-1 osteosynthesis in CPT

Generally, 4-in-1 osteosynthesis is a technique that places all of the 4 proximal and distal segments of the tibia and fibula in 1 healing mass so as to obtain bony union with cross-sectional area in a large scale and ankle stability, and this technique has recently been reported to be potential for application in atrophic-type CPT [9]. In the course of tibial osteosynthesis, in order to maintain normal ankle mortise and union, end-to-end osteosynthesis is preferred to be used and 4-in-1 osteosynthesis could be helpful when dysplasia of pseudarthrotic fibula occurs [10]. According to a previous study, minimally invasive plating osteosynthesis technique is promising method for treatment of distal tibial and fibular fractures [11]. In addition, other osteosynthesis techniques such as physeal and subphyseal distraction osteogenesis are also revealed as possible methods for treatment of CPT [12]. It has been reported that osteosynthesis could combine with bone graft to treat pseudarthrosis of the scaphoid, and in this way a carpal collapse could be prevented [13]. However, the application of 4-in-1 osteosynthesis in combined surgical techniques for treatment of CPT is rarely studied and still remains unclear. Considering the potential function of 4-in-1 osteosynthesis in bony union, which plays an important part in CPT healing, we applied it in the conventional combined surgical techniques. Therefore, this study aimed to explore the application of 4-in-1 osteosynthesis in combined surgical techniques, with the hope of finding a novel treatment for CPT.

Materials and methods

Ethics statement

This research was approved by the Ethics Committee of Hunan Children's Hospital, and all patients or their guardians signed the informed consent.

Study subjects

Forty CPT patients treated with 4-in-1 osteosynthesis and combined surgical techniques during March 2012 to March 2016 were collected. Baseline characteristics of the CPT patients were analyzed. The inclusion criteria were as follows: (1) patients were definitely diagnosed with CPT with the following clinical manifestations: bending deformation in the anterolateral part of the calf; changes detected

by X-ray images including tibial angulation, diaphyseal medullary stenosis, cyst and sclerosis [14]; (2) patients were treated with the same surgical method (4-in-1 osteosynthesis and combined surgical techniques) by the same surgical group of Orthopedics in Hunan Children's Hospital; (3) patients were with integrated follow-up records. The exclusion criteria were as follows: (1) patients were infected with acquired pseudarthrosis induced by other pathogenic factors (trauma, osteomyelitis, bone tumor, etc.) or other concurrent tibial lesions; (2) patients were not treated with the same surgical method (combined surgical techniques including sleeve resection of the lesioned tissues of pseudarthrosis of the tibia, intramedullary rod fixation, wrapped autogenous iliac bone graft and Ilizarov external fixation + 4-in-1 osteosynthesis) by the same surgery group of Orthopedics in Hunan Children's Hospital; (3) patients were treated with other surgical methods in Hunan Children's Hospital.

Preoperative preparation

The routine preoperative examinations were performed, including chest radiograph, electrocardiogram, routine blood test and hepatorenal function examination. Preoperative interview was conducted: the location of the lesion was determined and the relative skin was prepared one day before the surgery, including the skin at the diseased limb and contralateral hip; the patients were diagnosed with no systemic or local infectious diseases; the patients had no operative contraindication. Conventional instruments were prepared, and the X-ray and computerized tomography (CT) were used to measure the internal diameter of the narrowest marrow cavity in the tibia, the numerical value lower than which was considered as the diameter of the implanted tibial intramedullary rod. Next, the length of the proximal pseudarthrosis of the tibia and tibial tuberosity after the resection of pseudarthrosis of the tibia, and the distal pseudarthrosis of the tibia and the plantar surface were measured, respectively, the sum of which was the length of the implanted bone. Then the intravenous cannula was established in order to assist the anesthesiologist to give anesthesia. The patients were treated with blood transfusion and infusion, and the infusion fluid was timely replaced. The patency of the intravenous cannula was maintained to keep the stability of the internal circulation.

Application of 4-in-1 osteosynthesis in CPT

Surgical methods

The children patients were kept in supine position under complete anesthesia with trachea cannula. A sterile towel was placed under the ipsilateral buttock. The iliac region, calf and foot surgery were completely disinfected by 0.5% (5 g/L) iodine complex and 75% ethanol. Autogenous iliac bone graft was conducted as follows: the outer edge of the iliac crest on the opposite side of affected limb was chosen as the first incision (about 6 cm). The external iliac plate was exposed under the normal periosteum. Next, a completely square cortical bone of the external iliac plate (about 4.0 cm × 2.5 cm, the specific size depends on children patients' age) was extracted, and moderate amount of cancellous bone was obtained and restored as bone graft material. The integrity of the iliac cortical bone was maintained, and the square cortical bone was pierced by Kirschner wire, with each hole passed through the absorbable suture, and the suture lines prepared on the four sides of the square as the traction lashing line. With small rongeurs, the sutured iliac cortical bone was gradually molded into a cylindrical shape for use in subsequent wrapped bone grafts. Resection of pseudarthrosis of the tibia and surrounding affected tissues was performed as follows: with pseudarthrosis of the tibia as the centre, the lateral part was cut into an about 6-cm longitudinal incision, layer-by-layer. The diseased periosteum and tissues around pseudarthrosis of the tibia were exposed and pseudarthrosis of the tibia was densely surrounded by the tissues (5 mm), followed by complete sleeve resection of the affected tissues. The rongeurs was used to remove the tibial stump lesion, and the sclerotic tibial stump and closed marrow cavity could be seen. An electric drill was applied to reopen the marrow cavity with the tibial length maintained as long as possible and amplify the marrow cavity on the sclerotic side of the tibial pseudarthrosis to normal size. Next, a titanium alloy Kirschner wire (1 mm of diameter) was used to penetrate through the distal pseudarthrosis of the fibula and finally penetrated out of the skin from the lower back of the lateral malleolus. (3) Intramedullary rod fixation was carried out as follows: the intramedullary rod (the implanted rod was connected with the inserting rod) with previously selected diameter and length according to the preoperative preparation was used to penetrate from the distal

pseudarthrosis of the tibia, across the central part of the iliac plate, through the talus and calcaneus and out from the planta pedis. The same method was applied in reverse direction to penetrate the rod into the proximal marrow cavity in order to reach tibial tuberosity. Afterwards, the inserting rod was removed and the rear part of the implanted rod was embedded beneath the plantar dermis. The Kirschner wire was penetrated from the distal pseudarthrosis of the fibula through the proximal marrow cavity of pseudarthrosis of the tibia, in order to reach tibial tuberosity of the proximal fibula. Then the needle tail of the Kirschner wire was bent and restored below the skin at the lower back of the lateral malleolus. Ilizarov external fixation was conducted as follows: before the surgery, the Ilizarov external fixator was customized according to the length and cross section diameter of the calf of patients' diseased limb. According to the preoperative design, 2-3 Kirschner wires with the diameter of 1.5-2 mm were penetrated from the proximal and distal tibia parallel to the iliac plate in a multi-plane intersecting way. The two sides of the Kirschner wire were connected with all rings of the Ilizarov external fixator and the fixator was pressurized for fixation. Union of the tibia and fibula was performed as follows: 4-in-1 osteosynthesis and wrapped autogenous iliac bone graft were conducted, simultaneously. Kirschner wire was applied to punch holes on the fibula and the suture line was used to attach the tibia with the proximal and distal fibula, separately. The posterior tibia and fibula was tightly packed with massive cancellous bones, and the anterior part was packed with a cortical bone, after which the suture line was used to tie a knot. The proximal and distal tibia was placed together with the proximal and distal fibula, respectively. The autogenous iliac bone cortex previously bent into a cylindrical shape was used to wrap pseudarthrosis of the tibia and the proximal and distal tibia of 2 cm range from the back of tibia to the front. Next, the previously obtained cancellous bones were padded into pseudarthrosis of the tibia and the cylindrical shaped cortex bone. The traction lashing line was pulled taut, and knotted and fixed by the previously prepared absorbable suture line. A negative pressure drainage tube was conventionally placed in the incision of the calf and then the incision was sutured layer-by-layer. C-arm X-ray image analysis: the images from the C-arm X-ray machine showed good line alignment and position alignment. The posi-

Application of 4-in-1 osteosynthesis in CPT

tions of local wrapped bone graft, tibial intramedullary rod and fibular Kirschner wire were all suitable and satisfactory. At the same time, the Ilizarov external fixator was firmly fixed.

Postoperative treatment

After the surgery, the children patients were sent back to the care ward. Before the patients were fully awakened from anesthesia, the pillow was removed, and the patients were kept in a supine position. The shoulder of the patients was heightened and the head was deflected to another side. The airway was kept unobstructed in prevention of nausea and suffocation. The diseased limb was lifted up to the position slightly higher than the horizontal position of the heart, which was beneficial for venous return and alleviation of lower limb swelling. The bleeding symptom was closely observed, especially the swelling and tension of the diseased limb. The patency of the drainage tube was closely observed. At 3 days after surgery, the drainage volume was generally small, and at that time the drainage tube was removed. The condition of children patients was timely reported when the blood volume exceeded 100 mL within 24 hours. If insufferable pain occurred, which was induced by limb swelling and neurovascular problem, the pump was used for analgesia. At the same time, the children patients were instructed to listen to the music, read the cartoon and chat with others, in order to divert their attention, and they took oral analgesic when it was necessary.

Nursing for lengthening with external fixation

The external fixation was kept in a suitable elasticity without displacement, and the loose part of which was timely adjusted in prevention of refracture caused by the external fixation. Under the guidance of the attending doctor, the two units composed of Kirschner wire and ring were adjusted to a suitable angle. At the same time, the surgical site of the patients was pressurized for fixation and the proximal tibia was lengthened. The needle eye was dropwise added with 75% ethanol once to twice, in order to clean and disinfect the external fixation. At 7 days after surgery, the proximal tibia was gently lengthened 0.5 mm every day, and completed within 2~4 times. During the lengthening process, the state of the patients was carefully observed, including the body temperature, skin

color, blood transportation of the limb, general feeling and toe movement. Severe swelling and hypoesthesia observed in the patients were timely reported to the attending doctor for adjustment. Regular examinations were performed to confirm whether the direction for limb lengthening was correct and whether the Kirschner wire was distorted. The patients were not allowed to do intense movement which could affect bone fracture healing. At the same time, the X-ray line was reviewed every week to obtain bone healing information.

Postoperative functional exercises

Early functional exercises could effectively prevent ankylosis and muscular atrophy. Within 2 weeks after surgery, substantial movement was not suitable for the children patients. The children patients were instructed to take toe flexion and extension exercises, which could prevent foot drop. At 3-6 weeks after surgery, the children patients were instructed to take exercises including isometric contraction of musculus quadriceps of humerus and ankle dorsiflexion, in prevention of muscular atrophy and joint stiffness. Besides, patients were instructed to take the initiative in the right way to exercise. The diseased limb was fixed by the plaster cast for more than 2 months and the X-ray line was reviewed. With the approval of the attending doctor, the plaster cast was removed after diagnosis, and the patients could walk with the crutch under the protection of the tibial tubercle bearing brace. When the callus appeared, the load was gradually elevated. The exercises were taken gradually in prevention of tissue injury and bone fracture.

Healing evaluation

The healing of CPT was evaluated according to the X-ray grading standard for pseudarthrosis of the tibia proposed by Ohnishi [15], which was classified into pseudarthrosis healing, delayed healing and non-healing. The healing standard was that the lateral X-ray film showed nearly uniform cortical density of two sides of the pseudarthrosis with sufficient thickness and without obvious density reduction region. The delayed healing presented signs of healing at a slow speed, and the termination of healing referred to non-healing. The outcome of ankle valgus was evaluated with Malhotra ankle valgus grading method [16] (**Figure 1**): Grade 0

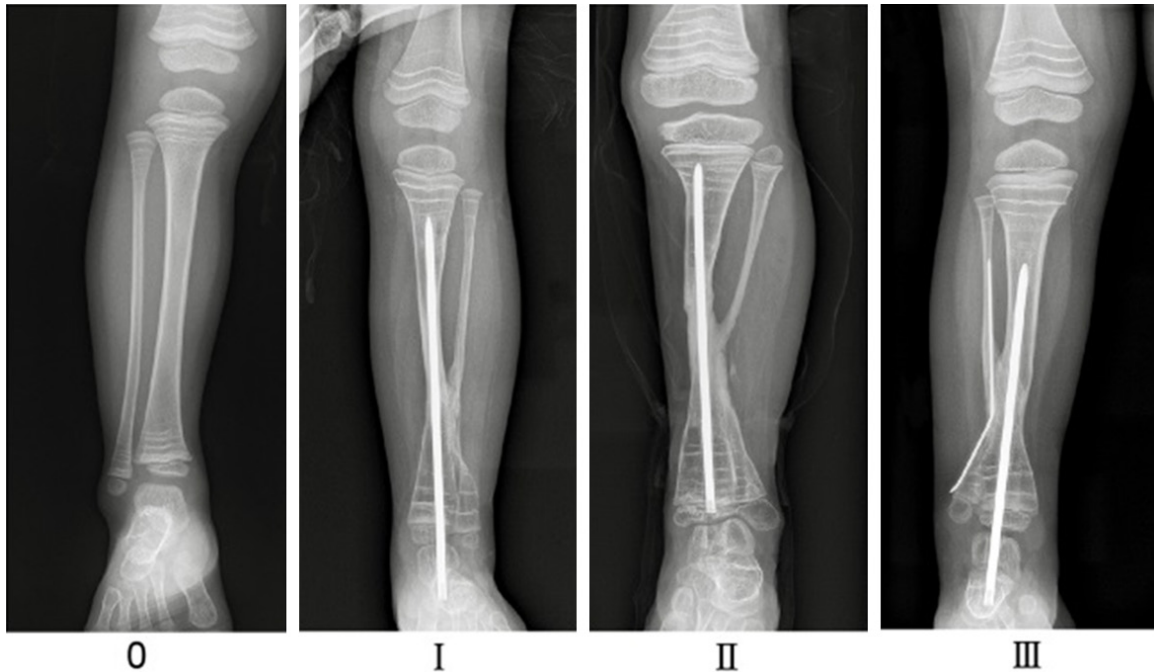

Figure 1. Malhotra ankle valgus grading method.

presents that no ankle valgus occurs and the distal tibia epiphyseal line is horizontal to the malleolar crest of ankle; Grade I presents that the distal fibular epiphyseal line is located at the malleolar crest and is horizontal to the distal tibia epiphyseal line; Grade II presents that the fibular epiphyseal line is roughly parallel to the distal tibia epiphyseal line; Grade III presents that the fibular epiphyseal line is parallel to the distal tibia epiphyseal line. Malhotra I, II, III detected in patients indicated that ankle valgus occurred. The cortical discontinuity appearing on two sides of the pseudarthrosis shown in lateral X-ray film was considered as refracture. The healing was judged by two associate chief physicians using blind method. If the diagnosis results were inconsistent, the judgement was made by another chief physician.

According to the measurement method proposed by Paley in Orthopedic surgery principles (Stature Lengthening: Skeletal Dysplasia), the normal value of lateral distal tibial angle (LDTA), the angle between the frontal surface of the distal epiphysis and the anatomical axis of the distal tibia, is ranged from 86° to 92° . The normal value of interior distal tibial angle (ADTA), the angle between the surface of the distal epiphysis on the sagittal plane and the anatomical axis of distal tibia, is ranged from 78° to

82° (**Figure 2A**). The tibial length was measured by picture archiving and communications system (PACS) (**Figure 2B**). The tibial length was measured, and difference between the tibial length of the diseased side and healthy side was considered as tibial length inequality.

The cross-sectional area was measured according to PACS. The ratio between the cross-sectional area of healing region of pseudarthrosis of the tibia and the average value of backbone cross-sectional area of the proximal and distal tibia was calculated. The cross-sectional area is the product of the normotopia and lateral tibial diameter. All the data measurement and clinical evaluation were performed by two staff, separately, under the instruction of the experienced professionals. The data were measured twice and the average value was taken. The data with deviation lower than 5% were included in statistical analysis.

Follow-up

Follow-up records were established for all patients. Follow-up was performed by telephoning or online reservation. The parents were instructed to closely observe the bleeding of the children patients, and taught how to use pin site care. Since pin tract infection is the

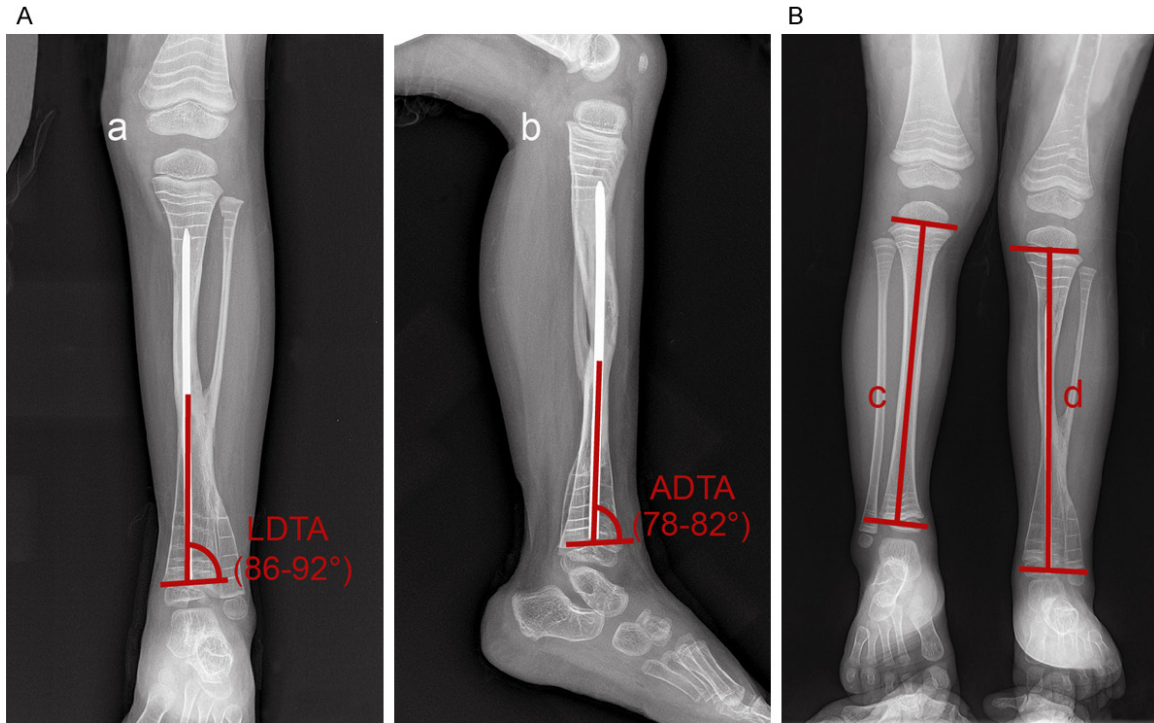


Figure 2. Measurement of LDTA, ADTA and tibial length. Notes: (A) Measurement of LDTA and ADTA, a, LDTA; b, ADTA; (B) Measurement of tibial length, c, tibial length of the healthy side; d, tibial length of the diseased side; LDTA, lateral distal tibial angle ADTA, anterior distal tibial angle.

most common complication of external fixation, the prevention of infection is of crucial importance. The clinical discomfortable symptoms were comparatively obvious, therefore the parents should positively communicate with the children and provide mental comfort to relieve their anxiety. The parents should learn correct bone lengthening method and the children patients should have further consultation with the doctor, regularly, during which they received X-ray examination every 3 months. The parents were taught the importance, methods and notes of the exercise to instruct their children to prevent ankylosis. The data were regularly recorded, early healing was conducted. The states of bone fracture and ankle valgus were recorded and comparisons of tibial length inequality, LDTA and ADTA abnormality, and cross-sectional area ratio were performed. The follow-up was conducted every 3 months and ended in May 2017. No patients were lost to follow-up. During follow-up, the follow-up was terminated if the patient died.

Statistical analysis

All data were analyzed with SPSS 19.0 statistical software (IBM Corp. Armonk, NY, USA).

Measurement data were expressed by mean \pm standard deviation (SD). The *t*-test was applied for comparison between two groups and one-way analysis of variance (ANOVA) was used for the comparison among multiple groups. Enumeration data were expressed by percentage and the comparison of these data among groups was tested by chi-square test. *P* value less than 0.05 was considered statistically significant.

Results

The baseline characteristics of the patients with CPT

This study included 40 cases of CPT, and their baseline characteristics are shown in **Table 1**. There were 27 males, accounting for 67.5% of the total cases, and 13 females, accounting for 32.5% of the total cases. The average age of the patients with CPT when they received the first consultation was ranged from 0~10 years old, among which the first visit age was mostly at 2-3 years old (9 cases). There was no significant difference in the distribution at the left side (18 cases) and the right side (19 cases) ($P > 0.05$). There were 3 cases whose CPT was

Application of 4-in-1 osteosynthesis in CPT

Table 1. Baseline characteristics of the children patients with CPT

Baseline characteristics		Case number (n = 40)
Gender	Male	27 (67.5%)
	Female	13 (32.5%)
Age	0~5 years old	24 (60.0%)
	5~10 years old	16 (40.0%)
Side distribution	Left side	18 (45%)
	Right side	19 (47.5%)
	Both sides	3 (7.5%)
Position of pseudarthrosis	Upper 1/3 of tibiofibula	4 (10%)
	Lower 1/3 of tibiofibula	19 (47.5%)
	Middle 1/3 of tibiofibula	17 (42.5%)
Crawford type classification	Crawford I	2 (5.0%)
	Crawford II	4 (10.0%)
	Crawford III	5 (12.5%)
	Crawford IV	29 (72.5%)
Neurofibromatosis	With	25 (62.5%)
	Without	15 (37.5%)
Family history of neurofibromatosis	With	32 (80.0%)
	Without	8 (20.0%)

Note: CPT, congenital pseudarthrosis of the tibia.

distributed at both sides. The number of the cases with CPT distribution at upper 1/3 of tibia and fibula was only 4, while those with CPT distribution at lower or middle 1/3 of tibia and fibula accounted for a large percent, which was 19 (47.5%) and 17 (42.5%), respectively. According to the Crawford type classification [7], among the cases the patients with Crawford I was the least, only 2 cases, accounting for 5%, and the patients with Crawford IV was the most, with 29 cases accounting for 72.5%. The cases with neurofibromatosis was 25, accounting for 62.5% and the cases with a family history of neurofibromatosis was 32, accounting for 80.0%.

4-in-1 osteosynthesis and combined surgical techniques improve early healing of CPT

The results of the relevant physical indicators of the patients with CPT in this study are shown in **Table 2**. Among the 40 cases of patients with CPT collected in this study, there were 26 cases that showed early healing, accounting for 65.0% and 14 cases that showed no early healing, accounting for 35.0%. There were 22 cases that showed ankle valgus, accounting for 55.0%, and 18 cases that showed no ankle valgus, accounting for 45.0%.

Refracture was observed in 17 cases, accounting for 42.5%; and 23 cases did not suffer from refracture, accounting for 57.5%. The early healing rate, ankle valgus rate and refracture rate were not significantly related to gender, age, side distribution, the position of pseudarthrosis (all $P > 0.05$), while these rates were associated with the Crawford type classification, and the patients with Crawford IV showed comparatively higher ankle valgus rate and refracture rate (both $P < 0.05$). Besides, the patients with a family history of neurofibromatosis showed increased ankle valgus rate and refracture rate than those who without such a family history of neurofibromatosis (both $P < 0.05$).

4-in-1 osteosynthesis and combined surgical techniques improve tibial length inequality

Among the 40 cases of patients with CPT recruited in this study, tibial length inequality was observed in 21 cases, accounting for 52.5% of the total cases, and 19 cases were without tibial length inequality, accounting for 47.5%. In different groups of patients with different gender, age, side distribution, position of pseudarthrosis, Crawford type classification, with or without neurofibromatosis and with or without a family history of neurofibromatosis, the incidence of tibial length inequality was 33.3-100.0%, with an average length of 0.41-1.98 cm (**Table 3**). The tibial length inequality were not significantly related to gender, age, side distribution, position of pseudarthrosis, Crawford type classification, neurofibromatosis and a family history of neurofibromatosis (all $P > 0.05$).

4-in-1 osteosynthesis and combined surgical techniques correct LDTA and ADTA abnormality

The normal LDTA value is 86°-92° and the normal ADTA value is 78°-82°. Among the 40 cases of patients with CPT collected in this study, the LDTA value was ranged from 79.7° to

Application of 4-in-1 osteosynthesis in CPT

Table 2. Early healing, ankle valgus and refracture conditions of CPT children patients after surgery

Baseline characteristics		Case number	Early healing (26)	Ankle valgus (22)	Refracture (17)
Gender	Male	27	17 (63.0%)	15 (55.6%)	11 (40.7%)
	Female	13	9 (69.2%)	7 (53.8%)	6 (46.3%)
Age	0~5 years old	24	13 (54.2%)	12 (50.0%)	11 (45.8%)
	5~10 years old	16	13 (81.3%)	10 (62.5%)	6 (37.5%)
Side distribution	Left side	18	14 (77.8%)	9 (50.0%)	6 (33.3%)
	Right side	19	10 (52.6%)	12 (63.2%)	10 (52.6%)
	Both sides	3	2 (66.7%)	1 (33.3%)	1 (33.3%)
Position of pseudarthrosis	Upper 1/3 of tibiofibula	4	3 (75.0%)	3 (75.0%)	3 (75.0%)
	Lower 1/3 of tibiofibula	19	13 (68.4%)	10 (52.6%)	8 (42.1%)
	Middle 1/3 of tibiofibula	17	10 (58.8%)	9 (52.9%)	6 (35.3%)
Crawford type classification	Crawford I	2	2 (100.0%)	0	0
	Crawford II	4	4 (100.0%)	1 (25.0%)	0
	Crawford III	5	5 (100.0%)	0	0
	Crawford IV	29	15 (51.7%)*	21 (72.4%)*	17 (58.6%)*
Neurofibromatosis	With	25	15 (60.0%)	19 (76.0%)&	15 (60.0%)&
	Without	15	11 (73.3%)	3 (20.0%)	2 (13.3%)
Family history of neurofibromatosis	With	32	21 (65.5%)	21 (65.6%)#	17 (53.1%)#
	Without	8	5 (62.5%)	1 (12.5%)	0

Notes: *, compared with the Crawford I/II/III patients, $P < 0.05$; #, compared with the patients without family history of neurofibromatosis, $P < 0.05$; &, compared with the patients without neurofibromatosis, $P < 0.05$; CPT, congenital pseudarthrosis of the tibia.

Table 3. Tibial length inequality of CPT children patients after surgery

Baseline characteristics		Case number	Incidence of tibial length discrepancy	Average length/cm
Gender	Male	27	14 (51.9%)	1.25 ± 0.33
	Female	13	7 (53.8%)	1.22 ± 0.28
Age	0~5 years old	24	13 (50.0%)	1.20 ± 0.35
	5~10 years old	16	8 (61.2%)	1.30 ± 0.24
Side distribution	Left side	18	11 (61.1%)	1.30 ± 0.25
	Right side	19	9 (47.4%)	1.19 ± 0.37
	Both sides	3	1 (33.3%)	1.21 ± 0.14
Position of pseudarthrosis	Upper 1/3 of tibiofibula	4	2 (50.0%)	1.36 ± 0.21
	Lower 1/3 of tibiofibula	19	11 (57.9%)	1.21 ± 0.30
	Middle 1/3 of tibiofibula	17	8 (47.1%)	1.24 ± 0.34
Crawford type classification	Crawford I	2	2 (100.0%)	1.04 ± 0.01
	Crawford II	4	3 (75.0%)	1.16 ± 0.26
	Crawford III	5	2 (40.0%)	1.19 ± 0.20
	Crawford IV	29	14 (48.3%)	1.27 ± 0.34
Neurofibromatosis	With	25	12 (80.0%)	1.31 ± 0.31
	Without	15	9 (36.0%)	1.12 ± 0.28
Family history of neurofibromatosis	With	32	15 (46.9%)	1.26 ± 0.31
	Without	8	6 (75.0%)	1.17 ± 0.34

Note: CPT, congenital pseudarthrosis of the tibia.

96.1° and the ADTA value was ranged from 78.5° to 90.9°. The abnormality of LDTA and

ADTA was not significantly related to gender, age, side distribution, position of pseudarthro-

Application of 4-in-1 osteosynthesis in CPT

Table 4. LDTA and ADTA abnormality of CPT children patients CPT surgery

Baseline characteristics		LDTA/°	ADTA/°
Gender	Male	86.9 ± 3.9	83.7 ± 2.6
	Female	87.2 ± 3.9	84.2 ± 4.0
Age	0~5 years old	87.1 ± 4.0	83.3 ± 2.8
	5~10 years old	86.8 ± 3.8	84.2 ± 3.3
Side distribution	Left side	87.0 ± 3.7	83.3 ± 2.5
	Right side	86.8 ± 4.3	86.0 ± 5.4
	Both sides	88.0 ± 3.6	82.7 ± 3.2
Position of pseudarthrosis	Upper 1/3 of tibiofibula	85.8 ± 2.9	84.3 ± 3.1
	Lower 1/3 of tibiofibula	86.7 ± 3.9	83.8 ± 3.1
	Middle 1/3 of tibiofibula	87.7 ± 4.2	83.7 ± 1.9
Crawford type classification	Crawford I	85.0 ± 0.8	84.6 ± 2.8
	Crawford II	87.3 ± 4.2	86.7 ± 4.5
	Crawford III	89.8 ± 3.8	84.3 ± 3.0
	Crawford IV	86.6 ± 3.9	83.4 ± 2.9
Neurofibromatosis	With	87.3 ± 4.3	83.4 ± 2.6
	Without	86.5 ± 3.1	84.8 ± 3.8
Family history of neurofibromatosis	With	87.3 ± 4.0	84.2 ± 3.1
	Without	85.8 ± 3.5	82.5 ± 2.7

Notes: LDTA, lateral distal tibial angle; ADTA, anterior distal tibial angle; CPT, congenital pseudarthrosis of the tibia.

sis, Crawford type classification, neurofibromatosis and the family history of neurofibromatosis (all $P > 0.05$, **Table 4**).

4-in-1 osteosynthesis and combined surgical techniques enlarge the cross-sectional area of pseudarthrosis healing region

Among the 40 cases of patients with CPT recruited in this study, the ratio between the cross-sectional area of the healing region of pseudarthrosis of the tibia and the average value of the backbone cross-sectional area of the proximal and distal tibia was 1.8-3.9 and the average value was 2.7. The cross-sectional area ratio was not significant related to gender, age, side distribution, position of pseudarthrosis, Crawford type classification, the family history of neurofibromatosis (all $P > 0.05$), while it was associated with Crawford type classification and neurofibromatosis (both $P < 0.05$). The patients with Crawford IV or neurofibromatosis showed decreased cross-sectional area of the healing region of pseudarthrosis of the tibia after they received 4-in-1 osteosynthesis and combined surgical techniques (**Table 5**).

Discussion

CPT is considered as one of the most severe skeletal diseases [17]. The management meth-

od for CPT treatment is not effective due to the failure of bony union and occurrence of amputation [18]. In this study, we tried to investigate the effects of 4-in-1 osteosynthesis and combined surgical techniques in the treatment of CPT.

Initially, our results revealed that patients with CPT after treatment of 4-in-1 osteosynthesis and combined surgical techniques showed higher early healing rate, lower ankle valgus rate and refracture rate, and the ankle valgus rate and refracture rate were associated with Crawford type classification and the family history of neurofibromatosis. In recent years, the recovery on ankle joint has been paid attention for treatment of CPT, due to the high incidence of ankle valgus and the occurrence of refracture was regarded as the difficult point to manage CPT [19, 20]. Lin et al. reported that after successful osteosynthesis of the tibia, the refracture of the tibia and ankle valgus in CPT patients is often related to the persistent pseudarthrosis of the fibula [21]. Crawford is a kind of thoraco-abdominal aortic aneurysm classified by Crawford and type IV was considered as a fracture or false pseudarthrosis [1, 22]. Neurofibromatosis type 1 is largely expressed in CPT and neurofibromatosis patients were have been found to be more vulnerable to

Application of 4-in-1 osteosynthesis in CPT

Table 5. Cross-sectional area ratio of CPT children patients after surgery

Baseline characteristics	Case number	Cross-sectional area	
Gender	Male	27	2.72 ± 0.64
	Female	13	2.76 ± 0.79
Age	0~5 years old	24	2.63 ± 0.67
	5~10 years old	16	2.88 ± 0.70
Side distribution	Left side	18	2.87 ± 0.68
	Right side	19	2.52 ± 0.56
	Both sides	3	3.20 ± 1.21
Position of pseudarthrosis	Upper 1/3 of tibiofibula	4	2.27 ± 0.53
	Lower 1/3 of tibiofibula	19	2.76 ± 0.72
	Middle 1/3 of tibiofibula	17	2.81 ± 0.67
Crawford type classification	Crawford I	2	3.65 ± 0.35
	Crawford II	4	3.34 ± 0.34
	Crawford III	5	3.47 ± 0.59
	Crawford IV	29	2.46 ± 0.54*
Neurofibromatosis	With	25	2.48 ± 0.53#
	Without	15	3.16 ± 0.71
Family history of neurofibromatosis	With	32	2.70 ± 0.73
	Without	8	2.86 ± 0.50

Notes: *, compared with the Crawford I/II/III patients, $P < 0.05$; #, compared with the patients without neurofibromatosis, $P < 0.05$; CPT, congenital pseudarthrosis of the tibia.

late refracture, for NF-1 gene mutation could lead to neurofibromin activity loss, which interferes with the osteoblast activity [23, 24]. A similar study has revealed the consistent results with ours that the application of distraction osteogenesis could exert some effects on tibial healing, with no patients had refracture after they received this technique [25]. The technique of minimally invasive plate osteosynthesis is reported to be capable of assisting in treating fractures [26]. Moreover, the patients underwent the combined surgical techniques of intramedullary stabilisation and Ilizarov external fixation showed early union rate and union time reduction, for Ilizarov technique could effectively improve ankle function and intramedullary support after nail removal could reduce refracture rate [27, 28].

Among the 40 cases, 21 cases were found with tibial length inequality, and all patients recruited in this study showed the abnormality of LDTA and ADTA, which was independent of gender, age, side distribution, position of pseudarthrosis, Crawford type classification, neurofibromatosis and a family history of neurofibromatosis. The ADTA is an angle between the joint orientation line of the ankle and the mechanical axis of the tibia, the normal lower extremity ranged

from $80^\circ \pm 3^\circ$ and the increase of which indicates a recurvatum deformity; the LDTA, normally ranged from $89^\circ \pm 3^\circ$, is an angle between the anatomical axis of the tibia and the distal tibial articular surface, the decrease of which suggests a varus deformity [29]. Limb-length inequality is related with various orthopaedic disorders and biomechanical gait variations involving excessive load of the posterior tibial tendon, is also one of the factors causing the difficulty of CPT treatment [30, 31]. Lower limb deformity could be improved by surgical technique called expandable nail system, which is an adaptation of osteosynthesis [32]. Besides, it was revealed that after osteosynthesis treatment, the mean value of LDTA improved from 75.6° to 86.6° in patients with CPT in the osteosynthesis group [33]. In our study, 4-in-1 osteosynthesis and combined surgical techniques, absorbing the advantages of conventional osteosynthesis and surgical techniques, could obtain satisfactory line and position alignment, which helped to prevent LDTA and ADTA from abnormality.

In addition, the 4-in-1 osteosynthesis and combined surgical techniques increased the cross-sectional area of healing region of CPT patients. The patients with Crawford IV or neurofibroma-

tosis showed decreased cross-sectional area of the healing area of pseudarthrosis of the tibia. A previous study reported that among 5 patients with neurofibromatosis type 1, 1 patient was detected with sustained nonunion, and 3 finally received amputation [34]. Maximization of the healing cross-sectional area is considered one of the most important principles of CPT treatment [35]. According to a recent report, osteosynthesis combined with other techniques including allograft strut as well as autografts could help to treat refractory distal femur non-unions [36]. Moreover, retrograde intramedullary nailing or less invasive stabilization on system performed under the guide of the biological osteosynthesis could contribute to osseous healing within 6 months in more than 90% of the patients with distal femur fracture according to the clinical and radiographic evaluation [37]. It has been reported that 4-in-1 osteosynthesis is equipped with many advantages because it is capable of maximizing the cross-sectional area of healing at pseudarthrosis, which is in consistency with our results [10].

To conclude, our study showed that the application of 4-in-1 osteosynthesis in combined surgery could effectively increase the cross-sectional area of the healing region of CPT and reduce the refracture rate of the patients, which may provide a novel treatment method for CPT. However, the specific mechanisms still lacks clarity and the long-term stability is hard to predict, therefore further researches are required in the future.

Disclosure of conflict of interest

None.

Address correspondence to: Dr. Haibo Mei, Department of Orthopedics, Hunan Children's Hospital, 86 Ziyuan Road, Changsha 410007, Hunan Province, P. R. China. Tel: +86-731-85600998; E-mail: mei_haibo@163.com

References

[1] Birke O, Schindeler A, Ramachandran M, Cowell CT, Munns CF, Bellemore M, Little DG. Preliminary experience with the combined use of recombinant bone morphogenetic protein and bisphosphonates in the treatment of congenital pseudarthrosis of the tibia. *J Child Orthop* 2010; 4: 507-517.

[2] Han J, Qu L, Li Y, Luo J, Cao J, Zhao W. A benign form of congenital anterolateral bowing of the tibia associated with ipsilateral polydactyly of the hallux: case report and literature review. *Am J Med Genet A* 2012; 158A: 1742-1749.

[3] Horn J, Steen H, Terjesen T. Epidemiology and treatment outcome of congenital pseudarthrosis of the tibia. *J Child Orthop* 2013; 7: 157-166.

[4] Lee DY, Cho TJ, Lee HR, Lee K, Moon HJ, Park MS, Yoo WJ, Chung CY, Choi IH. Disturbed osteoblastic differentiation of fibrous hamartoma cell from congenital pseudarthrosis of the tibia associated with neurofibromatosis type I. *Clin Orthop Surg* 2011; 3: 230-237.

[5] Shah H, Rousset M, Canavese F. Congenital pseudarthrosis of the tibia: management and complications. *Indian J Orthop* 2012; 46: 616-626.

[6] Seo SG, Lee DY, Kim YS, Yoo WJ, Cho TJ, Choi IH. Foot and ankle function at maturity after ilizarov treatment for atrophic-type congenital pseudarthrosis of the tibia: a comprehensive outcome comparison with normal controls. *J Bone Joint Surg Am* 2016; 98: 490-498.

[7] Liu Y, Mei H, Zhu G, Liu K, Wu J, Tang J, He R. Congenital pseudarthrosis of the tibia in children: should we defer surgery until 3 years old? *J Pediatr Orthop B* 2018, 27: 17-25.

[8] Granchi D, Devescovi V, Baglio SR, Magnani M, Donzelli O, Baldini N. A regenerative approach for bone repair in congenital pseudarthrosis of the tibia associated or not associated with type 1 neurofibromatosis: correlation between laboratory findings and clinical outcome. *Cytotherapy* 2012; 14: 306-314.

[9] Choi IH, Lee SJ, Moon HJ, Cho TJ, Yoo WJ, Chung CY, Park MS. "4-in-1 osteosynthesis" for atrophic-type congenital pseudarthrosis of the tibia. *J Pediatr Orthop* 2011; 31: 697-704.

[10] Choi IH, Cho TJ, Moon HJ. Ilizarov treatment of congenital pseudarthrosis of the tibia: a multi-targeted approach using the Ilizarov technique. *Clin Orthop Surg* 2011; 3: 1-8.

[11] Wang TJ, Ju WN, Qi BC. Novel management of distal tibial and fibular fractures with Acumed fibular nail and minimally invasive plating osteosynthesis technique: a case report. *Medicine (Baltimore)* 2017; 96: e6482.

[12] Jang WY, Choi YH, Park MS, Yoo WJ, Cho TJ, Choi IH. Physeal and subphyseal distraction osteogenesis in atrophic-type congenital pseudarthrosis of the tibia: efficacy and safety. *J Pediatr Orthop* 2017.

[13] Mehling IM, Sauerbier M. Scaphoid fractures and pseudarthrosis of the scaphoid. *Z Orthop Unfall* 2013; 151: 639-660.

[14] Salinas-Torres VM, Barajas-Barajas LO, Perez-Garcia N, Perez-Garcia G. Bilateral tibial hemi-

Application of 4-in-1 osteosynthesis in CPT

- melia type 1 (1a and 1b) with T9 and T10 hemivertebrae: a novel association. *Sao Paulo Med J* 2013; 131: 275-278.
- [15] Santos GW. Allogeneic and autologous bone marrow transplantation in AML. *Leukemia* 1992; 6 Suppl 2: 102-103.
- [16] Malhotra D, Puri R, Owen R. Valgus deformity of the ankle in children with spina bifida aperta. *J Bone Joint Surg Br* 1984; 66: 381-385.
- [17] Wang W, Nyman JS, Ono K, Stevenson DA, Yang X, Elefteriou F. Mice lacking Nf1 in osteochondroprogenitor cells display skeletal dysplasia similar to patients with neurofibromatosis type I. *Hum Mol Genet* 2011; 20: 3910-3924.
- [18] Mathieu L, Vialle R, Thevenin-Lemoine C, Mary P, Damsin JP. Association of Ilizarov's technique and intramedullary rodding in the treatment of congenital pseudarthrosis of the tibia. *J Child Orthop* 2008; 2: 449-455.
- [19] Shabtai L, Ezra E, Wientroub S, Segev E. Congenital tibial pseudarthrosis, changes in treatment protocol. *J Pediatr Orthop B* 2015; 24: 444-449.
- [20] Shah H, Doddabasappa SN, Joseph B. Congenital pseudarthrosis of the tibia treated with intramedullary rodding and cortical bone grafting: a follow-up study at skeletal maturity. *J Pediatr Orthop* 2011; 31: 79-88.
- [21] Liu YX, Mei HB, Zhu GH, He RG, Liu K, Tang J, Wu JY, Ye WH, Hu X, Tan Q, Yan A, Huang SX, Tan XQ, Lei T. Relationship between postoperative complications and fibular integrity in congenital pseudarthrosis of the tibia in children. *World J Pediatr* 2017; 13: 261-266.
- [22] Kieffer E, Chiche L, Bertal A, Koskas F, Bahnini A, Bla Try O, Cacoub P, Piette JC, Thomas D. Descending thoracic and thoracoabdominal aortic aneurysm in patients with Takayasu's disease. *Ann Vasc Surg* 2004; 18: 505-513.
- [23] Van Royen K, Brems H, Legius E, Lammens J, Laumen A. Prevalence of neurofibromatosis type 1 in congenital pseudarthrosis of the tibia. *Eur J Pediatr* 2016; 175: 1193-1198.
- [24] Vanderstappen J, Lammens J, Berger P, Laumen A. Ilizarov bone transport as a treatment of congenital pseudarthrosis of the tibia: a long-term follow-up study. *J Child Orthop* 2015; 9: 319-324.
- [25] Zhu GH, Mei HB, He RG, Liu K, Tang J, Wu JY. Effect of distraction osteogenesis in patient with tibial shortening after initial union of congenital pseudarthrosis of the tibia (CPT): a preliminary study. *BMC Musculoskelet Disord* 2015; 16: 216.
- [26] Sutter PM, Peltzer J. Principles of operative treatment of malleolar fractures today. *Eur J Trauma Emerg Surg* 2010; 36: 505-514.
- [27] Spiro AS, Babin K, Lipovac S, Stenger P, Mladenov K, Rupprecht M, Rueger JM, Stuecker R. Combined treatment of congenital pseudarthrosis of the tibia, including recombinant human bone morphogenetic protein-2: a case series. *J Bone Joint Surg Br* 2011; 93: 695-699.
- [28] Agashe MV, Song SH, Refai MA, Park KW, Song HR. Congenital pseudarthrosis of the tibia treated with a combination of Ilizarov's technique and intramedullary rodding. *Acta Orthop* 2012; 83: 515-522.
- [29] Bonasia DE, Dettoni F, Femino JE, Phisitkul P, Germano M, Amendola A. Total ankle replacement: why, when and how? *Iowa Orthop J* 2010; 30: 119-130.
- [30] Sanhudo JA, Gomes JL. Association between leg length discrepancy and posterior tibial tendon dysfunction. *Foot Ankle Spec* 2014; 7: 119-126.
- [31] Bobotas K, Lалlos SN, Nikolaou VS, Komicronrres DS, Efstathopoulos NE. Successful treatment of congenital pseudarthrosis of the tibia: still a challenge. *Eur J Orthop Surg Traumatol* 2013; 23 Suppl 2: S303-310.
- [32] Weber O, Florczyk A, Pittlik N, Burger C, Muller M, Kabir K, Rangger C, Wirtz DC. Correction of lower limb deformity by using an expandable nail system. Adaption of osteosynthesis to dystrophe soft-tissue situation. *Unfallchirurg* 2007; 110: 576-580.
- [33] Martus JE, Johnston CE 2nd. Isolated congenital pseudoarthrosis of the fibula: a comparison of fibular osteosynthesis with distal tibiofibular synostosis. *J Pediatr Orthop* 2008; 28: 825-830.
- [34] Richards BS, Anderson TD. rhBMP-2 and intramedullary fixation in congenital pseudarthrosis of the tibia. *J Pediatr Orthop* 2018; 38: 230-238.
- [35] Cho TJ, Choi IH, Lee SM, Chung CY, Yoo WJ, Lee DY, Lee JW. Refracture after Ilizarov osteosynthesis in atrophic-type congenital pseudarthrosis of the tibia. *J Bone Joint Surg Br* 2008; 90: 488-493.
- [36] Kanakeshwar RB, Jayaramaraju D, Agraharam D, Rajasekaran S. Management of resistant distal femur non-unions with allograft strut and autografts combined with osteosynthesis in a series of 22 patients. *Injury* 2017; 48 Suppl 2: S14-S17.
- [37] Hierholzer C, von Ruden C, Potzel T, Woltmann A, Buhren V. Outcome analysis of retrograde nailing and less invasive stabilization system in distal femoral fractures: a retrospective analysis. *Indian J Orthop* 2011; 45: 243-250.