

Original Article

Jumbo cups for repair of moderate-to-severe acetabular bone defects during revision of total hip arthroplasty: medium-term outcomes

Senbo An¹, Huiyu Hu², Yuwei Liu¹, Yihe Hu¹, Jie Xie¹, Long Wang¹

¹Orthopedics Department, ²Breast Surgery Department, Xiangya Hospital, Central South University, Changsha, China

Received June 2, 2017; Accepted February 14, 2018; Epub May 15, 2018; Published May 30, 2018

Abstract: Objective: To determine the medium-term clinical outcomes of revision surgery after total hip arthroplasty with jumbo cups in patients with Paprosky type II or type IIIA acetabular bone loss. Materials and Methods: We retrospectively reviewed 54 patients (54 hips) who underwent unilateral hip revision using jumbo cups in our institution between January 2007 and August 2012. The patients underwent clinical and radiographic evaluations before the revision surgery and at 3 months, 6 months, and 1 year after the revision surgery and every year thereafter. Harris Hip Score (HHS), Hip Disability and Osteoarthritis Outcome Score (HOOS), Short Form (36) Health Survey (SF-36) score, radiographic findings, and Kaplan-Meier implant-survivorship curves were evaluated. The operative findings and complications were also noted. Results: The patients were followed up for a mean of 5.3 years (range, 4-9 years). The mean HHS, HOOS, and SF-36 score had all significantly improved at the latest follow-up as compared with their preoperative values ($P < 0.05$). However, these scores did not significantly differ between patients with type II bone loss and those with type IIIA bone loss. Additionally, the HOOS and SF-36 score improved earlier than the HHS, indicating that the quality of life of the patients improved before hip-function recovery. The 5-year prosthesis-survival rate was 90.7%. Conclusion: Jumbo cups have similar satisfactory outcomes in both type II and type IIIA patients. The application of life-quality scales reveals early clinical improvement that may be useful to guide further recovery.

Keywords: Jumbo cup, bone defects, revision, acetabular, Paprosky, arthroplasty

Introduction

In recent decades, the functional outcomes and implant-survival rate after total hip arthroplasty (THA) have improved considerably; nevertheless, the number of patients requiring revision procedures has continued to increase [1]. Failure of THA is invariably associated with acetabular and/or femoral bone deficiency that leads to joint loosening and dysfunction, and revision THA in the presence of severe acetabular bone loss remains a challenge [2]. Several prostheses have been developed to restore the primary stability of the acetabular component during revision hip surgery; for example, conventional cups, uncemented jumbo cups, metallic cages or meshes with suitable cement lines, reinforcement rings, and customized acetabular prostheses [3] have all been successfully used to cope with different extents of ace-

tabular bone loss. The extent of acetabular bone loss is commonly categorized according to the Paprosky classification into types I, IIA, IIB, IIC, IIIA, and IIIB. Type II defects describe moderate acetabular bone loss, but the remaining bone bed can still offer stable fixation for prostheses such as jumbo cups, reinforcement rings, and metal meshes [4]. Type IIIA defects involve severe acetabular bone loss, in which the acetabular rim is not entirely supportive, but the remaining host bone may still be adequate for bony ingrowth. Jumbo cups are frequently used for the repair of type II and some type IIIA defects because they allow bony ingrowth and provide satisfactory long-term implant survival [5].

A jumbo cup is defined as a cementless cup measuring ≥ 62 mm in women and ≥ 66 mm in men [6]. Jumbo components combined with

Jumbo cups for revision of total hip arthroplasty

bone grafting have been used for almost 10 years at our institution. In this retrospective, follow-up study, we aimed to determine the medium-term outcomes, specifically, improvement in hip function and quality of life, of patients with type II or IIIA defects who underwent revision THA with jumbo cups.

Materials and methods

Patients

All patients with Paprosky type II or type IIIA defects who had undergone unilateral acetabular revision at our institution between January 2007 and August 2012 were eligible for inclusion in this study. The patients were divided into two groups according to the extent of acetabular bone loss: type II group and type IIIA group. Patients with Paprosky type I defects or type IIIB defects, which involve severe structural osteolysis, as well as those with severe systemic disease were excluded from the study. Written informed consent was obtained from all participants included in the study, and the study was approved by the ethics committee of our hospital.

Surgical procedure

All patients were operated on under general anesthesia by the same team of surgeons. During surgery, patients were placed in the lateral position, and a posterolateral surgical approach was used. The skin and subcutaneous tissues were incised layer by layer up to the joint capsule. The hip joint was clearly exposed after debridement of the cement and fibrous tissues around the acetabular fossa and removal of bony adhesions around the trochanter and acetabular rim by using specific types of osteotomes and osteotribes. The tissues removed were pathologically examined and cultured to identify bacterial infection [7]. Next, the liner and cup were retrieved; if fixation screws had been used for the primary surgery, they were carefully removed to avoid breakage of the screws. During these steps, care was taken to preserve as much of the host bone as possible. Then, the precise degree of bone defect was evaluated under direct vision, so as to adjust the operative method if required. After tissue debridement was completed, discontinuous marginal bone defects were found in the anterior and posterior structures. These defects could mostly be overcome by amplification of the acetabular socket with a drill. By

gradually increasing the drill size, some invagination defects around the medial wall could be eliminated. These defects were filled with morselized bone allografts, which were then compacted, or with frozen structural fragments when necessary. The surgeons then implanted the acetabular component in the proper position with appropriate anteversion and abduction angles relative to the position of the femoral modular component [8]. A matched ceramic or ultra-high-molecular-weight polyethylene liner and a regular 36-mm head were installed, so that the rotation center of the hip joint was restored. Several extra cortical screws were used in 47 hips to enhance early fixation. In 23 patients, an extended incision was required for replacement of the prosthesis because of femoral component failure. All patients received conventional anticoagulation treatment and nutritional support after the surgery. The patients were discharged from the hospital after a mean postoperative stay of 10 days, and were required to attend follow-up assessments at 3 weeks, 3 months, 6 months, and 1 year after the surgery, and every year thereafter.

Outcome evaluation

We compared the Harris Hip Score (HHS) and radiographic results between the two groups before the revision surgery, and at 3 weeks, 3 months, 6 months, and 1 year after the surgery, and every year thereafter [9]. For the radiological assessment, the hip rotation center and the inclination angle of the prosthesis were measured. The horizontal location of the femoral head center was measured as the distance from the ipsilateral teardrop on the inter-teardrop line, while the cup-inclination angle was determined with reference to the inter-teardrop line. Radiolucent lines at the bone-implant interface were recorded according to the acetabular zones described by Massin *et al.* [10]. Cup migration was defined as the presence of more than 2-mm-long clear lines in all zones, and loosening was defined as a complete demarcation line as well as migration by more than 5 mm or a change in the primary abduction angle by more than 5° or cortical screw breakage.

We monitored the patients for peri- and postoperative complications such as intraoperative fracture, dislocation, deep venous thrombosis, and infection. The Hip Disability and Osteoarthritis Outcome Score (HOOS) and Short

Jumbo cups for revision of total hip arthroplasty

Table 1. Patient characteristics before revision surgery

	Type II (n = 39)	Type IIIA (n = 15)	P-value*
Age (years), mean (range)	63.2 (36-72)	65.0 (45-75)	0.076
Gender, n (%)			
Male	15 (38.5%)	9 (60%)	
Female	24 (61.5%)	6 (40%)	
HHS, mean (range)	48.4 (37-72)	43.6 (33-68)	0.167
HOOS, mean (range)	45.9 (32-66)	39.1 (32-70)	0.621
SF-36, mean (range)	38.6 (32-63)	34.3 (31-67)	0.112
Femoral component revision, n (%)	15	8	
Revision indication, n (%)			
Aseptic loosening	35 (89.7%)	11 (73.3%)	
Septic loosening	4 (10.3%)	4 (26.7%)	

*P values of < 0.05 indicate significant differences. HHS, Harris Hip Score; HOOS, Hip Disability and Osteoarthritis Outcome Score; SF-36, Short Form (36) Health Survey.

Table 2. Outcomes of revision surgery at the latest follow-up

	Type II	Type IIIA	P-value
HHS	76.2 (42-91)	73.9 (43-87)	0.379
HOOS	82.3 (45-90)	79.1 (49-88)	0.126
SF-36	73.6 (49-88)	79.4 (45-86)	0.643

Values are shown as mean (range). HHS, Harris Hip Score; HOOS, Hip Disability and Osteoarthritis Outcome Score; SF-36, Short Form (36) Health Survey.

Form (36) Health Survey (SF-36) were also evaluated to assess the patients' subjective satisfaction and symptoms in order to formulate an individualized rehabilitation plan. In addition, we compared the HOOS and SF-36 score between the two groups. The 5-year implant survivorship rates were also calculated.

Statistical analysis

All statistical analyses were performed with SPSS (version 22.0, SPSS Inc., Chicago, IL). Continuous variables were compared using *t*-tests. Analysis of variance was used to compare follow-up data among various time points. Categorical variables were compared between the type II and type IIIA groups by means of the chi-square test. Implant survival was evaluated using Kaplan-Meier 5-year survivorship curves. A *P*-value of < 0.05 was considered significant.

Results

General information

The original series included 62 hips in 62 patients. During the follow-up period, two patients died of chronic cardiovascular diseases,

and six were lost to follow-up by 2 years after the revision surgery. Thus, the final series consisted of 54 hips in 54 patients, including 24 men and 30 women. The mean age of the patients was 63.4 years (range, 36-75 years) at the time of revision surgery and 68.7 years (range, 41-79 years) at the most recent follow-up.

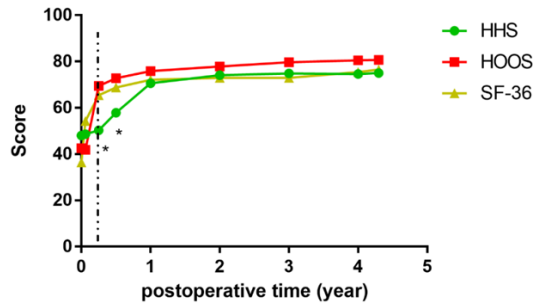
The reasons for primary total hip replacement were as follows: femoral

neck fracture (7 hips), osteoarthritis (19 hips), osteonecrosis of the femoral head (24 hips), rheumatoid arthritis (3 hips), and ankylosing spondylitis (1 hip). The reasons for revision surgery were aseptic loosening (43 hips) and osteolysis caused by prosthetic joint infection (11 hips). Additional femoral modular component revision was required in 23 patients, of whom, 7 developed postoperative prosthetic joint infection. The overall preoperative characteristics of the two groups have been shown in **Table 1**.

Hip function and quality of life

The mean follow-up duration was 5.3 years (range, 4-9 years). The HHS, HOOS, and SF-36 score were all significantly improved at the latest follow-up as compared to their preoperative values (*P* < 0.01). At the latest follow-up, the mean HHS increased from 48.4 (range, 37-72) preoperatively to 76.2 (range, 42-91) in the type II group and from 43.6 (range, 33-68) to 73.9 (range, 43-87) in the type IIIA group. The mean HOOS improved from 42.6 (range, 32-68) before the revision surgery to 82.3 (range, 45-90) in the type II group and from 39.7 (range, 31-76) to 79.1 (range, 47-89) in the type IIIA group at the last follow-up. The mean SF-36 improved from 36.3 (range, 31-65) preoperatively to 73.6 (range, 49-88) in the type II group and from 37.8 (range, 33-49) to 79.4 (range, 45-86) in type IIIA group. The HHS, HOOS, and SF-36 score at the latest follow-up did not significantly differ between the two study groups (**Table 2**). The temporal changes in these three scores have been shown in **Figure 1**. Hip function and quality of life were obviously improved

Jumbo cups for revision of total hip arthroplasty



* means significant difference compared with SF-36 group ($P < 0.05$) at one time follow-up

Figure 1. Temporal changes in Harris Hip Score (HHS), Hip Disability and Osteoarthritis Outcome Score (HOOS), and Short Form (36) Health Survey (SF-36).

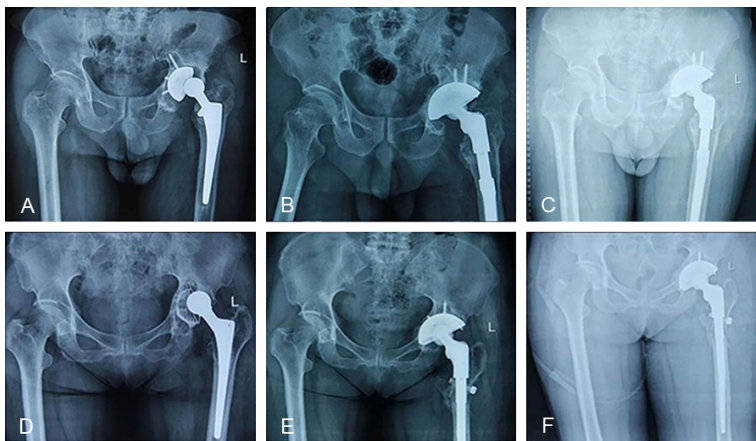


Figure 2. Typical X-ray characteristics of type IIA (A-C) and type IIIA (D-F) osteolysis at different stages. Radiographs taken in a 66-year-old man (A) before revision surgery and (B) 3 days and (C) 5 years after revision surgery. Radiographs taken in a 68-year-old woman (D) before revision surgery, and (E) 2 days and (F) 3 years after revision surgery.

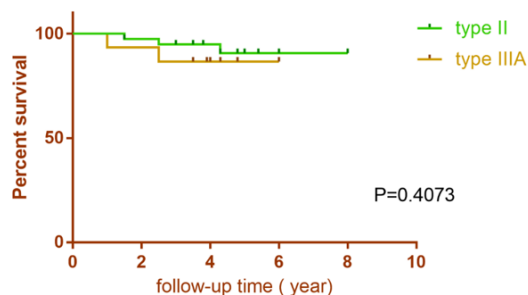


Figure 3. Kaplan-Meier implant-survivorship curves.

shortly after the revision surgery and then remained steady. We found that the HOOS and SF-36 score improved significantly earlier than the HHS. This indicates that the patients' daily and social life and their subjective satisfaction with the surgery dramatically improved at about 3 months after the surgery, which was much

earlier than any obvious functional improvement as shown by the HHSs (which occurred at about 6 months after the surgery).

Complications and Implant Survivorship

At the last follow-up, 46 patients had no pain in the thighs or knees. Five patients in the type II group and three patients in the type IIIA group had mild or moderate thigh pain, but none of them had to take nonsteroidal anti-inflammatory drugs or opioid analgesics for pain relief. Of the 54 patients, 41 had no or a slight limp, and 13 had a moderate limp. Single-stage healing was achieved in 52 patients, while delayed wound healing occurred in 2 patients. Different degrees of decrease in gluteus medius muscle strength were observed in 8 patients, but none of them developed hip dislocation. Representative X-ray characteristics have been shown in **Figure 2**. No patient developed deep venous thrombosis or pulmonary embolism.

The Kaplan-Meier implant survivorship curve (**Figure 3**) showed that implant survival did not differ between the type II and type IIIA groups ($P = 0.4073$). During the study period, five acetabular modular components failed and required re-revision. Three of these failures were associated with aseptic loosening with slightly rotated acetabular components, of which two were in the type IIIA group and one was in the type II group. All three were revised with larger cups. The remaining two patients developed periprosthetic infection and underwent a two-stage revision procedure. After taking out the previous prosthesis, we inserted an antibiotic spacer (containing gentamicin), which was retained for about 3 months until the infection was controlled. Then, we used a titanium mesh combined with a cement liner to maintain support of the cup. All five patients had satisfactory outcomes after several follow-up visits.

Discussion

In this study, we found that the medium-term outcomes of revision THA with jumbo cups were satisfactory in patients with Paprosky type II and type IIIA acetabular bone loss. No significant differences in the HHS, HOOS, and SF-36 score were found between the type II and type IIIA groups at the latest follow-up. In both study groups, the HOOS and SF-36 score improved earlier than the HHS.

Uncemented jumbo cups have been widely used in numerous conditions in which the relative integrity of the acetabular walls can be ensured by removing the periprosthetic tissues and filing the socket; this situation is most likely to occur in type II acetabular deficiency [11]. Jumbo cups can also be considered for type IIIA defects that are regular and rounded and for small defects that can be covered with morselized grafts. Furthermore, as the socket is enlarged by filing, the primary deficiency would be eliminated, and a larger size of press-fit cup is required to allow sufficient bone ingrowth. In the overwhelming majority of conditions, except in those associated with severe osteoporosis, uncemented cups are superior to cemented cups and can allow adequate long-term prosthesis survivorship [12].

In our study, the majority of patients had Paprosky type II bone loss. Type III deficiency is considered more severe, and is usually associated with acetabular bone loss that is too irregular to hold an uncemented cup. However, type IIIA deficiencies, which are relatively less common, can allow a close fit with jumbo cups. Our institution routinely uses jumbo cups or metal meshes to repair type IIIA defects without complications. Jumbo cups are suitable only for relatively limited acetabular rim defects that are rounded and regular, so that the defect can be eliminated during surgery, and a suitable rim regained [13]. This type of defect is common among people with aseptic loosening, which may be caused by incorrect component location, especially, cup abduction and anteversion [14]. Type III bone loss can also be treated with prostheses such as metal meshes, trabecular metal blocks, cages, and custom-made components with matched liners and femoral heads [15], all of which can provide initial firm fixation. We found satisfactory improvement in hip function and quality of life

in both the type II and type IIIA groups, without any significant difference between the two groups. Hence, we prefer using jumbo cups to treat type IIIA deficiency unless the patient has poor bone mass; we prefer using other types of prostheses for type IIIB defects [16].

The revision surgery failed in five patients. Three of these patients developed aseptic loosening, while the other two contracted infections. Aseptic loosening is probably attributable to the stress-shielding effect of the implant. If the cup is not placed perfectly, certain zones fail to gain sufficient mechanical stimulation, which is critical for bone growth; this eventually leads to regional bone loss. The implantation of a new, matched, larger femoral head in patients with aseptic loosening can result in a larger range of motion at the hip joint and a lower likelihood of joint dislocation [17]. However, if the bone substance is poor, the prosthesis will not have solid contact with the host bone, and further loosening or prosthesis movement can take place in the presence of stress or hip rotation. Patients may experience a slight ascending of the rotation center of the hip joint due to absorption of the contiguous surface of the host bone [18]. Moreover, dislocation can occur in the event of impact or falls. Once dislocation occurs, the components may stimulate the periprosthetic soft tissue and result in thigh pain. If prosthesis failure occurs, re-revision surgery is required, as the defect would be even more severe than before. In this case, other types of surgical prostheses should be used.

Two of our patients developed periprosthetic infections and required a two-stage revision with an antibiotic spacer and systemic antibiotic administration before replacement of the cup with a new prosthesis. Systemic infection can cause bacterial aggregation in the injured joint tissues, leading to infectious complications. To ensure long-term implant survivorship, the primary evaluation and operational procedure must be strictly executed. Moreover, patients should obey medical advice and avoid improper activities or tumbling in order to prevent recurrent dislocation and fracture [19].

The HHS is widely used for the comprehensive evaluation of pain, range of hip motion, and daily life function [20]. The HOOS has a more specific description of daily-life activities as well as hip motion and stiffness over a period of

time. SF-36 provides information about both health condition and emotional state related to illness [21]. In our study, we found that the patients' quality of life improved about 3 months earlier than their HHSs. This indicated to us that patients tended to do insufficient early functional recovery training due to fears or worries of damaging the hip joint [22]. By evaluating quality of life and physical state early and sharing these results with the patients, we may be able help patients to gain confidence in their recovery and comply with rehabilitative training exercises. Moreover, these evaluations are helpful to detect any discomfort at an early stage, so that the necessary examinations can be performed to exclude possible risk factors. The emotional state of the patient also plays an important role in recovery and the resumption of normal life [23]. Patients in whom the primary hip replacement fails may fear undergoing revision surgery and lose confidence in ever making a recovery. Through the HOOS and SF-36 scores, doctors can assess the patient's mental state, allay his/her fears, encourage him/her to start proper recovery training at an early stage, and be aware of small changes in mood and take instant actions to prevent worsening of the patient's condition [24].

This study has some drawbacks. First, the results would be more convincing if we had performed long-term follow-up of the uncemented prostheses to definitively determine their advantages in terms of bony ingrowth and further fixation. Second, we compared 39 type II patients with 15 type IIIA patients; the inclusion of more type IIIA patients in the study would make the results more convincing.

In brief, this retrospective study showed desirable medium-term outcomes in patients who underwent revision THA with jumbo cups due to type II or IIIA Paprosky deficiency. Hence, we recommend jumbo cups for type II deficiency and for type IIIA bone loss with sufficient bone quantity [25]. The HOOS and SF-36 score improve earlier than the HHS. This may offer an opportunity for ensuring better functional recovery and helping patients to avoid mental or physical distress [26]. Therefore, we recommend that both functional and quality-of-life evaluations be taken into consideration during follow-up.

Acknowledgements

This study was funded by two National Natural Science Foundation of China (NSFC) projects (grant numbers: 81672138 and 81601883). This clinical research was performed with the support of the Orthopedics Department and Medical Records Department of Xiangya Hospital.

Disclosure of conflict of interest

None.

Address correspondence to: Dr. Long Wang and Jie Xie, Orthopedics Department, Xiangya Hospital, Central South University, No. 87 Xiangya Road, Kaifu District, Changsha, Hunan Province, China. Tel: +86 13974931684; Fax: 0731 89753006; E-mail: Dr_wanglong@csu.edu.cn (LW); Tel: +86 13637400813; Fax: 0731 89753006; E-mail: Dr_xiejie@163.com (JX)

References

- [1] Wang L, Dai Z, Wen T, Li M and Hu Y. Three to seven year follow-up of a tapered modular femoral prosthesis in revision total hip arthroplasty. *Arch Orthop Trauma Surg* 2013; 133: 275-281.
- [2] Zhang JB, Chen BC, Wang F, Sun R and Zhao BH. [The anatomical study of safe zones of the screw fixations in acetabular revision surgery]. *Zhonghua Wai Ke Za Zhi* 2009; 47: 693-696.
- [3] Zhou C, You Y, Shen W, Zhu YZ, Peng J, Feng HT, Wang Y, Li D, Shao WW, Li CX, Li WZ, Xu J and Shen X. Deficiency of sorting nexin 10 prevents bone erosion in collagen-induced mouse arthritis through promoting NFATc1 degradation. *Ann Rheum Dis* 2016; 75: 1211-1218.
- [4] Zeng M, Xie J, Li M, Lin S and Hu Y. Cementless femoral revision in patients with a previous cemented prosthesis. *Int Orthop* 2015; 39: 1513-1518.
- [5] Zeng M, Hu Y, Leng Y, Xie J, Wang L, Li M and Zhu J. Cementless total hip arthroplasty in advanced tuberculosis of the hip. *Int Orthop* 2015; 39: 2103-2107.
- [6] von Roth P, Abdel MP, Harmsen WS and Berry DJ. Uncemented jumbo cups for revision total hip arthroplasty: a concise follow-up, at a mean of twenty years, of a previous report. *J Bone Joint Surg Am* 2015; 97: 284-287.
- [7] Sheth NP, Melnic CM and Paprosky WG. Acetabular distraction: an alternative for severe acetabular bone loss and chronic pelvic discontinuity. *Bone Joint J* 2014; 96-b: 36-42.

Jumbo cups for revision of total hip arthroplasty

- [8] Schwarzkopf R, Iln HE and Ries MD. Pelvic discontinuity: modern techniques and outcomes for treating pelvic disassociation. *Hip Int* 2015; 25: 368-374.
- [9] Nwankwo C, Dong NN, Heffernan CD and Ries MD. Do jumbo cups cause hip center elevation in revision THA? A computer simulation. *Clin Orthop Relat Res* 2014; 472: 572-576.
- [10] Girard J, Touraine D, Soenen M, Massin P, Lafargue P and Migaud H. [Measurement of head penetration on digitalized radiographs: reproducibility and accuracy]. *Rev Chir Orthop Reparatrice Appar Mot* 2005; 91: 137-142.
- [11] Lachiewicz PF and Soileau ES. Fixation, survival, and dislocation of jumbo acetabular components in revision hip arthroplasty. *J Bone Joint Surg Am* 2013; 95: 543-548.
- [12] Iwase T, Ito T and Morita D. Massive bone defect compromises postoperative cup survivorship of acetabular revision hip arthroplasty with impaction bone grafting. *J Arthroplasty* 2014; 29: 2424-2429.
- [13] Huang Z, Zhang W, Lin J, Li W, Bai G and Shen R. [Extra-large uncemented acetabular components for hip revision]. *Zhongguo Xiu Fu Chong Jian Wai Ke Za Zhi* 2013; 27: 1313-1317.
- [14] Hansen E and Ries MD. Revision total hip arthroplasty for large medial (protrusio) defects with a rim-fit cementless acetabular component. *J Arthroplasty* 2006; 21: 72-79.
- [15] Gustke KA, Levering MF and Miranda MA. Use of jumbo cups for revision of acetabulae with large bony defects. *J Arthroplasty* 2014; 29: 199-203.
- [16] Gustke KA. Jumbo cup or high hip center: is bigger better? *J Arthroplasty* 2004; 19: 120-123.
- [17] Gross AE, Blackley H, Wong P, Saleh K and Woodgate I. The role of allografts in revision arthroplasty of the hip. *Instr Course Lect* 2002; 51: 103-113.
- [18] Gomez MM, Tan TL, Manrique J, Deirmengian GK and Parvizi J. The fate of spacers in the treatment of periprosthetic joint infection. *J Bone Joint Surg Am* 2015; 97: 1495-1502.
- [19] Fan CY, Chen WM, Lee OK, Huang CK, Chiang CC and Chen TH. Acetabular revision arthroplasty using jumbo cups: an experience in Asia. *Arch Orthop Trauma Surg* 2008; 128: 809-813.
- [20] Faizan A, Black BJ, Fay BD, Heffernan CD and Ries MD. Comparison of head center position and screw fixation options between a jumbo cup and an offset center of rotation cup in revision total hip arthroplasty: a computer simulation study. *J Arthroplasty* 2016; 31: 307-311.
- [21] Araujo IL, Castro MC, Daltro C and Matos MA. Quality of life and functional independence in patients with osteoarthritis of the knee. *Knee Surg Relat Res* 2016; 28: 219-224.
- [22] Noordin S, Duncan CP, Masri BA and Garbusz DS. Pelvic dissociation in revision total hip arthroplasty: diagnosis and treatment. *Instr Course Lect* 2010; 59: 37-43.
- [23] Brown NM, Morrison J, Sporer SM and Paprosky WG. The use of structural distal femoral allograft for acetabular reconstruction of paprosky type IIIA defects at a mean 21 years of follow-up. *J Arthroplasty* 2016; 31: 680-683.
- [24] Blumenfeld TJ and Bargar WL. Surgical technique: a cup-in-cup technique to restore offset in severe protrusio acetabular defects. *Clin Orthop Relat Res* 2012; 470: 435-441.
- [25] Gallo J, Vaculova J, Goodman SB, Konttinen YT and Thyssen JP. Contributions of human tissue analysis to understanding the mechanisms of loosening and osteolysis in total hip replacement. *Acta Biomater* 2014; 10: 2354-2366.
- [26] Ezelsoy M, Oral K, Caynak B, Bayramoglu Z and Akpınar B. Pain and the quality of life following robotic assisted minimally invasive surgery. *Heart Surg Forum* 2016; 19: E165-168.