

Original Article

Posterolateral decompression combined with interbody fusion and internal fixation for thoracic spinal stenosis

Junming Cao, Yongsheng Lin, Xiangbei Qi, Zhihong Wang, Yipeng Yang, Hehuan Xia, Bin Xu

Department of Orthopedics, The Third Hospital of Hebei Medical University, Shijiazhuang, Hebei Province, P. R. China

Received October 11, 2017; Accepted November 20, 2017; Epub February 15, 2018; Published February 28, 2018

Abstract: Objective: To investigate the efficacy of the posterolateral decompression combined with interbody fusion and internal fixation for thoracic spinal stenosis in patients. Methods: Between January 2014 and May 2016, a total of 50 patients with thoracic spinal stenosis admitted to the author's institution were selected as participants. All the enrolled participants received the posterolateral decompression combined with interbody fusion and internal fixation. The patients' postoperative complications were documented. The spinal cord functions and surgical outcomes were evaluated according to the spinal cord injury Frankel classification and the Otani grading criteria. Results: The posterolateral decompression combined with interbody fusion and internal fixation was completed successfully among all the eligible patients in this study. The mean operative time was 3.3 ± 0.7 h, and the mean intraoperative blood loss was 970 ± 110 ml. Cerebrospinal fluid leak was present in 2 patients, and transient spinal cord dysfunction was also present in 2. Among all the eligible patients, the results of preoperative Frankel classification were markedly different from those at 1 year postoperatively ($P<0.05$). The evaluation of the Otani grading at 1 year postoperatively revealed that the rate of good and excellent results was 86%. Conclusion: After the posterior decompression combined with interbody fusion and internal fixation, the patients with thoracic spinal stenosis had decreased complications, but favorable clinical outcomes. Thus, it is worthy of clinically wide use.

Keywords: Thoracic spinal stenosis, posterolateral decompression, internal fixation, clinical outcomes

Introduction

Thoracic spinal stenosis is thoracic spinal cord compression syndrome as a result of a reduction in the cross-sectional area of thoracic vertebral canal [1]. Although thoracic spinal stenosis is rare in the clinical settings, it may lead to irreversible spinal cord injury in patients if not treated timely. The primary method for the treatment of thoracic spinal stenosis is surgery [2, 3]. Moreover, some studies have shown that early surgery is associated with a greater improvement in postoperative neurological functions [4, 5]. However, the special anatomical structure of thoracic vertebrae and complex operation are prone to the presence of complications and even paraplegia. In addition, to our knowledge, as thoracic spinal stenosis is characterized by atypical clinical manifestations and unclear pathogenesis, the selection of proper surgical method and efficacy has been controversial. Anterior decompression allows a

most direct and clearest vision, and has little effect on the spinal cord, but it is ineffective in relieving stenosis in the spinal canal and nerve roots, and associated with large trauma, pulmonary complications and poor clinical outcomes [6]. In recent years, a growing attention has been paid to the posterolateral approach to decompression by clinical orthopedic surgeons. In addition, studies have demonstrated that for patients with thoracic spinal stenosis, decompression alone is not effective, but the addition of thoracic vertebrae internal fixation results in spinal stability and reduced compression to the spinal cord [7, 8]. Nevertheless, few reports have involved in the clinical outcomes of posterolateral decompression combined with interbody fusion and internal fixation in the treatment of thoracic spinal stenosis. Therefore, this study was designed to explore the clinical outcomes of posterolateral decompression combined with interbody fusion and internal fixation in the management of thoracic spinal stenosis,

Efficacy of posterolateral decompression with interbody fusion

in hope of providing an alternative clinical strategy and experimental basis for the treatment of thoracic spinal stenosis.

Materials and methods

Participants

From January 2014 to May 2016, 50 patients with thoracic spinal stenosis admitted to the Department of orthopedics in the author's institution who were scheduled to undergo posterolateral decompression combined with interbody fusion and internal fixation were taken as subjects. Patients who had confirmed single-segmental thoracic spinal stenosis on CT or MRI assessments, agreed to undergo posterolateral decompression combined with interbody fusion and internal fixation but no relevant contraindications were eligible for the study. Patients were excluded if they had severe cardio and cerebrovascular disease, hepatorenal dysfunction, osteoporosis, thoracic deformity, and thoracic spinal instability. The present study was approved by the Hospital Ethics Committee in the hospital and informed written consent was collected from each patient and their families.

Operative procedures

The operation was performed by the spinal surgeons in the same group. After the induction of combined intravenous-inhalational anesthesia, the patients were placed in a prone position. A posterior median sternotomy was performed to expose the spinous process of the segment with thoracic spinal stenosis, the transverse process and the articular process of the upper and lower vertebral body. The ossification was removed or hypertrophic ligamentum flavum was excised. The dura mater and the spinal cord were fully exposed for assessment of the extent of disc protrusion and the degree of ossification. The spinal cord decompression was performed by gradually separating the adhesion between the dura sac and the intervertebral disc, and discectomy and decompressive laminotomy were conducted to remove the osteophyte on the posterior margin of the vertebral body. Great care should be taken to avoid damages to the spinal cord, nerve roots and peripheral vessels during the surgery. After completion of the intervertebral decompression, an interbody cage was implanted for the

following interbody fusion. Meanwhile, a rod linking the pedicle screws were mounted and fixed, followed by adequate hemostasis of the incision site, rinse of the wound, placement of the drainage catheter and suture of the incision layer by layer.

Postoperative treatment

For the patients, routine antibiotics were administered for 3 days to prevent infection. The drainage catheter was removed at 48 hours after surgery. They were encouraged to ambulate for early functional exercise after 1-week bedrest.

Outcome measures

The patients received 1-year follow-up by telephone reservation and outpatient review. The results of the final follow-up were considered as a measure of postoperative monitoring. Among the patients, the operation time, intraoperative blood loss and postoperative complications were documented; the preoperative and postoperative assessments on the Oswestry disability index (ODI) and the visual analogue scale (VAS) were observed. The ODI was a scale for evaluation of the quality of life and functionality in patients, including ten items of pain, self-care, lifting, walking, sitting, standing, sleeping, sexual life, social activities and travel. On a scale of 50 points, the scoring formula was as follows: Actual score/50 (maximum score possible) * 100%. If there was a problem unanswered, the scoring formula was: Actual score/45 (maximum score possible) * 100%, with higher scores indicating more severe functional disability. The VAS was a scale of 10 points in total, with the scoring criteria as follows: 0 indicating painless, less than 3 indicating mild pain which was tolerable, 4-6 pain affecting sleep which was basically tolerable, 7-10 incrementally severe pain which was unbearable, affecting appetite and sleep. The Frankel grading of spinal cord injury (Grade A, B, C, D and E) was used to evaluate and compare the functions of the spinal cord before and after the operation in patients [9]. The Otani grading criteria were applied to evaluate the surgical efficacy and calculate the rate of good and excellent results in the patients [10]. The formula states as below: Good and excellent rate = No. of good or excellent cases/Total number of cases * 100%. The assessment of

Efficacy of posterolateral decompression with interbody fusion

Table 1. General data of eligible patients

Variable	Value
Age ($\bar{x}\pm s$, year)	41.8 \pm 6.5
Sex (n, %)	
Male	35 (70%)
Female	15 (30%)
Course of disease ($\bar{x}\pm s$, month)	5.5 \pm 1.4
Complications (n, %)	
Thoracic and abdominal constriction	28 (56%)
Defecation dysfunction	22 (44%)
Intervertebral disc herniation (n, %)	
T7/T8	5 (10%)
T8/T9	11 (22%)
T9/T10	15 (30%)
T10/T11	19 (38%)

Table 2. Perioperative general data of patients

Variable	Value
Operation time ($\bar{x}\pm s$)	3.3 \pm 0.7 h
Intraoperative blood loss ($\bar{x}\pm s$)	970 \pm 110 ml
Postoperative complications (n, %)	
Cerebrospinal fluid leak	2 (4%)
Transient spinal cord dysfunction	2 (4%)
Dural laceration	1 (2%)

intervertebral fusion of the patients was made according to the method reported by Suk and colleagues [11].

Statistical analysis

All the data analyses were made with the use of the SPSS software, version 19.0. Measurement data were represented as mean \pm sd. The paired t-test was applied for comparisons of the indicators before and after operation. Enumeration data were represented as percentages, and the chi square test was used for comparison of the variables before and after operation. The value of $P < 0.05$ was deemed to be statistically significant.

Results

General data

Table 1 shows that among the eligible patients, 35 were male and 15 were female, with a mean age of 41.8 \pm 6.5 years and a mean course of

disease of 5.5 \pm 1.4 months. Thoracic and abdominal constriction occurred in 28 patients and defecation dysfunction in 22; the results of imaging examination showed the classification of intervertebral disc herniation among the patients: 5 cases of T7/T8, 11 of T8/T9, 15 of T9/T10 and 19 of T10/T11.

Perioperative period

Each of the 50 patients completed the operation successfully. Among them, the mean operative time was 3.3 \pm 0.7 h; the mean intraoperative blood loss was 970 \pm 110 ml. The postoperative complications included cerebrospinal fluid leak in 2 cases, transient spinal cord dysfunction in 2 cases and dural laceration in 1 case. All the patients were cured and discharged after active symptomatic treatment (**Table 2**).

ODI score and VAS score

Among the patients, the mean ODI score was 62.4 \pm 8.5 preoperatively but 22.3 \pm 2.6 at 1-year follow up postoperatively, and the difference was noticeably significant ($P = 0.000$). The mean VAS pain score was 6.1 \pm 0.5 preoperatively, but 2.6 \pm 0.3 at 1-year follow up postoperatively, and the difference was statistically significant ($P = 0.000$; **Figure 1**).

Frankel classification of spinal cord injury of the patients

Among the patients, there were 14 cases of Grade B, 22 of Grade C, and 14 of Grade D preoperatively; no patients with Grade B, but 27 cases of Grade C, 19 of Grade D and 14 of Grade E were seen at the final follow-up postoperatively, and the postoperative general improvement of Frankel classifications among the patients was significant as compared to that postoperatively ($\chi^2 = 26.225$, $P = 0.000$, **Table 3**).

Surgical outcomes

During the follow-up period, no cases of dislocation, loosening or even rupture of the internal fixers were observed among the patients (**Figure 2**). According to the criterion of bone union, the union rate was 100%. Based on the Otani grading criteria, no patients with poor results were noted at the final follow-up, with 24 cases of excellent results (48%), 19 of good results

Efficacy of posterolateral decompression with interbody fusion

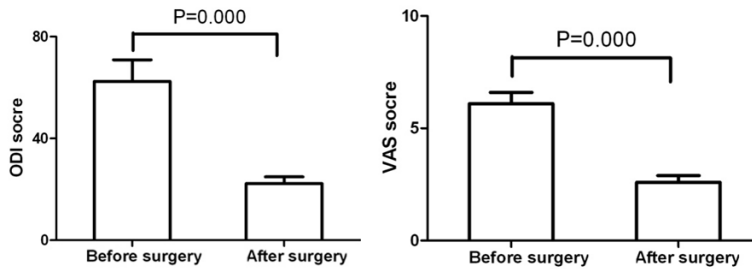


Figure 1. Comparison of ODI and VAS scores of patients before and after posterolateral decompression combined with interbody fusion and internal fixation for thoracic spinal stenosis.

Table 3. Comparison of preoperative and postoperative Frankel classification (n, %)

Frankel grade	Preoperative	Final follow-up
A	0 (0.0)	0 (0.0)
B	14 (28.0%)	0 (0.0)
C	22 (44.0%)	27 (54.0%)
D	14 (28.0%)	19 (38.0%)
E	0 (0.0)	4 (8.0%)

(38%), and 7 of fare results (14%), as shown in **Figure 3**.

Discussion

The preferred method for the treatment of thoracic spinal stenosis is surgery, the primary objective of which is to make decompression of the stenotic thoracic vertebral segments [12, 13]. As the spinal cord site, compression position, operation habits of the operators and the results of preoperative evaluation vary considerably, there are different clinical approaches to surgeries. How to improve the neurological functions, reduce operative complications and simplify the operative procedures regarding thoracic spinal stenosis in patients has been the focus of clinical orthopedics. Although anterior decompression is an ideal surgical technique for thoracic spinal stenosis with the compression originated from the anterior part. Nevertheless, the anterolateral approach is limited in the difficulties in assessments of the spinal canal, intervertebral discs, nerve roots and the nerve root canal, and in relief of compression from the posterior part on the spinal cord [14]. The conventional posterior decompression is relatively simpler, but intraoperative traction may result in spinal cord injury, leading to irreversible neurological recovery [15, 16]. Therefore, choosing a correct surgical approach

is paramount in the treatment of thoracic spinal stenosis.

When compared with anterior or posterior approaches to decompression, the posterolateral approach takes advantages in resecting the spinous processes, lamina, ossified ligamentum flava and hyperplastic articular processes in the stenotic thoracic spinal segments, allowing a better expose of dura mater and the

spinal cord, enlarging the nerve root canal, and solving the problem of the neurological compression from the posterior stenosis in the thoracic spinal canal. The posterolateral approach has shown to reduce traction to the spinal cord, avoiding traction-induced spinal cord injury [17]. Other studies have also reported that the posterior decompression combined with internal fixation and in situ fusion has more satisfactory outcomes and fewer complications than the posterior approach to decompression alone [18, 19]. A follow-up study involving postoperative thoracic spinal stenosis patients revealed that, the posterior decompression combined with interbody fusion and internal fixation led to good outcomes, with obvious kyphosis present in only 1 patient. Noticeably, the interbody fusion and internal fixation following posterior decompression may result in better recovery of the functions of spinal cord [20]. In the current study, the results of the Frankel grading showed 14 cases of Grade B, 22 of Grade C and 14 of Grade D before posterolateral decompression combined with interbody fusion and internal fixation. At the end of final follow-up postoperatively, the Frankel grading has improved significantly among the patients, with 27 cases of Grade C, 19 of Grade D and 4 of Grade E, and the differences between preoperative grades and postoperative grades were statistically significant. This suggests that the operation has the benefit of recovery of functions of the spinal cord in patients. Moreover, the rate of bone fusion in all the patients was 100%, and no cases of rupture or loosening of the internal fixators were found during the follow-up period. The Otani grading results demonstrated that the rate of good and excellent results was 86% at 1 year postoperatively.

The results of postoperative complications in this study indicated that transient spinal cord

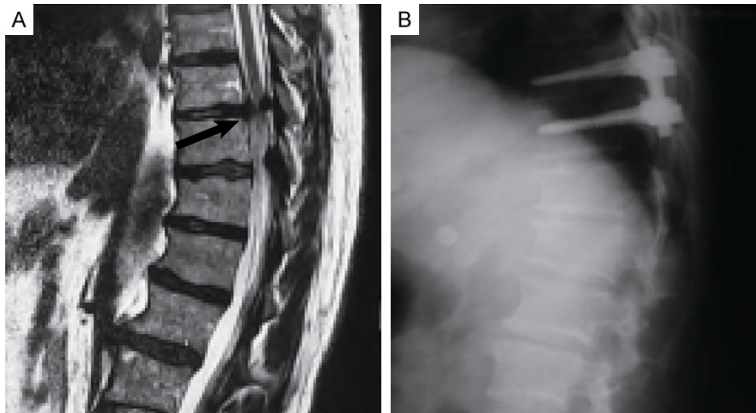


Figure 2. Typical preoperative and postoperative images of patients with thoracic spinal stenosis. A. Preoperative MRI scans, with the arrow showing the thoracic spinal stenosis lesion; B. Postoperative lateral radiograph.

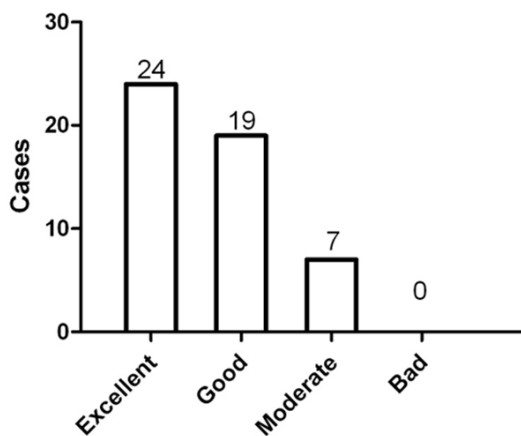


Figure 3. The Otani grading of postoperative outcomes among the patients with thoracic spinal stenosis.

dysfunction induced by spinal cord edema occurred in 2 patients; cerebrospinal fluid leak induced by adhesions between ventral dural and intervertebral disc and posterior longitudinal ligament also occurred in 2 patients; dural laceration occurred in 1 patient. These complications were all cured after active targeted treatment. The present study suggests that there are certain associations between complications and operative procedures. During the operation, we should seek to take the lateral approach to avoid spinal cord injury and incrementally separate the tissues adhering to dural mater to avoid dural rupture which would lead to cerebrospinal fluid leak. Hormone is administered before the surgical decompression to reduce spinal inflammation.

In conclusion, at 1 year after the posterolateral decompression combined with interbody fusion and internal fixation, the patients with thoracic spinal stenosis had significant pain relief, fewer complications, and more favorable short-term clinical outcomes. Therefore, it is worth of extensively clinical application. However, there are some limitations, including a small sample size and lack of randomized controlled trials. More long-term follow-up studies are needed for validation of the long-term outcomes of the posterolateral

decompression combined with interbody fusion and internal fixation.

Disclosure of conflict of interest

None.

Address correspondence to: Junming Cao, Department of Orthopedics, The Third Hospital of Hebei Medical University, No.139, Ziqiang Road, Shijiazhuang 050051, Hebei Province, P. R. China. Tel: +86-0311-88603000; Fax: +86-0311-88603000; E-mail: junmingcao68@163.com

References

- [1] Yoon SH, Kim WH, Chung SB, Jin YJ, Park KW, Lee JW, Chung SK, Kim KJ, Yeom JS, Jahng TA, Chung CK, Kang HS and Kim HJ. Clinical analysis of thoracic ossified ligamentum flavum without ventral compressive lesion. *Eur Spine J* 2011; 20: 216-223.
- [2] Nie ZH, Liu FJ, Shen Y, Ding WY and Wang LF. Lamina osteotomy and replantation with miniplate fixation for thoracic myelopathy due to ossification of the ligamentum flavum. *Orthopedics* 2013; 36: e353-359.
- [3] Amato V, Giannachi L, Irace C and Corona C. Thoracic spinal stenosis and myelopathy: report of two rare cases and review of the literature. *J Neurosurg Sci* 2012; 56: 373-378.
- [4] He B, Yan L, Xu Z, Guo H, Liu T and Hao D. Treatment strategies for the surgical complications of thoracic spinal stenosis: a retrospective analysis of two hundred and eighty three cases. *Int Orthop* 2014; 38: 117-122.
- [5] Hott JS, Feiz-Erfan I, Kenny K and Dickman CA. Surgical management of giant herniated tho-

Efficacy of posterolateral decompression with interbody fusion

- racic discs: analysis of 20 cases. *J Neurosurg Spine* 2005; 3: 191-197.
- [6] Simpson JM, Silveri CP, Simeone FA, Balderston RA and An HS. Thoracic disc herniation. Re-evaluation of the posterior approach using a modified costotransversectomy. *Spine (Phila Pa 1976)* 1993; 18: 1872-1877.
- [7] Kurosa Y, Yamaura I, Nakai O and Shinomiya K. Selecting a surgical method for thoracic myelopathy caused by ossification of the posterior longitudinal ligament. *Spine (Phila Pa 1976)* 1996; 21: 1458-1466.
- [8] Kawahara N, Tomita K, Murakami H, Hato T, Demura S, Sekino Y, Nasu W and Fujimaki Y. Circumspinal decompression with dekyphosis stabilization for thoracic myelopathy due to ossification of the posterior longitudinal ligament. *Spine (Phila Pa 1976)* 2008; 33: 39-46.
- [9] Frankel HL, Hancock DO, Hyslop G, Melzak J, Michaelis LS, Ungar GH, Vernon JD and Walsh JJ. The value of postural reduction in the initial management of closed injuries of the spine with paraplegia and tetraplegia. I. Paraplegia 1969; 7: 179-192.
- [10] Otani K, Yoshida M, Fujii E, Nakai S and Shibasaki K. Thoracic disc herniation. Surgical treatment in 23 patients. *Spine (Phila Pa 1976)* 1988; 13: 1262-1267.
- [11] Suk SI, Lee CK, Kim WJ, Lee JH, Cho KJ and Kim HG. Adding posterior lumbar interbody fusion to pedicle screw fixation and posterolateral fusion after decompression in spondylytic spondylolisthesis. *Spine* 1997; 22: 220-220.
- [12] Hou X, Sun C, Liu X, Liu Z, Qi Q, Guo Z, Li W, Zeng Y and Chen Z. Clinical features of thoracic spinal stenosis-associated myelopathy: a retrospective analysis of 427 cases. *Clin Spine Surg* 2016; 29: 86-89.
- [13] Dimar JR 2nd, Bratcher KR, Glassman SD, Howard JM and Carreon LY. Identification and surgical treatment of primary thoracic spinal stenosis. *Am J Orthop (Belle Mead NJ)* 2008; 37: 564-568.
- [14] Min JH, Jang JS and Lee SH. Clinical results of ossification of the posterior longitudinal ligament (OPLL) of the thoracic spine treated by anterior decompression. *J Spinal Disord Tech* 2008; 21: 116-119.
- [15] Koda M, Furuya T, Okawa A, Inada T, Kamiya K, Ota M, Maki S, Takahashi K, Yamazaki M, Aramomi M, Ikeda O and Mannoji C. Mid- to long-term outcomes of posterior decompression with instrumented fusion for thoracic ossification of the posterior longitudinal ligament. *J Clin Neurosci* 2016; 27: 87-90.
- [16] Xu ZW, Hu YC, Sun CG, Shang XP, Lun DX, Li F, Ji XB, Liu DY, Chen NW and Zhuang QS. Treatment for thoracic ossification of posterior longitudinal ligament with posterior circumferential decompression. *Orthop Surg* 2017; 9: 206-214.
- [17] Yang C, Bi Z, Fu C and Zhang Z. A modified decompression surgery for thoracic myelopathy caused by ossification of posterior longitudinal ligament: a case report and literature review. *Spine (Phila Pa 1976)* 2010; 35: E609-613.
- [18] Topalidou A, Tzagarakis G, Balalis K and Papaioannou A. Posterior decompression and fusion: whole-spine functional and clinical outcomes. *PLoS One* 2016; 11: e0160213.
- [19] Wang H, Ma L, Xue R, Yang D, Wang T, Wang Y, Yang S and Ding W. The incidence and risk factors of postoperative neurological deterioration after posterior decompression with or without instrumented fusion for thoracic myelopathy. *Medicine (Baltimore)* 2016; 95: e5519.
- [20] Li F, Chen Q and Xu K. Surgical treatment of 40 patients with thoracic ossification of the ligamentum flavum. *J Neurosurg Spine* 2006; 4: 191-197.