

Original Article

¹⁸F-FDG PET/CT is still a useful tool in detection of metastatic extent in patients with high risk prostate cancer

Guohua Shen^{1*}, Jiandong Liu^{2*}, Xue Jiang¹, Fanglan Li¹, Hao Zeng², Rui Huang¹, Anren Kuang¹

Departments of ¹Nuclear Medicine, ²Urology, West China Hospital of Sichuan University, Chengdu, China. *Equal contributors.

Received November 16, 2017; Accepted May 3, 2018; Epub July 15, 2018; Published July 30, 2018

Abstract: Recent studies have demonstrated that ¹⁸F-FDG PET/CT might indeed be useful in specific phases of prostate cancer, especially for aggressive primary prostate tumors. Therefore, our study aimed to evaluate its diagnostic performance in the detection of metastatic lesions in patients with high-risk prostate cancer with comparison to conventional imaging. The study included 67 patients with newly diagnosed high risk prostate cancer, who underwent FDG PET/CT for imaging evaluation. Of these patients, 40 underwent additional MRI with diffusion-weighted imaging (DWI-MRI) for the assessment of lymph node metastases and 46 underwent ^{99m}Tc-MDP bone scintigraphy for the assessment of bone involvement. All lymph nodes were diagnosed based on pathological analysis, and bone lesions were diagnosed based on comprehensive clinical examinations or clinical/imaging follow-up. Diagnostic performances were compared between FDG PET/CT and DWI-MRI regarding lymph node metastases, between FDG PET/CT, and BS regarding bone involvement. The sensitivity and specificity regarding identifying nodal metastases of high risk prostate cancer were 84.6% and 96.3% for FDG PET/CT, 46.2% and 100% for DWI-MRI, respectively. For detection of bone lesions, FDG PET/CT showed a higher specificity than BS (92.0% vs. 80.0%) despite the same sensitivity (90.4% vs. 90.4%). Current results indicated that ¹⁸F-FDG PET/CT may be useful in imaging evaluation of metastatic extent in high risk prostate cancer, and might help clinicians formulate the treatment plan.

Keywords: ¹⁸F-FDG PET/CT, bone scan, DWI-MRI, metastasis, prostate cancer, high-risk

Introduction

Prostate cancer is the most common male cancer, accounting for 21% of all estimated new cases in men [1]. Although men with localized prostate cancer can be treated with curative intent, some patients will experience biochemical failure and then probably develop castration-resistant metastatic prostate cancer, which is the main cause of disease-related mortality [2]. Thus, the initial staging of prostate cancer, especially for those with aggressive or high-risk prostate cancer, is of prime importance, which may affect clinical management.

Conventional imaging methods such as transrectal ultrasound, computed tomography, MRI and ^{99m}Tc-MDP bone scintigraphy (BS) are currently used for the diagnosis of prostate can-

cer. However, they are not completely satisfactory because of this remarkably heterogeneous disease [3]. Based on the Warburg effect, positron emission tomography/computed tomography (PET/CT) with ¹⁸F-fluorodeoxyglucose (FDG) has become the mainstay for the imaging evaluation such as diagnosis, guided biopsy, staging, response assessment, and prognostication for many cancers [4]. However, FDG PET/CT is not routinely performed in prostate cancer patients because of the following reasons: (a) general low avidity of ¹⁸F-FDG in the majority of prostate cancer (b) the influence of FDG excreted into the urinary bladder adjacent to the prostate gland (c) false positive FDG accumulation in benign prostate hyperplasia. Some initial studies assessed the role of FDG PET/CT in the diagnosis or staging of primary tumor, and the overall results were unsatisfactory [5, 6]. Several studies showed that FDG uptake tend-

Table 1. Baseline characteristics of subjects included in this study

Parameters	n
Age (year)	68.86 (48-85)
Biopsy Gleason score	
6	1
7	16
8	13
9	36
10	1
Pretreatment PSA (ng/ml)	
< 20	17
≥ 20	50
Distant metastatic sites revealed by FDG PET/CT	
Bone	21
Lung	9
Cervical/mediastinal lymph node	6
Liver	1
Adrenal gland	1
Imaging evaluation	
FDG PET/CT	67
DWI-MRI+FDG PET/CT	40
BS+FDG PET/CT	46
Treatment	
Radical prostatectomy + PLND	40
Hormonal therapy/radiotherapy/chemotherapy	24
No treatment	3

PLND: pelvic lymph node dissection.

ed to increase in more aggressive prostate cancer, either recurrent or metastatic lesions [7, 8]. Moreover, overexpression of glucose transporters has been revealed in prostate cancer with high Gleason score [9, 10]. Recently, the results of Liu's study indicated that although FDG PET-CT is not useful for the diagnosis of primary prostate cancer with a low sensitivity of 33%, whereas it helped detect metastatic disease in six of the nine patients with high serum PSA level [11]. Beauregard et al. reported that for patients with a high-grade prostate cancer (Gleason sum ≥ 8), suspicious foci of increased FDG uptake were found in the prostate, lymph nodes and bones in 44, 13, and 6% of patients, respectively [12]. FDG PET/CT also helped improve pre-treatment prognostic stratification by predicting pathological grade [12]. Taken together, FDG PET/CT is indeed limited in detection or diagnosis of primary prostate tumors, but it may be useful for

evaluating the extent of metastatic disease in patients with aggressive prostate cancer. Our study therefore aimed to evaluate the diagnostic performance of FDG PET/CT in detecting metastatic lesions in patients with high risk prostate cancer, with an emphasis on the comparison with conventional imaging procedures (DWI-MRI and BS).

Materials and methods

Patient enrollment

One hundred and fifty-four consecutive patients with newly diagnosed prostate cancer using transrectal ultrasound-guided prostate biopsy were referred for imaging evaluation using FDG PET/CT, in addition to whole-body BS and MRI with diffusion weighted imaging (DWI-MRI) between March 2013 and April 2014. The patients with Gleason score ≥ 8 or PSA ≥ 20 ng/ml were regarded to be at high-risk levels, and these patients were included in this study. Patients with contraindications to the imaging examinations were excluded from this study. Patients with a history of malignancy within 5 years or previous prostatic operation were also excluded. This retrospective study was approved by West China Hospital of Sichuan University and all the written consent was obtained.

PET/CT imaging

PET/CT scans were performed with a PET/CT modality (Gemini GXL, Philips Corp, the Netherlands). The patients were asked to fast for 6 hours, and the blood glucose level was lower than 200 mg/dL. The PET/CT scan was performed approximately 60 minutes after the administration of 185-370 MBq of ¹⁸F-FDG (5.18 MBq/kg), from base of skull to upper thigh. A low-dose CT scan was performed first with a voltage of 120 kV, a current intensity of 40 mA, a tube rotation of 0.8 s, and a section thickness of 4 mm, used for attenuation correction. A full-dose CT scan was then performed at 120 kV and 140 mA. Emission data was acquired in three dimensional mode for 2.5 min

FDG PET/CT in high risk prostate cancer

Table 2. Comparison of FDG PET/CT, DWI-MRI and BS for identifying nodal metastases (n=40) and bone metastases (n=46) in high-risk prostate cancer patients

	FDG PET/CT (+)	FDG PET/CT (-)	K value
Nodal metastases (n=40)			
DWI-MRI (+)	6	0	0.58
DWI-MRI (-)	6	28	
Bone involvement (n=46)			
BS (+)	19	5	0.70
BS (-)	2	20	

per bed position. PET images were reconstructed using a 3D-line of response algorithm. The PET and CT images were co-registered with Syntegra software.

MRI with DWI

All patients underwent a 3.0 T MRI with an endorectal coil for signal reception (Trio Tim, Siemens Medical System, Erlangen, Germany). T2-weighted imaging (TR/TE, 6300/94 ms; matrix size, 320×320) and diffusion weighted imaging (TR/TE, 5900/76 ms; matrix size, 192×192; acquisition time, 60 sec; b=50, 800 s/mm²) of the entire pelvis were acquired from the aortic bifurcation to the pubic symphysis. Dynamic contrast-enhanced imaging (DCEI) using volumetric interpolated breath-hold examinations (VIBE) (TR/TE, 4.03/1.43; matrix size, 320×320; flip angle, 9° bandwidth, 350 Hz/Px) were followed by fast intravenous injection of 0.1 mmol of gadobutrol (Gadovist; Bayer Schering Pharma AG, Germany) at a rate of 2 ml/sec. The slice thickness/interslice gap was 2.5 mm/0.5 mm for T2WI, 3 mm/0.5 mm for DWI, and 3 mm/0.5 mm for DCEI.

Bone scintigraphy

Three hours after administration of 740 MBq of technetium-99m methylene diphosphonate (99m-Tc MDP), whole-body planar imaging was performed in the anterior and posterior position using a dual head SPECT scanner (Precedence; Philips Medical Systems, Cleveland, OH, USA) with a low-energy, high-resolution, parallel-hole collimator. The images were acquired with a 128×128 pixel matrix at 10 cm/min.

Image analysis

All the images were interpreted blindly and separately, two experienced nuclear physicians

for FDG PET/CT images, one for BS images, and two experienced radiologists for DWI-MRI images. For FDG PET/CT, the lesions in the regional lymph nodes and distant sites were reported based on the abnormal FDG uptake and morphologic features. For DWI-MRI, the diagnosis was analyzed based on data from the combination of T2-weighted imaging, DWI and ADC mapping, dynamic contrast

enhanced (DCE) MRI. A lesion with high signal intensity relative to muscle on T2, or high signal intensity on DWI and low signal intensity on ADC map, or hyperenhancing on early phase images with rapid washout on delayed images was considered a positive finding. Lymph nodes lying in the territory of drainage of prostatic tumors were classified as malignant if they had a short-axis diameter > 10 mm or if they showed restricted diffusion on the ADC map [13]. Each site of abnormal uptake of ^{99m}Tc-MDP on BS that could not be definitely explained by benign abnormalities such as osteophytes, degenerative change, was considered as malignancies.

Reference standard

All the patients underwent a systematic 12-core biopsy, and the specimens were diagnosed by an experienced pathologist based on Gleason score and histological type. Forty patients then received radical prostatectomy with an extended bilateral pelvic lymph node dissection (PLND), and their lymph node lesions were pathologically diagnosed. All the bone lesions got a final diagnosis based on the clinical/imaging follow-up at least 1 year. An increase in tumor size or a change in tumor nature including lytic or sclerotic change was considered to be malignant.

Statistical analysis

For patients with high risk level, comparison of FDG PET/CT and DWI-MRI for detecting lymph node metastasis or FDG PET/CT and BS for detecting bone metastasis was performed with the McNemar test. The specificity, sensitivity, positive and negative predictive value (PPV and NPV) of individual modalities were also obtained. A *p* value of less than 0.05 was considered to be statistically significant.

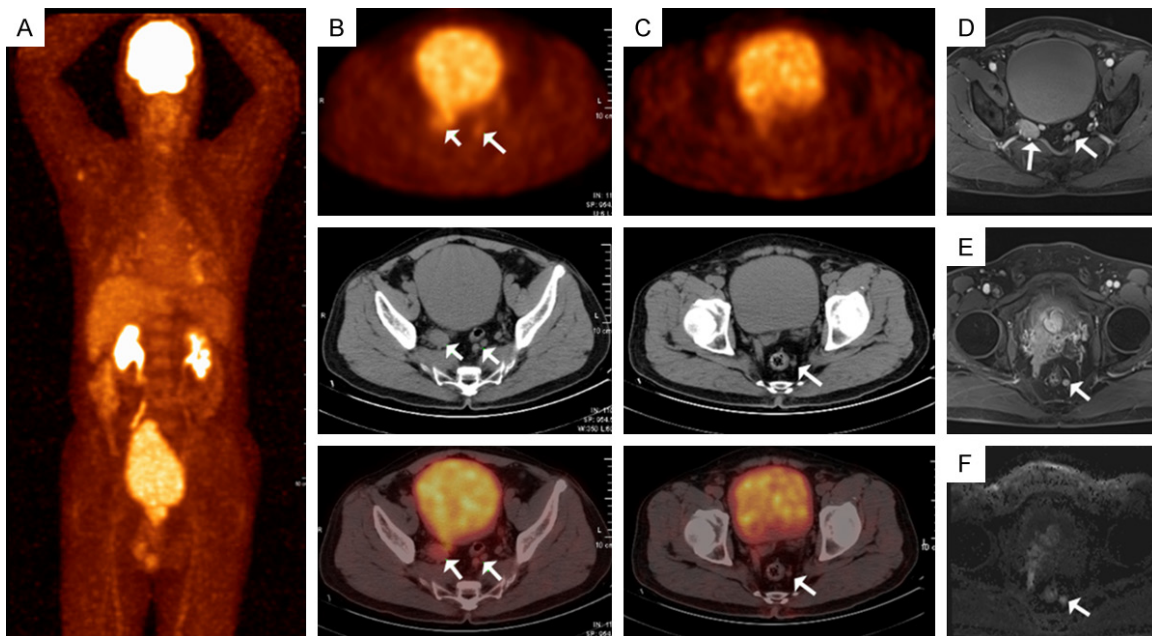


Figure 1. Concordant imaging findings of PET/CT and DWI-MRI in a 66-year-old patient with a Gleason sum 8 (4+4) prostate cancer. Multiple lymph nodes of bilateral internal iliac artery and sacral promontory showed increasing uptake of FDG with SUVmax of 3.5 and maximum diameter of 3.0 cm (A-C). These lesions also showed high signal intensity on T2 or DWI images with the maximum diameter of 3.2 cm (D-F).

Results

Patient characteristics

Eventually, sixty-seven patients with high risk prostate cancer were enrolled in the present analysis. Their baseline characteristics are summarized in **Table 1**. The mean age was 68.86 years ranging from 48 to 85 years. Of the included patients, 40 underwent radical prostatectomy and PLND, 14 patients received only hormonal therapy, 6 patients received hormonal therapy and radiotherapy, 4 patients received hormonal therapy and chemotherapy, and 3 patients received no therapy. Forty patients underwent FDG PET/CT and DWI for the assessment of lymph node status, and 46 patients underwent FDG PET/CT and BS for the assessment of bone metastases.

In addition to regional lymph node and bone metastases, other distant metastatic sites were also revealed by PET/CT, including lung, liver, adrenal gland, and cervical or mediastinal lymph node (**Table 1**).

FDG PET/CT for detecting metastatic extend

The comparison of FDG PET/CT and DWI-MRI for detecting nodal lesions is presented in **Table 2**. For detecting nodal metastases, there

was moderate agreement between FDG PET/CT and DWI-MRI ($k=0.583$). Six positive and 28 negative findings were concordant for both methods (**Figure 1**). In addition, FDG PET/CT identified metastatic lymph nodes in six patients that had negative presences on DWI-MRI (**Figure 2**), and of these patients, 5 cases had metastatic lesions while one patient did not have metastatic disease based on the reference standard. On a patient-based analysis, the sensitivity and specificity for detecting lymph node metastases in high-risk prostate cancer were 84.6% and 96.3% for FDG PET/CT, 46.2% and 100.0% for DWI-MRI, respectively (**Table 3**). There were 2 false negative findings with FDG PET/CT and 7 with DWI-MRI. One false positive node of FDG PET/CT was confirmed to be benign during follow-up.

For the diagnosis of bone involvement, the results of FDG PET/CT and BS were concordant in 39 patients (**Figure 3**). BS overdiagnosed distant metastases in 5 patients, of which all lesions were finally diagnosed as old occult fracture or focal degenerative change (**Table 2**). In addition, in a 67-year-old man, BS revealed some bone metastases that were not presented on PET/CT (**Figure 4**). Compared with the reference standard, both FDG PET/CT and BS failed to identify bone metastasis in two

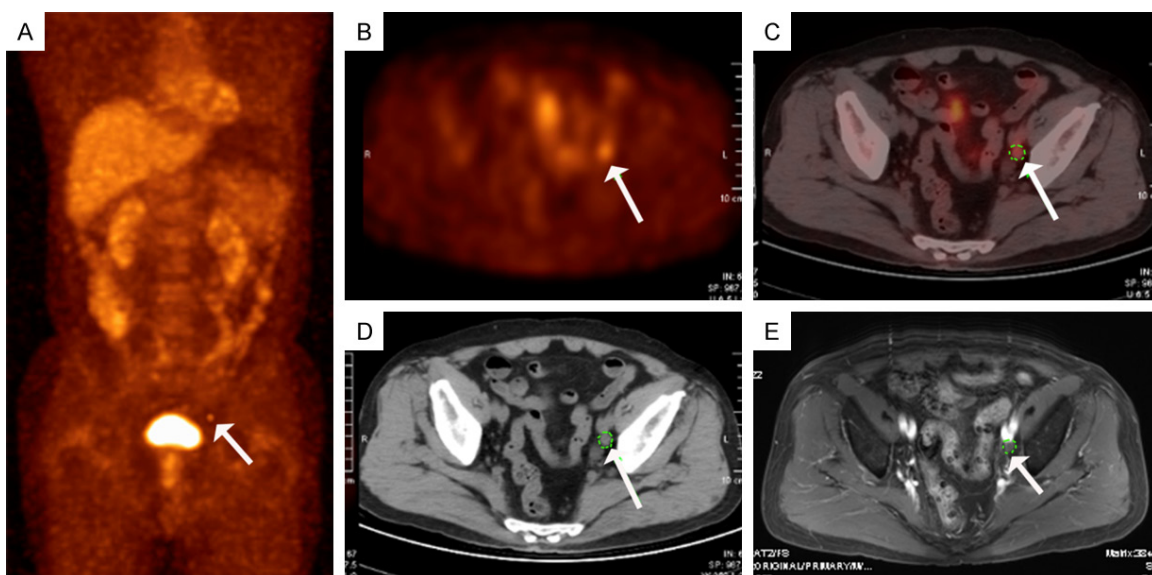


Figure 2. In a 75-year old prostate cancer patient with Gleason sum of 9 (5+4), FDG PET/CT identified a metastatic lymph node of left lateral iliac artery with SUVmax of 4.0, showing high FDG uptake (A-D) while it was diagnosed as negative report based on the criteria of DWI-MRI, which was only 0.7 cm in diameter without hyperenhancing (E).

Table 3. Diagnostic performance of FDG PET/CT, DWI-MRI and BS for detecting metastatic extent in high-risk prostate cancer patients

	Sensitivity	Specificity	PPV	NPV
Nodal metastases (n=40)				
FDG PET/CT	84.6% (11/13)	96.3% (26/27)	91.7% (11/12)	92.9% (26/28)
DWI-MRI	46.2% (6/13)	100.0% (27/27)	100.0% (6/6)	79.4% (27/34)
Bone metastases (n=46)				
FDG PET/CT	90.4% (19/21)	92.0% (23/25)	90.9% (19/21)	92.0% (23/25)
BS	90.4% (19/21)	80.0% (20/25)	79.2% (19/24)	90.9% (20/22)

PPV: positive predictive value; NPV: negative predictive value.

patients, however FDG PET/CT revealed more true negative findings than BS (23 vs. 20). FDG PET/CT showed a higher specificity compared with BS despite the same sensitivity (sensitivity: 90.4% vs. 90.4%; specificity: 92.0% vs. 80.0%, **Table 3**).

The proportions of patients for whom the imaging paradigm would have provided sufficient clinically relevant information to assess pelvic lymph nodes were 82.5% (33/40) for DWI-MRI and 92.5% (37/40) for FDG PET/CT, respectively. With regard to evaluating bone involvement, the proportions were 84.8% (39/46) for BS and 91.3% (42/46) for FDG PET/CT, respectively.

Discussion

To optimize the treatment strategy, accurate pre-treatment disease assessment is of prime

importance in prostate cancer, especially for high risk prostate cancer. For example, if there is lymph node or distant metastases, loco-regional treatment with radical prostatectomy or radiotherapy is rarely curative, and then patients might receive external beam radiotherapy, androgen deprivation therapy, or chemotherapy [14]. The present study demonstrates that FDG PET/CT is useful for imaging evaluation in this setting, especially in detecting pelvic lymph node and distant metastases. It showed better diagnostic performance in the assessment of nodal metastasis and bone involvement compared with conventional methods.

Indeed, the role of FDG PET/CT in prostate cancer has been somewhat misunderstood for a long time because of a general misconception that FDG PET/CT is not useful in prostate

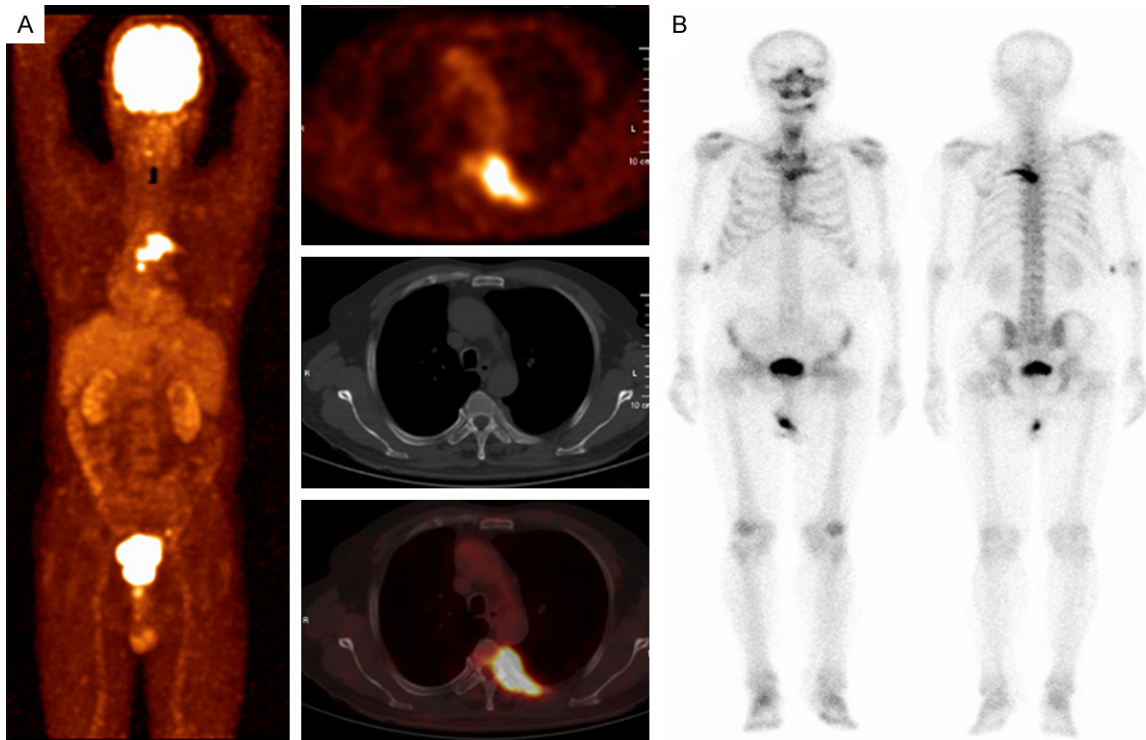


Figure 3. ^{18}F -FDG PET/CT showed remarkable uptake in the fourth, fifth, and sixth vertebral body as well as the fifth posterior rib without obvious destruction of bone (SUVmax = 10.6) (A). $^{99\text{m}}\text{Tc}$ -MDP bone scan also revealed intense MDP accumulation in the same region (B).

cancer. Because of low accumulation in indolent prostatic lesions [15], false positive findings with prostatitis or prostatic hyperplasia [16], and interference of urinary radiotracer [5], FDG PET/CT might not be useful in the diagnosis or staging of clinically organ-confined prostate cancer [17]. However, based on the initial data of the National Oncologic PET Registry, FDG PET/CT had an impact on clinical management of prostate cancer, with 25.3% of cases changing from non-treatment to treatment and 9.7% of cases from treatment to non-treatment [18]. It is reasonable that the initial staging for certain subgroups of patients with high-risk prostate cancer, FDG PET/CT is useful for evaluating the extent of metastatic lesions. Some biologic studies might provide reasonable explanations for its use in advanced or aggressive prostate cancer. Stewart et al. evaluated expression of glucose transporter-1 (Glut-1) that is closely related to the FDG uptake within benign prostatic hypertrophy and prostate cancer tissue, and found that Glut-1 gene expression was significantly higher in prostate cancer compared with benign tissue and also correlated directly with Gleason score [9]. A German

study investigated the expression of Glut-1 both in prostate cancer cell lines and clinical specimens of patients [10]. Poorly-differentiated cell lines (DU145 and PC3) showed higher Glut-1 expression compared with hormone-responsive cell line (LNCaP), and the same trend was also observed in moderately-poorly differentiated prostate cancer specimens, indicating that the level of Glut-1 expression increased with the advancing grade of malignancy. In the study of Liu, regarding clinical practice of FDG PET/CT in prostate cancer with high PAS levels, FDG PET/CT detected metastatic nodal and bone disease in five cases of the nine patients who underwent initial staging, and achieved the positive rate of 81% (13/16) for identifying metastases in patients with PSA relapse [11]. The consistent results of our study show that in 67 high risk prostate cancer patients, FDG PET/CT helped identify 28 patients with pelvic lymph node metastases and 31 patients with distant metastases.

Conventional imaging modalities such as CT, MRI, and BS, are commonly used to detect metastatic lesions; however, they were less sensi-

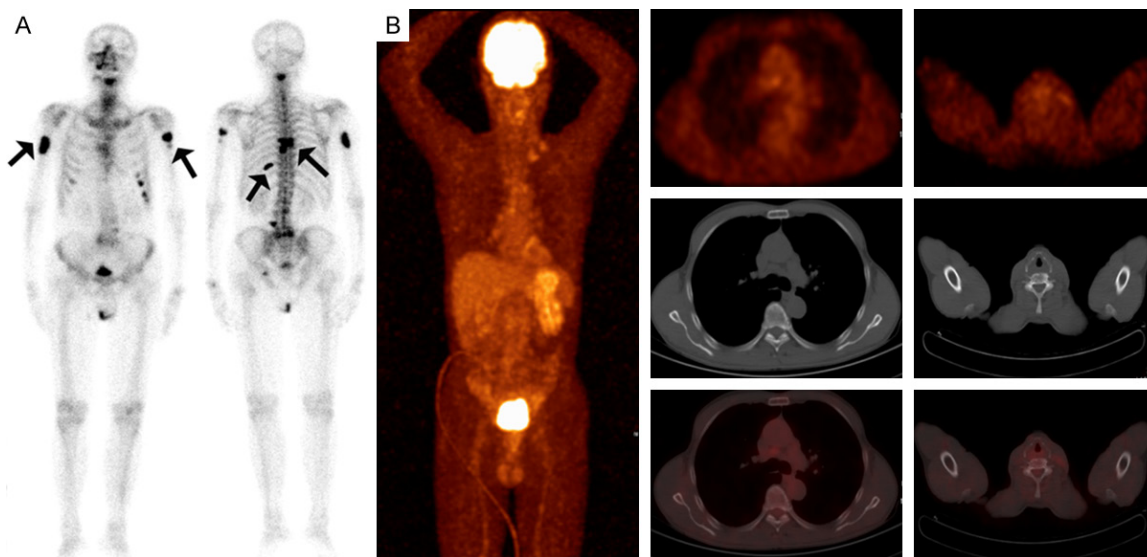


Figure 4. ^{99m}Tc -MDP bone scan showed multiple intense uptake in the skull, multiple vertebral bodies and ribs, bilateral humerus, and left acetabulum, which indicated extensive bone metastasis from prostate cancer (A) while these lesions were not detected on PET/CT (B).

tive than FDG PET/CT. For detection of pelvic lymph node metastases, a German study reported that FDG PET detected positive findings in 4/6 prostate cancer patients [19]. Similarly, Chang et al. found that the sensitivity and specificity of FDG PET/CT were 83.3% and 64.3% by patient-based analysis and 75% and 44.4% by lesion-based analysis, respectively [20]. With regard to identifying bone involvement, Minamimoto et al. prospectively evaluated the use of combined ^{18}F -NaF/ ^{18}F -FDG PET/CT in 15 patients with prostate cancer and compared the results with those for BS and MRI. ^{18}F -/ ^{18}F -FDG PET/CT had significantly higher sensitivity than MRI and BS in the evaluation of skeletal lesions (100%, 65.4% and 81.3%, respectively) [21]. Beaugregard et al. compared the performance of ^{18}F -choline PET/CT, ^{18}F -FDG PET/CT and conventional imaging (CT and BS) and assessed their impact on clinical management in patients with prostate cancer. They found that FDG PET/CT and choline PET/CT, nearly with the equal performance, had a higher detection rate than the combination of CT and BS for detecting malignant lesions (per-patient: 69% vs. 13%; per-lesion: 79% vs. 14%), in particular nodal disease and bone metastasis, and both PET/CT provided sufficient clinical information to form an appropriate management plan in 88% of cases, as compared with 56% for conventional imaging [22]. In our study, FDG PET/CT showed higher sensitivity than

DWI-MRI for detecting lymph node metastasis in high-risk prostate cancer patients (84.6% vs. 46.2%), identifying metastases in 5 patients that had negative presences on DWI-MRI for the reason that metastatic lymph nodes might have metabolic changes before morphologic change such as lesion size and shape. BS was less specific than FDG PET/CT mainly due to the false positive findings induced by occult fracture or degenerative change (80.0% vs. 92.0%).

In recent years, several novel radiotracers for PET imaging of prostate cancer have been used in preclinical and clinical practice, such as $^{18}\text{F}/^{11}\text{C}$ -acetate, $^{18}\text{F}/^{11}\text{C}$ -choline, ^{18}F -FACBC, and PSMA analogs. Although these innovative radiotracers will not only advance imaging evaluation of prostate cancer they also provide novel opportunities for cancer therapy since each of them has certain limitations in clinical application and practice [23-25]. As the only readily available PET tracer worldwide, the role of FDG PET/CT should not be ignored in specific phases of disease for certain subgroups of prostate cancer patients [26]. For high-risk prostate cancer, it is useful to evaluate the metastatic extent, especially the lymph nodes and bone involvement. Thus, in some areas that novel radiotracers such choline or acetate were not obtained, FDG PET/CT can be an alternative modality for patients with prostate cancer.

The study was retrospectively designed and the major limitation is enrollment bias. In our clinical practice, FDG PET/CT was not routinely performed for prostate cancer and only patients with a high probability of having metastatic lesions were referred for imaging evaluation using FDG PET/CT, which might lead to the high detection rate of metastatic lesions in our study. In addition, the reference standard of our study was the combination of histopathologic confirmation and/or clinical/imaging follow up, which might lead to a bias regarding the true diagnostic performance of FDG PET/CT in prostate cancer.

In conclusion, ¹⁸F-FDG PET/CT might be still useful for the detection of metastatic lesions, especially nodal and distant metastasis in patients with high risk prostate cancer. Compared to conventional imaging modalities including DWI-MRI and BS, FDG PET/CT has the advantage of detecting more metastatic or unexpected lesions by one scan. A prospective trial with larger sample size is needed to confirm the role of FDG PET/CT in high risk prostate cancer.

Acknowledgements

This study was supported by National Natural Science Foundation of China (Grant No. 81471692 and 81672547).

Disclosure of conflict of interest

None.

Address correspondence to: Rui Huang, Department of Nuclear Medicine, West China Hospital of Sichuan University, 37 Guoxue Alley, Chengdu 610041, China. Tel: +86-18980605781; E-mail: huangrui1977@163.com; Hao Zeng, Department of Urology, West China Hospital of Sichuan University, 37 Guoxue Alley, Chengdu 610041, China. E-mail: cdhx510@foxmail.com; kucaizeng@163.com

References

- [1] Siegel RL, Miller KD, Jemal A. Cancer statistics, 2016. *CA Cancer J Clin* 2016; 66: 7-30.
- [2] Jadvar H. Imaging evaluation of prostate cancer with 18F-fluorodeoxyglucose PET/CT: utility and limitations. *Eur J Nucl Med Mol Imaging* 2013; 40 Suppl 1: S5-10.
- [3] Jadvar H. Molecular imaging of prostate cancer: PET radiotracers. *AJR Am J Roentgenol* 2012; 199: 278-291.
- [4] Alavi A, Lakhani P, Mavi A, Kung JW, Zhuang H. PET: a revolution in medical imaging. *Radiol Clin North Am* 2004; 42: 983-1001, vii.
- [5] Liu IJ, Zafar MB, Lai YH, Segall GM, Terris MK. Fluorodeoxyglucose positron emission tomography studies in diagnosis and staging of clinically organ-confined prostate cancer. *Urology* 2001; 57: 108-111.
- [6] Salminen E, Hogg A, Binns D, Frydenberg M, Hicks R. Investigations with FDG-PET scanning in prostate cancer show limited value for clinical practice. *Acta Oncol* 2002; 41: 425-429.
- [7] Jadvar H, Desai B, Ji L, Conti PS, Dorff TB, Groshen SG, Pinski JK, Quinn DI. Baseline 18F-FDG PET/CT parameters as imaging biomarkers of overall survival in castrate-resistant metastatic prostate cancer. *J Nucl Med* 2013; 54: 1195-1201.
- [8] Chang CH, Wu HC, Tsai JJ, Shen YY, Changlai SP, Kao A. Detecting metastatic pelvic lymph nodes by 18F-2-deoxyglucose positron emission tomography in patients with prostate-specific antigen relapse after treatment for localized prostate cancer. *Urol Int* 2003; 70: 311-315.
- [9] Stewart GD, Gray K, Pennington CJ, Edwards DR, Riddick AC, Ross JA, Habib FK. Analysis of hypoxia-associated gene expression in prostate cancer: lysyl oxidase and glucose transporter-1 expression correlate with Gleason score. *Oncol Rep* 2008; 20: 1561-1567.
- [10] Effert P, Beniers AJ, Tamimi Y, Handt S, Jakse G. Expression of glucose transporter 1 (Glut-1) in cell lines and clinical specimens from human prostate adenocarcinoma. *Anticancer Res* 2004; 24: 3057-3063.
- [11] Liu Y. Diagnostic role of fluorodeoxyglucose positron emission tomography-computed tomography in prostate cancer. *Oncol Lett* 2014; 7: 2013-2018.
- [12] Beaugregard JM, Blouin AC, Fradet V, Caron A, Fradet Y, Lemay C, Lacombe L, Dujardin T, Tiguert R, Rimaq G, Bouchard F, Pouliot F. FDG-PET/CT for pre-operative staging and prognostic stratification of patients with high-grade prostate cancer at biopsy. *Cancer Imaging* 2015; 15: 2.
- [13] Pinaquy JB, De Clermont-Galleran H, Pasticier G, Rigou G, Alberti N, Hindie E, Mokrane Y, Fernandez P. Comparative effectiveness of [(18)F]-fluorocholine PET-CT and pelvic MRI with diffusion-weighted imaging for staging in patients with high-risk prostate cancer. *Prostate* 2015; 75: 323-331.
- [14] Mohler JL, Armstrong AJ, Bahnson RR, D'Amico AV, Davis BJ, Eastham JA, Enke CA, Farrington TA, Higano CS, Horwitz EM, Hurwitz M, Kane CJ, Kawachi MH, Kuettel M, Lee RJ, Meeks JJ, Penson DF, Plimack ER, Pow-Sang JM, Raben

FDG PET/CT in high risk prostate cancer

- D, Richey S, Roach M 3rd, Rosenfeld S, Schaefer E, Skolarus TA, Small EJ, Sonpavde G, Srinivas S, Strope SA, Tward J, Shead DA, Freedman-Cass DA. Prostate cancer, version 1.2016. *J Natl Compr Canc Netw* 2016; 14: 19-30.
- [15] Jadvar H, Xiankui L, Shahinian A, Park R, Tohme M, Pinski J, Conti PS. Glucose metabolism of human prostate cancer mouse xenografts. *Mol Imaging* 2005; 4: 91-97.
- [16] Kao PF, Chou YH, Lai CW. Diffuse FDG uptake in acute prostatitis. *Clin Nucl Med* 2008; 33: 308-310.
- [17] Jadvar H. Prostate cancer: PET with 18F-FDG, 18F- or 11C-acetate, and 18F- or 11C-choline. *J Nucl Med* 2011; 52: 81-89.
- [18] Hillner BE, Siegel BA, Shields AF, Liu D, Gareen IF, Hunt E, Coleman RE. Relationship between cancer type and impact of PET and PET/CT on intended management: findings of the national oncologic PET registry. *J Nucl Med* 2008; 49: 1928-1935.
- [19] Heicappell R, Muller-Mattheis V, Reinhardt M, Vosberg H, Gerharz CD, Muller-Gartner H, Ackermann R. Staging of pelvic lymph nodes in neoplasms of the bladder and prostate by positron emission tomography with 2-[(18)F]-2-deoxy-D-glucose. *Eur Urol* 1999; 36: 582-587.
- [20] Yi C, Yu D, Shi X, Zhang X, Luo G, He Q, Zhang X. The combination of 13N-ammonia and 18F-FDG whole-body PET/CT on the same day for diagnosis of advanced prostate cancer. *Nucl Med Commun* 2016; 37: 239-246.
- [21] Minamimoto R, Loening A, Jamali M, Barkhodari A, Mosci C, Jackson T, Obara P, Taviani V, Gambhir SS, Vasanawala S, Iagaru A. Prospective comparison of ^{99m}Tc-MDP scintigraphy, combined 18F-NaF and 18F-FDG PET/CT, and whole-body MRI in patients with breast and prostate cancer. *J Nucl Med* 2015; 56: 1862-1868.
- [22] Beauregard JM, Williams SG, Degrado TR, Roselt P, Hicks RJ. Pilot comparison of F-fluorocholine and F-fluorodeoxyglucose PET/CT with conventional imaging in prostate cancer. *J Med Imaging Radiat Oncol* 2010; 54: 325-332.
- [23] Lindenberg L, Choyke P, Dahut W. Prostate cancer imaging with novel PET tracers. *Curr Urol Rep* 2016; 17: 18.
- [24] Bjurlin MA, Rosenkrantz AB, Beltran LS, Raad RA, Taneja SS. Imaging and evaluation of patients with high-risk prostate cancer. *Nat Rev Urol* 2015; 12: 617-628.
- [25] Castellucci P, Jadvar H. PET/CT in prostate cancer: non-choline radiopharmaceuticals. *Q J Nucl Med Mol Imaging* 2012; 56: 367-374.
- [26] Jadvar H. Is there use for FDG-PET in prostate cancer? *Semin Nucl Med* 2016; 46: 502-506.