

## Case Report

# Metachronous metastasis to the right axillary lymph node and chest wall after curative gastrectomy in gastric adenocarcinoma: a case report

Hailong Jin<sup>1</sup>, Sabir Ahmad<sup>1</sup>, Hai Chen<sup>1</sup>, Xiaoqun Ba<sup>2</sup>, Qing Zhang<sup>1</sup>, Xiaosun Liu<sup>1</sup>, Jiren Yu<sup>1</sup>

Departments of <sup>1</sup>Gastrointestinal Surgery, <sup>2</sup>Pathology, The First Affiliated Hospital, Zhejiang University School of Medicine, Hangzhou, Zhejiang Province, China

Received January 4, 2018; Accepted July 2, 2018; Epub October 15, 2018; Published October 30, 2018

**Abstract:** A 44-year-old man underwent curative distal gastrectomy for advanced gastric cancer (T4aN3aM0, stage IIIC). Twenty-three months later, the patient complained of an asymptomatic right axillary mass, positron emission tomography using fluorine-18 fluorodeoxyglucose (FDG-PET) demonstrated multiple enlarged lymph nodes involving the right axillary, while no evidence of recurrent disease was found in the abdomen. The patient underwent radical axillary lymph node (ALN) dissection, and pathological examination demonstrated metastatic adenocarcinoma. Four months later, the patient had an erythematous lesion on the anterior aspect of the chest wall. Histopathologic analysis revealed atypical cells exhibiting in the dermis irregularly. Cutaneous metastasis was diagnosed. The patient was treated with second-line chemotherapy and target therapy sequentially. However, the patient died eight months later. Taken together, this is the first case documenting axillary lymph node metastasis (ALNM) and cutaneous metastasis in a gastric adenocarcinoma. In order to achieve good prognosis, early detection is very important.

**Keywords:** Gastric cancer, adenocarcinoma, axillary lymph node metastasis, cutaneous metastasis

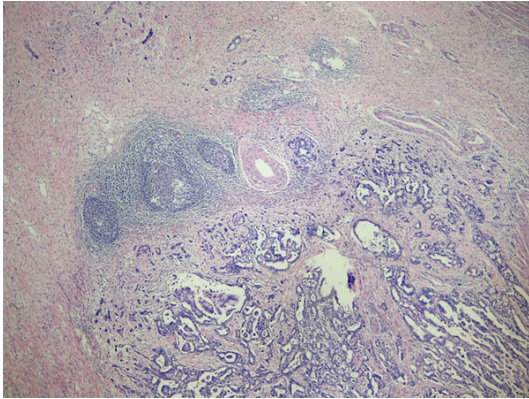
## Introduction

Patterns of metastasis in gastric cancer have been extensively reported, namely direct extension, lymphatic spread, and vascular dissemination. Liver, peritoneal cavity, and regional lymph nodes are the most commonly locations for gastric cancer metastases [1]. Axillary lymph node metastasis (ALNM) or cutaneous metastasis from internal occult neoplasms, especially gastric cancer, is rare [2-5]. The present report is the first to document a recurrent case of gastric adenocarcinoma presenting with ALNM and cutaneous metastasis.

## Case report

A 44-year-old man with upper abdominal discomfort accompanying with vomiting and melena was admitted to our department on July 2012. Computed Tomography (CT) and Magnetic Resonance Imaging (MRI) showed an advanced stage of gastric cancer with pyloric obstruction and celiac trunk lymph node

enlargement. Pathology examination confirmed moderately differentiated adenocarcinoma in a biopsy specimen through endoscopy. He had neither distant metastasis nor an elevated level of serum tumor markers, including carcinoembryonic antigen (CEA) and carbohydrate antigen (CA) 19-9. A nasal jejunum tube was implanted through endoscopy for nutrition support and he was treated with three cycles of fluorouracil, leukovorin, and oxaliplatin in a neoadjuvant intention. Curative distal gastrectomy with D2 lymphadenectomy was performed in October 2012. Resected specimen showed an ulcerative lesion, 3×2 cm in size, located in the lower third portion, moderately differentiated adenocarcinoma with lymphovascular invasion (**Figure 1**). The postoperative tumor stage was ypT4a, ypN3a with 10 of 38 positive lymph node metastasis, and pM0. The patient received 3 adjuvant cycles of fluorouracil, leukovorin, and oxaliplatin until January 2013. CT scans were without evidence of recurrence or residual disease in May 2013.



**Figure 1.** Histological findings of the primary lesion: moderately differentiated adenocarcinoma with lymphovascular invasion. (H&E, 40 $\times$ ).

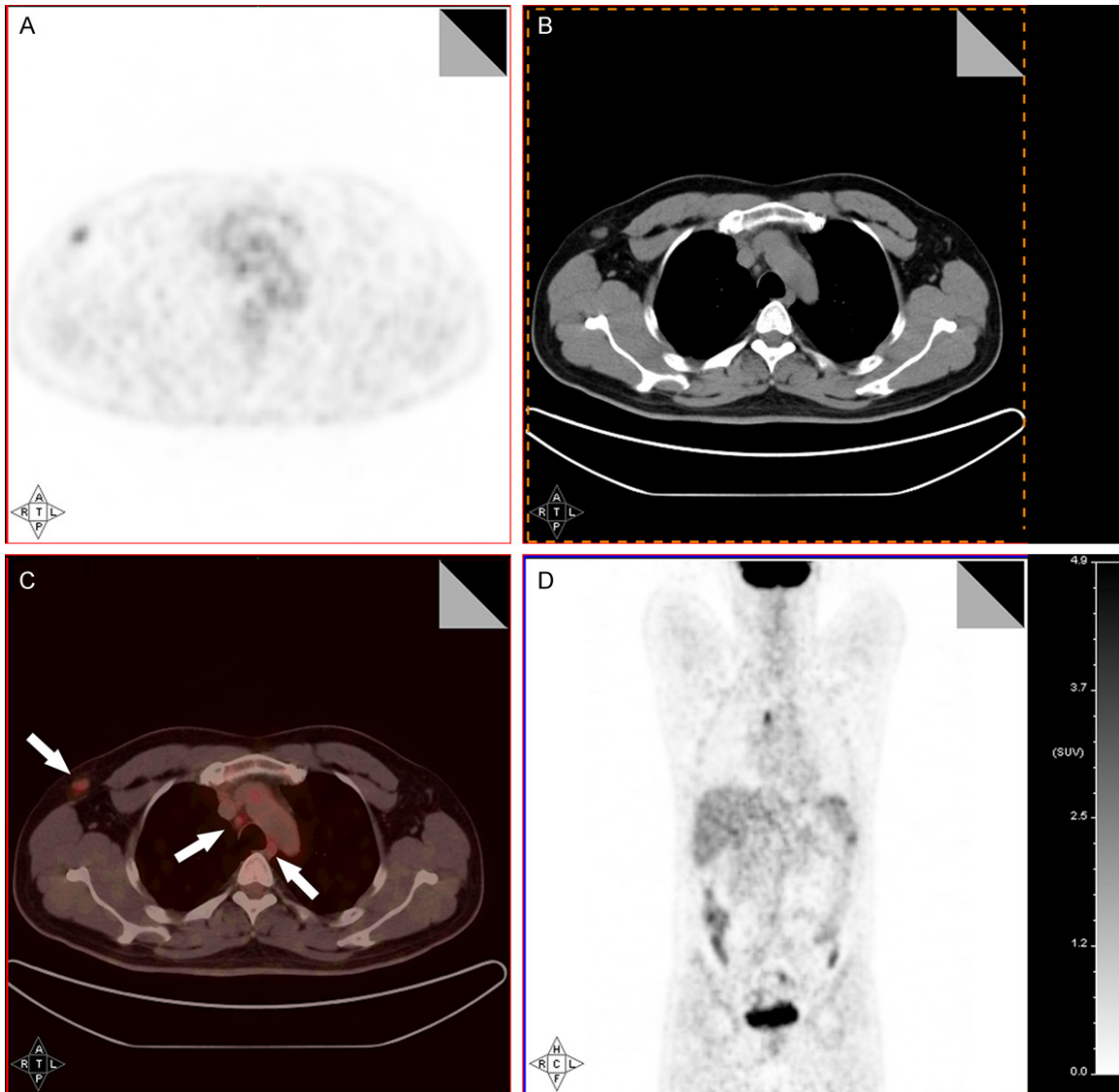
In September 2014, the patient complained of an asymptomatic right axillary mass. CT scans and ultrasonography examination demonstrated multiple enlarged lymph nodes involving the right axillary and mediastinum, while no other tumors were found by enhanced CT of the abdomen and positron emission tomography using fluorine-18 fluorodeoxyglucose (FDG-PET) (**Figure 2**). CA19-9 was increased (290.3 U/ml), and CEA was normal. The patient underwent radical axillary lymph node dissection in October 2014, the tumor was 2 cm in diameter, oval and elastic hard, and showed no invasion to the adjacent structures. Pathological examination demonstrated metastatic adenocarcinoma in two of three dissected lymph nodes (**Figure 3A, 3B**). Immunohistochemistry examination showed a positive reaction with cytokeratin (CK)-19, focal positive reaction with CK-20, caudal type homeo box 2 protein (CDX-2) and a negative reaction with prostate specific antigen (PSA) and thyroid transcription factor 1 (TTF-1) (**Figure 3C-G**). On the basis of these clinical and histological findings, axillary lymph node metastasis (ALNM) from gastric cancer was diagnosed. Subsequently, the patient was treated with 3 cycles of fluorouracil, leukovorin, and oxaliplatin in our Department until January 2015. Repeated CT scans revealed multiple enlarged lymph node involving the right axillary and mediastinum.

Meanwhile, the patient declared an erythematous lesion on the anterior aspect of the chest wall and upper central quadrant of the abdominal of 1 month duration (**Figure 4A**). He denied any history of allergies. The lesion was painless

and a mild itching. Physical examination revealed a 3 $\times$ 2 cm erythematous lesion with a clear boundary, accompanying with scattered pimples and blisters. Biopsy was conducted and the histopathologic analysis revealed atypical cells exhibiting in the dermis irregularly with pseudoglandular pattern (**Figure 4B**). Since curative resection was not possible, the patient refused excisional biopsy for further immunohistochemistry. Combined with tumor history, image and histological findings, cutaneous metastasis of gastric carcinoma was diagnosed. CA19-9 showed an additional increased (290.5 U/ml), and CEA remained normal. The enhanced CT of abdomen revealed no evidence of recurrent disease. Following this, the patient underwent another 3 cycles of palliative chemotherapy with paclitaxel and oral TS-1 (tegafur, gimeracil, oteracil potassium) until March 2015. Repeated CT scans demonstrated multiple enlarged lymph node including bilateral axillary, mediastinum, and hilum of right lung, as well as cutaneous nodule on the anterior chest wall. CA19-9 increased to 520.2 U/ml, while CEA remained normal. However, there was no evidence of recurrence or metastases of the abdomen. Due to the patient suffering from a progressive disease, he was treated with an oral targeted chemotherapeutics (Apatinib, a tyrosine kinase inhibitor that selectively inhibits the vascular endothelial growth factor receptor-2 (VEGFR2)) from April 2015. Five months after treatment of oral targeted chemotherapeutic plus best supportive care (BST), repeated CT scans showed multiple enlarged lymph node involving bilateral axillary, mediastinum, while there was still no evidence of recurrence or metastases of the abdomen. Ultimately, the patient died on September 2015 due to infection of the cutaneous metastasis and dyscrasia cause by tumor progressed.

### Discussion

This is the first case of a gastric adenocarcinoma presenting with ALNM and cutaneous metastasis. The mechanism of metastasis to axillary lymph node has been reported in bronchogenic and ovarian carcinoma [6-8]. Three hypothetical metastatic routes were documented. The first was that tumor spread through a newly developed lymphatic channels which arise in pleural adhesions to the chest wall of bronchogenic cancer, because lymphatic drain-



**Figure 2.** Positron emission tomography using fluorine-18 fluorodeoxyglucose (FDG-PET) showed that the intensity of FDG-uptake in multiple lymph node involving right axillary and mediastinum was increased (arrow, A-D).

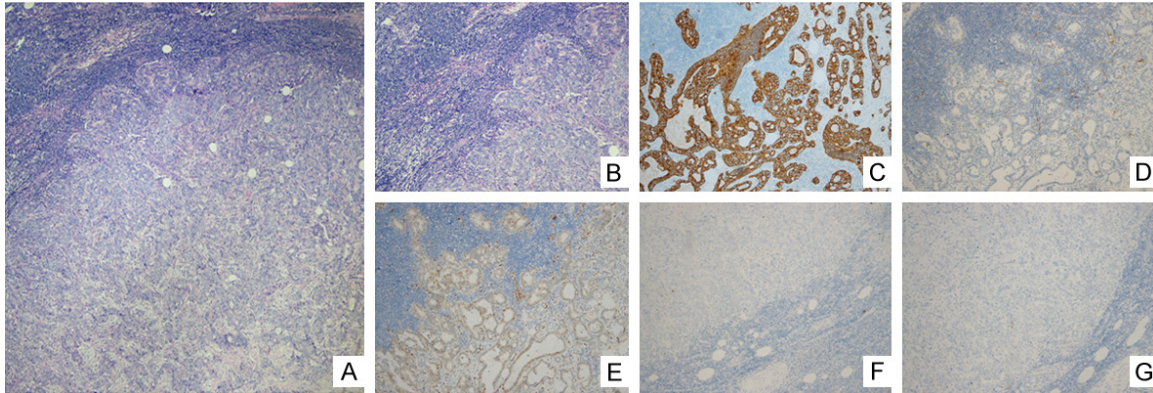
age to the axillary lymph node was from subcutaneous or intercostal lymphatic vessels in the chest wall. The second was a retrograde spread mechanism which referred to the presence of supraclavicular lymph node metastasis (SCLNM). While the left supraclavicular, Virchow's, lymph node is frequently involved in gastrointestinal cancer [9]. Marcantonio and Libshitz reported retrograde of axillary lymph node from the ipsilateral supraclavicular nodes was observed in 2% of 200 consecutive lymphangiograms and this type of spread could occur only when the valvar competence of lymphatic vessels was lost. A third hypothesis was that ALNMs could be of systemic origin, which

could be cause by lymphovascular invasion of the primary tumor and also by the tumor cells disseminating into the venous system. In the present patient, the most likely mechanism for ALNM was systemic origin, because the primary tumor showed lymphovascular invasion, as well as the recurrence presented only at the axillary without SCLNM.

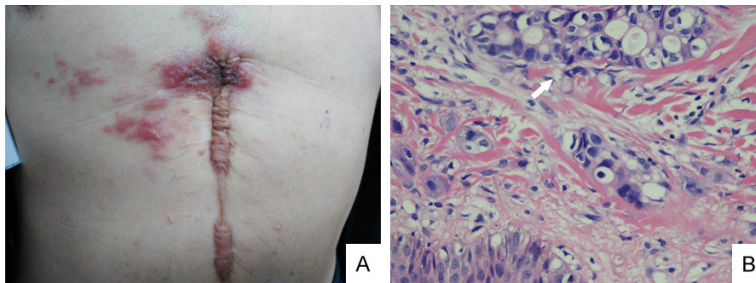
In our patient, cutaneous metastasis was detected 2 months after dissection of ALNM. The most common internal neoplasms leading to cutaneous metastasis are breast cancer, lung cancer, and colorectal cancer [10]. A typical location of gastric cancer cutaneous metas-



## Axillary lymph node and cutaneous metastasis from gastric cancer



**Figure 3.** (A, B) Histological findings of the metastatic axillary lymph node (H&E, A: 40 $\times$ , B: 100 $\times$ ). Immunohistochemical examination showed that the cells were positive for cytokeratin (CK)-19 (C), focal positive for CK-20 (D) and caudal type homeo box 2 protein (CDX-2) (E) but negative for prostate specific antigen (PSA) (F) and thyroid transcription factor 1 (TTF-1) (G) (C-G: 100 $\times$ ).



**Figure 4.** Cutaneous metastasis located on the anterior aspect of the chest and abdominal wall (A). Atypical cells exhibiting in the dermis with pseudoglandular pattern (arrow, B). (H&E, 400 $\times$ ).

tasis is the umbilical area (Sister Mary Joseph's nodule) [11] and rarely as an erythematous lesion arising from the chest wall as seen in our patient. Several mechanisms are responsible for cutaneous metastasis, including direct invasion, iatrogenic implantation, and lymphatic or hematogenous routes. Paget [12] first described the "soil and seed" hypothesis, whereby it seemed that interaction between tumor cells and chemokine secreted from the dermis or epidermis plays a crucial role in the skin involvement of metastatic cells [13].

The prognosis of recurrent and metastatic gastric cancer is poor. Nevertheless, improvement in metastatic gastric adenocarcinoma has been reported with some strategies [14, 15]. Generally this includes local excision, irradiation, or systemic chemotherapy. In our patient, radical resection of axillary lymph node with sequential systemic chemotherapy was conducted following development of ALNM. However, successive recurrence occurred, and

the patient was unable to receive curative resection of cutaneous metastasis, so combination chemotherapy and targeted therapy were conducted. Unfortunately, the patient died due to infection of the cutaneous metastasis and dyscrasia.

In conclusion, this is a very uncommon pattern of gastric metastatic tumor, as ALNM and cutaneous metastasis observed metachronous in one patient is very rare. However, there was no evidence of recurrence or metastases in the abdomen even when the patient died. In order to achieve good prognosis, treatment combined with chemotherapy and either operation or radiotherapy is needed, and early detection is very important.

### Acknowledgements

This work was supported by the grant of Zhejiang Science and Technology Program Key Projects (2014C03040-1) and Application of Public Welfare Technology of Zhejiang Province (2015C33174). The authors would like to thank Kui Zhao in the Department of Nuclear Medicine for collecting of images, and Hong Fang in the Department of Dermatology for biopsy of cutaneous metastasis in our hospital.

### Disclosure of conflict of interest

None.

## Axillary lymph node and cutaneous metastasis from gastric cancer

**Address correspondence to:** Dr. Jiren Yu, Department of Gastrointestinal Surgery, The First Affiliated Hospital, Zhejiang University School of Medicine, 79 Qingchun Road, Hangzhou 310003, Zhejiang Province, China. Tel: 0086-0571-87236-147; Fax: 0086-571-87072577; E-mail: yujr0909@zju.edu.cn

### References

- [1] Esaki Y, Hirayama R and Hirokawa K. A comparison of patterns of metastasis in gastric cancer by histologic type and age. *Cancer* 1990; 65: 2086-2090.
- [2] Kobayashi O, Sugiyama Y, Konishi K, Kanari M, Cho H, Tsuburaya A, Sairenji M, Motohashi H and Yoshikawa T. Solitary metastasis to the left axillary lymph node after curative gastrectomy in gastric cancer. *Gastric Cancer* 2002; 5: 173-176.
- [3] Ghanekar A and Himal HS. Carcinoma of the stomach: an unusual pattern of metastasis. *Can J Surg* 1997; 40: 392.
- [4] Schulmann K, Strate K, Pox CP, Wieland U and Kreuter A. Paraneoplastic acanthosis nigricans with cutaneous and mucosal papillomatosis preceding recurrence of a gastric adenocarcinoma. *J Clin Oncol* 2012; 30: e325-326.
- [5] Cesaretti M, Malerba M, Basso V, Boccardo C, Santoni R, D'Alessandro G, Weiss A, Campisi C and De Cian F. Cutaneous metastasis from primary gastric cancer: a case report and review of the literature. *Cutis* 2014; 93: E9-E13.
- [6] Marcantonio DR and Libshitz HI. Axillary lymph node metastases of bronchogenic carcinoma. *Cancer* 1995; 76: 803-806.
- [7] Riquet M, Le Pimpec-Barthes F and Danel C. Axillary lymph node metastases from bronchogenic carcinoma. *Ann Thorac Surg* 1998; 66: 920-922.
- [8] Hockstein S, Keh P, Lurain JR and Fishman DA. Ovarian carcinoma initially presenting as metastatic axillary lymphadenopathy. *Gynecol Oncol* 1997; 65: 543-547.
- [9] Negus D, Edwards JM and Kinmonth JB. Filling of cervical and mediastinal nodes from the thoracic duct and the physiology of Virchow's node--studies by lymphography. *Br J Surg* 1970; 57: 267-271.
- [10] Hu SC, Chen GS, Lu YW, Wu CS and Lan CC. Cutaneous metastases from different internal malignancies: a clinical and prognostic appraisal. *J Eur Acad Dermatol Venereol* 2008; 22: 735-740.
- [11] Li F, Yu J and Yang Z. Sister Mary Joseph's nodule originating from primary duodenal adenocarcinoma. *Am J Med Sci* 2012; 344: 40.
- [12] Paget S. The distribution of secondary growths in cancer of the breast. 1889. *Cancer Metastasis Rev* 1989; 8: 98-101.
- [13] Kakinuma T and Hwang ST. Chemokines, chemokine receptors, and cancer metastasis. *J Leukoc Biol* 2006; 79: 639-651.
- [14] Shah MA, Janjigian YY, Stoller R, Shibata S, Kemeny M, Krishnamurthi S, Su YB, Ocean A, Capanu M, Mehrotra B, Ritch P, Henderson C and Kelsen DP. Randomized multicenter phase II study of modified docetaxel, cisplatin, and fluorouracil (DCF) versus DCF plus growth factor support in patients with metastatic gastric adenocarcinoma: a study of the US gastric cancer consortium. *J Clin Oncol* 2015; 33: 3874-3879.
- [15] Li J, Qin S, Xu J, Xiong J, Wu C, Bai Y, Liu W, Tong J, Liu Y, Xu R, Wang Z, Wang Q, Ouyang X, Yang Y, Ba Y, Liang J, Lin X, Luo D, Zheng R, Wang X, Sun G, Wang L, Zheng L, Guo H, Wu J, Xu N, Yang J, Zhang H, Cheng Y, Wang N, Chen L, Fan Z, Sun P and Yu H. Randomized, double-blind, placebo-controlled phase III trial of apatinib in patients with chemotherapy-refractory advanced or metastatic adenocarcinoma of the stomach or gastroesophageal junction. *J Clin Oncol* 2016; 34: 1448-1454.