

Review Article

Molecular markers prognosticate the aggressiveness of papillary thyroid cancer

Shuang-Shuang Zhao, Bao-Ding Chen, Zheng Zhang

Department of Medical Ultrasound, Affiliated Hospital of Jiangsu University, Zhenjiang 212001, China

Received January 18, 2018; Accepted October 12, 2018; Epub March 15, 2019; Published March 30, 2019

Abstract: Application of molecular markers in diagnosing and prognosticating thyroid cancer is of high clinical significance. These include BRAF^{V600E}, TERT and RAS mutations, PAX8/PPAR γ rearrangement, and gene expression classifier (GEC). Molecular pathogenesis of thyroid cancer has been accepted, gradually, by the elucidation of the fundamental roles of several major signaling pathways and related molecular derangements. Although most papillary thyroid cancers (PTC) occupy higher TNM stages, 10-year overall survival rates have remained high. It seems that prognosticating the aggressiveness of PTC has more weight in diagnosis. However, to date, there is no unanimous consensus regarding prognosticating the aggressiveness of PTC using molecular markers. The present review aimed to illuminate the performance of molecular markers in predicting the aggressiveness of PTC, providing unprecedented opportunities for further research and clinical development of novel treatment strategies for this cancer.

Keywords: Aggressiveness, prognosticate, thyroid cancer, papillary, molecular

Introduction

Thyroid cancer (TC) is the most common endocrine malignancy worldwide, accounting for more than 95% of all endocrine malignancies [1]. The majority (> 90%) of TC are well differentiated thyroid cancer (DTC), consisting of papillary thyroid cancer (PTC) (> 80%) and follicular thyroid cancer (FTC) [2]. Approximately half of these patients have cervical lymph node metastasis (CLNM), with > 90% having occult micro-metastasis in lymph nodes [3]. According to the American Joint Committee on Cancer (AJCC) TNM staging system, the presence of lymph node metastasis (LNM) results in upstaging. However, the 10-year overall survival rate of PTC remains > 90%. Although PTC has a relatively slow growth rate and a high percentage of cure, achieved by the combination of surgery, radioiodine ablation, and TSH-suppressive therapy, it still retains the risk of recurrence and metastasis. The concept of molecular classification of cancer at a clinically relevant level has been accepted as an imminent reality.

Fine-needle aspiration (FNA) biopsies and cytological assessment have been a cornerstone of thyroid nodule management since the 1980's

[4]. This basic preoperative assessment has substantially reduced the number of diagnostic surgeries. In 15% to 30% of thyroid FNAs, the cytologic results are indeterminate, including atypia of undetermined significance/follicular lesions of undetermined significance (AUS/FLUS) and follicular neoplasm/suspicious for follicular neoplasms (FN/SFN), creating a dilemma for the clinical management of these patients [5]. The 2017 Bethesda System for Reporting Thyroid Cytopathology (TBSRTC) reaffirmed that every thyroid FNA report should begin with 1 of 6 diagnostic categories, the names of which have remain unchanged. The revised risks of malignancy are 10-30% in AUS/FLUS, 25-40% in FN/SFN, 50-75% in suspicious for malignancy (SFM), 97-99% in malignancy, and if non-invasive follicular thyroid neoplasms with papillary-like nuclear features (NIFTP) are considered a malignancy. Otherwise, the risks of malignancy are 6-18%, 10-40%, 45-60%, and 94-96%, respectively. In addition, the revised TBSRTC has recommended that the "usual management" of AUS/FLUS and FN/SFN incorporates the option of molecular testing [6]. Malignant nodules can be diagnosed using the categories of the TBSRTC, while invasive clini-

Molecular markers prognosticate PTC aggressiveness

Table 1. Summary of studies regarding diagnostic molecular markers on thyroid FNA specimens

Authors	Year	N*	Malignant† (%)	Markers	Sensitivity (%)	NPV (%)	Specificity (%)	PPV (%)
Faroux et al.	1997	69	13	A	89	97	58	24
Umbricht et al.	2004	100	48	B	90	87	65	70
Saggiorato et al.	2005	125	60	C	100	100	82	78
Nikiforov et al.	2009	52	40	D	71	84	100	100
Samija et al.	2011	142	20	E	79	91	53	28
Fadda et al.	2011	119	45	F	89	85	64	71
Nikiforov et al.	2011	513	24	G	61	89	98	89
Shen et al.	2012	68	65	H	89	79	79	89
Keutgen et al.	2012	72	31	I	100	100	86	73
Rossi et al.	2012	123	36	J	32	73	100	100
Alexander et al.	2012	265	32	K	92	93	52	47
Nikiforov et al.	2014	143	24	L	90	96	93	83
Labourier et al.	2015	109	32	M	89	94	85	74
Lithwick-Yanai et al.	2017	150	26	N	98	99	78	62

FNA = fine needle aspiration; NPV = negative predictive value; PPV = positive predictive value; A = TPO immunocytochemistry; B = human telomerase mRNA; C = galectin 3 plus KRT19 plus HBME-1 immunocytochemistry; D = BRAF and RAS mutations, RET-PTC and PAX8-PPAR rearrangements; E = galectin 3 mRNA RT-PCR; F = galectin 3 plus HBME-1 immunocytochemistry; G = BRAF and RAS mutations, RET-PTC and PAX8-PPAR rearrangements; H = four microRNA set (miR-30d, miR-146b, miR-187, miR-221) linear discrimination analysis; I = four microRNA set (miR-21, miR-197, miR-222, miR-328) support vector machine radial basis kernel model; J = BRAF^{V600E} mutation; K = gene expression classifier (the expression of 167 genes); L = ThyroSeq v2 (point mutations in 13 genes and for 42 types of gene fusions); M = ThyGenX/ThyraMIR; N = RosettaGX Revea; *Number of indeterminate FNAB with histopathology correlation; †Percentage malignancy among indeterminate FNAB nooules.

cal pathological characteristics of malignant nodules cannot be predicted. The aggressive clinical pathological characteristics of TC include LNM, extrathyroidal extension (ETE), and loss of radioiodine avidity. Hence, failure of radioiodine treatment and disease recurrence is common. Therefore, molecular testing plays a critical role in evaluation of thyroid nodules with indeterminate FNA results. Several studies have assessed the usefulness of different molecular markers for thyroid nodules with pre-operative indeterminate FNA cytology. The performance of molecular markers in predicting the aggressiveness of PTC has not been illuminated yet. The present study aimed to examine the contribution of molecular markers (BRAF^{V600E} mutation, TERT promoter mutations, RAS mutation, PAX8/PPAR γ rearrangement) in predicting the aggressiveness of PTC, providing unprecedented opportunities for further research and clinical development of novel treatment strategies for this cancer.

Molecular markers diagnosing thyroid cancer

FNA is recommended for thyroid nodules which have suspicious ultrasound (US) signs, according to medical guidelines for clinical practice for the diagnosis and management of thyroid nodules updated by American Association of Cli-

nical Endocrinologists (AACE), American College of Endocrinology (ACE), and Associazione Medici Endocrinologi (AME) in 2016 [7]. Diagnostic surgery (lobectomy or total thyroidectomy) is often performed to confirm whether a thyroid nodule is benign or malignant, whereas therapeutic surgery is performed to decrease the risk of cancer recurrence and mortality.

The accumulation of knowledge on diagnostic use of molecular markers has been reflected in the 2015 American Thyroid Association guidelines [8]. The great difficulty for more than 20 years has been to identify suitable molecular markers to guide surgery. At present, except for BRAF^{V600E} mutation, TERT promoter mutations, RAS mutation, and PAX8/PPAR γ rearrangement, there are various molecular markers which can be used to improve the performance of FNA for patients that have indeterminate thyroid FNA results, reducing unnecessary surgeries (Table 1, [9-22]). The present review focused on large studies assessing molecular markers in FNA specimens with indeterminate cytological results. Sensitivity, specificity, positive predictive value (PPV), and negative predictive value (NPV) were used as uniform statistical measures. Molecular markers with high sensitivity and NPV were considered to be 'rule-out' tests, including immunocytochemis-

Molecular markers prognosticate PTC aggressiveness

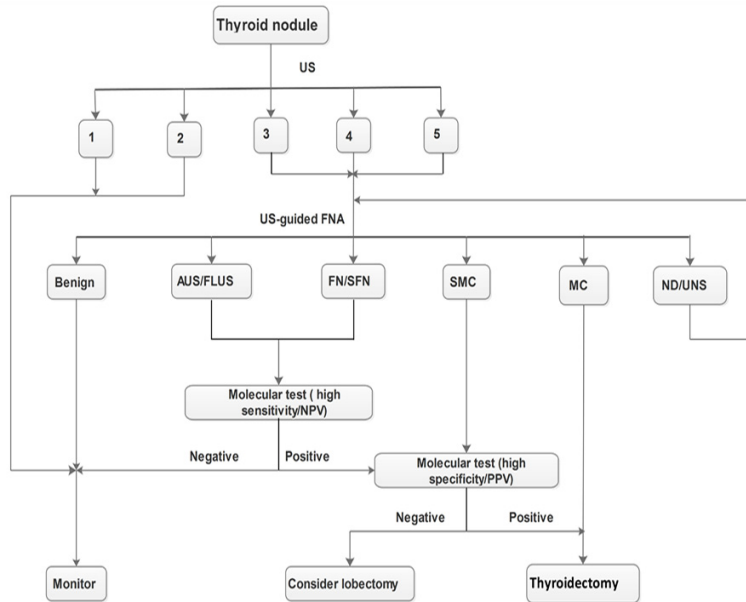


Figure 1. Algorithm for management of thyroid nodules based on US examination, FNA cytology, and molecular marker tests. US = Ultrasound; FNA = Fine-needle aspiration; AUS = Atypia of Undetermined Significance; FLUS = Follicular Lesion of Undetermined Significance; FN = Follicular Neoplasm; SFN = Suspicious for a Follicular Neoplasm; SMC = Suspicious for a Malignant Carcinoma; MC = Malignant Carcinoma; ND = Nondiagnostic; UNS = Unsatisfactory; NPV = Negative Predictive Value; PPV = Positive Predictive Value.

try combinations of protein markers, a set of four microRNAs, a complex gene expression classifier (GEC) (Afirma), a panel consisting of point mutations in 13 genes and for 42 types of gene fusions (ThyroSeq v2), two molecular tests for miRNA, mRNA, and DNA (ThyGenX/ThyraMIR), and a microRNA-based assay using quantitative RT-PCR (RosettaGX Revea). Molecular markers with high specificity and PPV were considered to be 'rule-in' tests, including genetic markers (mutations and rearrangements) which are believed to be the drivers behind many of the thyroid cancers [23]. Overall malignancy rates in these studies ranged from 13% to 65%. A panel of genetic markers, including BRAF^{V600E} mutation, TERT promoter mutations, RAS mutation, and PAX8/PPAR γ rearrangement, in a single-center unblinded study, yielded increased diagnostic sensitivities for TC to 88% for AUS and 87% for FN [15].

An algorithm was suggested, in this review, that incorporates US examination, cytology diagnosis, and molecular testing in the management of patients with thyroid nodules (Figure 1). The aim is to limit unnecessary surgery, to

perform the least aggressive surgery achieving diagnostic or therapeutic goals, and to make the first surgery the last surgery. First, every patient with thyroid nodules should undergo US examinations. Every nodule needs to be assessed using the thyroid imaging reporting and data system (TIRADS) [24]. Nodules classified as TIRADS 1 or 2 with very low probability of malignancy should be monitored. Those defined as TIRADS 3, 4, or 5 should undergo ultrasound-guided (US-guided) FNA for cytological assessment. Afterward, molecular testing should be performed on the nodules with indeterminate FNA results, according to the TBSRTC. Nodules with indeterminate FNA cytology should be considered for molecular testing with high sensitivity and NPV (GEC). Those with negative results should be monitored without surgery as benign results. Otherwise, they should undergo the other molecular testing with high specificity and PPV (BRAF mutation). Nodules that are suspicious for malignancy should undergo the latter molecular testing. If they have the negative results, they should undergo a lobectomy. Positive results and PTC should undergo a thyroidectomy.

without surgery as benign results. Otherwise, they should undergo the other molecular testing with high specificity and PPV (BRAF mutation). Nodules that are suspicious for malignancy should undergo the latter molecular testing. If they have the negative results, they should undergo a lobectomy. Positive results and PTC should undergo a thyroidectomy.

Molecular markers prognosticating papillary thyroid cancer

BRAF-gene mutation and PTC aggressiveness

BRAF-gene mutation is one of the most common mutations in PTC. It has been illuminated consistently. The aggressive roles of BRAF mutation in PTC can be explained by several molecular mechanisms, including its aberrant regulation of various signaling pathways, such as the MAP kinase pathway, NF κ B pathway, and RASSF1A pathway, upregulation of various oncogenic molecules, and downregulation of various tumor suppressor genes [25]. BRAF is a serine-threonine kinase belonging to the family of RAF proteins, which are intracellular effec-

Molecular markers prognosticate PTC aggressiveness

Table 2. Summary of studies regarding BRAF-gene mutations in prognosticating PTC aggressiveness

Authors	Year	Country	N*	Mutation frequency (%)	Significant associations	Effect size
Xing	2007	USA	3028 (meta-analysis; 28 studies)	50.0	A; B; C; D	Odds ratio
Li et al.	2012	USA	6372 (meta-analysis; 32 studies)	50.9	B; C; D; E; F; G; H	Odds ratio
Liu et al.	2014	China	14,170 (meta-analysis; 69 studies)	56.3	A; B; C; D; E	Odds ratio
Li et al.	2015	China	3,437 (meta-analysis; 19 studies)	47.5	B; C; D; E	Odds ratio
Zhang et al.	2016	China	25241 (meta-analysis; 81 studies)	60.6	A; B; C; D; E; I	Odds ratio
Liu et al.	2016	China	20764 (meta-analysis; 63 studies)	57.6	A; B; C; D	Odds ratio

A = recurrence/persistence; B = lymph node metastasis; C = extrathyroidal extension (ETE); D = higher TNM stage; E = multifocality; F = absence of capsule; G = more aggressive histology subtype; H = tumor size; I = vascular invasion; *Number of patients with histopathology results.

tors of the MAPK signaling cascade. Their activation is triggered by RAS binding and protein recruitment to the cell membrane, followed by phosphorylation and activation of downstream targets along the MAPK cascade [26]. BRAF mutation leads to constitutive activation of BRAF kinase and chronic stimulation of the MAPK pathway. It is tumorigenic for thyroid cells [27]. BRAF mutation also uniquely down-regulates thyroid iodide-metabolizing genes, such as sodium-iodide symporter (NIS) [25]. NIS explains the initial finding of the association of BRAF^{V600E} mutation with the loss of radioiodine avidity, leading to radioiodine treatment failure in PTC [28].

BRAF^{V600E}, the most common oncogene in PTC, with a higher specificity and absence in benign thyroid nodules, has been reported to have a role of prognosticating the aggressiveness of PTC. BRAF^{V600E} mutation has been widely studied in TC and has been considered to have a significant association with aggressive biologic behavior. Garcilaso Riesco-Eizaguirre et al. suggested that BRAF^{V600E} mutation in PTC can promote epithelial to mesenchymal transition. Aggressiveness based on the operation of an autocrine transforming growth factor (TGF) β loop, which leads to repressing the function of NIS and subsequent radioiodide-refractory metastatic, can also be increased. This high TGF β /Smad activity has been associated with PTC invasion, nodal metastasis, and BRAF^{V600E} status disease [28]. A retrospective investiga-

tion of 1,849 patients and a study of 653 patients revealed that BRAF^{V600E} promotes aggressive tumor behaviors, such as LNM, tumor invasion, and distant metastasis. It silences thyroid iodide-metabolizing genes and renders the tumor resistant to radioiodine treatment. It also expedites tumor progression, resulting in aggravated risk of PTC-related mortality [29, 30]. It is worth noting that even in conventionally low-risk TNM stage disease and papillary thyroid microcarcinoma (PTMC), BRAF^{V600E} mutation still has a significant association with recurrence. This has been confirmed in a smaller study [31].

In **Table 2** [32-37], six large meta-analyses were collected to analyze significant associations of BRAF^{V600E} mutation in PTC. The prevalence of this mutation ranged from 47.5% to 60.6% in **Table 2**. According to these analyses, many risk factors were found to be associated with BRAF^{V600E} mutation, including recurrence/persistence, LNM, ETE, higher TNM stage, multifocality, absence of capsule, more aggressive histology subtype, tumor size, and vascular invasion. However, there was no significant association between the presence of BRAF^{V600E} mutation and distant metastasis in all six meta-analyses. It was further confirmed that LNM, ETE, and higher TNM stage were significantly associated with BRAF^{V600E} mutation, depending on the meta-analyses. It is not known why different incidences of BRAF^{V600E} mutation were reported among different studies. It may

Molecular markers prognosticate PTC aggressiveness

Table 3. Summary of studies regarding TERT promoter mutations in prognosticating PTC aggressiveness

Authors	Year	Country	N*	Mutation frequency (%)	Significant associations	Effect size
Liu et al.	2013	Sweden	51	25.5	B	<i>P</i> -value
Melo et al.	2014	Portugal	284	7.5	B; C; D; F; G; H; I	<i>P</i> -value
Liu et al.	2014	China	408	11.3	C; D; F	<i>P</i> -value
Xing et al.	2014	USA	507	12.0	A; B; C; D; G; H	Hazard ratio
Qasem et al.	2015	Arabia	256	7.0	A; B; C; D; F; G; H	<i>P</i> -value
De Biase et al.	2015	Italy	288	4.7	A; B; D; I	<i>P</i> -value
Bae et al.	2016	Korea	222	5.4	B; C; D; F; H	<i>P</i> -value
Jin et al.	2016	Korea	653	4.1	B; C; D; E; F	<i>P</i> -value

A = recurrence/persistence; B = lymph node metastasis; C = extrathyroidal extension (ETE); D = higher TNM stage; E = capsule invasion; F=tumor size; G = vascular invasion; H=distant metastasis; I = BRAF^{V600E} mutation; *Number of patients with histopathology results.

be associated with the different methods, races, and areas.

TERT promoter mutations and PTC aggressiveness

Two mutations (C228T and C250T) in the promoter region of the telomerase reverse transcriptase (TERT) have recently been described in different types of cancer. They were first described in thyroid cancer in 2013 [38]. Cells develop mechanisms that protect the telomere length from excessive shortening with each cell division to overcome the Hayflick limit and become immortal [39]. Telomeres are mostly maintained by TERT, alternative mechanisms independent of telomerase that are sometimes utilized for telomere lengthening [40]. Telomerase, itself, is a nucleoprotein complex with many proteins and RNA. Normal cells and benign adenomas rarely have increased expression of telomerase, but self-renewing cells, such as stem and fetal cells, frequently have increased amounts of telomerase [41].

Consistent with the roles of TERT C228T in poor clinicopathologic outcomes of PTC were recent reports of the association of TERT promoter mutations with brain tumor-associated patient mortality [42], bladder cancer recurrence [43], and poor survival of patients with laryngeal cancer [44]. At the same time, a significant interest in TERT promoter mutations has developed and several publications have been generated over the last 5 years (Table 3, [30, 45-51]). The prevalence of TERT promoter mutations in PTC varied between 4.1% and 25.5%, according to these large cohorts of dif-

ferent racial studies. TERT promoter mutations were found to be associated with poor clinicopathological outcomes of PTC, including recurrence/persistence, LNM, ETE, higher TNM stage, capsule invasion, tumor size, vascular invasion, distant metastasis, and BRAF^{V600E} mutation. LNM is the only risk factor of TERT promoter mutations appearing in every study. Patients with PTC harboring TERT promoter mutations were submitted to more radioiodine treatments with higher cumulative doses and to more treatment modalities in one research. The study of Liu et al. showed no association of TERT promoter mutations with high iodine intake [46, 47]. Large studies from different ethnic backgrounds [30, 46-49, 51], taken together, strongly support the existence of an associative relationship of TERT promoter mutations with several conventional high-risk factors for poor prognosis of PTC, including older patient age, ETE, and higher TNM stage of PTC.

PTMCs are usually indolent lesions with a low rate of growth and low metastatic potential. However, a significant percentage of PTMCs behave aggressively. De Biase et al. analyzed the occurrence of TERT promoter mutations in a large cohort of PTMCs to discriminate aggressive PTMCs from those with an indolent course, avoiding overtreatment and long-term surveillance. They found that recurrence/persistence, LNM, higher TNM stage, and BRAF^{V600E} mutation in PTMCs were associated with TERT promoter mutations [50].

Several studies have shown co-existing BRAF^{V600E} and TERT promoter mutations form a novel genetic background that defines PTC with

Molecular markers prognosticate PTC aggressiveness

the worst clinicopathologic outcomes, providing unique prognostic and therapeutic implications [38, 45, 47, 48]. Sensitivity increases significantly when TERT promoter mutation testing is combined with other gene mutations, particularly BRAF^{V600E} and RAS mutations [30]. Another study proposed a four-genotype risk stratification system for PTC. They concluded a risk order: BRAF^{V600E}/RAS mutation and TERT promoter mutations >>>> BRAF^{V600E} mutation alone = TERT promoter mutations alone > RAS mutation alone = wild-type genes [52]. However, in another study, the concurrence or co-existence of TERT and BRAF^{V600E} mutations showed no association with increased aggressiveness and worse outcomes compared with the presence of TERT promoter mutations alone [46]. Recent findings on TERT promoter mutations in thyroid cancer are exciting. However, they should be confirmed and generalized by future high-powered studies.

RAS mutation and PTC aggressiveness

The family of human RAS genes includes HRAS, KRAS, and NRAS genes. Point mutations in 1 of the 3 RAS genes are currently the second-most common genetic alteration in thyroid cancer [53]. They encode highly related G proteins that are located at the inner surface of the cell membrane. They propagate signals arising from cell membrane receptor tyrosine kinase and G-protein-coupled receptors along the MAPK, PI3K/AKT, and other signaling pathways. Although RAS is a classical dual activator of MAPK and PI3K-AKT pathways, RAS mutations seem to preferentially activate the PI3K-AKT pathway in thyroid tumorigenesis, as suggested by the preferential association of RAS mutations with AKT phosphorylation in thyroid cancers [54, 55]. Activating point mutations in the discrete domains of the RAS genes (codons 12/13 and 61) are common in different types of human tumors. Types KRAS codon 12/13 mutations predominate in most cancer, while NRAS codon 61 and HRAS codon 61 involve the most frequent mutations in thyroid tumors. RAS mutations are found with variable frequency in all types of thyroid follicular cell-derived tumors [26]. RAS mutations occurs in 30-45% of PTC and are frequently found in encapsulated follicular variants of papillary carcinoma, a tumor with indolent behavior [56, 57].

Many studies have found a significant correlation between RAS mutations and metastatic behavior of PTC, especially concerning bone metastases. RAS mutations apparently predispose the well-differentiated cancer to dedifferentiation and more aggressive behavior [58-60]. It is likely that RAS mutations mark a subset of widely invasive PTC, prone to metastatic spread and dedifferentiation. However, these mutations cannot be used as universal prognostic markers for all types of thyroid tumors. It has also been suggested that RAS mutations may confer a more aggressive phenotype in some cases, increasing patient risks for tumor recurrence, distant metastases, and death [61, 62].

PAX8/PPAR γ rearrangement and PTC aggressiveness

PAX8/PPAR γ is a gene rearrangement occurring as a result of t (2; 3) (q13; p25) translocation. With the translocation, fusion between the paired box 8 (PAX8) gene and the peroxisome proliferator-activated receptor-activated receptor- γ (PPAR γ) gene takes place [63]. The rearrangement results in overexpression of the PPAR γ protein and exerts a dominant-negative effect on the wild-type tumor suppressor PPAR γ . It encodes a copying factor required for the proliferation of follicular thyroid cells [64]. This rearrangement can be found in many kinds of TCs, such as conventional-type follicular carcinoma, and follicular variants of papillary carcinoma and follicular adenoma. The prevalence of PAX8/PPAR γ rearrangement in follicular variants of papillary carcinoma is less than 5% in most populations, while the prevalence was as high as 38% in one study [65, 66]. Although the prevalence is up to 60% in FTA, PAX8/PPAR γ rearrangement is uncommon in benign thyroid lesions and its oncogenic roles remain unclear [67].

Past studies have demonstrated that tumors presenting a PAX8/PPAR γ rearrangement are seen in younger patients and are associated with tumorous characteristics, such as small size, solid/nested growth patterns, and a tendency to cause vascular invasion more frequently [68]. Detection of PAX8/PPAR γ rearrangement in a follicular lesion cannot fully diagnose malignancy by itself, but it should prompt the pathologist to perform an exhaus-

tive search for vascular or capsular invasion. Though it may not be seen at first, the invasion is found in many PAX8/PPAR γ -positive follicular tumors after examination of the entire capsule in multiple histologic levels [66, 69]. PAX8/PPAR γ rearrangement can be detected in thyroid FNA samples. This typically correlates with the presence of malignancy, although only a few positive cases have been reported in prospective studies [12, 70].

Conclusion

In recent years, many genetic mutations and other molecular alterations associated with PTC have been discovered and characterized. These alterations, particularly specific mutations, can be reliably detected by molecular techniques in thyroid surgical samples or in cells collected by FNA of thyroid nodules. The most extensive experience has been accumulated with the diagnostic use of BRAF^{V600E} mutation. It is highly specific for PTC when well-validated techniques are used. Moreover, the algorithm proposed in **Figure 1** may help to avoid unnecessary surgery or help with deciding the extent of surgery for patients with indeterminate FNA results. Cost-effectiveness analyses, however, have not been done for every molecular testing. Whether the algorithm presented in the previous paper is cost-effective remains to be systematically analyzed.

The biggest diagnostic impact can be achieved by testing FNA samples for a panel of mutations/rearrangements, typically including BRAF^{V600E}, TERT, RAS, and PAX8/PPAR γ . Finding any of these mutations/rearrangements in a thyroid nodule provides a strong indication of the aggressiveness. In addition, these findings may help to refine clinical management for a significant proportion of patients with indeterminate cytology.

Various clinicopathological risk factors have been reported to be related to recurrence and cancer death in PTC. According to most meta-analyses results, there was significant association between aggressiveness and molecular markers (BRAF^{V600E} mutation, TERT promoter mutations), as shown in **Tables 2** and **3**. LNM, ETE, and higher TNM stage were chosen as reliable predictors for poor prognosis in this review, as these factors not only represent aggressive behavior of cancer but also poor prognosis

[32]. LNM is an important risk factor for recurrence and/or persistent disease, as well as overall survival. ETE has been associated with an increased risk of invasion into cervical structures, such as the trachea, which requires more aggressive treatment. Accordingly, ETE is an important factor related to PTC prognosis, contributing to an increased risk of local recurrence/persistence of the disease. Higher TNM stage cancers have been associated with a poorer prognosis in terms of both recurrence and overall survival than lower TNM stage tumors [71]. According to meta-analyses results, there is a significant association between high TNM stage and BRAF^{V600E} mutation. Based on these results, it is suggested that the presence of BRAF^{V600E}, TERT, RAS, and PAX8/PPAR γ mutations/rearrangements are poor prognosis factors for PTCs. However, it is worth mentioning that different surgical approaches and treatments used in different countries may have influenced outcomes in terms of real incidence of nodal metastasis. Therefore, caution should be exercised when evaluating these molecular markers as prognostic indicators for aggressiveness in PTCs.

Methylation aberrations of genes and consequent alterations in their expression are fundamental molecular mechanisms in the tumorigenesis of human cancers [72]. A prominent epigenetic mechanism was discovered in 2011, through which BRAF^{V600E} can promote PTC tumorigenesis by altering methylation and, hence, the expression of numerous important genes [73]. Recently, one study revealed that Wiskott-Aldrich syndrome protein (WASP) interacting protein family member 1 (WIPF1) functions like an oncoprotein to robustly promote invasive cellular and tumor behaviors of PTC. Moreover, BRAF^{V600E}-activated MAP kinase pathways cause hypomethylation and overexpression of WIPF1 [74].

In conclusion, the presence of BRAF^{V600E}, TERT, RAS, and PAX8/PPAR γ mutations/rearrangements is significantly associated with high-risk clinicopathological factors and poor clinical outcomes, predicting the aggressiveness of PTCs. The present study aimed to provide significant and useful information for health-care system decision-makers, with a goal of avoiding unnecessary surgical risks and costs for PTC patients.

Disclosure of conflict of interest

None.

Address correspondence to: Bao-Ding Chen, Department of Medical Ultrasound, Affiliated Hospital of Jiangsu University, 438 Jiefang Road, Jingkou District, Zhenjiang 212001, China. Tel: 135-1169-6205; E-mail: alphalife@163.com

References

[1] Siegel RL, Miller KD and Jemal A. Cancer Statistics, 2017. *CA Cancer J Clin* 2017; 67: 7-30.

[2] Davies L, Welch HG. Increasing incidence of thyroid cancer in the united states, 1973-2002. *JAMA* 2006; 295: 2164-2167.

[3] Qubain SW, Nakano S, Baba M, Takao S and Aikou T. Distribution of lymph node micrometastasis in pNO well-differentiated thyroid carcinoma. *Surgery* 2002; 131: 249-256.

[4] Cibas ES and Ali SZ. The Bethesda system for reporting thyroid cytopathology. *American Journal of Clinical Pathology* 2009; 132: 658-665.

[5] Bongiovanni M, Spitale A, Faquin WC, Mazzucchelli L and Baloch ZW. The Bethesda system for reporting thyroid cytopathology: a meta-analysis. *Acta Cytol* 2012; 56: 333-339.

[6] Cibas ES and Ali SZ. The 2017 Bethesda system for reporting thyroid cytopathology. *Thyroid* 2017; 6: 217-222.

[7] Gharib H, Papini E, Garber JR, Duick DS, Harrell RM, Hegedüs L, Paschke R, Valcavi R and Vitti P. American association of clinical endocrinologists, american college of endocrinology, and associazione medici endocrinologi medical guidelines for clinical practice for the diagnosis and management of thyroid nodules – 2016 update. *Endocr Pract* 2016; 22: 1-60.

[8] Haugen BR, Alexander EK, Bible KC, Doherty GM, Mandel SJ, Nikiforov YE, Pacini F, Randolph GW, Sawka AM, Schlumberger M, Schuff KG, Sherman SI, Sosa JA, Steward DL, Tuttle RM and Wartofsky L. 2015 American thyroid association management guidelines for adult patients with thyroid nodules and differentiated thyroid cancer: the American thyroid association guidelines task force on thyroid nodules and differentiated thyroid cancer. *Thyroid* 2016; 26: 1-133.

[9] Faroux MJ, Theobald S, Pluot M, Patey M and Menzies D. Evaluation of the monoclonal antibody antithyroperoxidase MoAb47 in the diagnostic decision of cold thyroid nodules by fine-needle aspiration. *Pathol Res Pract* 1997; 193: 705-712.

[10] Umbricht CB, Conrad GT, Clark DP, Westra WH, Smith DC, Zahurak M, Saji M, Smallridge RC,

Goodman S and Zeiger MA. Human telomerase reverse transcriptase gene expression and the surgical management of suspicious thyroid tumors. *Clin Cancer Res* 2004; 10: 5762-5768.

[11] Saggiorato E, De Pompa R, Volante M, Cappia S, Arecco F, Dei Tos AP, Orlandi F and Papotti M. Characterization of thyroid “follicular neoplasms” in fine-needle aspiration cytological specimens using a panel of immunohistochemical markers: a proposal for clinical application. *Endocr Relat Cancer* 2005; 12: 305-317.

[12] Nikiforov YE, Steward DL, Robinson-Smith TM, Haugen BR, Klopper JP, Zhu Z, Fagin JA, Falciglia M, Weber K and Nikiforova MN. Molecular testing for mutations in improving the fine-needle aspiration diagnosis of thyroid nodules. *J Clin Endocrinol Metab* 2009; 94: 2092-2098.

[13] Samija I, Mateša N, Lukač J and Kusić Z. Galectin-3 and CD44v6 as markers for preoperative diagnosis of thyroid cancer by RT-PCR. *Diagn Mol Pathol* 2011; 20: 233-241.

[14] Fadda G, Rossi ED, Raffaelli M, Pontecorvi A, Sioletic S, Morassi F, Lombardi CP, Zannoni GF and Rindi G. Follicular thyroid neoplasms can be classified as low- and high-risk according to HBME-1 and Galectin-3 expression on liquid-based fine-needle cytology. *Eur J Endocrinol* 2011; 165: 447-453.

[15] Nikiforov YE, Ohori NP, Hodak SP, Carty SE, LeBeau SO, Ferris RL, Yip L, Seethala RR, Tublin ME, Stang MT, Coyne C, Johnson JT, Stewart AF and Nikiforova MN. Impact of mutational testing on the diagnosis and management of patients with cytologically indeterminate thyroid nodules: a prospective analysis of 1056 fna samples. *J Clin Endocrinol Metab* 2011; 96: 3390-3397.

[16] Shen R, Liyanarachchi S, Li W, Wakely PE Jr, Saji M, Huang J, Nagy R, Farrell T, Ringel MD, de la Chapelle A, Kloos RT and He H. MicroRNA signature in thyroid fine needle aspiration cytology applied to “atypia of undetermined significance” cases. *Thyroid* 2012; 22: 9-16.

[17] Keutgen XM, Filicori F, Crowley MJ, Wang Y, Scognamiglio T, Hoda R, Buitrago D, Cooper D, Zeiger MA, Zarnegar R, Elemento O and Fahey TJ. A panel of four miRNAs accurately differentiates malignant from benign indeterminate thyroid lesions on fine needle aspiration. *Clin Cancer Res* 2012; 18: 2032-2038.

[18] Rossi M, Buratto M, Bruni S, Filieri C, Tagliati F, Trasforini G, Rossi R, Beccati MD, Degli Uberti EC and Zatelli MC. Role of ultrasonographic/clinical profile, cytology, and BRAF V600E mutation evaluation in thyroid nodule screening for malignancy: a prospective study. *J Clin Endocrinol Metab* 2012; 97: 2354-2361.

Molecular markers prognosticate PTC aggressiveness

- [19] Alexander EK, Kennedy GC, Baloch ZW, Cibas ES, Chudova D, Diggans J, Friedman L, Kloos RT, LiVolsi VA, Mandel SJ, Raab SS, Rosai J, Steward DL, Walsh PS, Wilde JI, Zeiger MA, Lanman RB and Haugen BR. Preoperative diagnosis of benign thyroid nodules with indeterminate cytology. *N Engl J Med* 2012; 367: 705-715.
- [20] Nikiforov YE, Carty SE, Chiosea SI, Coyne C, Duvvuri U, Ferris RL, Gooding WE, Hodak SP, LeBeau SO, Otori NP, Seethala RR, Tublin ME, Yip L and Nikiforova MN. Highly accurate diagnosis of cancer in thyroid nodules with follicular neoplasm/suspicious for a follicular neoplasm cytology by ThyroSeq v2 next-generation sequencing assay. *Cancer* 2014; 120: 3627-3634.
- [21] Labourier E, Shifrin A, Busseniers AE, Lupo MA, Manganelli ML, Andruss B, Wylie D and Beaudenon-Huibregtse S. Molecular testing for miRNA, mRNA, and DNA on fine-needle aspiration improves the preoperative diagnosis of thyroid nodules with indeterminate cytology. *J Clin Endocrinol Metab* 2015; 100: 2743-2750.
- [22] Lithwick-Yanai G, Dromi N, Shtabsky A, Morgenstern S, Strenov Y, Feinmesser M, Kravtsov V, Leon ME, Hajdúch M, Ali SZ, VandenBussche CJ, Zhang X, Leider-Trejo L, Zubkov A, Vorobyov S, Kushnir M, Goren Y, Tabak S, Kadosh E, Benjamin H, Schnitzer-Perlman T, Marmor H, Motin M, Lebanony D, Kredon-Russo S, Mitchell H, Noller M, Smith A, Dattner O, Ashkenazi K, Sanden M, Berlin KA, Bar D and Meiri E. Multicentre validation of a microRNA-based assay for diagnosing indeterminate thyroid nodules utilising fine needle aspirate smears. *J Clin Pathol* 2017; 70: 500-507.
- [23] Vargas-Salas S, Martínez JR, Urra MS, Dominguez JM, Mena N, Uslar T, Lagos M, Henriquez M and Gonzalez HE. Genetic testing for indeterminate thyroid cytology: review and meta-analysis. *Endocr Relat Cancer* 2018; 25: R163-R177.
- [24] Kwak JY HK, Yoon JH, Moon HJ, Son EJ, Park SH, Jung HK, Choi JS, Kim BM and Kim EK. Thyroid imaging reporting and data system for US features of nodules: a step in establishing better stratification of cancer risk. *Radiology* 2011; 260: 892-899.
- [25] Xing M. Molecular pathogenesis and mechanisms of thyroid cancer. *Nat Rev Cancer* 2013; 13: 184-199.
- [26] Nikiforov YE. Molecular diagnostics of thyroid tumors. *Arch Pathol Lab Med* 2011; 135: 569-577.
- [27] Wan PT, Garnett MJ, Roe SM, Lee S, Niculescu-Duvaz D, Good VM, Jones CM, Marshall CJ, Springer CJ, Barford D, Marais R. Mechanism of activation of the RAF-ERK signaling pathway by oncogenic mutations of B-RAF. *Cell* 2004; 116: 855-867.
- [28] Riesco-Eizaguirre G, Rodriguez I, De la Vieja A, Costamagna E, Carrasco N, Nistal M and Santisteban P. The BRAF^{V600E} oncogene induces transforming growth factor beta secretion leading to sodium iodide symporter repression and increased malignancy in thyroid cancer. *Cancer Res* 2009; 69: 8317-8325.
- [29] Xing M, Alzahrani AS, Carson KA, Viola D, Elisei R, Bendlova B, Yip L, Mian C, Vianello F, Tuttle RM, Robenshtok E, Fagin JA, Puxeddu E, Fugazzola L, Czarniecka A, Jarzab B, O'Neill CJ, Sywak MS, Lam AK, Riesco-Eizaguirre G, Santisteban P, Nakayama H, Tufano RP, Pai SI, Zeiger MA, Westra WH, Clark DP, Clifton-Bligh R, Sidransky D, Ladenson PW and Sykora V. Association between BRAF^{V600E} mutation and mortality in patients with papillary thyroid cancer. *JAMA* 2013; 309: 1493-1501.
- [30] Jin L, Chen E, Dong S, Cai Y, Zhang X, Zhou Y, Zeng R, Yang F, Pan C, Liu Y, Wu W, Xing M, Zhang X and Wang O. BRAF and TERT promoter mutations in the aggressiveness of papillary thyroid carcinoma: a study of 653 patients. *Oncotarget* 2016; 7: 18346-18355.
- [31] Elisei R, Viola D, Torregrossa L, Giannini R, Romai C, Ugolini C, Molinaro E, Agate L, Biagini A, Lupi C, Valerio L, Materazzi G, Miccoli P, Piaggi P, Pinchera A, Vitti P and Basolo F. The BRAF (V600E) mutation is an independent, poor prognostic factor for the outcome of patients with low-risk intrathyroid papillary thyroid carcinoma: single-institution results from a large cohort study. *J Clin Endocrinol Metab* 2012; 97: 4390-4398.
- [32] Xing M. BRAF mutation in papillary thyroid cancer: pathogenic role, molecular bases, and clinical implications. *Endocr Rev* 2007; 28: 742-762.
- [33] Li C, Lee KC, Schneider EB and Zeiger MA. BRAF^{V600E} mutation and its association with clinicopathological features of papillary thyroid cancer: a meta-analysis. *J Clin Endocrinol Metab* 2012; 97: 4559-4570.
- [34] Liu X, Yan K, Lin X, Zhao L, An W, Wang C and Liu X. The association between BRAF (V600E) mutation and pathological features in PTC. *Eur Arch Otorhinolaryngol* 2014; 271: 3041-3052.
- [35] Li F, Chen G, Sheng C, Gusdon AM, Huang Y, Lv Z, Xu H, Xing M and Qu S. BRAF^{V600E} mutation in papillary thyroid microcarcinoma: a meta-analysis. *Endocr Relat Cancer* 2015; 22: 159-168.
- [36] Zhang Q, Liu S, Zhang Q, Guan Y, Chen Q and Zhu Q. Meta-analyses of association between BRAF V600E mutation and clinicopathological features of papillary thyroid carcinoma. *Cell Physiol Biochem* 2016; 38: 763-776.

Molecular markers prognosticate PTC aggressiveness

- [37] Liu C, Chen T and Liu Z. Associations between BRAF (V600E) and prognostic factors and poor outcomes in papillary thyroid carcinoma: a meta-analysis. *World J Surg Oncol* 2016; 14: 241-252.
- [38] Liu X, Bishop J, Shan Y, Pai S, Liu D, Murugan AK, Sun H, El-Naggar AK and Xing M. Highly prevalent TERT promoter mutations in aggressive thyroid cancers. *Endocr Relat Cancer* 2013; 20: 603-610.
- [39] Kim NW, Piatyszek MA, Prowse KR, Harley CB, West MD, Ho PL, Coviello GM, Wright WE, Weinrich SL and Shay JW. Specific association of human telomerase activity with immortal cells and cancer. *Science* 1994; 266: 2011-2015.
- [40] Reddel RR. Alternative lengthening of telomeres, telomerase, and cancer. *Cancer Lett* 2003; 194: 155-162.
- [41] Heaphy CM, Subhawong AP, Hong SM, Goggins MG, Montgomery EA, Gabrielson E, Netto GJ, Epstein JI, Lotan TL, Westra WH, Shih Ie M, Iacobuzio-Donahue CA, Maitra A, Li QK, Eberhart CG, Taube JM, Rakheja D, Kurman RJ, Wu TC, Roden RB, Argani P, De Marzo AM, Terracciano L, Torbenson M and Meeker AK. Prevalence of the alternative lengthening of telomeres telomere maintenance mechanism in human cancer subtypes. *Am J Pathol* 2011; 179: 1608-1615.
- [42] Killela PJ, Reitman ZJ, Jiao Y, Bettegowda C, Agrawal N, Diaz LA, Friedman AH, Friedman H, Gallia GL, Giovannella BC, Grollman AP, He TC, He Y, Hruban RH, Jallo GI, Mandahl N, Meeker AK, Mertens F, Netto GJ, Rasheed BA, Riggins GJ, Rosenquist TA, Schiffman M, Shih IM, Theodorescu D, Torbenson MS, Velculescu VE, Wang TL, Wentzensen N, Wood LD, Zhang M, McLendon RE, Bigner DD, Kinzler KW, Vogelstein B, Papadopoulos N and Yan H. TERT promoter mutations occur frequently in gliomas and a subset of tumors derived from cells with low rates of self-renewal. *Proc Natl Acad Sci U S A* 2013; 110: 6021-6026.
- [43] Kinde I, Munari E, Faraj SF, Hruban RH, Schoenberg M, Bivalacqua T, Allaf M, Springer S, Wang Y, Diaz LA, Kinzler KW, Vogelstein B, Papadopoulos N and Netto GJ. TERT promoter mutations occur early in urothelial neoplasia and are biomarkers of early disease and disease recurrence in urine. *Cancer Res* 2013; 73: 7162-7167.
- [44] Qu Y, Dang S, Wu K, Shao Y, Yang Q, Ji M, Shi B and Hou P. TERT promoter mutations predict worse survival in laryngeal cancer patients. *Int J Cancer* 2014; 135: 1008-1010.
- [45] Liu T, Wang N, Cao J, Sofiadis A, Dinets A, Zedeni J, Larsson C and Xu D. The age- and shorter telomere-dependent TERT promoter mutation in follicular thyroid cell-derived carcinomas. *Oncogene* 2014; 33: 4978-4984.
- [46] Melo M, da Rocha AG, Vinagre J, Batista R, Peixoto J, Tavares C, Celestino R, Almeida A, Salgado C, Eloy C, Castro P, Prazeres H, Lima J, Amaro T, Lobo C, Martins MJ, Moura M, Cavaco B, Leite V, Cameselle-Teijeiro JM, Carrilho F, Carvalheiro M, Máximo V, Sobrinho-Simões M and Soares P. TERT promoter mutations are a major indicator of poor outcome in differentiated thyroid carcinomas. *J Clin Endocrinol Metab* 2014; 99: E754-E765.
- [47] Liu X, Qu S, Liu R, Sheng C, Shi X, Zhu G, Murugan AK, Guan H, Yu H, Wang Y, Sun H, Shan Z, Teng W and Xing M. TERT promoter mutations and their association with BRAF^{V600E} mutation and aggressive clinicopathological characteristics of thyroid cancer. *J Clin Endocrinol Metab* 2014; 99: E1130-1136.
- [48] Xing M, Liu R, Liu X, Murugan AK, Zhu G, Zeiger MA, Pai S and Bishop J. BRAF^{V600E} and TERT promoter mutations cooperatively identify the most aggressive papillary thyroid cancer with highest recurrence. *J Clin Oncol* 2014; 32: 2718-2726.
- [49] Qasem E, Murugan AK, Al-Hindi H, Xing M, Almohanna M, Alswailem M and Alzahrani AS. TERT promoter mutations in thyroid cancer: a report from a Middle Eastern population. *Endocr Relat Cancer* 2015; 22: 901-908.
- [50] de Biase D, Gandolfi G, Ragazzi M, Eszlinger M, Sancisi V, Gugnoni M, Visani M, Pession A, Casadei G, Durante C, Costante G, Bruno R, Torlontano M, Paschke R, Filetti S, Piana S, Frasoldati A, Tallini G and Ciarrocchi A. TERT promoter mutations in papillary thyroid microcarcinomas. *Thyroid* 2015; 25: 1013-1019.
- [51] Bae JS, Kim Y, Jeon S, Kim SH, Kim TJ, Lee S, Kim MH, Lim DJ, Lee YS and Jung CK. Clinical utility of TERT promoter mutations and ALK rearrangement in thyroid cancer patients with a high prevalence of the BRAF V600E mutation. *Diagn Pathol* 2016; 11: 21-30.
- [52] Shen X, Liu R and Xing M. A six-genotype genetic prognostic model for papillary thyroid cancer. *Endocrine-Related Cancer* 2017; 24: 41-52.
- [53] Howell GM, Hodak SP and Yip L. RAS mutations in thyroid cancer. *The Oncologist* 2013; 18: 926-932.
- [54] Abubaker J, Jehan Z, Bavi P, Sultana M, Al-Harbi S, Ibrahim M, Al-Nuaim A, Ahmed M, Amin T, Al-Fehaily M, Al-Sanea O, Al-Dayel F, Uddin S and Al-Kuraya KS. Clinicopathological analysis of papillary thyroid cancer with PIK3CA alterations in a middle eastern population. *J Clin Endocrinol Metab* 2008; 93: 611-618.

Molecular markers prognosticate PTC aggressiveness

- [55] Liu Z, Hou P, Ji M, Guan H, Studeman K, Jensen K, Vasko V, El-Naggar AK and Xing M. Highly prevalent genetic alterations in receptor tyrosine kinases and phosphatidylinositol 3-Kinase/Akt and mitogen-activated protein kinase pathways in anaplastic and follicular thyroid cancers. *J Clin Endocrinol Metab* 2008; 93: 3106-3116.
- [56] Xing M, Haugen BR and Schlumberger M. Progress in molecular-based management of differentiated thyroid cancer. *Lancet* 2013; 381: 1058-1069.
- [57] Parlea L, Fahim L, Munoz D, Hanna A, Anderson J, Cusimano M, Kovacs K, Gardiner G. Follicular carcinoma of the thyroid with aggressive metastatic behavior in a pregnant woman: report of a case and review of the literature. *Hormones* 2006; 5: 295-302.
- [58] Fagin JA. Minireview: branched from the start-distinct oncogenic initiating events may determine tumor fate in the thyroid. *Mol Endocrinol* 2002; 16: 903-911.
- [59] Basolo F, Pisaturo F, Pollina LE, Fontanini G, Elisei R, Molinaro E, Iacconi P, Miccoli P, Pacini F. N-ras mutation in poorly differentiated thyroid carcinomas: correlation with bone metastases and inverse correlation to thyroglobulin expression. *Thyroid* 2009; 10: 19-23.
- [60] Garcia-Rostan G, Zhao H, Camp RL, Pollan M, Herrero A, Pardo J, Wu R, Carcangiu ML, Costa J and Tallini G. Ras mutations are associated with aggressive tumor phenotypes and poor prognosis in thyroid cancer. *J Clin Oncol* 2003; 21: 3226-3235.
- [61] Fukahori M, Yoshida A, Hayashi H, Yoshihara M, Matsukuma S, Sakuma Y, Koizume S, Okamoto N, Kondo T, Masuda M and Miyagi Y. The associations between RAS mutations and clinical characteristics in follicular thyroid tumors: new insights from a single center and a large patient cohort. *Thyroid* 2012; 22: 683-689.
- [62] Miller KA, Yeager N, Baker K, Liao XH, Refetoff S and Di Cristofano A. Oncogenic kras requires simultaneous PI3K signaling to induce ERK activation and transform thyroid epithelial cells *In vivo*. *Cancer Res* 2009; 69: 3689-3694.
- [63] Kroll TG, Sarraf P, Pecciarini L, Chen CJ, Mueller E, Spiegelman BM and Fletcher JA. PAX8-PPAR γ 1 fusion in oncogene human thyroid carcinoma. *Science* 2000; 289: 1357-1360.
- [64] Kocjan G, Feichter G, Hagmar B, Kapila K, Kardum-Skelin I, Kloboves V, Kobayashi TK, Koutselini H, Majak B, Schenck U, Schmitt F, Tani E, Totch M, Onal B, Vass L, Vielh P, Weynand B and Herbert A. Fine needle aspiration cytology: a survey of current European practice. *Cytopathology* 2006; 17: 219-226.
- [65] Castro P, Rebocho AP, Soares RJ, Magalhães J, Roque L, Trovisco V, Vieira de Castro I, Cardoso-de-Oliveira M, Fonseca E, Soares P and Sobrinho-Simões M. PAX8-PPAR γ rearrangement is frequently detected in the follicular variant of papillary thyroid carcinoma. *J Clin Endocrinol Metab* 2006; 91: 213-220.
- [66] Nikiforova MN, Biddinger PW, Caudill CM, Kroll TG and Nikiforov YE. PAX8-PPAR γ rearrangement in thyroid tumors: RT-PCR and immunohistochemical analyses. *Am J Surg Pathol* 2002; 26: 1016-1023.
- [67] Eberhardt NL, Grebe SK, McIver B and Reddi HV. The role of the PAX8/PPAR γ fusion oncogene in the pathogenesis of follicular thyroid cancer. *Mol Cell Endocrinol* 2010; 321: 50-56.
- [68] Sahnaz A, Onal B, Yesilyurt A, Han U and Delibasi T. BRAF (V600E) Mutation, RET/PTC1 and PAX8-PPAR γ gamma rearrangements in follicular epithelium derived thyroid lesions - institutional experience and literature review. *Balkan Med J* 2015; 32: 156-166.
- [69] French CA, Alexander EK, Cibas ES, Nose V, Laguette J, Faquin W, Garber J, Moore F, Fletcher JA, Larsen PR and Kroll TG. Genetic and biological subgroups of low-stage follicular thyroid cancer. *Am J Pathol* 2003; 162: 1053-1060.
- [70] Otori NP, Nikiforova MN, Schoedel KE, LeBeau SO, Hodak SP, Seethala RR, Carty SE, Ogilvie JB, Yip L and Nikiforov YE. Contribution of molecular testing to thyroid fine-needle aspiration cytology of "follicular lesion of undetermined significance/atypia of undetermined significance". *Cancer Cytopathol* 2010; 118: 17-23.
- [71] Cooper DS, Doherty GM, Haugen BR, Kloos RT, Lee SL, Mandel SJ, Mazzaferri EL, McIver B, Sherman SI and Tuttle RM. Management guidelines for patients with thyroid nodules and differentiated thyroid cancer. *Thyroid* 2006; 16: 109-142.
- [72] Jones PA and Baylin SB. The epigenomics of cancer. *Cell* 2007; 128: 683-692.
- [73] Hou P, Liu D and Xing M. Genome-wide alterations in gene methylation by the BRAF V600E mutation in papillary thyroid cancer cells. *Endocr Relat Cancer* 2011; 18: 687-697.
- [74] Zhang T, Shen X, Liu R, Zhu G, Bishop J and Xing M. Epigenetically upregulated WIPF1 plays a major role in BRAF V600E-promoted papillary thyroid cancer aggressiveness. *Oncotarget* 2017; 8: 900-914.