

## Original Article

# Identification of a novel crizotinib-sensitive NR-110219 & MIR4432-ALK gene fusion in a patient with lung adenocarcinoma by high-throughput sequencing of circulating tumor DNA and tumor-derived DNA from pleural effusion fluid

Mengdie Qi<sup>1</sup>, Yanfei Yang<sup>1</sup>, Yangyang Gu<sup>1,2</sup>, Hequan Li<sup>1</sup>

<sup>1</sup>Department of Respiratory Diseases, The First Affiliated Hospital, College of Medicine, Zhejiang University, Hangzhou 310012, Zhejiang, China; <sup>2</sup>Department of Respiratory Diseases, Jiaxing Second Hospital, The Second Affiliated Hospital of Jiaxing University, Jiaxing 314000, Zhejiang, China

Received February 23, 2018; Accepted May 28, 2018; Epub July 15, 2018; Published July 30, 2018

**Abstract:** We found a novel NR-110219 & MIR4432-ALK gene fusion in a lung adenocarcinoma patient by high-throughput sequencing of circulating tumor DNA and tumor-derived DNA from pleural effusion fluid and the patient responded well to crizotinib.

**Keywords:** Lung adenocarcinoma, NR-110219 & MIR4432-ALK gene fusion, ctDNA, crizotinib

## Introduction

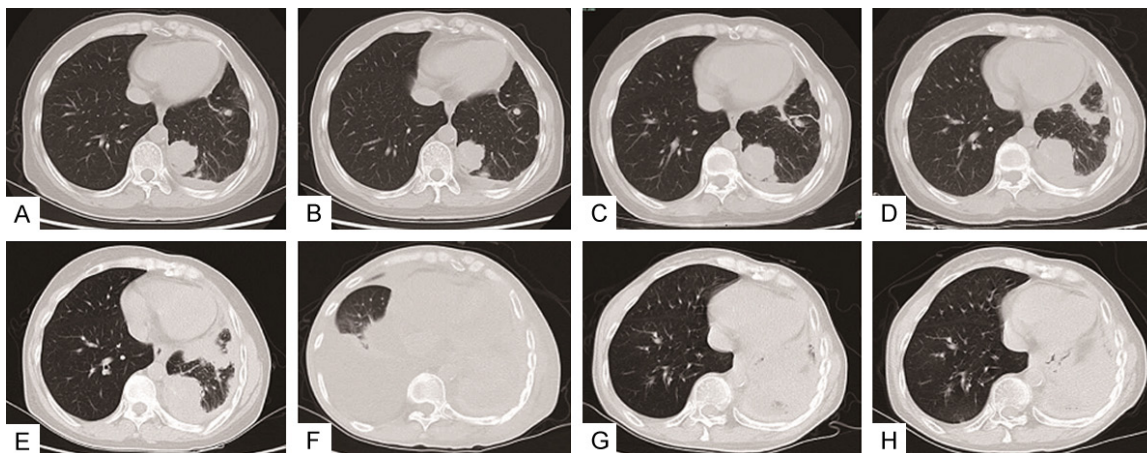
Lung cancer is one of the most common cancers and the leading cause of cancer-caused death currently [1]. Non-small-cell lung cancer (NSCLC) accounts for 80% of lung cancer which contains adenocarcinoma and squamous cell carcinoma [2]. Approximately half of NSCLC cases are adenocarcinoma [3]. In recent years, epidermal growth factor receptor (EGFR), anaplastic lymphoma kinase (ALK) and c-ros oncogene 1 receptor tyrosine kinase gene (ROS proto-oncogene 1) were discovered as driver mutations in lung adenocarcinoma thus dramatically changing the therapeutic strategy for unresectable disease [4]. More than 10 different ALK fusion partners have been discovered in lung adenocarcinoma: EML4, KIF5B, KLC1, TFG, TPR, HIP1, STRN, DCTN1, SQSTM1, BIRC 6 and others [5]. Pre-clinical studies have shown that ALK mutation-driven tumors are highly sensitive to ALK TKIs *in vitro* in a panel of human tumor cell lines including NSCLC, and that these tumor cells were dependent on ALK for their growth and survival [6]. Recent advances in multiplex genotyping based on circulating tumor DNA (ctDNA) provide an alternative

method for detection of the gene mutation [7], compared with currently accepted methods for detecting ALK rearrangement, such as FISH, RT-PCR, and Ventana IHC [8]. We herein present a novel NR-110219 & MIR4432-ALK gene fusion in a lung adenocarcinoma patient identified by high-throughput sequencing of ctDNA and tumor-derived DNA from pleural effusion fluid. The patient responded to the ALK inhibitor crizotinib.

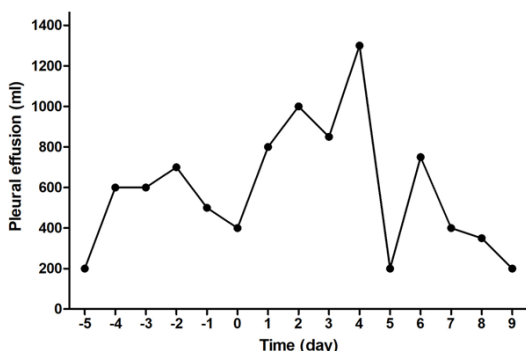
## Material and methods

### Patient

A 50-year-old, never-smoking woman experienced chest pain and breathlessness for 2 months and sought for help in the second Affiliated Hospital of Zhejiang University. A computed tomography (CT)-scan showed a left-lobe lung lesion in the inferior lobe with a maximum diameter of 27 mm. Pleural metastasis and pleural effusion also existed. A thoracoscopy was performed there and the evaluation of biopsy from the pleural samples confirmed the diagnosis of adenocarcinoma. IHC showed that tumor cells, which came from lung, were posi-



**Figure 1.** Computed Tomography (CT) scans of the patient during treatment with chemotherapy, icotinib, and crizotinib respectively. A. Chest CT scan before chemotherapy treatment. B. Chest CT Scan after 12 months of chemotherapy. C. Chest CT scan after 1 month of icotinib treatment. D. Chest CT scan after 5 months of icotinib. E. Chest CT scan after 8 months of icotinib treatment. F. Chest CT scan before crizotinib treatment. G. Chest CT scan after 11 months of crizotinib. H. Chest CT scan after 15 months of crizotinib.



**Figure 2.** Dynamic change of pleural effusion before and during crizotinib treatment.

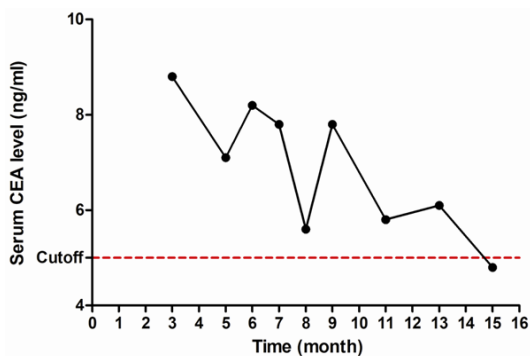
tive for TTF-1 and CK7+, but negative for CK 2, whereas Ki67 was 30%. The patient received chemotherapy with 2 cycles of carboplatin-pemetrexed from November to December 2012 in that hospital. Later she came to our hospital for help. Since she had already received 2 cycles of chemotherapy and the lung nodules remained stable at that time. She later received 10 cycles of cisplatin-pemetrexed from December 2012 to April 2014. The CT showed a steady increase in the size of lung nodules during that period. A research study showed that DCR, 1-year OS, and PFS of chemotherapy combined with the DC-CIK is longer [8]. After 12 cycles of chemotherapy, she underwent DC-CIK between May 2014 and August 2014.

The lung nodules remained stable from January 2014 to May 2014. However, the size of lung

nodules increased to 35 \* 33 mm on July 19 2014, an increase of 25.8% from January, 2014. The disease was progressing at that point and she refused to do the genetic testing. However, she received treatment of icotinib starting on August 4, 2014. Fortunately, she was in stable condition between August 2014 to April 2015, with the largest mass increasing from 36 \* 34 mm to 39 \* 38 mm. However, the lung nodules rapidly increased in size to 55 \* 41 mm on June 27, 2015 (**Figure 1**). From June 2015 to August 2016, she experienced progressive disease with pleural effusion, and mediastinal lymph nodes metastases. She didn't stop the icotinib therapy until December 2016. At the end of 2016, she experienced chest tightness again and was hospitalized. Then on December 10, 2016, her blood and pleural effusion was sent to detect whether there was a gene rearrangement.

We collected 50 ml of pleural effusion fluid and 10 ml of peripheral blood respectively from the patient on Dec 2, 2016. DNA was extracted and processed, after which DNA quantification was performed using 20 ng of DNA to build the library construction according to kit instructions. The probe enrichment was completed and high-throughput sequencing was performed [9]. (Captured library follow the kit description The Illumina HiSeq 4000 High Throughput Sequencing Platform loads the DNA on the Flow cell kit to form DNA clusters. The sequencing platform pauses after single

## Identification of a novel NR-110219 & MIR4432-ALK gene fusion in a NSCLC patient



**Figure 3.** Dynamic change of CEA during crizotinib treatment.

base synthesis, and fluorescence is detected.) Bio informatics Analysis [10].

It was surprising to discover a novel NR-110219 & MIR4432-ALK fusion transcript, the first NR-110219 & MIR4432-ALK fusion variant described in lung adenocarcinoma to date. The NR-110219 & MIR4432 gene spacer broke down and fused to ALK 19th introns, with abundance of 0.8% and 4.1% respectively. The product may consist of NR-110219 & MIR4432 gene spacer and 20 to 29 exon of ALK gene.

The patient received crizotinib (from 2016-12-14) and stable disease (SD) has currently reached 15 months. During this time, we could see absorption of pleural effusion on the right as the graph shows. (Figure 2). CEA decreased from 14.4 ng/ml (2016-11-23) to 4.8 ng/ml (2018-3-31) (Figure 3).

### Discussion

The Lung Cancer Mutation Consortium and the Clinical Lung Cancer Genome Project studies have demonstrated the feasibility of tumor genotyping to guide therapy in lung adenocarcinoma patients. As part of the Lung Cancer Mutation Consortium, patients received matched targeted treatments after multiplexed testing for alterations in genes. Pre-clinical studies showed that ALK-driven tumors such as NSCLC are highly sensitive to ALK TKIs [6]. We therefore predicted that the NR-110219 & MIR4432-ALK fusion was also sensitive to crizotinib and let the patient receive crizotinib. Moreover, there was no EGFR mutation of the patient at the first diagnosis. Therefore, the current mutation might be related with previous therapy. Approximately 10% of EGFR wild-type

patients may have an improvement with TKIs in terms of response rate and PFS [11-13]. The patient experienced PFS during the icotinib therapy.

This is the first report that demonstrates the presence of a novel NR-110219 & MIR4432-ALK mutation in a patient. Both NR-110219 & MIR4432 are located at 2p16.1. NR-110219 & MIR4432-ALK could be considered as an oncogenic fusion gene, which should be added to the list of ALK fusion genes. It was reported on a study of breast and prostate cancer in the NHLBI's Framingham Heart Study. MIR4432 was reported about Hematologic Malignancies. The product may consist of NR-110219 & MIR4432 gene spacer and 20 to 29 exon of ALK gene. The integrated approach has not been reported yet, so specific fusion significance is not clear. The domain contains ALK complete kinase structure, which may participate in the development of tumor, and may increase the ALK inhibitor drugs sensitivity. Of note, molecular analysis was not performed on our patient prior to crizotinib therapy, so it is unclear when the mutation developed. To our knowledge, lung adenocarcinoma patients with ALK fusion can benefit from pemetrexed-based chemotherapy [14]. But they have no response to EGFR-TKIs since the patient experienced PFS, both during chemotherapy and icotinib during 2012 December to 2015 April. We have reason to believe that she did not have the ALK mutation at the beginning since she responded to icotinib. However, she experienced rapid disease progression during 2015 March to 2016 December during icotinib therapy and later she responded to crizotinib. It is reasonable to speculate that ALK mutation emerged after icotinib but prior to crizotinib therapy. Additionally, it can be predicted that it is icotinib that caused the mutation of ALK.

This study warrants future investigation of clinical characteristics and biological features of lung adenocarcinoma harboring the NR-110219 & MIR4432-ALK fusion gene.

### Acknowledgements

The authors thank the investigators and patient who participated in the study. Supported by Zhejiang Provincial Natural Science Foundation: LY18H010002, LY15H010001.

### Disclosure of conflict of interest

None.

### Abbreviations

NSCLC, Non-small-cell lung cancer; AdCa, adenocarcinoma; EGFR, epidermal growth factor receptor; ROS-1, c-ros oncogene 1 receptor tyrosine kinase; SCC, squamous cell carcinoma; ALK, anaplastic lymphoma kinase; ctDNA, circulating tumor DNA; FISH, fluorescence *in situ* hybridization; RT-PCR, reverse transcription PCR; IHC, immunohistochemistry; LAK, lymphokine-activated killer; CEA, carcinoembryonic antigen; TKI, tyrosine kinase inhibitor; PFS, progression-free survival.

**Address correspondence to:** Dr. Hequan Li, Department of Respiratory Diseases, First Affiliated Hospital of Zhejiang University School of Medicine, 79 Qingchun Road, Hangzhou 310003, Zhejiang, China. Tel: (+86-571) 8723-6551; Fax: (+86-571) 8723-6551; E-mail: lihequan@zju.edu.cn

### References

- [1] Nanavaty P, Alvarez MS, Alberts WM. Lung cancer screening: advantages, controversies, and applications. *Cancer Control* 2014; 21: 9-14.
- [2] Molina JR, Yang P, Cassivi SD, Schild SE, Adjei AA. Non-small cell lung cancer: epidemiology, risk factors, treatment, and survivorship. *Mayo Clinic Proceedings* 2008; 83: 584-94.
- [3] Reck M, Heigener DF, Mok T, Soria JC, Rabe KF. Management of non-small-cell lung cancer: recent developments. *Lancet* 2013; 382: 709-19.
- [4] Roca E, Gurizzan C, Amoroso V, Vermi W, Ferrari V, Berruti A. Outcome of patients with lung adenocarcinoma with transformation to small-cell lung cancer following tyrosine kinase inhibitors treatment: a systematic review and pooled analysis. *Cancer Treat Rev* 2017; 59: 117-22.
- [5] Iyevleva AG, Raskin GA, Tiurin VI, Sokolenko AP, Mitiushkina NV, Aleksakhina SN, Garifullina AR, Strelkova TN, Merkulov VO, Ivantsov AO, Kuligina ES, Pozharisski KM, Togo AV, Imyaninov EN. Novel ALK fusion partners in lung cancer. *Cancer Lett* 2015; 362: 116-21.
- [6] McDermott U, Iafrate AJ, Gray NS, Shioda T, Classon M, Maheswaran S, Zhou W, Choi HG, Smith SL, Dowell L, Ulkus LE, Kuhlmann G, Greninger P, Christensen JG, Haber DA, Settleman J. Genomic alterations of anaplastic lymphoma kinase may sensitize tumors to anaplastic lymphoma kinase inhibitors. *Cancer Res* 2008; 68: 3389.
- [7] Santarpia M, Karachaliou N, González-Cao M, Altavilla G, Giovannetti E, Rosell R. Feasibility of cell-free circulating tumor DNA testing for lung cancer. *Biomark Med* 2016; 10: 417-30.
- [8] Liang W, He Q, Chen Y, Chuai S, Yin W, Wang W, Peng G, Zhou C, He J. Metastatic EML4-ALK fusion detected by circulating DNA genotyping in an EGFR-mutated NSCLC patient and successful management by adding ALK inhibitors: a case report. *BMC Cancer* 2016; 16: 62.
- [9] Escobar-Escamilla N, Ramirez-Gonzalez JE, Castro-Escarpulli G, Diaz-Quinonez JA. Utility of high-throughput DNA sequencing in the study of the human papillomaviruses. *Virus Genes* 2018; 54: 17-24.
- [10] Reuter JA, Spacek DV, Snyder MP. High-throughput sequencing technologies. *Mol Cell* 2015; 58: 586-97.
- [11] Tomasini P, Brosseau S, Mazieres J, Merlino JP, Beau-Faller M, Mosser J, Wislez M, Ouafik L, Besse B, Rouquette I, Debieuvre D, Escande F, Westeel V, Audigier-Valette C, Missy P, Langlais A, Morin F, Moro-Sibilot D, Zalcman G, Barlesi F. EGFR tyrosine kinase inhibitors versus chemotherapy in EGFR wild-type pre-treated advanced nonsmall cell lung cancer in daily practice. *Eur Respir J* 2017; 50.
- [12] Wu D, Duan C, Wu F, Chen L, Chen S. Which treatment is preferred for advanced non-small-cell lung cancer with wild-type epidermal growth factor receptor in second-line therapy? A meta-analysis comparing immune checkpoint inhibitor, tyrosine kinase inhibitor and chemotherapy. *Oncotarget* 2017; 8: 66491-503.
- [13] Gridelli C, Ciardiello F, Gallo C, Feld R, Butts C, Gebbia V, Maione P, Morgillo F, Genestreti G, Favaretto A, Leighl N, Wierzbicki R, Cinieri S, Alam Y, Siena S, Tortora G, Felletti R, Riccardi F, Mancuso G, Rossi A, Cantile F, Tsao MS, Saiegh M, da Cunha Santos G, Piccirillo MC, Di Maio M, Morabito A, Perrone F. First-line erlotinib followed by second-line cisplatin-gemcitabine chemotherapy in advanced non-small-cell lung cancer: the TORCH randomized trial. *J Clin Oncol* 2012; 30: 3002-11.
- [14] Park S, Park TS, Choi CM, Lee DH, Kim SW, Lee JS, Kim WS, Song JS, Lee JC. Survival benefit of pemetrexed in lung adenocarcinoma patients with anaplastic lymphoma kinase gene rearrangements. *Clin Lung Cancer* 2015; 16: e83-9.