

## Case Report

# Ocular syphilis presenting with multiple eye lesions as the only manifestation: a case report

Bowen Cao<sup>1</sup>, Xuxia Meng<sup>1</sup>, Penghui Liu<sup>1</sup>, Zhiying Yu<sup>1</sup>, Yu Lun<sup>2</sup>

Departments of <sup>1</sup>Ophthalmology, <sup>2</sup>Endocrinology and Metabolism, The Affiliated Hospital of Qingdao University, Qingdao, P. R. China

Received August 19, 2017; Accepted October 30, 2018; Epub February 15, 2019; Published February 28, 2019

**Abstract:** Syphilis is a common sex-infectious disease in the world. Ocular syphilis is an uncommon presentation of this disease, and even can mimic a variety of eye diseases. It often presents with common ophthalmic manifestations, for example, vision loss, ocular inflammation, etc. Uveitis is the most common symptom of ocular syphilis. We presented a unique case of ocular syphilis involving damage of anterior and posterior segments simultaneously but without any skin lesions. A 52 year-old man was firstly diagnosed with ophthalmoneuritis, several days later, his sclera, ciliary body and uvea were affected by inflammation, finally the retina and macular were also involved. Laboratory check-up of TPPA and RPR was positive. Then diagnosis of ocular syphilis was established. After treatment with penicillin G for 3 months, the visual acuity was improved and ocular inflammation was subsided.

**Keywords:** Ocular syphilis, scleritis, syphilitic uveitis, ophthalmoneuritis, antibiotics

## Introduction

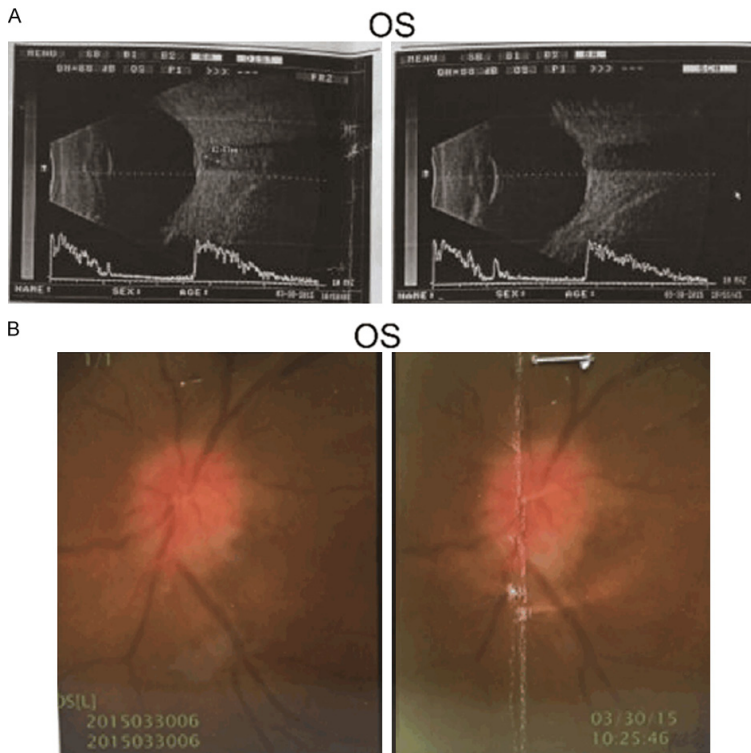
Syphilis is a common sex-infectious disease in the world, which is almost resolved after the usage of antibiotics in the mid-20th century. However, due to the increasing incidence of new cases, it is now a contemporary issue [1]. Ocular syphilis is an uncommon and deceptive manifestation of this disease. Uveitis is the most common symptom of ocular syphilis, accounting for 2.5%-5% of patients with tertiary syphilis [2]. However, a multitude of other ocular manifestations have been reported, including interstitial keratitis, chorioretinitis, retinitis, retinal vasculitis, and optic neuropathies [3]. About one-third of patients with neurosyphilis show painless bilateral vision loss as the only presenting symptom [4]. So, it is crucial for our ophthalmologists to be able to recognize manifestations of ocular syphilis as a cause of painless vision loss. We here presented a complicated case involving almost all forms of ocular inflammation as the only manifestation, from anterior segment to posterior segment, presenting with painless vision loss but without any cutaneous deficiency. Persistent visual loss was dramatically improved after treatment with

penicillin G, and inflammation had also been largely alleviated.

## Case presentation

A 52-year-old man submitted a 1-year history of fading eyesight in his left eye. The examination results in other institutions 4-month ago showed that his visual acuities were 20/20 in his right eye and 20/32 in his left eye. BCVAs in both eyes were 20/20. Vitreous turbidity was assessed by eye B ultrasonic examination (**Figure 1A**). Papilloedema and a fuzzy boundary of the left optic disc were detected by ophthalmoscope. Retinal artery got thinner and retinal veins become circuitous (**Figure 1B**). P-VEP amplitude was decreased. Visual field defects occurred in low nasal of right eye and low temporal of left eye. Brain MRI showed no abnormalities. Without a further thorough systemic check-up, this patient was diagnosed as "ophthalmoneuritis (left eye)" by an outside ophthalmologist, and took oral administration of fufangxueshuantong, mecobalamine and vitamine B, uncontinuous intravenous and oral glucocorticoids (dose unknown).

## Ocular syphilis with multiple eye lesions as the only manifestation



**Figure 1.** Eye B ultrasonic examination and fundusoscopic examination of left eye in other institution. A. B ultrasonic examination showed a vitreous turbidity and papilledema in left eye. B. Fundus microscope presented a fuzzy boundary of left optic disc. Retinal artery got smaller and retinal veins became circuitous.

After two months of treatment, vision in his left eye was progressively blurred and the right eye also appeared a diminution of vision. Then he was transferred to our hospital with a complaint of blurred vision and eye redness. He denied suffering from any other diseases through a case history inquiry. Ophthalmic examination showed BCVAs of 20/40 in right eye and 6/20 in left eye. The results of slit-lamp examination presented a dull-red, non-mobile, congestive, symmetrical nodule locating in bilateral nasal sclera. A spotty distribution of KP, ciliary congestion and 1+ aqueous cells in the anterior chamber had also been found. Eye grounds showed no abnormalities through fundusoscopic examination. Our preliminary diagnosis was nodular scleritis and iridocyclitis. Thus this patient received anti-inflammation therapy with tobradex and pranoprofen.

This patient visited our hospital again after one month of treatment. Bilateral nodules were completely flattened, whereas, a further vision loss appeared. His BCVAs were deteriorated to

6/20 in the right eye and 20/125 in the left eye. Aqueous cells still existing and 3+ vitreous cells were occurring. Eye ground inspected faintness of disc boundary in both eyes; left eye was more severe (**Figure 2A**). P-VEP and visual fields of both eyes were damaged to varying degrees. OCT revealed fovea-involved macular cystoid edema. FFA showed leakage of fluorescein from the retinal vessels in both eyes (**Figure 2D**). Complicated as this case which aroused our attention, he was asked to perform a complete evaluation and observation. Laboratory check-up was significant for RPR titers of 1:64 and a positive serum TPPA, whereas, HIV serum antibodies, tuberculous antibodies and serum immune indices were negative. This patient refused to do CSF examination and finally admitted that he had a history of feculent sexual behavior. Dermatology consultation revealed

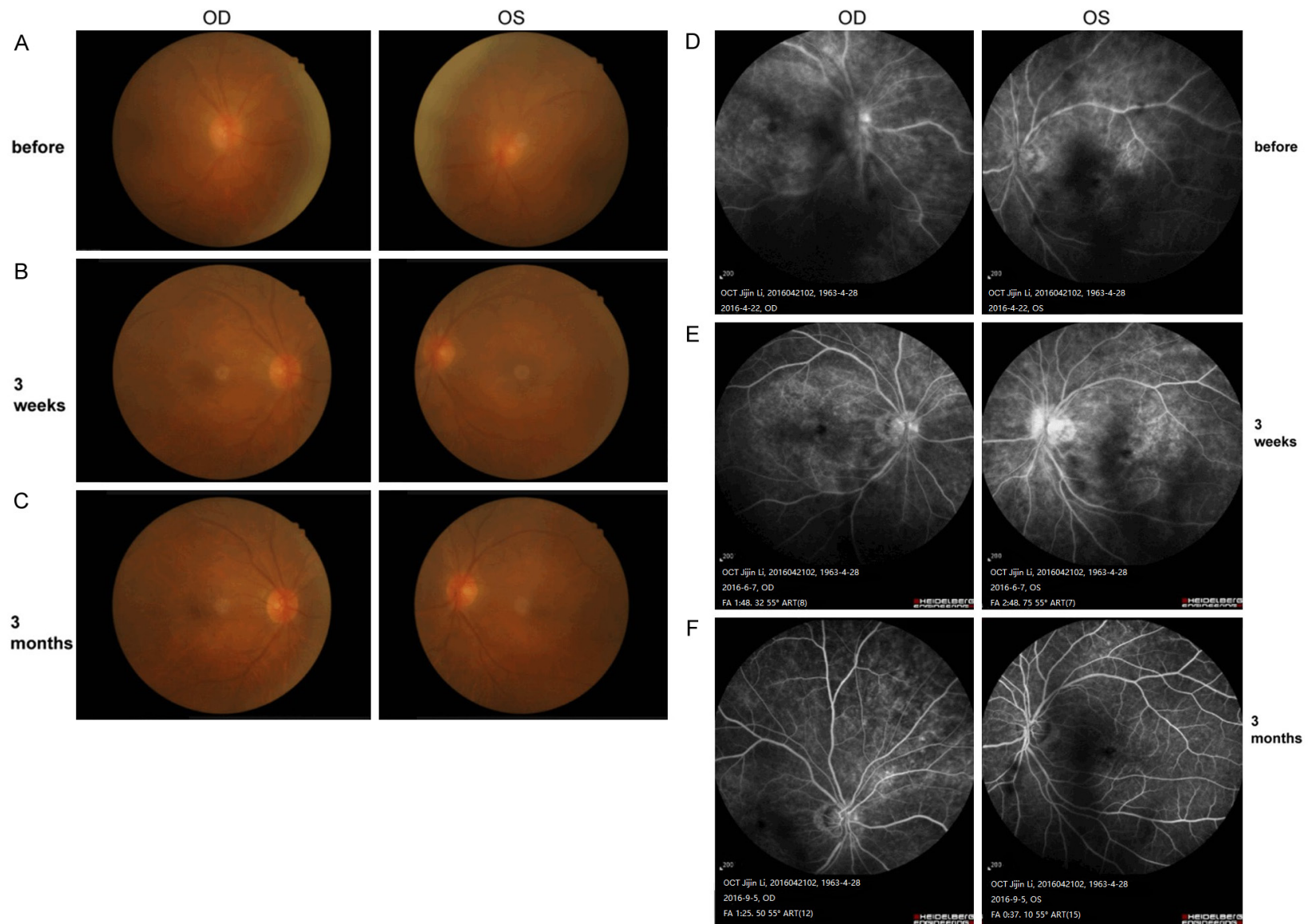
that no cutaneous deficiency was detected on this patient. Eye was the only affected organ. This patient was diagnosed with syphilitic panuveitis, retinal vasculitis and ophthalmoneuritis, and received 3 consecutive weekly intramuscular injections of IV penicillin G (2.4 million IU).

### Follow-up

Three weeks after penicillin G treatment, the patient's BCVAs were improved to 20/32 in his right eye and 20/50 in his left eye. There were no inflammatory cells in anterior chamber and 1+ vitreous cells. Fundusoscopic examination showed a decreased hyperaemia of the optic disc (**Figure 2B**). FFA revealed a reduction of vascular fluorescein leakage in both eyes (**Figure 2E**). Serum RPR was significantly decreased with an 8-fold reduction of the titer (1:8).

Three months after the initiation of antisiphilitic therapy with penicillin G, the patient's BCVAs were significantly improved with 20/25 in the right eye and 20/32 in the left eye. Anterior

Ocular syphilis with multiple eye lesions as the only manifestation



**Figure 2.** Fundus photograph (A-C) and fluorescein angiography (D-F) of the eyes before and after penicillin treatment. A. Color fundus of photograph showed a binocular blurred image and faintness of disc boundary, left eye was more severe. B. After treatment for 3 weeks, disc boundary was clearer than before. C. 3 months later, disc boundary can be clearly identified. D. FFA showed staining and leakage of vessel wall. Black plaque in the pictures were caused by vitreous opacity. E. The leakage was decreased after 3 weeks of penicillin treatment. F. FFA showed there was almost no dye leakage from the retinal vessels after 3 months of treatment.

## Ocular syphilis with multiple eye lesions as the only manifestation

chamber was quiet. And vitreous-opacity and optic-disc-hyperaemia were almost completely regressed. There were clear ocular fundus images in both eyes (**Figure 2C**). FFA showed a good retinal vascular morphology and an elimination of fluorescein leakage (**Figure 2F**). Serum RPR titer remained 1:8.

### Discussion

Syphilis, once thought to be eliminated with the usage of penicillin, appears to be increased in incidence and prevalence in the world [5]. It can affect the entire ocular structures and ocular syphilis can be the only presentation of syphilis [6]. Panuveitis and posterior uveitis are the best-known types among the clinical manifestations of ocular syphilis [3, 6]. In a review of 143 patients with ocular syphilis, posterior uveitis accounts for 55.2%, panuveitis accounts for 25.2%, and anterior/intermediate uveitis accounts for 19.6% [2]. Ocular syphilis can also act as papilledema, optic nerve atrophy, inflammatory disk swelling and gummatous optic disk. It is reported that optic disk swelling accounts for 13% in the posterior segment-involved patients [2, 7]. Stromal keratitis, scleritis and episcleritis have also been proved to occur [8, 9]. Chancres are the characters of primary syphilis. Secondary syphilis always presents with ulcers or skin damage, tertiary syphilis is marked by myocardial, nervous system involvement and ophthalmic lesions. While in our case, there was no typical skin lesion but complicated ocular disorders, which affect almost all ocular structures (including sclera, uveitis, retina and optic nerve) appeared in one patient. To our knowledge, such an ocular syphilis case has been rarely reported.

The present patient was diagnosed as ophthalmoneuritis (left eye) by outside eye center previously, and then was transferred to our hospital with decreased vision in both eyes and resolution of inflammation in left optic nerve. With apparent symptoms and signs of scleritis and anterior uveitis, we provided symptomatic treatment. But his visual acuity was persistently diminished, and another lesion in uveitis and retina appeared. This patient's ocular manifestations were so complex and changeable, while accompanied with intractable vision loss persistently, thus we suspected that his eye disease may be caused by other diseases. Systemic investigations revealed a high RPR

titer (1:64) and a positive serum TPPA. These findings strongly suggest a syphilis infection and diagnosis as ocular syphilis, although the patient denied his illness history at the beginning of medical inquiry.

With nonspecific clinical manifestations and pathognomonic features, it makes the diagnosis of ocular syphilis very elusive and is easy to make a misdiagnosis. It is worthwhile to note that vision loss is the most common clinical manifestation of ocular syphilis [10]. In our case, this patient presented a reduction in visual acuity throughout his clinical course which exactly corresponds with the above point. Scleritis is the first performance of this patient when he referred to our hospital. Jain et al. [11] did not find any cases of scleritis secondary to syphilis in the eyes with infectious scleritis. So the occurrence of syphilitic scleritis is rare, this is a special and notable point in our report. Another interesting aspect of our case is that as one ocular inflammation retreated, another one would flourish. This lesion affects entire ocular structure from sclera, ciliary body, uveitis to retina and optic nerve. Some experts point out that serologic testing for syphilis is needed particularly if ocular inflammation has special characteristics [12]. But in this case, our patient refused this medical examination.

Some experts pointed out that an immediate treatment should be taken to avoid further damage once the diagnosis of ocular syphilis is established, especially for a impurity sexual population, for a retinal inflammation and for poor response to steroids [12]. HIV coinfection should also be tested. Current treatment guidelines suggest that ocular syphilis should be treated as neurosyphilis with IV penicillin G. In this case, the patient's ocular inflammation is reduced and visual acuity is significantly improved after the treatment.

### Conclusion

We presented here a complicated ocular syphilis with multiple lesions of ocular structures. This case reminds our ophthalmologists to consider the possibility of syphilis infection when encountering an unusual ocular inflammation. Patients with unexplained vision loss and no response to routine treatments should be taken into account of infectious disease involving the eye to avoid misdiagnosis, such as leptospirosis, tuberculosis and syphilis.

## Ocular syphilis with multiple eye lesions as the only manifestation

### Disclosure of conflict of interest

None.

**Address correspondence to:** Xuxia Meng, Department of Ophthalmology, The Affiliated Hospital of Qingdao University, No. 16 Jiangsu Road, Qingdao 266555, Shandong, P. R. China. Tel: +86 0532-8291-9559; E-mail: 1245434690@qq.com

### References

- [1] Hook EW 3rd, Peeling RW. Syphilis control-a continuing challenge. *N Engl J Med* 2004; 351: 122-124.
- [2] Amaratunge BC, Camuglia JE and Hall AJ. Syphilitic uveitis: a review of clinical manifestations and treatment outcomes of syphilitic uveitis in human immunodeficiency virus-positive and negative patients. *Clin Exp Ophthalmol* 2010; 38: 68-74.
- [3] Kiss S, Damico FM and Young LH. Ocular manifestations and treatment of syphilis. *Semin Ophthalmol* 2005; 20: 161-167.
- [4] Moradi A, Salek S, Daniel E, Gangaputra S, Ostheimer TA, Burkholder BM, Leung TG, Butler NJ, Dunn JP and Thorne JE. Clinical features and incidence rates of ocular complications in patients with ocular syphilis. *Am J Ophthalmol* 2015; 159: 334-343.
- [5] Chen ZQ, Zhang GC, Gong XD, Lin C, Gao X, Liang GJ, Yue XL, Chen XS and Cohen MS. Syphilis in China: results of a national surveillance programme. *Lancet* 2007; 369: 132-138.
- [6] Yang P, Zhang N, Li F, Chen Y, Kijlstra A. Ocular manifestations of syphilitic uveitis in chinese patients. *Retinal* 2012; 32: 1906-1914.
- [7] Northey LC, Skalicky SE, Gurbaxani A and McCluskey PJ. Syphilitic uveitis and optic neuritis in Sydney, Australia. *Br J Ophthalmol* 2015; 99: 1215-1219.
- [8] Wilhelmus KR and Jones DB. Adult-onset syphilitic stromal keratitis. *Am J Ophthalmol* 2006; 141: 319-321.
- [9] Yoon KC, Im SK, Seo MS and Park YG. Neurosyphilitic episcleritis. *Acta Ophthalmol Scand* 2005; 83: 265-6.
- [10] Woolston SL, Dhanireddy S and Marrazzo J. Ocular syphilis: a clinical review. *Curr Infect Dis Rep* 2016; 18: 36.
- [11] Jain V, Garg P and Sharma S. Microbial scleritis-experience from a developing country. *Eye (Lond)* 2009; 23: 255-261.
- [12] Gaudio PA. Update on ocular syphilis. *Curr Opin Ophthalmol* 2006; 17: 562-566.