

Original Article

Efficacy of maxillary protraction correction in angle class III patients

Fan Zhang*, Yang Li*, Lili Guo

Department of Orthodontics, Daqing Oilfield General Hospital, Daqing, Heilongjiang Province, China. *Equal contributors and co-first authors.

Received April 18, 2018; Accepted May 28, 2018; Epub August 15, 2018; Published August 30, 2018

Abstract: Objective: The aim of this study was to investigate differences in effects between frame and fixed maxillary protraction in the treatment of Angle class III malocclusion patients, providing theoretical basis and reference for clinical treatment. Methods: A total of 34 patients with skeletal Angle class III malocclusion, having not received any orthodontic treatment, in the Orthodontics Department of Daqing Oilfield General Hospital, were selected as research subjects. According to the random number table method, patients were randomly divided into an experimental group and control group, with 17 cases in each group. The experimental group adopted frame internal fixation combined with facemask appliance for treatment of maxillary protraction, while the control group was treated with traditional fixation combined with facemask appliance for maxillary protraction treatment. After 1 year of post-treatment follow ups, treatment times and number of return visits were recorded in both groups. Efficacy was evaluated according to results of cephalometric analysis, before and after treatment. Results: Values of angle between sella-nasion line and nasion-point A line, angle between Frankfurt horizontal plane and mandibular plane, and nasolabial angle, after treatment, in the two groups were significantly higher than those before treatment (all $P < 0.05$). There were no statistical differences in improvement values of these indicators between the two groups (all $P > 0.05$). Values of angle between nasion-point A line and nasion-point B line, distance from sella-nasion line to median mandibular point, angle between sella-nasion line and nasion-point B line, and angle between long axis of lower incisor and mandibular plane, after treatment, in the two groups were significantly lower than before treatment (all $P < 0.05$). There were no statistical differences in improvement values of these indicators between the two groups (all $P > 0.05$). There were no statistically significant changes in cephalometric measurements and dental arch widths, before and after treatment, in the two groups (all $P > 0.05$). Treatment times and number of return visits in the experimental group were lower than the control group. Differences were statistically significant (both $P < 0.05$). Conclusion: Both frame and fixed maxillary protraction correction achieved good correction effects and obtained better stability. The former had less treatment times and fewer return visits. It is relatively efficient, practical, and worthy of clinical promotion.

Keywords: Skeletal angle class III, facemask appliance, maxillary protraction, malocclusion

Introduction

Skeletal Angle class III malocclusion is a complex facial disease, with occurrence related to genetic and environmental factors. Because of anatomical differences, it is characterized by mandibular protrusion, maxillary retraction, or combination of both [1]. If no treatment is performed, the trend of malformation will aggravate patient growth and development. It will not only affect oral function and facial appearance, but also affect the mental health of patients [2]. Prevalence of skeletal Angle class III malocclusion is quite different among different populations. Incidence of class III malocclu-

sion in ranges from 5% to 14%, of which 42% to 63% are characterized by insufficient maxillary development [3]. At present, the common clinical application of maxillary protraction is used to correct skeletal class III malocclusion during growth and development stages. It can restore normal overbite and overjet relationship and significantly improve facial development malformations. Its results have been recognized [4]. The maxillary protraction device can be divided into two basic parts: intraoral and extraoral. The intraoral appliance can be divided into a movable type and fixed type. Due to the short crown of children in mixed dentition period and difficulty of fixing the movable appli-

Maxillary protraction correction in angle class III patients

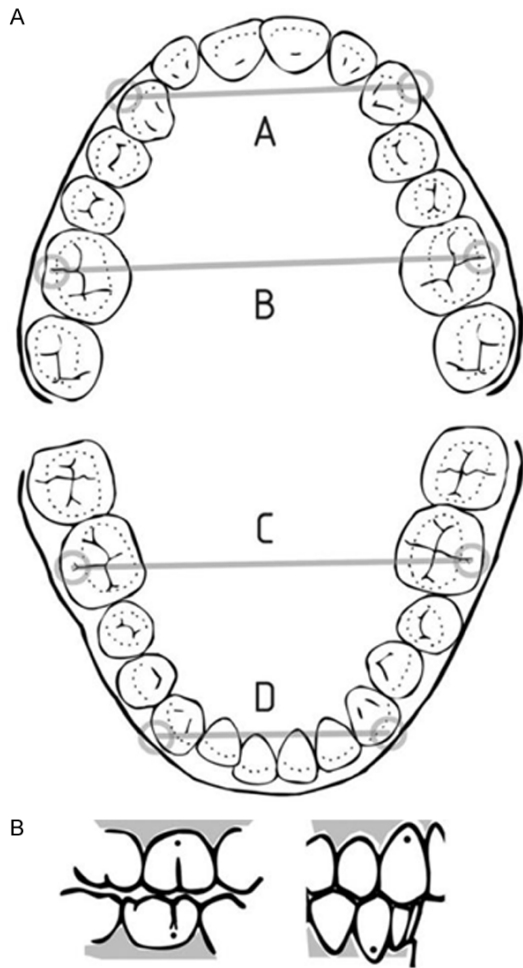


Figure 1. Method for measuring the width of dental arch. A, UC-C; B, UM-M; C, LM-M; D, LC-C. UC-C, maxillary inter-canine width; UM-M, maxillary first intermolar width; LM-M, mandibular first intermolar width; LC-C, mandibular inter canine width.

ance, fixed appliance is often used clinically [5]. However, traditional internal fixators have problems such as place difficulty, multi-solder joints, complex fabrication, and difficulty of oral hygiene maintenance. The frame internal fixator is relatively simple to fabricate and comfortable to wear [6]. In this present research, patients with Angle class III malocclusion were treated with frame and conventional internal fixators, respectively, to evaluate the efficacy of these two methods.

Materials and methods

Research objects

This study was approved by the Medical Ethics Committee of Daqing Oilfield General Hospital. All patients and their families provided informed

consent. A total of 34 patients with Angle class III malocclusion, in the Orthodontics Department of Daqing Oilfield General Hospital, from May 2013 to May 2016, were selected as research subjects.

Inclusion criteria: 1) Children in mixed dentition period; 2) No orthodontic treatment experience, no trauma or congenital malformations; and 3) Lateral cephalometrics were taken before correction.

Exclusion criteria: 1) History of cleft lip and palate; 2) Lack of more than 1 tooth per half arch; 3) Surgical history of oral and maxillofacial trauma; and 4) History of temporomandibular joint disease [7].

Research methods

Research subjects were divided into an experimental group and control group, according to the random number table method, with 17 cases in each group. The experimental group was treated with frame internal fixation combined with facemask appliance for maxillary protraction treatment [6]. The control group was treated by traditional fixation combined with facemask appliance for maxillary protraction [8]. First, for the experimental group, the frame appliance was fabricated according to the following method: bands were tried on the first premolar and the first molar, then the refractory model was produced. Bands for maxillary first permanent molar, second deciduous molars, first deciduous molars (or first premolar), maxillary palatine frame, and traction hook were made from 1.2 mm stainless steel wire and welded together using silver welding [5]. Second, the Frankel III functional appliance was used for the control group, consisting of lip bumper, cheek panel, palatal arch, upper anterior teeth lingual arch, and lower lip arch. The upper lip bumper should leave the alveolar 2.5 mm from the upper edge of the turning point of mucosa [6]. All patients had a 1-week initial trial to wear and test the tenderness and comfort of the appliance. Wearing time was gradually extended. Other than eating, strenuous exercise, and language training courses, appliances were worn at least 14 hours per day, mainly in the daytime.

Observation indexes

Cephalometer radiographs were taken by Siemens 128-row CT (SOMATOM Definition Flash),

Maxillary protraction correction in angle class III patients

Table 1. Comparison of general data between two groups ($\bar{x} \pm sd$)

	Experimental group	Control group	t/X ²	P
Gender (male/female)	9/8	11/6	0.486	0.486
Age (year old)	10.3±1.6	9.9±1.7	0.417	0.691

1 year before and after treatment. Cephalometric analysis was performed by the same doctor to evaluate effects of the two methods of maxillary protraction on a patient skeletal structures and soft tissues. Treatment times and number of return visits were recorded for both groups.

Cephalometric analysis indicators included: 1) Angle between sella-nasion line and nasion-point A line (SNA); 2) Angle between sella-nasion line and nasion-point B line (SNB); 3) Distance from sella-nasion line to median mandibular point (SND); 4) Angle between nasion-point A line and nasion-point B line (ANB); 5) Wits value; 6) Upper incisor to lower incisor angle (U_1-L_1); 7) Angle between Frankfurt horizontal plane and mandibular plane (FMA); 8) Distance from SN plane to mandibular plane (SN-MP); 9) Distance from SN plane to palatal plane (SN-PP); 10) Distance from nasion to anterior point on maxillary bone (N-ANS); 11) Distance from menton to anterior point on maxillary bone (ANS-Me); 12) Angle between long axis of upper incisor and SN plane (U_1-SN); 13) Angle between long axis of lower incisor and mandibular plane (IMPA); 14) Nasolabial angle (NLA); 15) Upper lip protrusion (ULP); and 16) Lower lip protrusion (LLP).

Dental arch width measurement

Dental arch widths of each patient were recorded using digital caliper measurements: 1) Maxillary inter-canine width (UC-C); 2) Maxillary first intermolar width (UM-M); 3) Mandibular first intermolar width (LM-M); and 4) Mandibular inter canine width (LC-C) as shown in **Figure 1**.

Statistical analysis

Data were analyzed by STATA 14.0 software and plotted by Graphpad Prism 7.0. Measurement data are expressed as mean \pm standard deviation ($\bar{x} \pm sd$). Measurement data with normal distribution, such as changes

before and after treatment, were detected using paired t-tests. Differences of indexes, before and after treatment, within groups were compared using t-tests. Count data are represented in terms of number of cases. Differences between groups were analyzed using Chi-square analysis or Fisher's exact test. $P < 0.05$ was considered statistically significant.

Results

Comparison of two groups of general data

The total of 34 cases of skeletal Angle class III malocclusion included 20 boys and 14 girls, aged 7-14, with an average age of 10.1 ± 1.6 years. There were no significant differences in age and gender between the two groups (both $P > 0.05$), as shown in **Table 1**.

Cephalometric analysis results

There were no statistically significant differences in indexes of cephalometric analysis between the experimental group and control group before treatment (all $P > 0.05$). Compared with those before treatment, values of SNA, FMA, and NLA increased in the two groups, after treatment, while values of ANB, SND, SNB, and IMPA decreased. Differences between these indexes were statistically significant (all $P < 0.05$). There were no statistically significant changes in measured values of the other indicators (all $P > 0.05$) as shown in **Table 2**.

Differences in cephalometric values of the two groups, before and after treatment, were calculated and compared between the groups. There were no statistically significant differences in all indicators (all $P > 0.05$) as shown in **Table 3**.

Changes in dental arch width

Changes in dental arch width in the two groups, before and after treatment, are shown in **Table 4**. Width of the maxillary arch and mandibular arch in the two groups, after treatment, increased to a certain extent compared with before treatment, but differences were not statistically significant (all $P > 0.05$). Comparison of changes in dental arch width, before and after treatment, are shown in **Figure 2**. The

Maxillary protraction correction in angle class III patients

Table 2. Comparison of cephalometric values before and after treatment of two groups ($\bar{x} \pm sd$)

	Experimental group		Control group	
	Before treatment	After treatment	Before treatment	After treatment
SNA (°)	77.53±4.22	83.17±3.76 [#]	77.49±4.27	82.68±3.91 [#]
SNB (°)	84.48±1.28	81.46±1.35 [#]	84.57±1.31	81.72±1.43 [#]
SND (mm)	76.12±0.71	75.61±0.74 [#]	76.34±0.69	75.35±0.69 [#]
ANB (°)	2.36±2.11	-2.14±2.04 [#]	2.38±1.98	-2.25±1.97 [#]
Wits	-4.33±0.54	-4.21±0.57	-4.29±0.57	-4.23±0.50
U ₁ -L ₁ (°)	130.08±8.16	134.13±7.35	130.12±8.23	133.89±7.41
FMA (°)	28.94±0.41	29.17±0.43 [#]	28.76±0.52	29.12±0.46 [#]
SN-MP (mm)	36.24±3.87	33.36±3.63	36.31±3.65	34.13±3.74
SN-PP (mm)	3.57±0.49	3.64±0.55	3.63±0.54	3.68±0.51
N-ANS (mm)	47.95±2.16	47.52±2.11	48.10±2.19	47.47±2.09
ANS-Me (mm)	60.18±5.35	54.60±4.48	60.23±5.46	56.73±4.53
U ₁ -SN (°)	108.10±7.30	114.64±8.12	107.52±7.49	115.83±8.19
IMPA (°)	84.12±0.47	83.79±0.52 [#]	84.57±0.71	83.24±0.56 [#]
NLA (°)	87.24±18.36	94.36±16.24 [#]	86.75±17.90	93.56±16.80 [#]
ULP (mm)	4.31±1.28	6.04±2.13	4.27±1.37	5.79±2.42
LLP (mm)	6.15±1.46	6.27±1.52	6.17±1.61	6.32±1.18

Note: Compared with before treatment, [#]P<0.05. SNA, angle between sella-nasion line and nasion-point A line; SNB, angle between sella-nasion line and nasion-point B line; SND, distance from sella-nasion line to median mandibular point; ANB, angle between nasion-point A line and nasion-point B line; U₁-L₁, upper incisor to lower incisor angle; FMA, angle between Frankfurt horizontal plane and mandibular plane; SN-MP, distance from SN plane to mandibular plane; SN-PP, distance from SN plane to palatal plane; N-ANS, distance from nasion to anterior point on maxillary bone; ANS-Me, distance from menton to anterior point on maxillary bone; U₁-SN, angle between long axis of upper incisor and SN plane; IMPA, angle between long axis of lower incisor and mandibular plane; NLA, nasolabial angle; ULP, upper lip protrusion; LLP, lower lip protrusion.

maxillary dental arch had a greater change than the mandibular dental arch. The maxillary dental arch width in experimental group was smaller than that in control group. Differences were not statistically significant (all P>0.05).

Treatment times and number of return visits

Treatment times and number of return visits in the experimental group were lower than the control group and differences were statistically significant (both P<0.05), as shown in **Table 5**.

Discussion

Class III malocclusion is a complex maxillofacial disease involving a variety of skeletal and dental compensatory factors, including the skull base, maxilla, and mandible [9]. An important factor determining the success rate of orthodontic treatment is the time of treatment. Domestic and foreign experts generally recommend that facemask treatment should be started at ages of 6-8 years, when the first maxillary molar and incisor grows, or at early mixed dentition [10]. Cases selected for this

present study were all in this period. Regardless of whether there is a maxillary arch stenosis or not, maxillary protraction facemask treatment has been a commonly used method for correction of Class III malocclusion, at home and abroad [11].

There have been many reports on the treatment of skeletal Angle class III malocclusion during mixed dentition using maxillary protraction. Vaughn et al. used frame anterior traction to treat children with class III malocclusion in early dentition [12]. After one year of treatment, skull changes of expansion and non-expansion facemask treatment in the experimental group, compared with control group, were mainly the forward and longitudinal displacement of the maxilla and downward and backward rotation of the mandible. SNA angle increased by 3.02° and 2.78° and the distance from nasion to subspinale increased from 2.41 mm to 2.49 mm, respectively. Subspinale moved forward by 2.63 mm and 2.43 mm and the maxillary to skull base increased by 1.67 mm and 1.41 mm, respectively. In orthodontic treatment, impro-

Maxillary protraction correction in angle class III patients

Table 3. Comparison of difference of cephalometric values between two groups before and after treatment ($\bar{x} \pm sd$)

	Experimental group	Control group	t	P
Δ SNA ($^{\circ}$)	5.64 \pm 4.25	5.19 \pm 3.41	1.831	0.083
Δ SNB ($^{\circ}$)	-3.02 \pm 1.26	-2.85 \pm 1.25	1.372	0.195
Δ SND (mm)	-0.51 \pm 0.76	-0.99 \pm 0.62	1.984	0.076
Δ ANB ($^{\circ}$)	-4.52 \pm 1.15	-4.63 \pm 2.21	0.675	0.512
Δ Wits	0.12 \pm 0.46	0.06 \pm 0.49	2.058	0.065
Δ U ₁ -L ₁ ($^{\circ}$)	4.05 \pm 3.15	3.77 \pm 4.11	0.439	0.673
Δ FMA ($^{\circ}$)	0.23 \pm 0.34	0.36 \pm 0.39	0.544	0.602
Δ SN-MP (mm)	-2.88 \pm 1.62	-2.18 \pm 1.89	0.841	0.417
Δ SN-PP (mm)	0.07 \pm 0.37	0.05 \pm 0.45	0.658	0.523
Δ N-ANS (mm)	-0.43 \pm 2.11	-0.63 \pm 2.31	1.071	0.296
Δ ANS-Me (mm)	-5.58 \pm 3.25	-3.51 \pm 4.09	1.674	0.118
Δ U ₁ -SN ($^{\circ}$)	6.53 \pm 4.51	8.34 \pm 5.50	0.160	0.875
Δ IMPA ($^{\circ}$)	-0.33 \pm 0.43	-1.33 \pm 0.47	0.559	0.592
Δ NLA ($^{\circ}$)	7.12 \pm 3.42	6.81 \pm 3.94	0.518	0.627
Δ ULP (mm)	1.73 \pm 1.10	1.52 \pm 1.03	1.164	0.263
Δ LLP (mm)	0.12 \pm 1.06	0.15 \pm 1.18	1.117	0.284

Note: Δ means difference. SNA, angle between sella-nasion line and nasion-point A line; SNB, angle between sella-nasion line and nasion-point B line; SND, distance from sella-nasion line to median mandibular point; ANB, angle between nasion-point A line and nasion-point B line; U₁-L₁, upper incisor to lower incisor angle; FMA, angle between Frankfurt horizontal plane and mandibular plane; SN-MP, distance from SN plane to mandibular plane; SN-PP, distance from SN plane to palatal plane; N-ANS, distance from nasion to anterior point on maxillary bone; ANS-Me, distance from menton to anterior point on maxillary bone; U₁-SN, angle between long axis of upper incisor and SN plane; IMPA, angle between long axis of lower incisor and mandibular plane; NLA, nasolabial angle; ULP, upper lip protrusion; LLP, lower lip protrusion.

Table 4. Comparison of changes in dental arch width in two groups before and after treatment (mm; $\bar{x} \pm sd$)

	Experimental group		Control group	
	Before treatment	After treatment	Before treatment	After treatment
UC-C	28.15 \pm 2.61	29.76 \pm 2.59	28.24 \pm 2.37	30.14 \pm 2.72
UM-M	42.64 \pm 3.63	44.53 \pm 3.58	42.81 \pm 4.58	44.96 \pm 3.30
LC-C	23.79 \pm 2.69	24.93 \pm 2.70	23.82 \pm 2.53	24.16 \pm 2.41
LM-M	40.47 \pm 3.32	41.33 \pm 3.37	40.41 \pm 4.32	40.97 \pm 3.28

Note: UC-C, maxillary inter-canine width; UM-M, maxillary first intermolar width; LM-M, mandibular first intermolar width; LC-C, mandibular inter canine width.

vement of the soft tissue profile is very important. Elnagar et al. used bone-anchored maxillary traction to treat patients with class III malocclusion [13]. In addition to significant maxillary moving forward, three-dimensional soft tissue analysis revealed significant soft tissue improvement. Specifically, a positive shift in the sagittal plane occurred in the upper

lip, cheeks, and middle of the face. A significant negative change occurred in the sagittal plane of the lower lip and chin region. In this study, SNA and FMA increased and SNB decreased in both groups, suggesting that maxillary and mandibular positions changed, indicating that the purpose of orthopedic treatment was achieved in both groups [14].

In addition, the increased U₁-SN and decreased ANB and IMPA of research subjects showed that the upper incisor leaned forward, the lower incisor leaned back, and the occlusion relationship improved significantly [15]. The intraoral appliance of maxillary protraction was fixed on the teeth, so that orthodontic force produced by the anterior traction was mainly via teeth transfer to the jaw. However, treatment principles of the two kinds of internal fixation are different. Frankel III functional appliance therapy relieved the limitations of development of upper dental arch by perioral muscles through the buccal shield and lip bumper and stretched the periosteum at the vestibular mucosal transition to stimulate osseous hyperplasia, thereby stimulating growth of alveolar bone and basal bone [4]. Blood circulation of the soft tissue was improved via massage by the lip bumper and buccal screen, so that teeth moving in parallel with the alveolus while the dispersing force of the lips was moved from the maxilla via the upper lip pad, and the force of the upper lip was transmitted to the lower jaw through the appli-

ance due to the device matched closely with the dental arch [16]. In the frame-type appliance, the occlusion relationship was constructed by retracting the mandible to make the condyle to the final position, thus, the lip was closed with minimum stress [17]. In this study, Δ U₁-SN of the experimental group was (6.53 \pm 4.51) $^{\circ}$ and Δ U₁-SN of the control group was

Maxillary protraction correction in angle class III patients

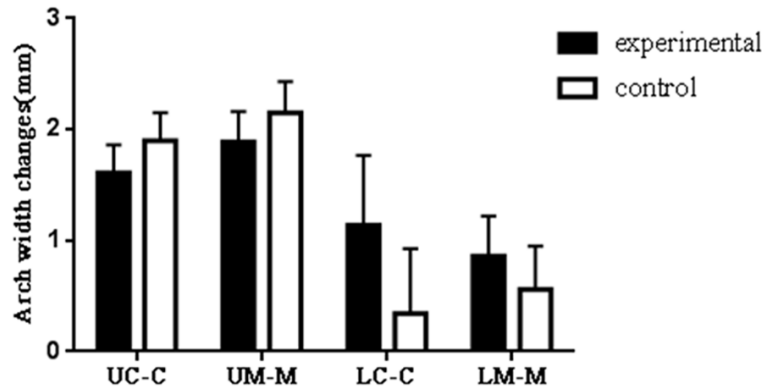


Figure 2. Change of dental arch width before and after orthodontic treatment in the two groups (mm).

Table 5. Comparison of treatment times and number of return visits between two groups ($\bar{x} \pm sd$)

	Experimental group	Control group	t	P
Treatment time (month)	7.1±2.3	9.5±4.1	2.073	0.048
Number of return visits	8.4±2.6	10.1±3.5	2.286	0.034

(8.34±5.50)°, suggesting that for patients with compensatory upper incisors occurring prior to treatment, the frame-type appliance could prevent upper incisors from leaning forward to a certain extent, reducing the side effects of frontal traction. This result is consistent with the study reports of Al-Mozany and Kim et al. [18, 19].

A Japanese study reported that the lateral width of bones of dental arch and mandibular maxillary base in patients with untreated class III malocclusion gradually increased between the ages of 10-14 years [20]. During this period, the width of the mandible increased more than the growth of maxilla. Class III malocclusion research subjects lower jaws tended to lean toward the lingual surface and the mandibular teeth tended to buccal direction due to the limitation of maxillary development. Researchers believed that rapid maxillary expansion should be considered before or during treatment of class III malocclusion patients undergoing facemask treatment [21]. Other studies have suggested that the inward component of the maxillary protraction leads to a tendency of compression and narrowing in the anterior part of the palate during traction. This tendency is irrelevant to the direction of traction [22, 23]. However, some scholars have

held an opposite view that the tiny forward movement of the internal appliance leads to lateral expansion of dental arch and lateral displacement occurs while the upper jaw is moving forward, indicating an enlargement of the dental arch [12]. Results of before and after treatment in this present study show that maxillary and mandibular arch widths of the two groups, after treatment, were all increased to some extent compared to before treatment. Changes in the maxillary arch were larger than those in mandibular arch and changes in width of maxillary dental arch in the experimental group were smaller than the control group. This suggests that maxillary growth was faster than mandible growth and that the occlusion

relationship was improved. Frankel III functional correction method seems to be a better choice.

Clinically, selection of intraoral devices can be based on the choice of different retention devices depending on whether maxillary and mandibular posterior teeth are coordinated, the wearing path of anchorage molar, and crowding degree of upper dentition [15, 21]. Disadvantages of the Frankel III functional appliance include the bulky size, complex fabrication, and requirement of good compliance from patients [24]. In addition, it cannot be applied to adult patients after growth has stopped. It cannot be used for patients with teeth movement and congestion [25]. In comparison, the frame-type appliance as a reduced size and is easier to wear during the day and night [5]. The longer the appliance is worn, the faster and better the correction effects are. In this research, treatment times and number of return visits of patients in the experimental group were significantly less than those in control group. The frame-type appliance is simple to fabricate and easy to fix, requiring a shorter time to achieve desired effects. It is relatively efficient, simple, practical, and worthy of clinical promotion. However, the sample size for this research was too small.

Maxillary protraction correction in angle class III patients

Research with further accumulation and a longer study term is needed to arrive at a more precise conclusion [26].

In summary, the occlusion relationship of patients with Angle III malocclusion can be improved by frame-type and fixed maxillary protraction, each having its own characteristics and both obtaining good results.

Disclosure of conflict of interest

None.

Address correspondence to: Lili Guo, Department of Orthodontics, Daqing Oilfield General Hospital, No. 9 Zhongkang Street, Sartu District, Daqing 163001, Heilongjiang Province, China. Tel: +86-0459-5805362; E-mail: guolili733@126.com

References

- [1] Elnagar MH, Elshourbagy E, Ghobashy S, Khe-dr M and Evans CA. Dentoalveolar and arch dimension changes in patients treated with miniplate-anchored maxillary protraction. *Am J Orthod Dentofacial Orthop* 2017; 151: 1092-1106.
- [2] Arruda MBP. Angle class III malocclusion with anteroposterior and vertical discrepancy in the final stage of growth. *Dental Press J Orthod* 2017; 22: 109-118.
- [3] Li C, Cai Y, Chen S and Chen F. Classification and characterization of class III malocclusion in Chinese individuals. *Head Face Med* 2016; 12: 31.
- [4] Azamian Z and Shirban F. Treatment options for class III malocclusion in growing patients with emphasis on maxillary protraction. *Scientifica (Cairo)* 2016; 2016: 8105163.
- [5] Yang R, Jiang Y and Li H. Traction of impacted canines in a skeletal class III malocclusion. *Am J Orthod Dentofacial Orthop* 2017; 152: 578.
- [6] Bichara LM, Aragon ML, Brandao GA and Normando D. Factors influencing orthodontic treatment time for non-surgical class III malocclusion. *J Appl Oral Sci* 2016; 24: 431-436.
- [7] Liu CY, Lu HY, Wang W, Ma WS, Hu XY and Chen WJ. Comparison of frame and fixed protraction appliances in the treatment of skeletal III malocclusion in mixed dentition. *J Prac Stom* 2014; 227-231.
- [8] Turley PK. Does the Frankel function regulator III affect maxillary growth over the short term? *Am J Orthod Dentofacial Orthop* 2015; 147: 296-297.
- [9] Ferreira JTL, Romano FL, Sasso Stuaní MB, Assed Carneiro FC and Nakane Matsumoto MA. Traction of impacted canines in a skeletal class III malocclusion: a challenging orthodontic treatment. *Am J Orthod Dentofacial Orthop* 2017; 151: 1159-1168.
- [10] Ferreira FP, Goulart MD, de Almeida-Pedrin RR, Conti AC and Cardoso MA. Treatment of class III malocclusion: atypical extraction protocol. *Case Rep Dent* 2017; 2017: 4652685.
- [11] Smyth RSD and Ryan FS. Early treatment of class III malocclusion with facemask. *Evid Based Dent* 2017; 18: 107-108.
- [12] Vaughn GA, Mason B, Moon HB and Turley PK. The effects of maxillary protraction therapy with or without rapid palatal expansion: a prospective, randomized clinical trial. *Am J Orthod Dentofacial Orthop* 2005; 128: 299-309.
- [13] Elnagar MH, Elshourbagy E, Ghobashy S, Khe-dr M, Kusnoto B and Evans CA. Three-dimensional assessment of soft tissue changes associated with bone-anchored maxillary protraction protocols. *Am J Orthod Dentofacial Orthop* 2017; 152: 336-347.
- [14] Wendl B, Stampfl M, Muchitsch AP, Droschl H, Winsauer H, Walter A, Wendl M and Wendl T. Long-term skeletal and dental effects of face-mask versus chincup treatment in class III patients: a retrospective study. *J Orofac Orthop* 2017; 78: 293-299.
- [15] Moshkelgosha V, Raoof A, Sardarian A and Salehi P. Photogrammetric comparison of facial soft tissue profile before and after protraction facemask therapy in class III children (6-11 Years Old). *J Dent (Shiraz)* 2017; 18: 7-16.
- [16] Zhao G, Li S and Chang BB. Soft tissue profile changes by Frankel-III appliance on correcting Angle class III malocclusion in mixed dentition. *Shanghai Kou Qiang Yi Xue* 2011; 20: 201-203.
- [17] Cozza P, Marino A and Mucedero M. An orthopaedic approach to the treatment of class III malocclusions in the early mixed dentition. *Eur J Orthod* 2004; 26: 191-199.
- [18] Al-Mozany SA, Dalci O, Almuzian M, Gonzalez C, Tarraf NE and Ali Darendeliler M. A novel method for treatment of class III malocclusion in growing patients. *Prog Orthod* 2017; 18: 40.
- [19] Kim H, Sakamoto T, Yamaguchi H and Sueishi K. Evaluation of chewing movement in skeletal class III patients with orthognathic treatment. *Bull Tokyo Dent Coll* 2017; 58: 213-221.
- [20] Chen F, Terada K, Wu L and Saito I. Dental arch widths and mandibular-maxillary base width in class III malocclusions with low, average and high MP-SN angles. *Angle Orthod* 2007; 77: 36-41.
- [21] Maino G, Turci Y, Arreghini A, Paoletto E, Siciliani G and Lombardo L. Skeletal and dentoalveolar effects of hybrid rapid palatal expansion and facemask treatment in growing skeletal

Maxillary protraction correction in angle class III patients

- class III patients. *Am J Orthod Dentofacial Orthop* 2018; 153: 262-268.
- [22] Uysal T, Usumez S, Memili B and Sari Z. Dental and alveolar arch widths in normal occlusion and class III malocclusion. *Angle Orthod* 2005; 75: 809-813.
- [23] Park JH, Bayome M, Zahrowski JJ and Kook YA. Displacement and stress distribution by different bone-borne palatal expanders with face-mask: a 3-dimensional finite element analysis. *Am J Orthod Dentofacial Orthop* 2017; 151: 105-117.
- [24] Yan BX, Wang XD and Zhou YH. Treatment effectiveness of the Frankel function regulator on class III malocclusion. *Am J Orthod Dentofacial Orthop* 2015; 147: 9.
- [25] Yang X, Li C, Bai D, Su N, Chen T, Xu Y and Han X. Treatment effectiveness of Frankel function regulator on the class III malocclusion: a systematic review and meta-analysis. *Am J Orthod Dentofacial Orthop* 2014; 146: 143-154.
- [26] Park JH, Lee KS, Lee JY and Shin SW. Fabricating a maxillary obturator using an intraoral digital impression: a case history report. *Int J Prosthodont* 2017; 30: 266-268.