

## Case Report

# Recurrent atrial tachycardia after catheter ablation due to right atrial diverticulum

Hai-Xia Xu, Yin-Hao Huang, Qi Lu

Department of Cardiology, Affiliated Hospital of Nantong University, No. 20 Xisi Road, Chongchuan District, Nantong 226001, China

Received September 24, 2018; Accepted June 10, 2019; Epub July 15, 2019; Published July 30, 2019

**Abstract:** Right atrial diverticulum being associated with arrhythmia, such as supraventricular tachycardia or atrial flutter/fibrillation presents challenges to catheter ablation. Here, a case of a 62-year-old man with recurrent palpitations is presented. This patient had undergone atrial fibrillation cryoballoon ablation and relapsed six months later. Atrial tachycardia was induced unexpectedly during electrophysiological study. The electroanatomic mapping and cardiac multidetector-row computed tomography revealed a diverticulum structure within the right atrium. To cure the atrial tachycardia originating from the RA diverticulum, radiofrequency ablation was successfully performed.

**Keywords:** Atrial tachycardia, right atrial diverticulum, radiofrequency catheter ablation

### Introduction

Catheter ablation of supraventricular tachycardia, especially atrial fibrillation (AF) is currently considered a reasonable alternative to pharmacological therapy and an increasing number of such procedures are conducted worldwide [1]. Right atrial (RA) diverticulum is rare, and in some cases is associated with arrhythmia, such as supraventricular tachycardia and atrial flutter/fibrillation [2-5]. The presence of minor abnormalities presents challenges to catheter ablation. Here, a case of a man with atrial tachycardia originating from the RA diverticulum is described and the patient was cured through radiofrequency (RF) ablation.

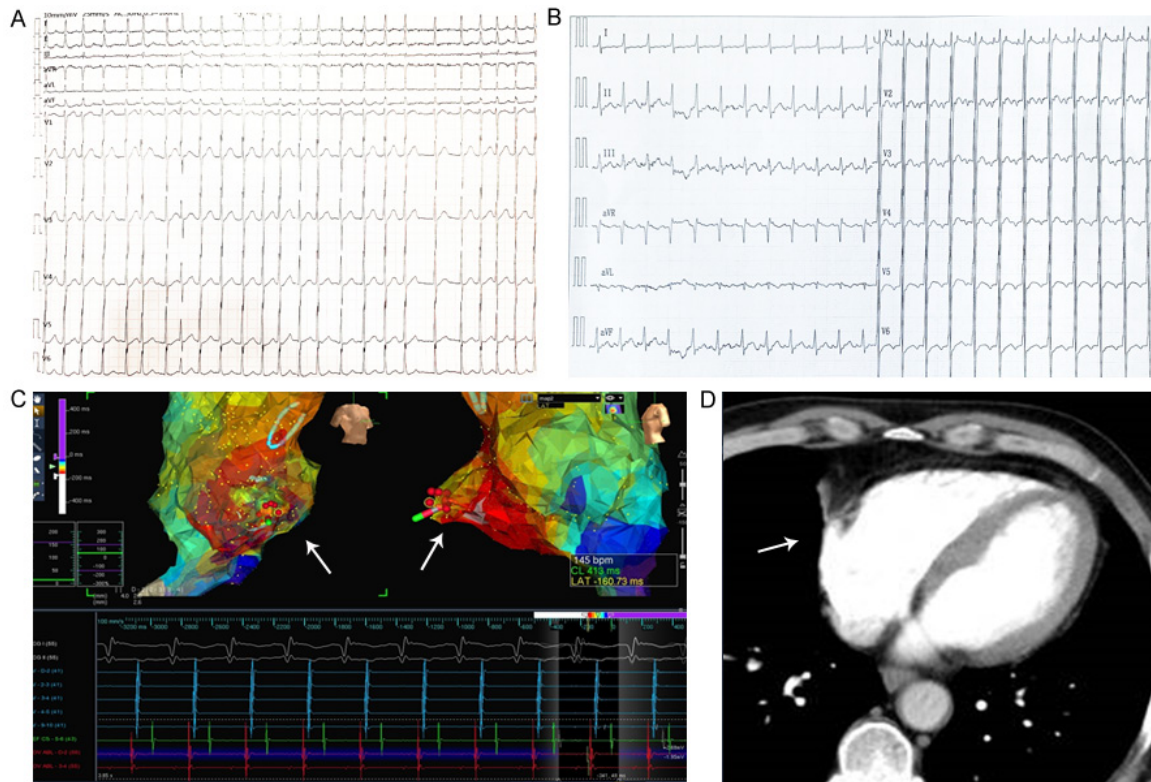
### Case report

A 62-year-old man without any medical history reported recurrent palpitations and dyspnea for 2 years. Electrocardiogram showed paroxysmal AF (**Figure 1A**) and frequent premature atrial contractions. Clinical examination, chest X-ray and echocardiogram did not suggest the presence of structural heart disease. Having given informed consent, the patient was scheduled for cryoballoon ablation for paroxysmal

AF. Oral anticoagulation drug and amiodarone were administered for 3 months after the procedure. However, six months later, the patient experienced palpitation again and 12-lead electrocardiogram revealed paroxysmal AF and atrial flutter (2:1) (**Figure 1B**). To identify the mechanism of supraventricular tachycardia, an electrophysiological study and RF catheter ablation were conducted under the 3-dimensional geometrical mapping of left atria and pulmonary veins (PVs) through the Ensite NavX mapping system (St. Jude Medical, Minneapolis, MN).

Additional RF ablation was initially performed at the left superior pulmonary vein antrum based on the residual pulmonary vein potentials revealed by Lasso electrode. Pulmonary vein isolation (PVI) was validated completely. While electrophysiological study was continued, an unexpected atrial tachycardia (AT) at rate of 145 beats/min was induced easily by programmed electrical stimulation with S1/S2/S3 extra-stimulus of 500/300/200 ms. To identify the earliest activation mechanism, 3-dimensional geometrical geometry of the RA was constructed through a non-contact mapping system (Ensite System). Like in previous proce-

## AT from RA diverticulum



**Figure 1.** A. ECG showed atrial fibrillation. B. ECG showed atrial Flutter (2:1). C. Non-contact mapping system revealed the earliest activation of atrial tachycardia originating from the margin area of the right atrial diverticulum (white arrow). D. cardiac multi-detector-row computed tomography showing a diverticulum (white arrow).

dures, a CoolFlex catheter with a 4 mm deflectable tip, an embedded thermistor and inter-electrode spacing of 2-5-2 mm (St. Jude Medical, Minneapolis, MN, Baldwin Park, CA, USA; EP Technologies Inc., San Jose, CA, USA) was inserted for mapping and ablation. During the mapping process, an unexpected movement of the mapping catheter was observed and a diverticulum structure in the middle anterior wall of the RA was revealed. This structure exhibited an enlarged expansion and shrinkage with each cardiac cycle. Activation mapping revealed a centrifugal activation pattern from the site (**Figure 1C**). The cardiac 64-slice of multidetector-row computed tomography (MDCT) was performed before the ablation procedure, but no abnormality was reported. The structure of the MDCT was then carefully re-studied, and a diverticulum structure at the anterior wall of right atrium (RA) was demonstrated through the volume-rendering reconstruction computed tomography (**Figure 1D**). Combined with 3-D mapping, the AT was considered originated from the marginal area of the RA diverticulum. Considering the thin wall

of the diverticulum, careful manipulation was required to avoid cardiac perforation. Finally, a non-irrigated RF ablation application at this site with a target temperature of 43°C and power output of 15-20 W successfully terminated the AT. No AT was induced thereafter with or without intravenous administration of isoproterenol during an observational period of 30 minutes. No complications occurred during and after the procedure. So far, the patient has been followed up for more than 1 year and no recurrence of any atrial arrhythmia was reported.

### Discussion

Right atrial diverticulum is a rare congenital malformation, and various forms of arrhythmia related to RA diverticulum have been reported, including atrial flutter/fibrillation, atrial tachycardia, and atrioventricular reentry tachycardia [3-5]. RA diverticulum can be detected through echocardiography or magnetic resonance imaging, and surgical or catheter ablation was tried in some cases [6]. Characteristically, it exhibits similar histological construction as nor-

## AT from RA diverticulum

mal atrial wall and the exact pathophysiological mechanism is still unclear. Here, a case of a patient with RA diverticulum who presented AT and received RF catheter ablation is discussed.

Non-contact mapping with a multielectrode array has long been established and extensively used to map arrhythmias. This is a unique technique for identifying the site of the earliest activation as well as the activation pattern [7]. In this case, the electroanatomic mapping and cardiac MDCT revealed an unusual structure within the RA. AT origin was finally identified from the margin of the structure by the precise reconstruction of the diverticulum geometry. The mechanism of this particular AT remains unclear. Based on its focal activation mode, this tachycardia might be explained by triggered activity. It has yet to be determined if it is a congenitally abnormal structure or a diseased structure protruding from inside the endocardial contour.

The etiology of recurrent palpitations for this patient may include repeated attacks of atrial tachycardia originating from the RA diverticulum. Echocardiography or cardiac MDCT might be the first clue for these anomalies, but it isn't unordinary to be neglected. An unexpected movement during mapping catheter-on fluoroscopy may be the next clue for reaching that conclusion. Apart from the electroanatomic mapping, cardiac MDCT or Magnetic Resonance Imaging could help confirm the presence of these structures as well. The presence of RA diverticulum increases the challenge for supra-ventricular tachycardia RF ablation. Better localization by MDCT and meticulous RF ablation around the diverticulum are crucial for successful treatment of the AT. While conducting catheter ablation adjacent to this kind of structure, it should be kept in mind that the diverticulum is a "thin-ice" during the mapping and ablation.

### Acknowledgements

This study was approved by the Science Project of Nantong (No. MS12017003-7).

### Disclosure of conflict of interest

None.

**Address correspondence to:** Dr. Qi Lu, Department of Cardiology, Affiliated Hospital of Nantong University, No. 20 Xisi Road, Chongchuan District, Nantong 226001, China. Tel: +86-513-85052504; Fax: +86-513-85052504; E-mail: luqint@126.com

### References

- [1] Berger T, Alber H. Radiofrequency ablation as initial therapy in paroxysmal atrial fibrillation. *N Engl J Med* 2013; 368: 478.
- [2] Kurian KC, Nguyen M and Wilke N. Right atrial diverticulum - a rare cause of atrial fibrillation. *Clin Cardiol* 2007; 30: 631.
- [3] Liu H, Wei L, Xia L and Wang C. An arrhythmogenic right atrial diverticulum resected through a minimally invasive approach without cardiopulmonary bypass. *J Am Coll Cardiol* 2013; 62: e21.
- [4] Tsai WC, Chu CS, Wu DK, Lai WT and Lee KT. Successful catheter ablation of typical atrial flutter in a patient with a long vertical and diverticulum-like cavotricuspid isthmus. *Pacing Clin Electrophysiol* 2008; 31: 1653-1655.
- [5] Chiu SN, Lin JL, Chang CC, Sun LJ, Dai ZK, Tsai SK, Lin SM, Wang JK and Wu MH. Radiofrequency ablation of a concealed right anterior accessory pathway associated with right atrial diverticulum in a child. *Pacing Clin Electrophysiol* 2005; 28: 72-74.
- [6] Morrow AG and Behrendt DM. Congenital aneurysm (diverticulum) of the right atrium. Clinical manifestations and results of operative treatment. *Circulation* 1968; 38: 124-128.
- [7] Schilling RJ, Peters NS and Davies DW. Feasibility of a noncontact catheter for endocardial mapping of human ventricular tachycardia. *Circulation* 1999; 99: 2543-2552.