

## Case Report

# Crossed fused renal ectopia with repeated kidney and congenital spinal deformity: a case report and literature review

Hong-Qin Li<sup>1,2</sup>, Wei-Gang Wang<sup>2</sup>, Jia-Nan Ma<sup>3</sup>, Wei An<sup>2</sup>, Yuan-Tao Wang<sup>2\*</sup>, Jin Pei<sup>1\*</sup>

<sup>1</sup>Jilin University School of Pharmaceutical Sciences, Changchun, Jilin Province, China; <sup>2</sup>The First hospital of Jilin University, Changchun, Jilin Province, China; <sup>3</sup>National-Local Joint Engineering Laboratory of Animal Models for Human Diseases, Jilin University, Changchun, Jilin Province, China. \*Equal contributors.

Received April 2, 2019; Accepted June 25, 2019; Epub August 15, 2019; Published August 30, 2019

**Abstract:** Crossed renal ectopia is a rare type of congenital malformation of the urinary system that shares a 1/2000 incidence. Patients with crossed renal ectopia often have other organ and system malformations. In this case, a male patient was admitted to our hospital because of double-limb edema, hematuria and proteinuria and all pre-operative examinations indicated that the left kidney is ectopic to the right side and fused with the right orthotopic kidney and there was a repeated kidney existed. In addition, the patient had a congenital spinal deformity at the same time. The hydronephrosis of repeated kidney formed a cystic mass and led to a loss of function. Exploratory laparoscopic surgery was performed and confirmed the preoperative diagnosis. The repeated non-functional kidney was removed, corresponding ureter was blocked and the fused internal membranes of the other kidneys was treated with electrocautery. The patient suffered little discomfort and recovered quickly.

**Keywords:** Crossed renal ectopia, repeated kidney, congenital malformation, hydronephrosis

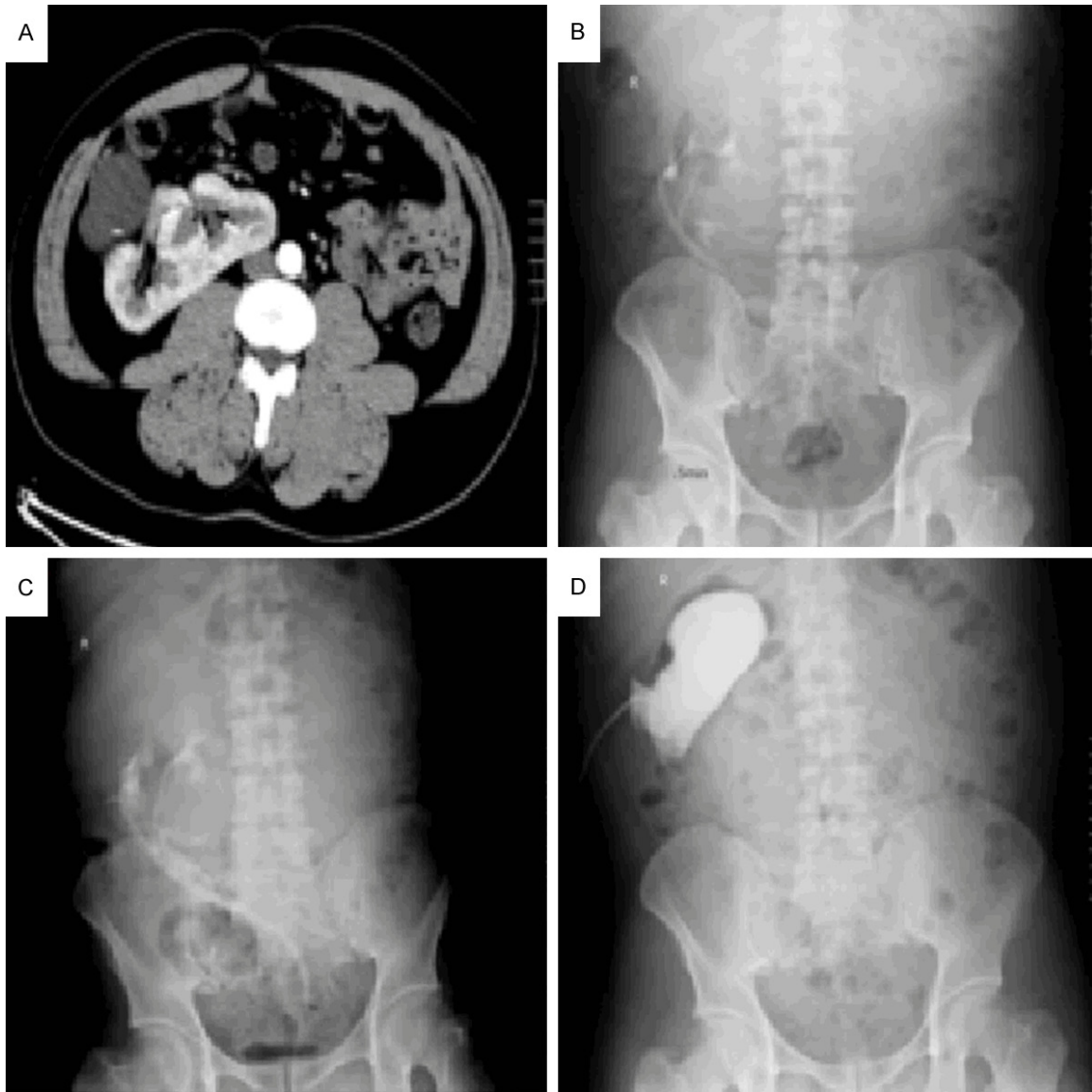
## Introduction

Crossed renal ectopia is a rare congenital malformation of the urinary system and it is a type of congenital renal ectopia. It means that the kidney is displaced from one side to the contralateral side crossed the midspinal line, however, the ureteral opening is still on the primary side of the bladder [1]. The clinical manifestations and imaging features are different from most other malformations of urinary system, but easily confused with repeated kidneys and repeated ureters. The patient is usually asymptomatic and diagnosed by chance or autopsy [2]. At present, the relevant reports about crossed renal ectopia are so rare that the relative knowledge of diagnosis and treatment is insufficient in clinical practice. Hereon, we report the diagnosis and treatment of a case of crossed fused renal ectopia with repeated kidney and congenital spinal deformity in our hospital. Review of related literature and discussion of the characteristic, diagnosis and treatment of the rare disease were provided.

## Case report

A 41-year-old male was admitted to our urology center because of double-limb edema, hematuria and proteinuria for 8 years and aggravated for 6 months. The patient was diagnosed with chronic glomerulonephritis 8 years ago and received a regular medical treatment. 6 months ago, the patient's condition was aggravated, and then he was admitted to the Department of Nephrology in our hospital. Computed tomography scan (CT) and images with enhancement in three phases of kidneys indicated that there was no kidney in the left renal area and the left ureter rose to the right renal area. The right kidney was irregular with two groups of renal pelvis. In addition, in the right renal area, there was a 15.7 cm × 11.1 cm × 10.8 cm irregular cystic low-density liquid shadow in which many evenly separated lesions with small nodular calcification in the edge can be seen. No abnormal enhancement was observed in enhanced scan (**Figure 1A**). The cervical MRI was performed because of a neck discomfort and it indicated

## Case report of crossed fused renal ectopia

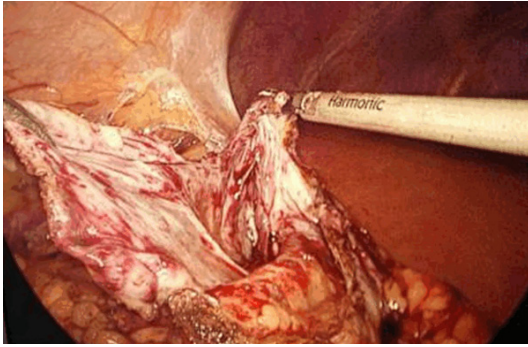


**Figure 1.** Imaging findings. A. The arterial phase of CT scan. There was no kidney in the left renal area and the right kidney was irregular with two groups of renal pelvises. A 15.7 cm × 11.1 cm × 10.8 cm cystic low-density liquid shadow was in the right renal area, in which many evenly separated lesions with small nodular calcification in the edge could be seen. No abnormal enhancement was observed in enhanced scan. B. Intravenous pyelography. After injecting contrast medium, there were two or three groups of renal pelvis in the right renal area and the corresponding ureters fused. There was no development in the left renal area. C. Ureteral retrograde radiography. In the right renal area, there were three groups of suspected renal pelvis, and the corresponding ureters merged to enter into the left side of bladder crossed the midspinal line. D. Antegrade radiography. There was no contrast agent down.

that the third and fourth, the sixth and seventh cervical vertebrae were fused due to congenital dysplasia. So the patient was transferred to our department for further examination and treatment. Intravenous pyelography (**Figure 1B**): after injecting contrast medium, there were two or three groups of renal pelvises in the right renal area. The corresponding ureters were merged into one that crossed the midspinal

line and entered into the left side of bladder. There was no development in the left ureter running zone and no ureter entered into the right side of bladder. Cystoscopy: the left ureteral opening was clearly visible with normal peristalsis and urine spray. However, the right ureteral opening, peristalsis and urine spray were not observed. Ureteral retrograde radiography (**Figure 1C**): in the right renal area, there

## Case report of crossed fused renal ectopia



**Figure 2.** Intraoperative condition. The 10 cm cystic mass in right renal area.

were three groups of suspected renal pelvis, and the corresponding ureters were merged to enter into the left side of bladder crossed the midspinal line. In order to identify whether the irregular cystic low-density shadow was caused by cyst or hydronephrosis, puncture and drainage of the cystic mass was performed. The amount of drainage fluid was approximately 20 ml per day. A review of the urinary color doppler ultrasound revealed that the cystic mass in the right renal area was disappeared and antegrade radiography indicated there was no contrast down (**Figure 1D**). Combined these examinations, we considered that the left kidney was ectopic to the right side and fused with the right orthotopic kidney. Moreover, there was a repeated kidney existed. That is to say, there were three closely integrated kidneys and three groups of ureters in the right renal area. Three ureters were merged into one, crossed the midspinal line and entered into the left side of bladder to urinate. The cystic lesion might be caused by hydronephrosis of the repeated kidney and led to a loss of function.

Then, exploratory laparoscopic surgery was performed. Three groups of renal pelvis and ureters and the puncture tube can be seen after the right renal area were exposed. After physiological saline was injected into the fistula, the cystic mass was clearly localized and confirmed that it was caused by hydronephrosis of the repeated kidney (**Figure 2**). The other two fused kidneys enclosed the cystic lesion. After enlarging the cystic wall incision and aspirating the cyst fluid, the cyst wall was thick and irregular. Therefore, repeated non-functional kidney was removed, the corresponding ureter was blocked and the fused internal membranes of the

other kidneys were treated with electrocautery. The patient had less drainage after operation. On the fourth day, the renal color ultrasound was performed and indicated that the dark area in the right renal area was disappeared. Then, the drainage tube was removed.

### Discussion

The normal kidney is located at the level of the second lumbar spine behind the retroperitoneum and the renal portal faces inside. When the kidney is mature but fails to reach the kidney socket, it is called renal ectopia. Renal ectopia includes acquired renal ectopia and congenital renal ectopia [3]. Acquired renal ectopia, such as nephrospasia, has normal lengths of blood vessels and ureters. Congenital renal ectopia refers that the kidney stopped, overspeeded or was ectopic to the contralateral side during ascent including pelvic kidney, thoracic kidney and crossed ectopic kidney [4]. The lengths of blood vessels and ureters are often abnormal, but the ureteral opening of the bladder is usually normal [5]. Crossed renal ectopia means the kidney is displaced from one side to the contralateral side, but the ureteral opening is still on the primary side of bladder. The incidence of crossed renal ectopia is 1/2000 and the ratio of men and women is about 2:1. 90% of crossed ectopic kidney is located under the contralateral kidney and fuses with it [6]. Patients with crossed renal ectopia often have other system abnormalities, such as hypospadias, cryptorchidism, vaginal dystrophy, malformations of gastrointestinal and cardiovascular system, bone malformation and so on [7-9]. There are also cases of crossed renal ectopia combined with renal malignancy such as nephroblastoma reported in the literature [10, 11]. Most patients are asymptomatic. However, ectopic kidney and blood vessels may cause obstruction and lead to hydronephrosis and stones [12, 13]. So some patients may have abdominal pain and masses. Other symptoms include pyuria, hematuria, urinary tract infection and so on [14].

At present, the diagnosis of crossed renal ectopia mainly depends on imaging examination and the value of CT is particularly prominent. Plain and enhanced scan of CT could clearly show the relationship between renal pelvis, renal pedicle and other structures around the ectopic kidney. Urinary angiography could show

## Case report of crossed fused renal ectopia

the origin and walking of renal vessels, moreover, urography could show the collection system [15, 16]. Color doppler ultrasonography, intravenous urography (or retrograde urography) and CT can be combined to diagnose crossed renal ectopia. Clinically, crossed renal ectopia needs to be differentiated from repeat kidneys and ureters with contralateral kidney absent. Most of the ectopic kidneys are well developed and located under the contralateral kidney. However, the ureter usually spans the spine and the ureteral opening is still on the primary side of bladder. Repeated kidneys are usually located in the upper pole of the orthotopic kidney, and only a few are located in the lower pole. Most are abnormal development. Repeated ureters descend on the ipsilateral side and the opening usually located below the normal ureteral opening or in the urethra, and sometimes combined with malformations, such as ureteral cysts [17].

Similar to the clinical features of the crossed renal ectopic reported in the literature, the patient in this case is a middle-aged man whose initial symptoms were hematuria and proteinuria. The presence of crossed ectopic kidney was found by imaging examination, and it fused with orthotopic kidney. In addition, the patient had a congenital spinal deformity. Specifically, it is different from other case reports that our patient also had other urinary system malformation. There was a repeated kidney existed and it fused with ectopic kidney and orthotopic kidney. That is to say, there were three kidneys in total and they fused with each other so that it was unable to determine which kidney the repeated kidney was originated from. It increased the complexity of the case and the difficulty of diagnosis and treatment.

The incidence of crossed renal ectopia is very low. Patients usually do not have obvious clinical symptoms and most of them are diagnosed by autopsy. So there are only a few reports about the treatment of crossed renal ectopia and a complete and mature therapeutic system has not yet been formed. Generally, the treatment is mainly based on the symptoms and accompanying diseases [18, 19].

In summary, the report about crossed renal ectopia is very rare and its diagnosis and treatment need to be individualized and precise. The author believes that it is necessary to raise awareness of this disease by adding reports.

### Disclosure of conflict of interest

None.

**Address correspondence to:** Dr. Yuan-Tao Wang, Department of Urology, First Hospital of Jilin University, 71 Xinmin Street, Changchun, Jilin Province, China. Tel: +86-431-81875831; Fax: +86-431-81875831; E-mail: wangyuantaobs@163.com

### References

- [1] Mudoni A, Caccetta F, Caroppo M, Musio F, Accogli A, Zacheo MD, Burzo MD and Nuzzo V. Crossed fused renal ectopia: case report and review of the literature. *J Ultrasound* 2017; 20: 333-337.
- [2] Nemoyer R, Narayanan S and Maloney-Patel N. A case of crossed left renal ectopia identified during colostomy reversal. *Case Rep Surg* 2017; 2017: 1-3.
- [3] Bhatt K and Herts BR. Crossed fused renal ectopia. *J Urol* 2014; 191: 475-6.
- [4] Zhao YW, Zheng W and Peng QL. Diagnosis and treatment of congenital ectopic kidney with ectopic opening of ureter (report of 7 cases). *Journal of Clinical Pediatric Surgery* 2004; 3: 343-345.
- [5] Al-Hamar NE and Khan K. Crossed nonfused renal ectopia with variant blood vessels: a rare congenital renal anomaly. *Radiol Case Rep* 2017; 12: 59-64.
- [6] Zajicek M, Perlman S, Dekel B, Lahav E, Lotan D, Lotan D, Achiron R and Gilboa Y. Crossed ectopic kidney: prenatal diagnosis and postnatal follow-up. *Prenat Diagn* 2017; 37: 712-715.
- [7] Naseri M. Cross-fused renal ectopia associated with vesicoureteral reflux; a case report. *J Renal Inj Prev* 2016; 5: 200-202.
- [8] Drevna DW, Dankoff J and Leeuwen BV. A potential link: cross-fused renal ectopia with concomitant absent left testicle. *Rev Urol* 2018; 20: 49-51.
- [9] Wanjari P, Sharma R, Dey AK, Ray A, Mittal K and Thakkar H. Crossed fused renal ectopia with Wolffian duct anomaly. *Indian J Nephrol* 2016; 26: 232.
- [10] Cakmak O, Isoglu CS, Peker EA, Tarhan H, Kucuk U, Celik O, Zorlu F and Ilbey YO. Renal cell carcinoma in patient with crossed fused renal ectopia. *Arch Ital Urol Androl* 2016; 87: 330-331.
- [11] Rac G, Ellet JD, Sarkissian H, Eklund MJ and Stec AA. Open partial nephrectomy for wilms' tumor in a cross-fused pelvic ectopic kidney. *Urology* 2016; 93: 188-190.
- [12] Agrawal S, Chipde SS, Kalathia J and Agrawal R. Renal stone in crossed fused renal ectopia and its laparoscopic management: case repo-

## Case report of crossed fused renal ectopia

- rt and review of literature. *Urol Ann* 2016; 8: 236-238.
- [13] Muhammad Umar A, Shamraiz K and Muhammad N. Crossed fused renal ectopia with stag-horn calculus and gross hydronephrosis. *J Coll Physicians Surg Pak* 2009; 19: 69-70.
- [14] Liu DY, Wang HF, Xia WM, He HC and Shen ZJ. Right-crossed, fused renal ectopia I-shaped kidney type with urinary chyluria. *Urol Int* 2015; 95: 243-245.
- [15] Miclaus GD, Pupca G, Gabriel A, Matusz P and Loukas M. Right lump kidney with varied vasculature and urinary system revealed by multi-detector computed tomographic (MDCT) angiography. *Surg Radiol Anat* 2015; 37: 859-865.
- [16] Giani A, Garancini M, Delitala A, Riva L, Giannotti L and Giardini V. 3D-laparoscopic anterior rectal resection in a patient with crossed fused renal ectopia: the importance of 3D imaging. *Minerva Chir* 2017; 72: 546-547.
- [17] Hirsch K, Heinz M and Wullich B. Diagnosis and therapeutic management in kidney, ureter and bladder trauma. *Aktuelle Urol* 2017; 48: 64.
- [18] Meral U, Zor M, Ureyen O, Oren NC and Gungor H. A case of acute appendicitis in a patient with crossed renal ectopia. *Journal of Acute Disease* 2016; 5: 355-356.
- [19] O'Donnell MT, Maddox J, Wind G and Mukherjee D. A staged repair of crossed fused renal ectopia with complex abdominal aortic and iliac aneurysms. *Journal of Vascular Surgery Cases & Innovative Techniques* 2016; 2: 77-79.