

Original Article

Effect of arthroscopic operation combined with sodium hyaluronate on quality of life and inflammatory factors in patients with meniscus injury

Ren Lin, Jinglai Xue, Junqin Qiu

Department of Orthopedics, Fuzhou Second Hospital Affiliated to Xiamen University, Fuzhou, Fujian Province, China

Received January 15, 2020; Accepted February 16, 2020; Epub June 15, 2020; Published June 30, 2020

Abstract: Objective: To explore the effect of arthroscopic operation combined with sodium hyaluronate on quality of life and inflammatory factors in patients with meniscus injury. Methods: In this prospective study, 108 cases of Meniscus injury of the knee joint were collected from January 2018 to July 2019 and randomized into an experimental group and a control group according to a random number table, with 54 patients in each group. Both groups underwent arthroscopic meniscus plasty, and the experimental group was treated with sodium hyaluronate after the operation. We compared the two groups' clinical therapeutic effects and pain levels, knee joint functions and quality of life before and after the treatment, and detected and compared the levels of serum inflammatory factors of the two groups. Results: The effective rate of treatment in the experimental group was significantly higher than that in the control group ($P < 0.05$). The visual analogue scale (VAS) score and brief pain inventory (BPI) score were significantly decreased in the two groups after the operation as compared with the scores before the operation ($P < 0.001$), and the scores were significantly lower in the experimental group than in the control group ($P < 0.01$). After the operation, the Lysholm score, HSS (The Knee Society score) and the 36-Item short form survey score (SF-36) of the two groups were significantly increased ($P < 0.001$), and the scores of the experimental group were significantly higher than those of the control group ($P < 0.01$). The levels of Interleukin-1 β (IL-1 β) and Interleukin-6 (IL-6) in the two groups were significantly decreased after treatment ($P < 0.001$), and the levels were significantly lower in the experimental group than in the control group ($P < 0.01$). Conclusion: The injection of sodium hyaluronate after arthroscopic meniscus plasty can effectively promote the recovery of patients with meniscus injury and improve the function of the knee joint. It has a positive effect on the improvement of their quality of life and has high safety. Thus it is worthy of clinical application and promotion.

Keywords: Meniscus injury, arthroscopic meniscus plasty, sodium hyaluronate, quality of life, inflammatory factors

Introduction

Meniscus injury of the knee joint is a common orthopedic disease, which is mainly caused by joint retrograde degeneration, trauma, chronic strain, and other factors. With the progress of the disease, the meniscus can be degenerated, which will then lead to the hyperplasia and edema of its edge and surrounding muscle tissue, further affecting the stability of the knee joint, and significantly reducing patients' quality of life of [1]. In the past, meniscectomy was often adopted in clinical treatment. Although the short-term effect was good, the postoperative complication rate was high; especially intense postoperative pain. At present, arthros-

copie meniscus plasty is an orthopedic operation widely that is applied. Although it is less traumatic and can greatly shorten postoperative recovery time, it still has different degrees of influence on the knee joint function. Besides, with the gradual increase of patients' and their families' requirements for curative effect and symptom improvement effect, arthroscopic minimally invasive treatment of meniscus injury is also being studied clinically [2, 3]. It has been reported that sodium hyaluronate injection after arthroscopy can significantly inhibit the release of pro-inflammatory factors in the joint fluid, which is conducive to the improvement of the treatment effect of meniscus injury [4]. However, there is no clinical report on

Effect of arthroscopic operation combined with sodium hyaluronate

the effect of sodium hyaluronate injection, based on arthroscopic meniscus plasty, on the quality of life, the degree of pain, inflammatory factors, and other aspects of patients with meniscus injury. The purpose of this study was to explore the effect of arthroscopic minimally invasive operation combined with sodium hyaluronate on the quality of life and inflammatory factors of patients with meniscus injury. The results are reported as follows.

Materials and methods

General information

In this prospective study, 108 cases of meniscus injury occurring from January 2018 to July 2019 in Fuzhou Second Hospital Affiliated to Xiamen University were randomized into an experimental group and a control group according to a random number table, with 54 patients in each group. Diagnostic criteria: MRI showed that the spherical or round signals not in contact with the meniscus articular surface were dense with obscure margin; the horizontal shape not in contact with the meniscus articular surface demonstrated a high signal shadow, indicating a high dense signal in the meniscus, involving the articular surface. Inclusion criteria: (1) patients with meniscus injury but without ligament relaxation or injury confirmed by imaging; (2) patients aged 20-60 years without contraindications of arthroscopic meniscus plasty and sodium hyaluronate treatment; (3) patients without history of knee joint operation; (4) patients with unilateral meniscus injury; (5) patients who did not take other treatments after the onset of the disease. Exclusion criteria: (1) patients who couldn't follow the doctor's advice, or with poor cooperation; (2) patients with serious joint retrograde degeneration; (3) patients with malignant tumor; (4) patients complicated with serious combined articular cartilage injury or knee osteoarthritis; (5) patients with abnormal coagulation function; (6) patients with cognitive dysfunction; (7) patients who can't communicate; (8) patients with severe dysfunction of heart, brain and kidney and other vital organs. The contents of this study had been approved by the Medical Ethics Committee of Fuzhou Second Hospital Affiliated to Xiamen University, and the patients knew the contents of the investigation and signed the informed consent form.

Methods

Surgical method: Arthroscopic meniscus plasty was performed in both groups. The specific operation method was [5]: after combined spinal and epidural anesthesia, patients were maintained at the supine position. Then an arthroscope was inserted, through the anterolateral or anteromedial approach, to investigate the injury status and specific location of the meniscus. Subsequently, epinephrine was injected into the articular cavity, and the cavity structure was fully comprehended by a hook, and the excess synovial tissue was completely removed. Meanwhile, the annulus fibrosus of the union site connecting the articular capsule of the meniscus was reserved, the damaged edges were removed by basket punch, and partial meniscectomy was performed. Finally, we checked whether there was any residual loose body or arthropathy in the joint cavity, and if there was any, it would be removed entirely by negative pressure suction. At the end of the operation, a suture was performed according to the tear type; after the operation, the knee joint was treated with anti-infection treatment. Patients were instructed to carry out functional exercises as soon as possible, that is, to carry out quadriceps isometric contraction rehabilitation training after recovery from anesthesia, to conduct knee flexion exercise after three days, and to gradually carry out weight-bearing exercises with crutches after seven days. The experimental group was given intra-articular injections of sodium hyaluronate (manufactured by Shanghai Jingfeng Pharmaceutical Co., Ltd.; specification: 2.5 mL: 25 mg) from the first to fourth week after the operation, 25 mg/time, once a week.

Detection methods: Joint fluid collection and detection methods: before and after the operation, 5 mL of joint fluid was collected respectively from each patient in the two groups by joint puncture, and the supernatant was taken after separation and stored at -20°C for testing. Enzyme linked immunosorbent assay was used to detect the inflammatory factors of the two groups, including interleukin-1 β , 6 (IL-1 β , IL-6). The detection kit was purchased from a Chinese company, Jiangsu Baolai Biotechnology, and the operation procedures strictly followed the instructions.

Effect of arthroscopic operation combined with sodium hyaluronate

Table 1. Comparison of clinical data between the two groups

Group	Experimental group (n=54)	Control group (n=54)	t/ χ^2	P
Gender (n/%)				
Male	25	26	0.037	0.847
Female	29	28		
Age (years)	50.1±2.2	50.3±2.4	0.451	0.653
Average course of the disease (years)	5.3±1.2	5.3±1.4	0.399	0.691
Diseased part (n)				
Left knee	27	29	0.148	0.7
Right knee	27	25		
Meniscus injury type (n)				
Horizontal fissure	16	17	0.795	0.851
Oblique fissure	13	12		
Transverse fissure	10	13		
Others	15	12		

Observation index and clinical efficacy evaluation

(1) Specialists evaluated and compared the clinical therapeutic effect of the patients in the two groups three months after the operation [6]. For cases that obtained complete recovery of knee joint function without pain symptoms, the treatment would be counted as significantly effective; for cases that gained partial recovery of knee joint function, with occasional pain that had significantly reduced, but without significant impact on normal activities, the treatment would be regarded as effective; for cases with no improvement of, or even worse pain level and knee joint function, the treatment would be deemed to be ineffective. Effective rate = significantly effective cases + effective cases/total cases × 100%.

(2) Visual Analogue Scale (VAS) [7] and Brief Pain Inventory (BPI) [8] were used to evaluate the degree of pain before and after the operation on patients in the two groups. The full score of each scale was 10 points, the higher the score was, the more serious the degree of pain was.

(3) Lysholm Knee Scoring Scale [9] and HSS Knee Scoring Scale [10] were used to evaluate the knee joint function of the patients in the two groups before and six months after the operation. The full score of each scale was 100, and the lower the score was, the worse the recovery of knee joint function was.

(4) The 36-Item Short Form Survey (SF-36) [11] was used to evaluate and compare the quality of life of the patients in the two groups before and three months after the operation. The full score of the scale was 100, and the lower the score was, the worse the quality of life was.

(5) The levels of Interleukin-1 β (IL-1 β) and Interleukin-6 (IL-6) in the synovial fluid were compared.

Statistical method

SPSS 20.0 statistical software was used to analyze the statistical data. The measurement data were expressed as mean \pm standard deviation, the measurement data before and after the treatment were checked by paired t-test, and the comparison between two groups was done with an independent t-test. The enumeration data were expressed as the number of cases/percentage (n/%) and verified by Chi Square test. If $P < 0.05$, the difference was considered statistically significant.

Results

Comparison of clinical data between the two groups

None of the enrolled patients dropped out of the study, and there was no significant difference in gender, age, average course of the disease, diseased part, meniscus injury type, and other primary clinical baseline information between the two groups ($P > 0.05$), as shown in **Table 1**.

Effect of arthroscopic operation combined with sodium hyaluronate

Table 2. Comparison of clinical efficacy between the two groups

Group	Significantly effective (n)	Effective (n)	Ineffective (n)	Effective rate [n (%)]
Experimental group (n=54)	37	12	5	49 (90.74)
Control group (n=54)	26	15	13	41 (75.93)
χ^2				4.267
P				0.039

Table 3. Comparison of pain degrees between the two groups before and after the operation ($\bar{x} \pm sd$)

Group	VAS	BPI
Experimental group (n=54)		
Pre-operation	6.03±0.40	8.36±1.97
Post-operation	2.33±0.20**###	2.77±0.26**###
Control group (n=54)		
Pre-operation	6.02±0.43	8.25±1.95
Post-operation	4.10±0.18###	4.35±0.38###

Note: VAS: visual analogue scale; BPI: brief pain inventory. Compared with the control group after the operation, **P<0.01; Compared with the same group before the operation, ###P<0.001.

Table 4. Comparison of knee joint functions between the two groups before and after the operation ($\bar{x} \pm sd$)

Group	Lysholm score	HSS score
Experimental group (n=54)		
Pre-operation	55.37±10.13	58.43±11.20
Post-operation	88.97±11.94**###	92.01±10.33**###
Control group (n=54)		
Pre-operation	55.43±10.20	58.46±11.18
Post-operation	73.86±11.42###	77.29±10.36###

Note: Compared with the control group after the operation, **P<0.01; Compared with the same group before the operation, ###P<0.001. HSS: The Knee Society score.

Comparison of clinical efficacy between the two groups

The effective rate of the treatment in the experimental group was significantly higher than that in the control group (P<0.05), as shown in **Table 2**.

Comparison of pain degree between the two groups before and after the operation

There was no significant statistical difference in pain degree between the two groups before the operation (P>0.05). The VAS score and BPI score of the two groups after the operation were significantly decreased (P<0.001) as compared with the scores before the operation,

and the scores were significantly lower in the experimental group than in the control group (P<0.01). See **Table 3**.

Comparison of knee joint functions between two groups before and after the operation

There was no significant statistical difference in knee joint function between the two groups before the operation (P>0.05). After the operation, the Lysholm score and HSS score of the two groups were significantly increased (P<0.001), and the scores were significantly higher in the experimental group than in the control group (P<0.01). See **Table 4**.

Comparison of quality of life between the two groups before and after the operation

The SF-36 score before and after the operation was (57.10±8.79), (70.03±10.01) in the experimental group respectively, and (57.09±8.81), (65.14±10.20) in the control group respectively. After the operation, the SF-36 scores in the two groups were significantly increased (P<0.001), and the score in the experimental group was significantly

higher than that in the control group (P<0.01). See **Figure 1**.

Comparison of levels of inflammatory factors between the two groups before and after the operation

There was no significant statistical difference in the levels of inflammatory factors between the two groups before the operation (P>0.05). After the operation, the levels of IL-1 β and IL-6 in the two groups were significantly reduced (P<0.001) as compared with the levels before the operation, and the levels were significantly lower in the experimental group than in the control group (P<0.01). For details, please see **Table 5**.

Effect of arthroscopic operation combined with sodium hyaluronate

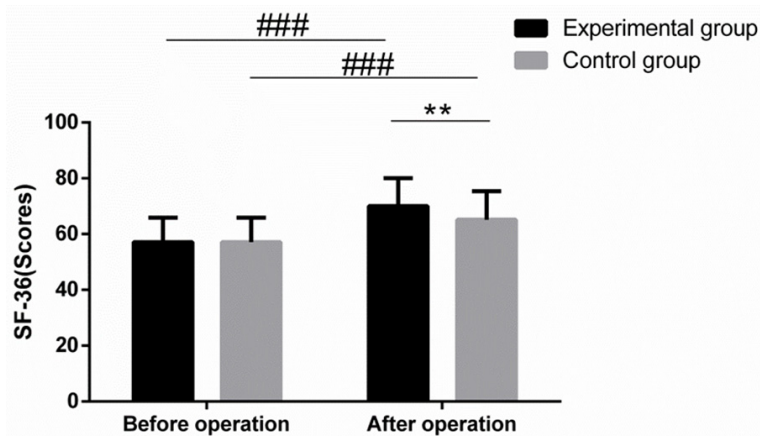


Figure 1. Comparison of quality of life between the two groups before and after the operation. SF-36: 36-item short form survey. Compared with the control group after the operation, ** $P < 0.01$; Compared with the same group before the operation, ### $P < 0.001$.

Table 5. Comparison of levels of inflammatory factors between the two groups before and after the operation ($\bar{x} \pm sd$)

Group	IL-1 β (pg/L)	IL-6 (pg/mL)
Experimental group (n=54)		
Pre-operation	165.02 \pm 11.35	175.32 \pm 10.17
Post-operation	123.09 \pm 10.15**###	102.42 \pm 9.33**###
Control group (n=54)		
Pre-operation	165.03 \pm 11.36	175.44 \pm 10.18
Post-operation	143.97 \pm 10.20###	114.74 \pm 11.40###

Note: Compared with the control group after the operation, ** $P < 0.01$; Compared with the same group before the operation, ### $P < 0.001$.

Discussion

As one of the key parts of the knee joint, the meniscus is mainly composed of fibrous soft-tissue. It can limit the excessive movement of the femur, absorb shock, lubricate and stabilize the knee joint, etc. Due to its special physiological structure, the meniscus will bear unbalanced horizontal pull or vertical pressure when the human body is in different movements. The unbalanced horizontal pull or vertical pressure can injure the meniscus, and then significantly change the biomechanical property of the knee joint, break the original balance, and can also induce knee osteoarthritis with the progress of the disease [12]. In recent years, the primary principle of arthroscopic minimally invasive treatment of meniscus injury is to preserve the meniscus as much as possible.

Although arthroscopic minimally invasive treatment means quick recovery and fewer compli-

cations, some studies indicated that some patients still had significant postoperative pain. The leading cause is that arthroscopic minimally invasive treatment alone cannot eradicate the inflammation around the meniscus, and residual inflammation can further stimulate the pain [13]. At present, sodium hyaluronate is a commonly used drug for knee osteoarthritis. As an effective component of joint fluid, its primary function is to enhance lubrication and reduce joint friction. Meanwhile, it also has the functions of protecting the articular cartilage surface, inhibiting the excessive secretion of inflammatory factors, and alleviating inflammatory pain [14]. It has been clinically reported that postoperative injection of sodium hyaluronate into patients undergone arthroscopic minimally invasive treatment for meniscus injury can significantly improve clinical symptoms and knee joint mobility [15]. The results of the study showed that the effective rate of the treatment

in the experimental group was significantly higher than that in the control group. This indicates that postoperative injection of sodium hyaluronate can effectively improve the effect of surgical treatment and promote the prognosis of patients. It may be that the sodium hyaluronate, the main component of joint fluid, can better protect the cartilage surface and the medial synovial of the knee joint.

According to a foreign study, intraoperative injection of sodium hyaluronate into the articular cavity can help reduce the pain degree and improve the postoperative knee joint function [16]. In the meantime, another clinical study found that the use of synthetic joint fluid containing sodium hyaluronate for patients with knee osteoarthritis during the treatment can greatly alleviate the pain and reduce the degree of the knee joint swelling, which is conducive to the improvement of postoperative quality of life [17]. The results of this study

showed that the VAS score and BPI score were significantly decreased in the two groups after the operation as compared with the scores before the operation, and the scores were significantly lower in the experimental group than in the control group. Meanwhile, the Lysholm score, HSS score, and SF-36 score were significantly higher in the two groups after the operation as compared with the scores before the operation, and the scores of the experimental group were significantly higher than those of the control group. This indicates that timely injection of sodium hyaluronate after arthroscopic minimally invasive operation for patients with meniscus injury can significantly reduce knee pain, improve knee function and quality of life. It may be that, on the one hand, arthroscopic minimally invasive treatment can observe the articular cavity form and the damage degree directly, and thus makes the choice of a reasonable operation possible [18]; on the other hand, exogenous supplementation of sodium hyaluronate can facilitate the formation of protective barriers, inhibit the erosion and destruction of joints caused by bacterial toxins to the greatest extent, and improve the lubrication function of intra-articular joint lubricant to promote postoperative healing and regeneration of articular cartilage [19]. Some scholars have found that only giving arthroscopic minimally invasive treatment to patients with meniscus injury may render some patients with poor treatment effect due to the residual inflammatory response, among which the IL-6 and IL-1 β are two typical inflammatory factors [20, 21]. IL-6 can stimulate the proliferation and differentiation of B cells and T cells, and secrete and release a large number of acute phase proteins, thus promoting the continuous progress of the inflammatory reaction and inhibiting meniscus healing. As a common clinical pro-inflammatory factor, IL-1 β 's excessive secretion can aggravate the joint injury. The results of the study showed that the levels of IL-1 β and IL-6 in the two groups after the operation were significantly decreased as compared with the levels before the operation, and the levels of IL-1 β and IL-6 were significantly lower in the experimental group than in the control group. This indicates that sodium hyaluronate injection can effectively inhibit the development of inflammatory response, which may be closely related to sodium hyaluronate's function of inhibiting inflammation.

However, this study still has some deficiencies, and the number of samples is limited. The exact influence mechanism of sodium hyaluronate on meniscus repair and the effect of sodium hyaluronate on patients of different ages and with different meniscus injury degree and different sutures can be further explored through later large-scale and multicenter research.

In conclusion, the injection of sodium hyaluronate after arthroscopic meniscus plasty can effectively improve the clinical symptoms of patients with meniscus injury, relieve their pain, and improve their knee function and quality of life. Therefore it is worthy of clinical application and promotion.

Disclosure of conflict of interest

None.

Address correspondence to: Junqin Qiu, Department of Orthopedics, Fuzhou Second Hospital Affiliated to Xiamen University, No.47 Shangteng Road, Cangshan District, Fuzhou 350007, Fujian Province, China. Tel: +86-18750162256; E-mail: qiujunqinfz2y@163.com

References

- [1] Hong-hai X, Zhang F, Liu N, Zheng JJ, Zhang YP, Zhao QM, Guo X, Yu M, Liu ZZ, Sun ZM, Zou QY and Liu C. Clinical natural development in human meniscus injury. *Zhongguo Gu Shang* 2013; 26: 836-840.
- [2] Ebrahimi N, Jalaie S, Salsabili N, Ansari NN and Naghdi S. Knee injury and osteoarthritis outcome score in patients with isolated meniscus injury; validity and reliability. *J Res Med Sci* 2017; 22: 55.
- [3] Zou YC, Chen LH, Ye YL, Yang GG, Mao Z, Liu DD, Chen JQ, Chen JJ and Liu G. Attenuated synovial fluid ghrelin levels are linked with cartilage damage, meniscus injury, and clinical symptoms in patients with knee anterior cruciate ligament deficiency. *Discov Med* 2016; 22: 325-335.
- [4] Liang X, Tian Y, Wang S and Zheng Y. Clinical efficacy of arthroscopic simultaneous treatment for anterior cruciate ligament injury combined with meniscus bucket-handle tear. *Zhongguo Xiu Fu Chong Jian Wai Ke Za Zhi* 2017; 31: 547-552.
- [5] Kocher MS, Tepolt FA and Vavken P. Meniscus transplantation in skeletally immature patients. *J Pediatr Orthop B* 2016; 25: 343-348.

Effect of arthroscopic operation combined with sodium hyaluronate

- [6] Van Rossom S, Smith CR, Thelen DG, Vanwanseele B, Van Assche D and Jonkers I. Knee joint loading in healthy adults during functional exercises: implications for rehabilitation guidelines. *J Orthop Sports Phys Ther* 2018; 48: 1-42.
- [7] Helito CP, Helito PVP, Costa HP, Demange MK and Bordalo-Rodrigues M. Assessment of the anterolateral ligament of the knee by magnetic resonance imaging in acute injuries of the anterior cruciate ligament. *Arthroscopy* 2017; 33: 140-146.
- [8] Rowe MA, Harper LR, McNulty MA, Lau AG, Carlson CS, Leng L, Bucala RJ, Miller RA and Loeser RF. Reduced osteoarthritis severity in aged mice with deletion of macrophage migration inhibitory factor. *Arthritis Rheumatol* 2017; 69: 352-361.
- [9] Cao Y. Recent progress in cartilage tissue engineering-our experience and future directions. *Engineering* 2017; 3: 28-35.
- [10] Bai L, Zhou W, Zhang WT, Huang W, You T, Chen P and Zhang HL. Correlation between morphological factor of lateral plateau fracture and meniscus injury. *Beijing Da Xue Xue Bao Yi Xue Ban* 2016; 48: 274-278.
- [11] Lin Z, Huang W, Ma L, Chen L, Huang Z, Zeng X, Xia H and Zhang Y. Kinematic features in patients with lateral discoid meniscus injury during walking. *Sci Rep* 2018; 8: 5053.
- [12] Ozeki N, Koga H and Sekiya I. Homeostasis and disorder of musculoskeletal system. Transplantation of synovial mesenchymal stem cells for cartilage and meniscus regeneration. *Clin Calcium* 2018; 28: 319-327.
- [13] Eitzen I, Grindem H, Nilstad A, Moksnes H and Risberg MA. Quantifying quadriceps muscle strength in patients with ACL injury, focal cartilage lesions, and degenerative meniscus tears: differences and clinical implications. *Orthop J Sports Med* 2016; 4: 2325967116-667717.
- [14] Starke C, Kopf S and Becker R. Indication and limitations of meniscus replacement. *Orthopade* 2017; 46: 831-838.
- [15] Gao S, Yuan Z, Xi T, Wei X and Guo Q. Characterization of decellularized scaffold derived from porcine meniscus for tissue engineering applications. *Front Mater Sci* 2016; 10: 101-112.
- [16] Hur CI, Song EK, Kim SK, Lee SH and Seon JK. Early anterior cruciate ligament reconstruction can save meniscus without any complications. *Indian J Orthop* 2017; 51: 168-173.
- [17] Ristic V, Maljanovic M, Mihajlov I, Milankov V and Harhaji V. Concomitant injuries of anterior cruciate ligament and meniscus. *Med Pregl* 2016; 69: 217-223.
- [18] Harhaji V, Subasic S, Ninkovic S, Lalic I, Salamon T and Ristic V. The impact of combined meniscus tear on quality of life after anterior cruciate ligament reconstruction. *Med Pregl* 2016; 69: 153-159.
- [19] Rajasekar S and Marchand AM. Fascial Manipulation((R)) for persistent knee pain following ACL and meniscus repair. *J Bodyw Mov Ther* 2017; 21: 452-458.
- [20] Yang J, Guan K and Wang JZ. Clinical study on the arthroscopic refreshing treatment of anterior cruciate ligament injury combined with stable medial meniscus ramp injury. *J Musculoskelet Neuronal Interact* 2017; 17: 108-113.
- [21] Sun B, Wu XD and Shen W. Analysis on treatment and diagnosis of Segond fracture combined with injuries. *Zhongguo Gu Shang* 2016; 29: 149-153.