

Original Article

Retinal venule correlation with schizophrenia

Yanhong Liu^{1*}, Lvzhen Huang^{2*}, Jingxu Chen¹, Shuping Tan¹, Kexin Zhao¹, Shaoxiao Yan¹, Yan Li², Yunlong Tan¹, Fude Yang¹

¹Department of Psychiatry, Beijing Huilongguan Clinical Hospital, Peking University, Beijing 100096, China; ²Department of Ophthalmology, People's Hospital of Peking University, Beijing 100044, China. *Equal contributors.

Received March 3, 2020; Accepted June 2, 2020; Epub September 15, 2020; Published September 30, 2020

Abstract: Schizophrenia is a mental illness characterized by relapsing episodes of psychosis. The aim of this study was to investigate the changes of retinal vessels in schizophrenia patients. We performed a case-control study in a group of Chinese schizophrenia patients (n=165) and healthy control subjects who were matched for age and sex (n=72). Family history, current severity of symptoms, blood pressure, smoking and duration of illness were recorded. A photo of the retinal arteries and veins captured, with OCT (Optical coherence tomography) was used to measure the vasculature diameter with a semiautomated software package 'ImageJ'. Vascular Endothelial cell Growth Factor (VEGF) was assayed. The 237 subjects enrolled were aged 18 to 56 years. The mean diameter of both the retinal artery and vein assessment was significantly greater in the schizophrenia patient group than in the control group ($P \leq 0.001$). The mean diameters of retinal veins were significantly larger in the 20 patients with a positive family history of schizophrenia than in the 145 patients without a positive family history (right $P=0.001$; left $P=0.007$), while the retinal vessel diameter was not significantly correlated with the current severity of symptoms, duration of illness, and the level of VEGF. Retinal vein enlargement may be associated with abnormal neuroectoderm development and thus a potential marker of an increased risk of subsequently developing schizophrenia. These findings highlight the potential of retinal imaging as a potential tool for understanding the pathogenesis of schizophrenia.

Keywords: Schizophrenia, retina, microvein

Introduction

Schizophrenia has been related to an anomaly in the development of neural vasculature networks of the brain. The abnormal development of the cerebral vascular structure has been considered as a pathological feature of schizophrenia [1, 2]. According to functional genomic studies, schizophrenia may be a vascular ischaemic disease with onset in adulthood [3]. Interactions between hypoxia and vascular factors have been proposed to play a key role in the neurodevelopment of schizophrenia [4]. The retinal and cerebral microvessels are structurally and functionally homologous in the embryonic neuroectoderm, thus, the retinal microvasculature indirectly reflects the microvasculature in the brain.

Through observing the optical structure by OCT directly, we may find early changes in schizophrenia. Several researchers have objectively evaluated vessels of the optic disc with special

techniques (e.g., adaptive optics scanning laser ophthalmoscopy or Integrative Vessel Analysis software) [5, 6]. Unfortunately, these techniques require specialized equipment or copyrighted analysis software. ImageJ has the advantage of being a free platform for image processing and analysis (<https://imagej.en.softonic.com>). It completes measurements like a "ruler" and automatically extracts vessel edges and reduces the error of manual measurement, moreover, this software is equivalent to the direct measurement of computer-aided calculation formulas [7, 8]. It has been widely used in the field of medical imaging meterage [9].

To date, few studies have investigated retinal vessels in patients with schizophrenia. As shown in the study by Meier et al., retinal vein dilatation in patients with schizophrenia suggests the presence of microvascular abnormalities in venules that may be caused by a chronically insufficient oxygen supply [10]. It was shown that the widest retinal venule diameter

was observed among patients with schizophrenia in a case control study, followed by unaffected twins [11]. Furthermore, the retinal venular microvessels have been shown to reflect familial susceptibility to psychotic symptoms [11]. However, the study of participants only underwent retinal imaging at the age of 38 years. Knowledge about the stages of schizophrenia at which this abnormality begins early in life is still limited [10].

Therefore, we hypothesized that individuals with schizophrenia might be identified by wider retinal vessels. In the current study, we have included patients with different duration of mental illness and determined whether enlargement of the retinal microvessels was a diagnostic marker of schizophrenia, particularly among those patients with a positive family history, using retinal imaging.

Methods

Patients

This study enrolled age-and-sex-matched patients with schizophrenia and normal controls. The patients recruited to the neurology hospital were diagnosed with schizophrenia by two senior psychiatrists according to the Diagnostic and Statistical Manual of Mental Disorders (DSM-V) [12]. The patient group was divided into three subgroups according to the duration of illness (acute: <2 years, chronic: 2-10 years, and long-term chronic: >10 years) [13]. The normal subjects were recruited as volunteers from staff members at our hospital who had normal physical examinations and underwent a structured clinical interview to exclude psychiatric disorders using the Structured Clinical Interview for DSM-V guidelines [14].

Participants with a history of hypertension, diabetes, or eye or head trauma were excluded. Participants reporting a history of drug abuse, a history of addiction, glaucoma (intraocular pressure >21 mmHg), best corrected visual acuity (BCVA) <0.5, cataracts, high astigmatism, or congenital diseases of the optic nerve were also excluded.

Assessment

A complete medical history, physical examination, and laboratory tests were performed,

including measurements of systolic blood pressure (SBP) and diastolic blood pressure (DBP). Then, we calculated the mean arterial pressure (MAP). The body mass index (BMI) was also recorded [15].

The Positive and Negative Syndrome Scale (PANSS) [16] was administered to the patient group by two psychiatrists. The consistency test produced a Kappa value of 0.80. A Chinese version of the Wechsler Adult Intelligence Scale (WAIS) [17] was administered by another psychiatrist. We surveyed the patients' histories and recorded the dosage and duration of prescribed antipsychotic drugs. The total dosage of antipsychotic drugs used by each participant was converted to the equivalent amount of olanzapine according to the conversion table of antipsychotic drugs [18].

Measurement of the retinal vessel diameter

The BCVA was measured in each eye using the Snellen visual acuity test. An anterior slit lamp and Goldman tonometer were used to exclude potential participants with eye diseases and measure the intraocular pressure. Optical coherence tomography (OCT) was performed with a 90D focusing lens in the fundus examination to observe and exclude participants with diseases of the retinal nerve fibre layer (RNFL) or macula around the disc.

Binocular fundus photography: The subjects were seated with the mandible placed on the jaw tray and the forehead tightly attached to the headband. The ophthalmologist selected a 35-degree horizontal line of sight deviation to the nose, and used OCT to capture a digital image of the retina (TOPCON-2001, made in Japan). OCT is a widely accepted method to obtain objective measurements and analyse fundus photographs [19].

No differences of the diameter of the retinal vessels in the corresponding quadrants were observed between the two eyes of a normal individual. However, the diameters of retinal vessels in different monocular quadrants vary substantially [20]. Thus, the retinal artery and its accompanying vein were measured in the temporal quadrant of the annular region located 1.0-2.0 disc diameters from the optic disc margin, where the diameters of both were the thickest and least variable. The measurement

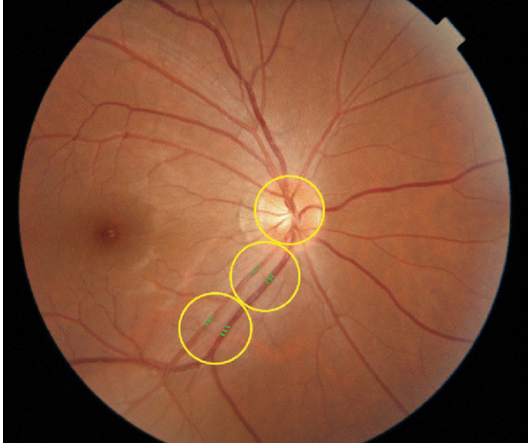


Figure 1. Binocular fundus photography. The largest artery and the largest vein in the temporal quadrant of the annular region located 1.0-2.0 disc diameters from the optic disc margin of each eye were selected by the technician, and the diameters of the four selected vessels were measured using a semiautomated software package ('ImageJ').

line was perpendicular to the wall of the vessels.

An engineer of ophthalmology who was blinded to the study design used 'ImageJ' to analyse the photographed data. Both eyes were examined from the 165 patients with schizophrenia and 72 healthy control subjects, who were matched for age and sex. As shown in **Figure 1**, the largest artery and the largest vein in the temporal quadrant of the annular region located 1.0-2.0 disc diameters from the optic disc margin of each eye were selected by the technician, and the diameters of the four selected vessels were measured using a semiautomated software package ('ImageJ').

The measurement area was located in the range of 1.0-2.0 disc diameters from the edge of the disc, as shown in **Figure 1** [10]. 'ImageJ' version 1.48 software (<https://imagej.en.softonic.com>) was used to measure the retinal arteriovenous diameter (pixel) in this area. ImageJ is an image processing software based on Java developed by the National Institutes of Health that has been used to calculate regional and pixel statistics of images, calculate distances and angles, and create histograms and sectional drawings for Fu Liye trans-forms [21].

The measured results were displayed automatically. Each vessel was measured 5 times, and the interval of each measurement was selected

to be as equal as possible. The advantage of ImageJ is that it has been used as a platform for image processing and analysis based on its powerful colour image processing and 3D image processing functions, and it is able to process many types of images without the need for other software [22]. It automatically extracts the edge of blood vessels and reduces the error of manual measurements. It has been widely used in the field of medical imaging diagnostics.

Blood tests

Blood samples were taken at the same time in the morning (6.30 a.m.) after an overnight fast. Blood naturally coagulated at room temperature for 10-20 minutes and was centrifuged for approximately 10 minutes (3000 rpm). Serum was separated, aliquoted, rapidly frozen and stored at -80°C until analysed. Vascular Endothelial cell Growth Factor (VEGF) was analysed using 96-well ELISA kits supplied by Abcam (USA). The experimental protocol strictly followed the instructions provided by Abcam Technology. All tests were executed in double. The calibrator was simultaneously tested with each batch of samples, and a standard curve was generated in each instance [23]. All blood samples were assayed by a laboratory technician with certification who was blinded to the clinical study. The serum cholesterol, triglyceride, glucose, alanine aminotransferase (ALT), aspartate aminotransferase (AST), and uric acid (UA) levels were also assayed.

Statistical analysis

All data were analysed using SPSS 17.0 statistical software. An independent t-test was used to analyse the data from one eye between matched patients and controls. A Chi square analysis was used for the count data. The Shapiro-Wilk test was used to assess whether the data were normally distributed. We calculated Pearson's correlation coefficients to examine whether the demographic and clinical variables were associated with the retinal arteriovenous diameter. After considering the potential effects of smoking and other factors [11, 24], an analysis of covariance (ANCOVA) was used to compare the demographic and clinical variables among the subgroups with schizophrenia after controlling for confounding variables, including age, sex, BMI, MAP, olan-

Retinal microveins in schizophrenia

Table 1. Participant demographics and a comparison of the average vascular diameter around the optic disc in the patients with schizophrenia and control subjects

Mean ± SD	Schizophrenia group	Control group	t/χ ²	p
Age (years)	42.30±11.49	40.60±8.30	1.287	0.256
Sex				
Female (n)	76	34	2.741	0.941
Male (n)	89	38		
Duration of illness (years)	18.38±11.44	-		
BMI ¹	24.01±4.55	24.87±2.85	-1.402	0.164
Smokers/non-smokers (n)	33/132	17/55	0.393	0.531
SBP ² (mmHg)	108.21±11.09	110.26±9.86	-1.056	0.292
DBP ³ (mmHg)	68.27±7.36	73.07±6.94	-3.705	0.002
MAP ⁴ (mmHg)	81.58±8.04	84.79±7.92	-2.294	0.023
Eye pressure (left eye, mmHg)	14.72±3.92	15.88±3.31	-1.411	0.160
IQ	121.92±8.75	130.68±9.48	-2.249	0.045
Glucose (mmol/L)	4.66±0.64	5.21±0.87	-4.805	<0.001
Cholesterol (mmol/L)	3.92±0.75	4.96±0.82	-8.334	<0.001
Triglyceride (mmol/L)	1.75±0.96	1.46±0.81	1.927	0.055
AST ⁵ (U/L)	22.89±13.06	20.81±9.81	1.028	0.305
ALT ⁶ (U/L)	25.78±23.31	23.63±17.39	0.596	0.552
UA ⁷ (mmol/L)	355.33±84.72	344.73±88.36	0.741	0.460
VEGF	999.34±159.61	1025.43±190.00	-0.727	0.469
Right vein (pixels)	16.22±2.78	14.60±2.91	3.966	<0.001
Left vein (pixels)	16.24±2.43	14.96±2.16	4.027	<0.001
Right artery (pixels)	9.36±1.69	8.41±1.58	4.431	<0.001
Left artery (pixels)	9.50±1.67	8.76±1.15	3.335	0.001
PANSS ⁸ positive	16.87±6.90	-		
PANSS negative	21.42±7.76	-		
PANSS total	69.46±20.63	-		

1. Body Mass Index, 2. Systolic blood pressure, 3. Diastolic blood pressure, 4. Mean arterial pressure, 5. Aspartate amino-transferase, 6. Alanine aminotransferase, 7. Uric acid, 8. Vascular Endothelial cell Growth Factor 9. Positive and Negative Syndrome Scale.

zapine equivalent dose (OED), and glucose and cholesterol levels. Post-hoc comparison Least Significant Difference (LSD) test was then performed. A partial correlation analysis was also used to examine the relationships among the retinal vessels, family history and duration of illness after controlling for the confounding variables (age, sex, BMI, MAP, OED, and glucose and cholesterol levels). In addition, a stepwise multiple linear regression analysis was used to examine the effects of the demographic and clinical variables on the optic disc blood vessels in the right eye. We performed a partial correlation analysis to examine the relationships between the optic disc blood vessels and PANSS or IQ in patients with schizophrenia. Two-tailed *p*-values <0.05 were considered statistically significant, and the power analysis was performed using

G*power (<http://www.softpedia.com/get/Science-CAD/G-Power.shtml>).

Results

Basic characteristics

A total of 165 patients and 72 age-and-sex-matched normal controls were included in the final analysis. The age range of the 237 subjects was 18 to 56 years.

Comparison of vessel diameters of the optic disk

There were no significant differences between the left and right vessel diameters of the optic disk (artery *t*=1.188, *P*=0.236; vein *t*=1.209, *P*=0.228). As shown in **Table 1**, we detected a significant difference in the diameters of the

Retinal microveins in schizophrenia

Table 2. Comparison of the average vascular diameter around the optic disc among the acute, chronic, and long-term schizophrenia groups and normal control group (subgroup, df=3)

Mean ± SD/n	Acute group	Chronic group	Long-term group	Normal group	F	P1	P2 (LSD)
N	15	39	112	72			
Right vein (pixels)	16.39±2.51	16.25±2.93	16.20±2.78	14.60±2.91	5.11	0.002	<0.001 ¹ /0.005 ² /0.033 ³
Right artery (pixels)	9.67±1.61	9.15±1.49	9.41±1.77	8.41±1.58	5.69	0.001	<0.001 ¹ /0.029 ² /0.01 ³
Left vein (pixels)	16.05±1.68	16.34±2.43	16.22±2.52	14.96±2.16	4.42	0.005	0.001 ¹ /0.005 ²
Left artery (pixels)	9.54±1.28	9.53±1.03	9.49±1.91	8.76±1.15	3.62	0.014	0.003 ¹ /0.023 ²
Duration of illness (years)	16.94±10.28	17.48±11.01	18.46±11.56	-	-	-	0.169 ⁴

¹p-value: long-term chronic group compared with the normal control group; ²p-value: chronic group compared with the normal control group; ³p-value: acute group compared with the normal control group; ⁴p-value: compared between patient groups.

arteries and veins of the optic disc between the patients with schizophrenia and the normal controls ($P \leq 0.001$).

Evaluation of blood glucose and cholesterol levels

The blood glucose and cholesterol levels were also significantly different between the patients and normal controls and were further adjusted in the multivariate regression analysis. However, no significant difference in the duration of illness was observed among the three subgroups in the ANCOVA after post-hoc comparison (**Table 2**).

Correlation between the retinal vessels and the duration of illness

We analysed the correlation between the retinal vessels and the duration of illness using a partial correlation analysis. Neither the diameter of the artery nor vein was associated with the duration of illness in schizophrenia group (right vein: $r = -0.242$, $P = 0.256$; left vein: $r = -0.219$, $P = 0.315$; right artery: $r = -0.103$, $P = 0.641$; left artery: $r = 0.075$, $P = 0.735$). The correlation between the right eye arterioles and venules was not significant ($r = 0.312$, $P = 0.147$), but the correlation was significant in the left eyes ($r = 0.469$, $P = 0.024$).

Comparison between patients with positive family history and negative family history

There were no significant correlations between the average vessel diameter of the optic disc and IQ (total score: 79.10 ± 28.65 , $P > 0.05$), VEGF or symptoms ($P > 0.05$). The OED (mg/day) did not differ significantly between the patients with positive family history and negative family history (1316.62 ± 1538.05 vs. 494.17 ± 583.46 , $t = 1.79$, $P = 0.098$). Similarly, no sig-

nificant differences of BMI (24.79 ± 3.35 vs. 23.88 ± 4.73 , $t = 0.74$, $P = 0.463$) and age (42.42 ± 10.24 vs. 42.29 ± 11.68 , $t = 0.05$, $P = 0.962$) were observed. Glucose, cholesterol, triglyceride, ALT, AST, VEGF and UA levels also did not exhibit significant differences between the two patient groups ($P > 0.05$). The patients of schizophrenia especially with a positive family history of schizophrenia displayed a greater enlargement of the retinal vessels than normal (**Table 3**).

Correlation between positive family history of schizophrenia and the vascular diameter around the optic disc in schizophrenia group

Age, sex, smoking, BMI, duration of illness, OED, glucose level, cholesterol level, MAP and family history were included as independent variables using the backward stepwise method in the multiple linear regression analysis, and the retinal vessel diameter was the dependent variable. Only family history of patients group was entered last into the effective models, which showed significant correlations with the diameters of the retinal veins (**Table 4**). Greater retinal vein dilatation of both eyes and retinal artery of right eye was observed among the patients with positive family history of schizophrenia than the patients with negative family history and the normal controls after controlling for confounding factors (age, sex, BMI, MAP, OED, and glucose and cholesterol levels) ($P < 0.001$). Enlargement of retinal veins was shown to be highly accumulated in schizophrenia families.

Discussion

In current study, noninvasive fundus photography was used to observe abnormal fundus blood vessels in patients with schizophrenia. We provided evidence that the enlargement of

Retinal microveins in schizophrenia

Table 3. Comparison of the average vascular diameter around the optic disc among patients with schizophrenia who had positive or negative family histories and normal controls

	Positive family History	Negative family history	Normal control (no family history)	F/X ²	P
N	20	145	72		
Male (n)	14	75	38	2.39	0.303
Smokers	4	29	17	0.39	0.824
Age (years)	42.42±10.24	42.29±11.68	40.60±8.30		
Glucose	4.64±0.84	4.67±0.61	4.96±0.82	11.51	<0.001
Cholesterol	3.64±0.72	3.96±0.75	4.96±0.82	36.65	<0.001
Triglyceride	1.84±1.02	1.73±0.95	1.46±0.81	1.96	0.143
OED ¹ (mg/day)	1316.62±1538.05	494.17±583.46	-	1.79	0.098
VEGF	1038.78±219.74	1017.35±175.90	1025.43±190.00	0.219	0.803
BMI ²	24.79±3.35	23.88±4.73	24.87±2.85	0.89	0.413
Right artery	10.10±1.22	9.26±1.72	8.40±1.59	10.16	<0.001
Right vein	17.64±2.19	16.02±2.81	14.60±2.93	10.51	<0.001
Left artery	9.73±1.22	9.47±1.73	8.77±1.39	5.66	0.004
Left vein	17.64±1.36	16.05±2.48	15.00±2.15	10.38	<0.001

1. olanzapine equivalent dose, 2. Body Mass Index.

Table 4. Correlation between positive family history of schizophrenia and the vascular diameter around the optic disc (linear regression analysis) in patients group

	constant	*Positive family history			
		β	S.E.	t	p
Right artery	10.06	-1.015	0.282	-3.602	<0.001
Right vein	19.32	-1.626	0.477	-3.411	0.001
Left artery	11.39	-0.424	0.287	-1.478	0.142
Left vein	16.01	-1.051	0.385	-2.730	0.007

*Using a positive family history of schizophrenia as an independent variable after controlling for age, sex, BMI, MAP, OED, and glucose and cholesterol levels. β of the multivariate models shows the variation in the dependent variables (Y-axis) following a decrease in the risk with a family history (X-axis: 1, positive Sch; 2, negative Sch; and 3, normal control).

the retinal veins in patients with schizophrenia is noticeably different from normal individuals, regardless of the duration of illness. Patients with positive family history of schizophrenia presented wider optic vessel diameters than patients without family history and normal subjects.

Following the development of the central nervous system, nerves and blood vessels gradually establish close and complicated interacting networks to ensure adequate tissue perfusion. The lack of tissue oxygenation and metabolic supply caused by a disruption of the microcircu-

lation has gradually been considered as a pathogenic process of neurodegenerative diseases [25]. Schizophrenia was initially described as early onset dementia because of severe cognitive impairment, which is the main clinical symptom of Alzheimer's dementia and has strong ties to an autoimmune hypothesis [26]. We speculate that cognitive impairment may be associated with an abnormal vascular structure in the fundus. Stimulation with recombinant human erythropoietin promotes angiogenesis and markedly improves cognitive function in patients with schizophrenia [27], highlighting the close correlation between cognitive function and brain blood vessels. IQ test is part of a cognitive function assessment. Previous studies showed that IQ in patients with schizophrenia is lower than healthy people that these results were also observed in our study. In addition some studies demonstrated that with increases of disease duration, IQ decreased [28]. However, we did not observe a relationship between the diameters of retinal vessels and IQ in our research. Currently, relationship between retinal vein occlusions and cognition has not been identified in a large-scale ophthalmological study [29]. But the pathophysiology of schizophrenia has been reported to be related to the angiogenesis of the microvascular system [3, 4]. Vascular endothelial growth factor (VEGF) levels are increased in patients with schizophrenia experiencing medicated multi-

ple-episode psychosis compared to patients experiencing first-episode psychosis, according to a meta-analysis [30]. The development of schizophrenia may be related to microangiopathy, which forms through a similar process to angina pectoris [3]. Therefore, retinal vein enlargement may also be related to the long-term antipsychotic intervention, as the diameter of the retinal vessels gradually changes from contraction to expansion, which in turn obscures these subtle changes.

One study based on MRI scanner has revealed extensive abnormalities in the cerebral microvasculature of patients with schizophrenia [31]. In our study, the retinal microvascular dilatation further confirms the abnormalities in the cerebral vascular system. In animal experiments, cortical areas and the hippocampus also showed age-dependent increases in capillary spacing and an increased blood vessel diameter with surgery [32]. In our study, we did not identify an apparent effect of the duration of illness of schizophrenia. Schizophrenia has an obvious tendency to cluster within families. The retinal vessels showed greater enlargement among schizophrenia patients with positive family history. This finding may be related to the regional changes in brain haemodynamics in patients with schizophrenia [33].

Regional changes in brain haemodynamics have been reported to be associated with both the positive and negative symptoms of the PANSS [34, 35]. This finding appears to be consistent with the findings reported by M.H. Meier, who found that the diameters of retinal venules in patients presenting with psychosis symptoms were wider than normal controls, and the diameters of the healthy twins were intermediate between the two groups. Thus, the pathophysiological mechanism of psychosis may begin at the level of microtubule system from early life, and extensive retinal venules may be a marker of family susceptibility to psychosis [11]. This evidence provides strong support to our research hypothesis of schizophrenia. However, in our study, we did not identify a relationship between the psychiatric symptoms and retinal vessel diameters. Further prospective studies are required to confirm it.

Serum VEGF and corticosterone levels were found decreased following the state of prenatal hypoxia in schizophrenia [36]. We didn't

find the relationship between VEGF and retinal vessels in our study, which is possible due to that the morphology of retinal primitive vessels is not affected by VEGF level.

There were also some limitations in this study. This was a cross-sectional study, thus it was unable to explore the retinal vasculature before the onset of schizophrenia. We included only Chinese population of hospitalized patients. The subgroup analysis on patients with or without a family history was based on a small number of individuals with a family history. The state of fundus vascularization in the absence of the onset of disease is difficult to determine. In the detection of fundus blood vessels, which was conducted by a professional who performed a blinded assessment, the selection of blood vessels was based on the investigator's experience. Further research with strict study design and large sample size is needed.

In conclusion, patients who develop schizophrenia may have a wider retinal venular calibre. Moreover, the diameters of retinal vessels are not influenced by the duration of illness but are associated with symptoms and, thus, may serve as a genetic biomarker of schizophrenia. Fundus photography is a simple and direct non-invasive method to investigate the microvascular structure in the eye, which is homologous to that in the brain.

Acknowledgements

This research is supported by Beijing Municipal Science & Technology Commission (BMST) NO Z181100001718115 and Beijing traditional Chinese medicine science and technology (BTCM) project No. JJ2016-13. The BTCM has no role in the design of this study and will not have any role during its execution, analyses, interpretation of the data. It provided in-kind contributions through the involvement of schizophrenia study. The project of BMST managed by YH Liu is specially used in the study about retinal abnormality of schizophrenia.

Disclosure of conflict of interest

None.

Address correspondence to: Fude Yang, Department of Psychiatry, Beijing Huilongguan Hospital, Huilongguan Clinical Institute of Peking University,

Nandian Road, Changping District, Beijing 100096, China. Tel: +86-10-83024251; Fax: +86-10-8302-4302; E-mail: fudeyang@yandex.com

References

- [1] Crespo-Facorro B, Paradiso S, Andreasen NC, O'Leary DS, Watkins GL, Ponto LL and Hichwa RD. Neural mechanisms of anhedonia in schizophrenia: a PET study of response to unpleasant and pleasant odors. *JAMA* 2001; 286: 427-435.
- [2] Kiehl TR, Chow EW, Mikulis DJ, George SR and Bassett AS. Neuropathologic features in adults with 22q11.2 deletion syndrome. *Cereb Cortex* 2009; 19: 153-164.
- [3] Moises HW, Wollschlager D and Binder H. Functional genomics indicate that schizophrenia may be an adult vascular-ischemic disorder. *Transl Psychiatry* 2015; 5: e616.
- [4] Schmidt-Kastner R, van Os J, Esquivel G, Steinbusch HW and Rutten BP. An environmental analysis of genes associated with schizophrenia: hypoxia and vascular factors as interacting elements in the neurodevelopmental model. *Mol Psychiatry* 2012; 17: 1194-1205.
- [5] Arichika S, Uji A, Ooto S, Muraoka Y and Yoshimura N. Comparison of retinal vessel measurements using adaptive optics scanning laser ophthalmoscopy and optical coherence tomography. *Jpn J Ophthalmol* 2016; 60: 166-171.
- [6] Yip W, Tham YC, Hsu W, Lee ML, Klein R, Klein B, Ikram MK, Wong TY and Cheung CY. Comparison of common retinal vessel caliber measurement software and a conversion algorithm. *Transl Vis Sci Technol* 2016; 5: 11.
- [7] Bhuiyan A, Karmakar C, Kawasaki R, Lamoureux E, Ramamohanarao K, Kanagasalingam Y and Wong TY. Retinal artery and venular caliber grading: a semi-automated evaluation tool. *Comput Biol Med* 2014; 44: 1-9.
- [8] Tang XN, Berman AE, Swanson RA and Yenari MA. Digitally quantifying cerebral hemorrhage using Photoshop and Image J. *J Neurosci Methods* 2010; 190: 240-243.
- [9] Kim US, Kim SJ, Baek SH, Kim HK and Sohn YH. Quantitative analysis of optic disc color. *Korean J Ophthalmol* 2011; 25: 174-177.
- [10] Meier MH, Shalev I, Moffitt TE, Kapur S, Keefe RS, Wong TY, Belsky DW, Harrington H, Hogan S, Houts R, Caspi A and Poulton R. Microvascular abnormality in schizophrenia as shown by retinal imaging. *Am J Psychiatry* 2013; 170: 1451-1459.
- [11] Meier MH, Gillespie NA, Hansell NK, Hewitt AW, Hickie IB, Lu Y, McGrath J, MacGregor S, Medland SE, Sun C, Wong TY, Wright MJ, Zhu G, Martin NG and Mackey DA. Retinal microvessels reflect familial vulnerability to psychotic symptoms: a comparison of twins discordant for psychotic symptoms and controls. *Schizophr Res* 2015; 164: 47-52.
- [12] Young JW, Winstanley CA, Brady AM and Hall FS. Research domain criteria versus DSM V: how does this debate affect attempts to model corticostriatal dysfunction in animals? *Neurosci Biobehav Rev* 2017; 76: 301-316.
- [13] Lee WW, Tajunisah I, Sharmilla K, Peyman M and Subrayan V. Retinal nerve fiber layer structure abnormalities in schizophrenia and its relationship to disease state: evidence from optical coherence tomography. *Invest Ophthalmol Vis Sci* 2013; 54: 7785-7792.
- [14] Tay L, Lim WS, Chan M, Ali N, Mahanum S, Chew P, Lim J and Chong MS. New DSM-V neurocognitive disorders criteria and their impact on diagnostic classifications of mild cognitive impairment and dementia in a memory clinic setting. *Am J Geriatr Psychiatry* 2015; 23: 768-779.
- [15] Tayyari F, Venkataraman ST, Gilmore ED, Wong T, Fisher J and Hudson C. The relationship between retinal vascular reactivity and arteriolar diameter in response to metabolic provocation. *Invest Ophthalmol Vis Sci* 2009; 50: 4814-4821.
- [16] Kay SR, Fiszbein A and Opler LA. The positive and negative syndrome scale (PANSS) for schizophrenia. *Schizophr Bull* 1987; 13: 261-276.
- [17] Yamamoto D, Kazui H and Takeda M. Wechsler Adult Intelligence Scale-III (WAIS-III). *Nihon Rinsho* 2011; 69 Suppl 8: 403-407.
- [18] Leucht S, Samara M, Heres S and Davis JM. Dose equivalents for antipsychotic drugs: the DDD method. *Schizophr Bull* 2016; 42 Suppl 1: S90-94.
- [19] Ouyang Y, Shao Q, Scharf D, Jousseaume AM and Heussen FM. Retinal vessel diameter measurements by spectral domain optical coherence tomography. *Graefes Arch Clin Exp Ophthalmol* 2015; 253: 499-509.
- [20] Ikram MK, Wittman JC, Vingerling JR, Breteler MM, Hofman A and de Jong PT. Retinal vessel diameters and risk of hypertension: the rotterdam study. *Hypertension* 2006; 47: 189-194.
- [21] Shalev I, Moffitt TE, Wong TY, Meier MH, Houts RM, Ding J, Cheung CY, Ikram MK, Caspi A and Poulton R. Retinal vessel caliber and lifelong neuropsychological functioning: retinal imaging as an investigative tool for cognitive epidemiology. *Psychol Sci* 2013; 24: 1198-1207.
- [22] Fischer MJ, Uchida S and Messlinger K. Measurement of meningeal blood vessel diameter in vivo with a plug-in for ImageJ. *Microvasc Res* 2010; 80: 258-266.
- [23] Murugavel S, Bugyei-Twum A, Matkar PN, Al-Mubarak H, Chen HH, Adam M, Jain S, Narang T, Abidin RM, Qadura M, Connelly KA, Leong-Poi

Retinal microveins in schizophrenia

- H and Singh KK. Valproic acid induces endothelial-to-mesenchymal transition-like phenotypic switching. *Front Pharmacol* 2018; 9: 737.
- [24] Newman A, Andrew N and Casson R. Review of the association between retinal microvascular characteristics and eye disease. *Clin Exp Ophthalmol* 2018; 46: 531-552.
- [25] Miloudi K, Dejda A, Binet F, Lapalme E, Cerani A and Sapieha P. Assessment of vascular regeneration in the CNS using the mouse retina. *J Vis Exp* 2014; e51351.
- [26] Benros ME, Nielsen PR, Nordentoft M, Eaton WW, Dalton SO and Mortensen PB. Autoimmune diseases and severe infections as risk factors for schizophrenia: a 30-year population-based register study. *Am J Psychiatry* 2011; 168: 1303-1310.
- [27] Chai HT, Yip HK, Sun CK, Hsu SY and Leu S. AG490 suppresses EPO-mediated activation of JAK2-STAT but enhances blood flow recovery in rats with critical limb ischemia. *J Inflamm (Lond)* 2016; 13: 18.
- [28] Van Haren NEM, Van Dam DS and Stellato RK; Genetic Risk and Outcome of Psychosis (GROUP) investigators. Change in IQ in schizophrenia patients and their siblings: a controlled longitudinal study. *Psychol Med* 2019; 49: 2573-2581.
- [29] Jonas JB, Wei WB, Zhu LP, Xu L and Wang YX. Cognitive function and ophthalmological diseases: the Beijing Eye Study. *Sci Rep* 2018; 8: 4816.
- [30] Misiak B, Stramecki F, Stanczykiewicz B, Frydecka D and Lubeiro A. Vascular endothelial growth factor in patients with schizophrenia: a systematic review and meta-analysis. *Prog Neuropsychopharmacol Biol Psychiatry* 2018; 86: 24-29.
- [31] Hua J, Brandt AS, Lee S, Blair NIS, Wu Y, Lui S, Patel J, Faria AV, Lim IAL, Unschuld PG, Pekar JJ, van Zijl PCM, Ross CA and Margolis RL. Abnormal grey matter arteriolar cerebral blood volume in schizophrenia measured with 3D inflow-based vascular-space-occupancy MRI at 7T. *Schizophr Bull* 2017; 43: 620-632.
- [32] Sonntag WE, Lynch CD, Cooney PT and Hutchins PM. Decreases in cerebral microvasculature with age are associated with the decline in growth hormone and insulin-like growth factor 1. *Endocrinology* 1997; 138: 3515-3520.
- [33] Blinder P, Tsai PS, Kaufhold JP, Knutsen PM, Suhl H and Kleinfeld D. The cortical angiome: an interconnected vascular network with non-columnar patterns of blood flow. *Nat Neurosci* 2013; 16: 889-897.
- [34] Pinkham A, Loughead J, Ruparel K, Wu WC, Overton E, Gur R and Gur R. Resting quantitative cerebral blood flow in schizophrenia measured by pulsed arterial spin labeling perfusion MRI. *Psychiatry Res* 2011; 194: 64-72.
- [35] Schobel SA, Chaudhury NH, Khan UA, Paniagua B, Styner MA, Asllani I, Inbar BP, Corcoran CM, Lieberman JA, Moore H and Small SA. Imaging patients with psychosis and a mouse model establishes a spreading pattern of hippocampal dysfunction and implicates glutamate as a driver. *Neuron* 2013; 78: 81-93.
- [36] Howell KR and Pillai A. Effects of prenatal hypoxia on schizophrenia-related phenotypes in heterozygous reeler mice: a gene x environment interaction study. *Eur Neuropsychopharmacol* 2014; 24: 1324-1336.