

Original Article

A case of delayed contralateral oculomotor nerve palsy after microsurgical clipping of a posterior communicating artery aneurysm

Yang Sun^{1*}, Guangquan Li^{1,2*}, Kun Hou¹, Xianfeng Gao¹, Xiaobo Zhu¹

¹Department of Neurosurgery, The First Hospital of Jilin University, Changchun, P. R. China; ²Jilin Provincial Key Laboratory on Molecular and Chemical Genetics, The Second Hospital of Jilin University, Changchun, P. R. China.

*Equal contributors.

Received November 19, 2015; Accepted January 25, 2016; Epub July 15, 2016; Published July 30, 2016

Abstract: Delayed postoperative oculomotor nerve palsy is a rare complication that occurs in the setting of microsurgical aneurysm clipping. While a number of theories have been postulated to explain the development of delayed postoperative oculomotor nerve palsies, the underlying pathophysiology of such complications still remain to be elucidated. In this report, we present a case of delayed postoperative isolated contralateral oculomotor nerve palsy after clipping of a posterior communicating artery aneurysm, which we believe may be attributed to lumbar over drainage. With timely and appropriate management, complete neurologic recovery was achieved.

Keywords: Oculomotor nerve palsy, posterior communicating artery aneurysm, postoperative, subarachnoid hemorrhage

Introduction

Oculomotor nerve is the third cranial nerve that enters the orbit through the superior orbital fissure and controls muscles that drive most movements of the eye and raise the eyelid [1]. Oculomotor nerve is derived from the basal plate of the embryonic midbrain. Cranial nerves IV and VI also participate in the control of eye movement. Oculomotor nerve palsy is an eye condition resulting from damage to the third cranial nerve or a branch thereof. As the name suggests, oculomotor nerve supplies the majority of the muscles that control eye movements. Therefore, damages to oculomotor nerve will render affected individuals unable to move his or her eye normally. Unilateral oculomotor nerve palsy is often encountered in the setting of ipsilateral aneurysms located at the posterior communicating artery (PcomA), internal carotid artery (ICA) or their junction (PcomA/ICA) [2]. There have been some reports on oculomotor nerve palsy as a result of aneurysms in basilar tip, anterior artery or anterior communicating artery [3-5]. In the present report, we describe a case of PcomA aneurysm presenting with contralateral postoperative delayed oculo-

motor nerve palsy that is thought to be attributed to lumbar catheter over drainage.

Case report

A 46-year-old female with no significant past medical history or contributing family history complained about sudden explosive headache for two hours on admission at our hospital. Physical examination results were within normal limits except for considerable neck stiffness. Computed tomography (CT) scan demonstrated diffuse subarachnoid hemorrhage, which was especially concentrated in ambient, interpeduncular and suprasellar cisterns (**Figure 1**). CT angiography (CTA) revealed an aneurysm located at the proximal end of the right PcomA to ICA (**Figure 2**). Preoperatively, a lumbar catheter was placed after general anesthesia induction to facilitate intraoperative brain relaxation and postoperative drainage of bloody cerebrospinal fluid (CSF). The aneurysm was microsurgically clipped via the right pterional approach. CSF (250 ml) was drained via lumbar catheter during postoperative day one, after which the CSF was clear enough to withdraw

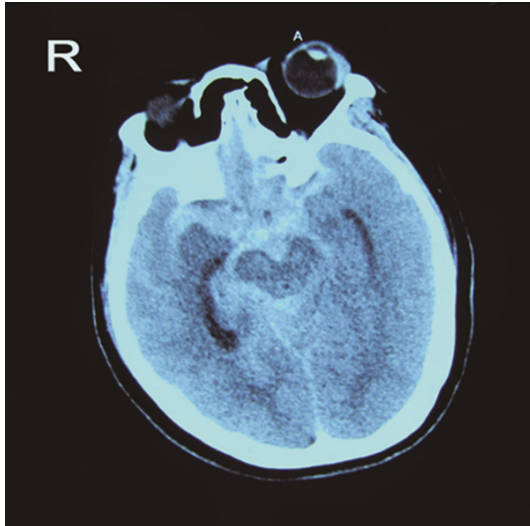


Figure 1. Computed tomography of the head showing diffuse subarachnoid hemorrhage especially concentrated in ambient, interpeduncular and suprasellar cisterns.

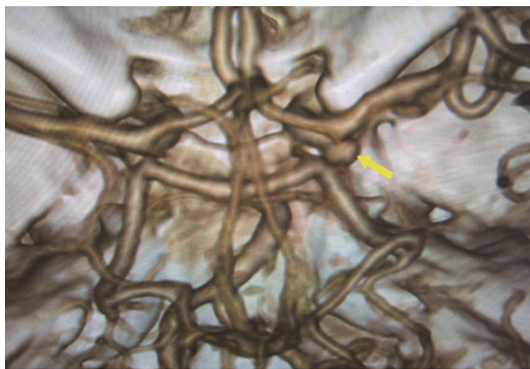


Figure 2. Computed tomography angiography showing an aneurysm located at the proximal end of the right posterior communicating artery to internal carotid artery. The arrow indicates the aneurysm.

the catheter. On postoperative day three, the patient developed a complete left third nerve palsy characterized by the presence of dilated pupil, ptosis, and downward deviation and abduction of the eyeball. CT scan revealed no postoperative intracranial hematoma, and the surgical clip was in the proper location. However, compression of the basal cisterns and assessment of the ventricular system were noted (**Figure 3**). Postoperative CTA showed no existence of another aneurysm or vasospasm. Furthermore, transcranial Doppler ultrasonography demonstrated that the velocity of blood flow within bilateral middle cerebral arteries was less than 100 cm/s. As CSF overdrainage

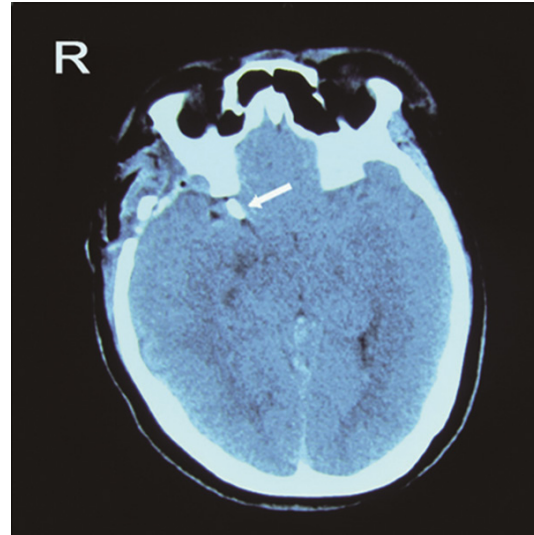


Figure 3. Computed tomography of the head showing tight basal cisterns and ventricular system, as well as a slight midline shift. The clip is perfectly in situ. The arrow indicates the clip.

was suspected, temporary clipping of the catheter combined with normal saline hydration was initiated. The external ocular muscles of the patient returned to baseline six hours after temporary clipping of the catheter, and her left ptosis was resolved three days later. On postoperative day 10, the lumbar catheter was removed. The patient was discharged 2 weeks after the surgery. At this point, her mydriasis was still present to a lesser extent. At one-month follow-up, the patient's pupil was slightly contracted and reflexed reluctantly to direct and indirect light stimulation. At her last follow-up three months after the surgery, all neurologic deficits had been resolved.

Discussion

There are many proposed hypotheses pertaining to the etiology of oculomotor nerve palsy before and after aneurysm surgery. Direct compression by the aneurysm is the most classic and common cause. Other causes include direct injury to the third nerve intraoperatively [6], microvascular ischemia [7], focal hematoma formation [8], vasospasm [9], anomaly of the vessels along the oculomotor nerve [1], elevated intracranial pressure and herniation, compression by intracranial structures other than aneurysms [10], and undetermined origins [11].

Delayed contralateral oculomotor nerve palsy

In the present case, compression by aneurysm may not be possible, because of the anatomical distance between the two entities. Delayed onset of oculomotor nerve palsy lowers the possibility of direct surgical insult. Postoperative CT, CTA and the indwelling of lumbar catheter decrease the chances of hematoma formation, vasospasm and elevated intracranial pressure. Although we cannot rule out the possibility of ischemic injury to the oculomotor nerve, several facts make this less likely. First, our patient did not have pre-existing co-morbidities such as diabetes or hypertension. In addition, small-vessel ischemic injury to oculomotor nerve usually exhibits pupil-sparing [7], whereas our patient demonstrated a blown pupil.

When comparing pre- and post-operative CT imaging, we find that postoperative CT scan has demonstrated tighter basal cisterns and a more compact ventricular system. In addition, there has been a slight midline shift to the left, raising the plausibility of overdrainage of CSF from the lumbar catheter, because collapsed cerebral cisterns and shifted midline structures might collectively push the oculomotor nerve to the tentorial notch or the brain tissue. Therefore, we speculate that mechanical compression is the mechanism that causes the third nerve palsy in the patient. Although family of the patient refused a further magnetic resonance imaging scan, our hypothesis is still supported by the fact that the recovery process first began from extraocular muscles, and later exhibited the resolution of parasympathetic deficits. In conclusion, delayed postoperative oculomotor nerve palsy is rarely encountered in patients with aneurysms, especially when it occurs contralaterally. Here, we present a case where overdrainage of CSF through a lumbar catheter leads to the development of the third nerve palsy. With early diagnosis and timely intervention, complete recovery can be achieved.

Acknowledgements

This research was supported by grants from the National Natural Science Foundation of China (No. 81401649) and the Natural Science Foundation of Jilin Province.

Disclosure of conflict of interest

None.

Address correspondence to: Xiaobo Zhu, Department of Neurosurgery, The First Hospital of Jilin University, No. 3302, Jilin Road, Changchun, Jilin Province, P. R. China. Tel: 86-431-85619481; Fax: 86-431-84808174; E-mail: bobozhu1962@sohu.com

References

- [1] Richards BW, Jones FR Jr and Younge BR. Causes and prognosis in 4,278 cases of paralysis of the oculomotor, trochlear, and abducens cranial nerves. *Am J Ophthalmol* 1992; 113: 489-496.
- [2] Green WR, Hackett ER and Schlezinger NS. Neuro-Ophthalmologic Evaluation Of Oculomotor Nerve Paralysis. *Arch Ophthalmol* 1964; 72: 154-167.
- [3] Fairbanks C and White JB. Oculomotor nerve palsy in the setting of an anterior cerebral A2 segment aneurysm. *J Neurointerv Surg* 2011; 3: 74-76.
- [4] Boccardo M, Ruelle A and Banchemo MA. Isolated oculomotor palsy caused by aneurysm of the basilar artery bifurcation. *J Neurol* 1986; 233: 61-62.
- [5] Aiba T and Fukuda M. Unilateral oculomotor nerve paresis associated with anterior communicating artery aneurysm rupture—two case reports. *Neurol Med Chir (Tokyo)* 2003; 43: 484-487.
- [6] Grayson MC, Soni SR and Spooner VA. Analysis of the recovery of third nerve function after direct surgical intervention for posterior communicating aneurysms. *Br J Ophthalmol* 1974; 58: 118-125.
- [7] Lee SH, Lee SS, Park KY and Han SH. Isolated oculomotor nerve palsy: diagnostic approach using the degree of external and internal dysfunction. *Clin Neurol Neurosurg* 2002; 104: 136-141.
- [8] Balossier A, Postelnicu A, Khouri S, Emery E and Derlon JM. Third nerve palsy induced by a ruptured anterior communicating artery aneurysm. *Br J Neurosurg* 2012; 26: 770-772.
- [9] Kudo T. Postoperative oculomotor palsy due to vasospasm in a patient with a ruptured internal carotid artery aneurysm: a case report. *Neurosurgery* 1986; 19: 274-277.
- [10] Jeon JS, Lee SH, Son YJ and Chung YS. Dissecting aneurysm of vertebral artery manifesting as contralateral abducens nerve palsy. *J Korean Neurosurg Soc* 2013; 53: 194-196.
- [11] White JB, Layton KF and Cloft HJ. Isolated third nerve palsy associated with a ruptured anterior communicating artery aneurysm. *Neurocrit Care* 2007; 7: 260-262.