Int J Clin Exp Med 2016;9(3):6148-6151
www.ijcem.com /ISSN:1940-5901/IJCEM0020901

Original Article

Effect of fully charged and discharged batteries on esophageal tissue: an experimental study

Menduh Oruc[1], Ahmet Yilmaz[2], Nazım Ekin[3], Atilla Durkan[5], Atalay Sahin[5], Yusuf Nergiz[4]

Departments of [1]Chest Surgery, [2]Family Medicine, [3]Gastroenterology, [4]Histology and Embryology, School of Medicine, Dicle University, Diyarbakir, Turkey; [5]Department of Chest Surgery, Gazi Yasargil Training and Research Hospital, Diyarbakır, Turkey

Received December 1, 2015; Accepted February 29, 2016; Epub March 15, 2016; Published March 30, 2016

Abstract: The aim of this study was to compare the effect of charged and discharged alkaline batteries on esophageal tissue, and to determine the impact of duration due to the exposure to alkaline batteries. Thirty-five rabbits were divided into 5 groups each containing 7 rabbits. Alkaline batteries were ingested by rabbits [except for the control group [Group 1]]. Rabbits in Group 2 were exposed to discharged alkaline batteries for 180 minutes. In Group 3-5, the fully charged batteries were left in esophagus for 60, 120, and 180 minutes, respectively. Macroscopic appearance of esophageal mucosa as well as histopathologic examination of battery induced esophageal injury and pH of environment were compared. Battery capsules were intact in each group. No color change was observed in the anode pole of batteries for Group 2. Color change was evident in the anode pole of batteries for 3 rabbits in Group 3, in 4 rabbits in Group 4, and in 7 rabbits from Group 5; while no significant change was observed in any rabbit from Group 2. Histopathologically, mucosal erosion was observed in 7 rabbits of Group 3. In Group 4, mucosal erosion extended to the internal muscular layer. Necrosis was exceeding external muscular layer in Group 5. Alkaline batteries may cause erosion as a result of electrical currency without corrosive substrate leakage. Duration of exposure is an important determinant of tissue injury.

Keywords: Foreign bodies, esophageal perforation, esophagus, trauma

Introduction

Flat batteries account for 2% of all esophageal foreign bodies, which may cause esophageal perforation. Recently, increasing use of batteries in plaything industry, and miniaturizing of batteries, frequency of accidental battery ingestion is more frequently observed that may resulted with esophagitis, perforation, mediastinitis, and even death; especially in childhood period [1-3].

Flat shaped batteries have two major types: flat alkaline batteries and lithium batteries. Flat alkaline batteries may contain manganese, mercury, silver oxide and zinc [4]. Flat alkaline batteries can produce 1.5 volts of energy by using potent alkaline solution. Esophageal tissue injury from flat alkaline batteries arises from leakage of alkaline content due to break up of the battery capsule [5].

In the present study, we aimed to examine the effect of charged and discharged batteries in esophagus of rabbits.

Materials and methods

Thirty-five male rabbits with a mean weight of 2,300 gram (2,000-3,100) were enrolled to examine the effect of flat alkaline batteries on esophageal mucosa. Rabbits were divided into 5 groups, each containing 7 rabbits. Intraperitoneal injection of a ketamine-xylasine mixture (10-15 mg/kg) was administered to rabbits for anesthesia. Except for the control group [Group 1], a flat alkaline battery (Macintosh®) was inserted to esophagus with the assistance of a pediatric laryngoscope using a nonconductive clamp. Simultaneously, the alkaline battery was placed in the esophageal narrowness by the assistance of palpation. Subsequently, a posterior-anterior lung graph was performed to check the site of battery (**Figure 1**). The control group (Group 1) was used as a non-intervention control. In Group 2, a discharged battery was placed in the esophagus for 180 minutes. Rabbits in Group 3-5 were exposed to charged batteries for 60, 120, and 180 minutes, respectively. After a determined amount of time under

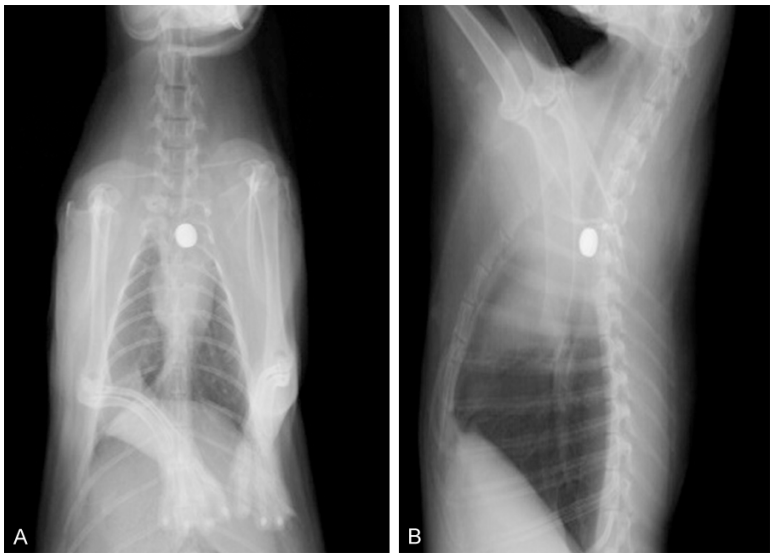

Figure 1. A and B. A posterior-anterior lung graph was performed to check the site of battery.

Table 1. Colour change in eosaphageal mucosa in different rabbit groups

Groups	N [Colour changed]	Fawn-Coloured	Blackish	Colour Change of batteries
Group 1	None	None	None	None
Group 2	None	None	None	None
Group 3	7	4	3	3
Group 4	7	2	5	4
Group 5	7	1	6	7

anesthesia, high dose pentothal was administered to rabbits for euthanasia. Environmental pH was analyzed by litmus strips (pH meter). Excised esophageal tissues was replaced in capes containing 10% formalin and embedded in paraffin blocks. Finally, the sections were stained by hematoxylin and eosin and examined by a single pathologist. This study was approved by local animal ethics committee.

Results

Macroscopic and microscopic evidences of battery induced esophageal injury were examined. The capsules of the batteries were intact and the mean pH of esophageal mucosa around the battery was 7.1 (range: 6.9-7.2). No significant change was observed in the anode pole of the alkaline batteries in Group 2. In Group 3, the anode poles of batteries in 3 rabbits were black. Anode poles of the batteries were black in 4 and 7 rabbits in Group 4 and 5, respectively.

Macroscopic examination of esophageal tissue surrounding the batteries was performed. No color change was observed in Group 2. In Group 3, 4 rabbits had brownish and 4 rabbits had blackish color change. Five rabbits had total black color esophageal tissue around the battery, and the remaining 2 rabbits were partially blackish and brownish in color change in Group 4. In Group 5, 6 rabbits had black color change in the surrounding tissue of battery, and a rabbit had partially black and brown color change (**Table 1**).

In histopathologic examinations of esophageal biopsy specimens, no microscopic change was observed in any of rabbits in Group 2. Erosions were evident in each rabbit in Group 3 (**Figure 2**). In Group 4, necrosis was extended to the internal muscular layer of the esophageal mucosa, which came up to anode pole of the battery in 5 rabbits (**Figure 3**). Necrosis extended to the external muscular layer of esophagus in each 7 rabbits in Group (**Figure 4**; **Table 2**).

Discussion

In the present study, we demonstrated that charged batteries is associated with severe tissue injury in esophageal mucosa when compared to discharged batteries. Additional duration of exposure to battery is one of a determinant of severity of esophageal mucosal injury.

As a result of increased frequency of flat battery use in daily activities, a gradual increase in flat battery ingestion cases has been encountered [6, r1(7), r2(8)]. Children aged 0-3 years have a habit of foreign body ingestion [9]. Flat batteries have negative and positive terminals. Negative terminals contain zinc and lithium while positive terminal contains oxygen (1.5 volt), silver oxyte (1.5 volt), zinc oxyte (1.5 volt), lithium manganese (1.5 volt) and magnesium

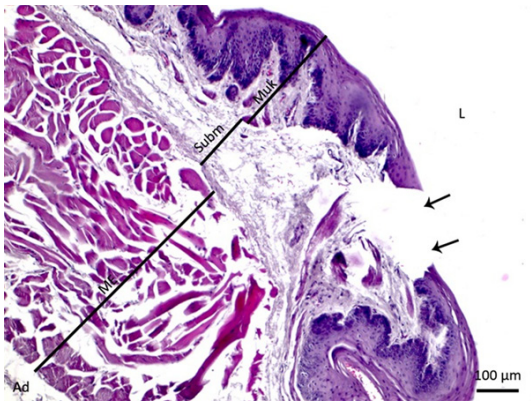

Figure 2. Mucosal damage in esophagus of a rabbit from Group 3 exposed the battery for 60 minutes [arrow]. Muk: mucosa, Subm:submucosa, ME: muscularis externa, Ad: adventitia [hematoxylen-eosin, bar: 100 µm].

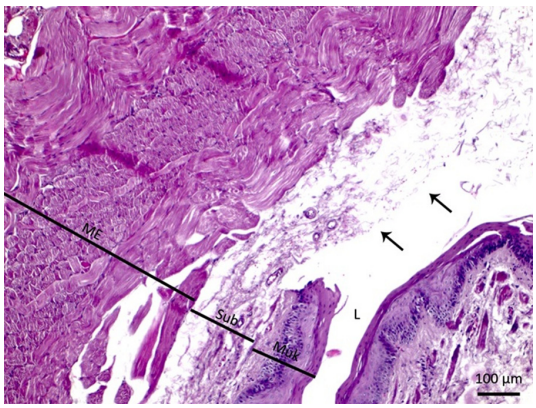

Figure 3. Mucosal necrosis involving inner muscular layers in esophageal section of a rabbit from Group 4 exposed the battery for 120 minutes [arrow]. Muk: mucosa, Subm:submucosa, ME: muscularis externa, Ad: adventitia, [hematoxylen-eosin, bar: 100 µm].

dioxyte (1.5 volt). Negative terminal is the narrowest side of a battery which is associated with electrical currency and tissue injury. Positive terminals have potassium hydroxyte and sodium hydroxyte containing solutions in varying concentrations and have pathogenetic mechanisms of battery-induced tissue injury are mucosal compression as well as electrical currency and corrosive substrate release which can lead necrosis and perforation. Potassium and sodium containing batteries may cause faction-like necrosis. However mercury and other heavy metals may relate to metal poisoning in addition to tissue necrosis which is well correlated with duration of exposure [10, 11].

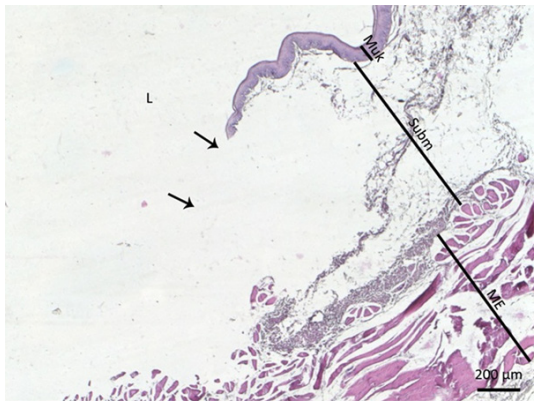

Figure 4. Necrosis extending outer muscular layer in esophageal section of a rabbit from Group 5 exposed the battery for 180 minutes [arrow]. Muk: mucosa, Subm:submucosa, ME: muscularis externa, Ad: adventitia, [hematoxylen-eosin, bar: 100 µm].

Table 2. Histopathologic examination of eosaphagal tissue in 5 rabbit groups

Groups	Mucosa	Submucosa	Internal muscularis	External muscularis
Group 1	Normal	Normal	Normal	Normal
Group 2	Normal	Normal	Normal	Normal
Group 3	Erosion	Erosion	Normal	Normal
Group 4	Necrosis	Necrosis	Necrosis	Normal
Group 5	Necrosis	Necrosis	Necrosis	Necrosis

A lithium battery has high rate currency that can produce higher alkaline substrate than flat batteries. While removing batteries from eosaphagus, researchers showed that tissue injury was significantly more severe in the area contacting with negative pole of battery. Lithium batteries have longer duration of action and higher risk of mucosal damage [12, 13]. Flat batteries-related mucosal damage is caused by corrosive substrate leakage from alkaline battery [13-15]. However, controversy exists on the role of corrosive substrate. Rivera et al showed that flat battery leakage causes chemical injury on esophageal mucosa which may be regressed by neutralizing with slight acidic substrate infusion [16]. In another study on dogs, at the 2nd and 4th of battery ingestion, a bluish-brown change was observed on the surrounding tissue of anode side [5]. Flat batteries, if not removed, may lead to mucosal erosion at the 1st hour and full-thickness damage at the 4th hour. Because of potassium or sodium chloride content, flat batteries have

corrosive effect [9, 14, 15]. In another animal study, flat batteries caused electrochemical burn at the 8th hour of ingestion even no leakage was observed, suggesting the role of electrical currency until break down of battery capsule [5, 13-15]. We demonstrated macroscopically evident color change in esophageal mucosa that exposed to charged batteries, but not to discharged batteries.

Dark colored oxidizing appearance was observed in the anode side of the batteries. Capsules of batteries were intact, and the pH of the environment was neutral. The neutral pH of the environment indicated an absence of alkaline leakage from the batteries, and presence of electrical tissue injury.

Recently, battery induced esophageal injury has been less observed due to increased stability of battery capsules that decreases corrosive substrate leakage [13]. Discharged batteries have no significant harmful effect on the esophageal tissue during a 3-hour period in our study. However, charged batteries lead to erosions even in the 1st hour of exposure. There is a linear and positive correlation between esophageal mucosal injury and duration of exposure. In the absence of corrosive substrate leakage, we concluded that alkaline batteries may result in esophageal injury via electrical currency caused by the negative pole of battery.

The esophagus is the primary area of battery-induced injury. Anatomical narrowness of the esophagus facilitates the development of battery-induced mucosal damage. Charged batteries may cause electrical current-induced mucosal injury, even without corrosive substrate leakage.

Disclosure of conflict of interest

None.

Address correspondence to: Dr. Menduh Oruc, Department of Chest Surgery, School of Medicine, Dicle University, Diyarbakir, Turkey. Tel: 009053-06914081; E-mail: menduhor@hotmail.com

References

[1] Turkyılmaz A, Aydın Y, Genc F, Eroglu A. Increasing cause of esophageal foreign body ingestion in children: alkaline batteries. Turkish Journal of Thoracic and Cardiovascular Surgery 2008; 16: 250-253.

[2] Sheikh A. Button battery ingestions in children. Pediatr Emerg Care 1993; 9: 224-229.

[3] Guven DG, Yaman H, Subası B, Guclu E. Fluoroscopy guided removal of a metallic foreign body in the neck: a case report. Konuralp Medical Journal 2013; 5: 42-45.

[4] Lıtovıtz T, Butterfıeld AB, Holloway RR, Marıon LI. Button battery ingestion: assessment of therapeutic modalities and battery discharge state. J Pediatr 1984; 105: 868-873.

[5] Yamashlta M, Saıto S, Koyama K, Hattorı H, Ogata T. Esophageal electrochemical burn by button-type alkaline batteries in dogs. Vet Hum Toxicol 1987; 29: 226-30.

[6] Lın HH, Lee SC, Chu HC, Chang WK, Chao YC, Hsıeh TY. Emergency endoscopic management of dietary foreign bodies in the esophagus. Am J Emerg Med 2007; 25: 662-5.

[7] Sucakli MH, Keten HS, Celik M, Olmez S, Yilmaz A. Alcohol and substance use among children and adolescents in an orphanage. Konuralp Medical Journal 2015; 7: 23-27.

[8] Ayaz T, Bilir O, Ersunan G, Sahin Oz, Yavasi O, Rakici H. Evaluation of drug intoxications due to suicides. Konuralp Medical Journal 2015; 7: 53-56.

[9] Tanaka J, Yamashita M, Yamashita M, Kajigaya H. Esophageal electrochemical burns due to button type lithium batteries in dogs. Vet Hum Toxicol 1998; 40: 193-6.

[10] Button and cylindrical battery ingestion-up to date. 2014; 15.

[11] Yardeni D, Yardeni H, Coran AG, Golladay ES. Severe esophageal damage due to button battery ingestion: can it be prevented? Pediatr Surg Int 2004; 20: 496-501.

[12] Chevin JC, Attik G, Dika H. Button battery induced cell damage: a pathophysiological study. Electrochem Commun 2008; 1756-1760.

[13] Guven A. Dangers to children at home: corrosive esophageal burn. Preventive Medicine Bulletin 2008; 7: 535-540.

[14] Lıtovıtz T, Whıtaker N, Clark L. Emerging battery-ingestion hazard: clinical implications. Pediatrics 2010; 125: 1168.

[15] Sahin A, Meteroglu F, Erbey A, Sızlanan A, Ulku R. Insidious threat of children: esophageal foreign body ıngestion. The Journal Of Academıc Emergency Medıcıne 2014; 13: 159-161.

[16] Rıvera EA, Maves MD. Effects of neutralizing agents on esophageal burns by discatteries. Ann Otol Rhinol Laryngol 1997; 96: 362-366.