

Case Report

Delayed repair of traumatic aortic injury complicated by hepatic rupture: a successful case report

Tao Guo^{1,2}, Wen Peng¹, Guifang Yang¹, Zhenyu Peng¹, Yuzhong Cai¹, Xiangping Chai^{1,2}

¹Department of Emergency Medicine, The second Xiangya Hospital of Central South University, Changsha, Hunan, P. R. China; ²Emergency Medicine and Difficult Diseases Institute of Central South University, Changsha, Hunan, P. R. China

Received February 26, 2016; Accepted June 4, 2016; Epub July 15, 2016; Published July 30, 2016

Abstract: Blunt traumatic aortic injury (BTAI) is a life-threatening injury and traditional viewpoints considered that immediate surgical repair of the aortic injury would be optimal. This study reported a case with traumatic aortic injury complicated by hepatic rupture and the repair of traumatic aortic injury was delayed for 21 days. This study demonstrated that surgical repair of traumatic aortic injury can be safely delayed.

Keywords: Blunt traumatic aortic injury, hepatic rupture, surgery

Introduction

Blunt traumatic aortic injury (BTAI) is a life-threatening injury, and is the second most common cause of death following blunt trauma. The most common site of rupture occurs at the aortic isthmus, followed by the ascending aorta, the aortic arch, the distal descending aorta, and the abdominal aorta [1]. Because of the high rate of early mortality in patients with BTAI, traditional viewpoints considered that immediate surgical repair of the aortic injury may help avoid the inevitable risk of fatal aortic rupture with exsanguinating hemorrhage. However, this form of management has resulted in high mortality and complications [2]. Recently, some authors have proposed that delayed repair could be allowed if aortic wall stress and blood pressure was controlled better, particularly in patients who have concomitant life-threatening injuries that require lifesaving procedures (such as laparotomy or embolization for pelvic artery bleeding) [3]. Unfortunately, successful application of this alternative approach is not widely available in literature.

Case report

A 52-year-old man fell from the 10th floor of a building to the 6th floor and presented to our

emergency department. The patient was in coma with a blood pressure reading of 70/46 mmHg. Upon administration of normal saline and blood transfusion, the patient gradually regained consciousness and complained of dull pain in the abdomen. The physical examination revealed tachycardia, multiple lacerations on his body and extremities, and severe upper abdominal pain and tension. Computed tomography (CT) scan image reconstruction showed traumatic aortic injury beginning at the level of the distal left subclavian artery and ending at the level of the right iliac artery. In addition, the left hepatic rupture, laceration of both kidneys, pulmonary laceration, and lumbar vertebra fracture were observed (**Figure 1A, 1C**). Fortunately, CT of the head showed no apparent bleeding or damage. Laboratory tests showed acute anemia (Hb 7 g/dL) and lactic acid level of 3.9 mmol/L. Abdominal puncture revealed numerous blood clots in the abdominal cavity.

The patient was sent to operating room immediately, and an exploratory laparotomy was performed under general anesthesia. Left hepatic rupture with hemorrhagic mass and massive hemoperitoneum (1500 cc), serious jejunum and ileum dilation, and colon trauma were observed (**Figure 1B**). No rupture in the entire intestinal tract was observed. After resection of

Traumatic aortic injury complicated by hepatic rupture

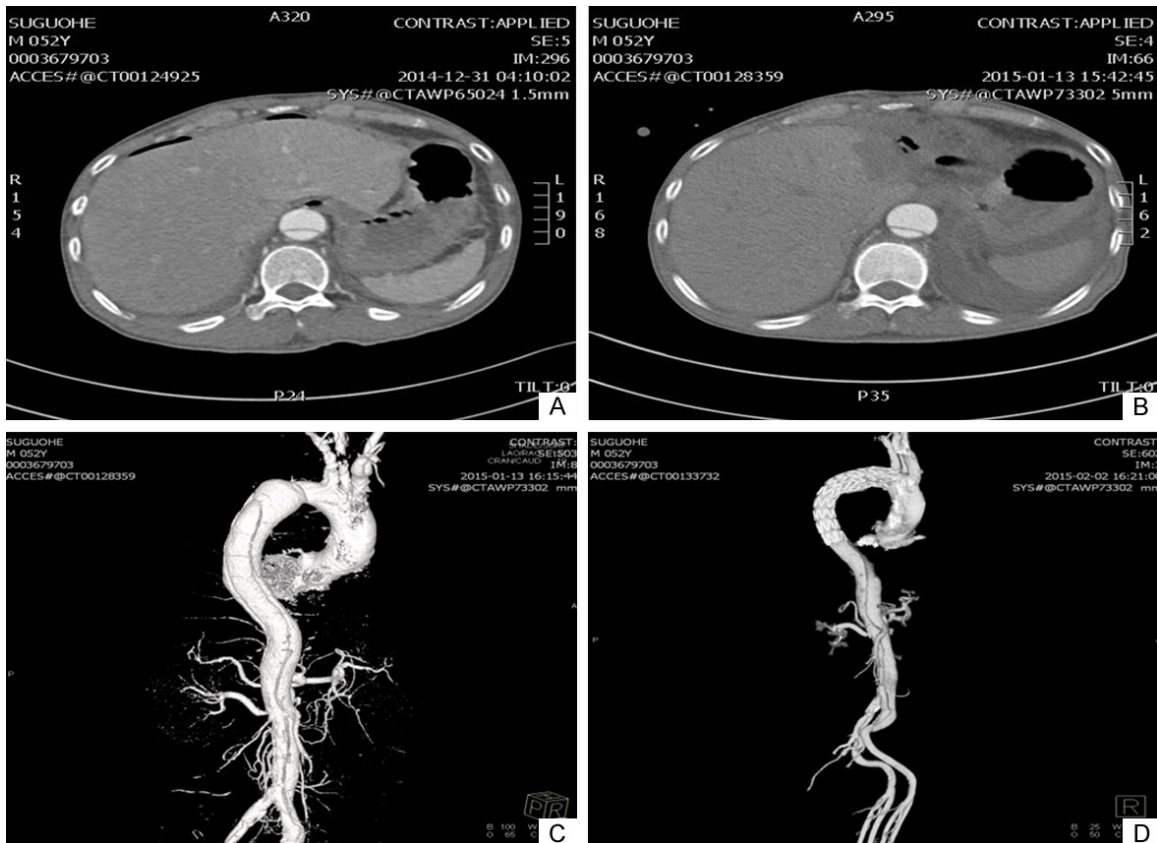


Figure 1. A. The left hepatic rupture with hemorrhagic. B. After the resection of the left liver mass and massive hemoperitoneum. C. The aortic injury from isthmus to lateral sacral artery. D. After received endovascular graft therapy.

the left liver lobe and repair of the serious tear of plasma muscularis, the patient was transported to the intensive care unit. During ICU treatment, vasodilators and beta-blockers were used to control the blood pressure and heart rate. Twenty-one days later, angiography demonstrated that the first crack of aortic dissection lining was located about 1.5 cm far from the left subclavian artery, the ratio of true to false lumen was about 1:1, and blood flow in important organs was normal. After measuring the vascular diameter in the anchor zone, a coated stent ankura (REF XJDZ32-26-180) was implemented in the anchor zone (**Figure 1D**). The patient recovered well and was discharged with no complications 13 days later.

Discussion

Although delayed repair of traumatic aortic injury has been suggested when aortic wall stress and blood pressure were controlled better, whether it can be safely delayed remains

unclear. Some clinical studies have indicated that in-hospital death remains a problem with a delayed approach. Fabian *et al.* reported a multicenter prospective study of 274 patients with BTAI and found that 9% (n=24) of patients with aortic rupture were in stable condition upon admission to the hospital [4]. However, Hemmila *et al.* found that delay of surgical repair for BTAI beyond 16 hours from the time of injury did not increase the risk of overall patient mortality if heart rate and systolic blood pressure were well-controlled [5]. Delayed repair may lead to an increase in the length of hospital stay and morbidity in patients. However, repair of BTAI should not take priority over all other life-threatening injuries. Instead, operative aortic repair should be triaged and given an appropriate priority according to its severity in relation to the patient's overall condition and coexisting injuries.

In this case, the treatment for blunt traumatic aortic injury had been delayed for 21 days.

Traumatic aortic injury complicated by hepatic rupture

Patients spent these days in the ICU and were given vasodilators and beta-blockers, and blood pressure and heart rate were controlled. After that, endovascular stent graft therapy was performed, and the patient recovered well without any complication. Our study suggests that delayed repair is safe for patients with traumatic aortic injury complicated by organ injury.

Acknowledgements

This study was supported by the National Natural Science Foundation of China (No: 81100221 and No: 81471896).

Disclosure of conflict of interest

None.

Address correspondence to: Xiangping Chai, Department of Emergency Medicine, The second xiangya Hospital of Central South University, Changsha, Hunan, P. R. China; Emergency Medicine and Difficult Diseases Institute of Central South University, 139 Renmin Road, Changsha 410011, Hunan, P. R. China. Tel: +86-731-85294048; Fax: +86-731-85533525; E-mail: laochaicn@aliyun.com

References

- [1] Nzewi O, Slight RD, Zamva R. Management of blunt thoracic aortic injury. *Eur J Vasc Endovasc Surg* 2006; 31: 18-27.
- [2] von Oppell UO, Dunne TT, De Groot MK, Zilla P. Traumatic aortic rupture: twenty-year meta analysis of mortality and risk of paraplegia. *Ann Thorac Surg* 1994; 58: 585-593.
- [3] Maggisano R, Nathens A, Alexandrova NA, Cina C, Boulanger B, McKenzie R, Harrison AW. Traumatic rupture of the thoracic aorta: should one always operate immediately? *Ann Vasc Surg* 1995; 9: 44-52.
- [4] Fabian TC, Richardson JD, Croce MA, Smith JS Jr, Rodman G Jr, Kearney PA, Flynn W, Ney AL, Cone JB, Luchette FA, Wisner DH, Scholten DJ, Beaver BL, Conn AK, Coscia R, Hoyt DB, Morris JA Jr, Harviel JD, Peitzman AB, Bynoe RP, Diamond DL, Wall M, Gates JD, Asensio JA, Enderson BL, et al. Prospective study of blunt aortic injury: Multicenter Trial of the American Association for the Surgery of Trauma. *J Trauma* 1997; 42: 374-380.
- [5] Hemmila MR, Arbabi S, Rowe SA, Brandt MM, Wang SC, Taheri PA, Wahl WL. Delayed repair for blunt thoracic aortic injury: is it really equivalent to early repair? *J Trauma* 2004; 56: 13-23.