

## Original Article

# Application of loop plating technique in fractures of ulna coronoid process

Jianhua Ge<sup>1\*</sup>, Long Chen<sup>1,2\*</sup>, Zhou Xiang<sup>1</sup>

<sup>1</sup>Department of Orthopedics, West China Hospital, Sichuan University, Chengdu, China; <sup>2</sup>Department of Orthopedics, Guizhou Provincial People's Hospital, Guiyang, Guizhou, China. \*Equal contributors.

Received June 14, 2016; Accepted August 15, 2016; Epub November 15, 2016; Published November 30, 2016

**Abstract:** *Objective:* Although ulna coronoid process fracture is uncommon, it is a complex injury and its treatment remains difficult. This study assessed the clinical efficacy of loop plating technique, a potential method to treat ulna coronoid process fracture. *Materials and Methods:* Seven cases of ulna coronoid process fractures treated with loop plating technique from October 2012 to May 2015 were analyzed retrospectively. Patients' age ranged from 18-55 years (mean age 36 years). All cases were closed fractures. X-ray and 3D computed tomography were applied to all patients before surgery. After anteromedial incision, a homemade loop plate was fixed after satisfactory reduction of fractures. Lateral collateral ligament injuries were repaired and reconstructed in 4 cases and medial collateral ligament injury was repaired in 1 case during surgery because of elbow instability. Functional evaluation data were collected and analyzed statistically. *Results:* No patients suffered from delayed incision healing, redisplacement, fixation failure, or elbow joint instability. At last follow-up, mean Broberg and Morrey score was 94.1, Mayo Elbow Performance Index was 92.1, Ewald scoring system was 88.6 and Disabilities of the Arm, Shoulder and Hand score was 5.4. During follow-up, only 1 patient had elbow heterotopic ossification (grade I-II). *Conclusion:* Application of loop plating technique might be a valid method for treatment of ulna coronoid process fractures, including various fracture styles, especially for comminuted fractures, but excluding simple coronion fractures of ulna coronoid process.

**Keywords:** Coronoid process fractures, dislocation, loop plating technique, internal fixation, ligament repairing

## Introduction

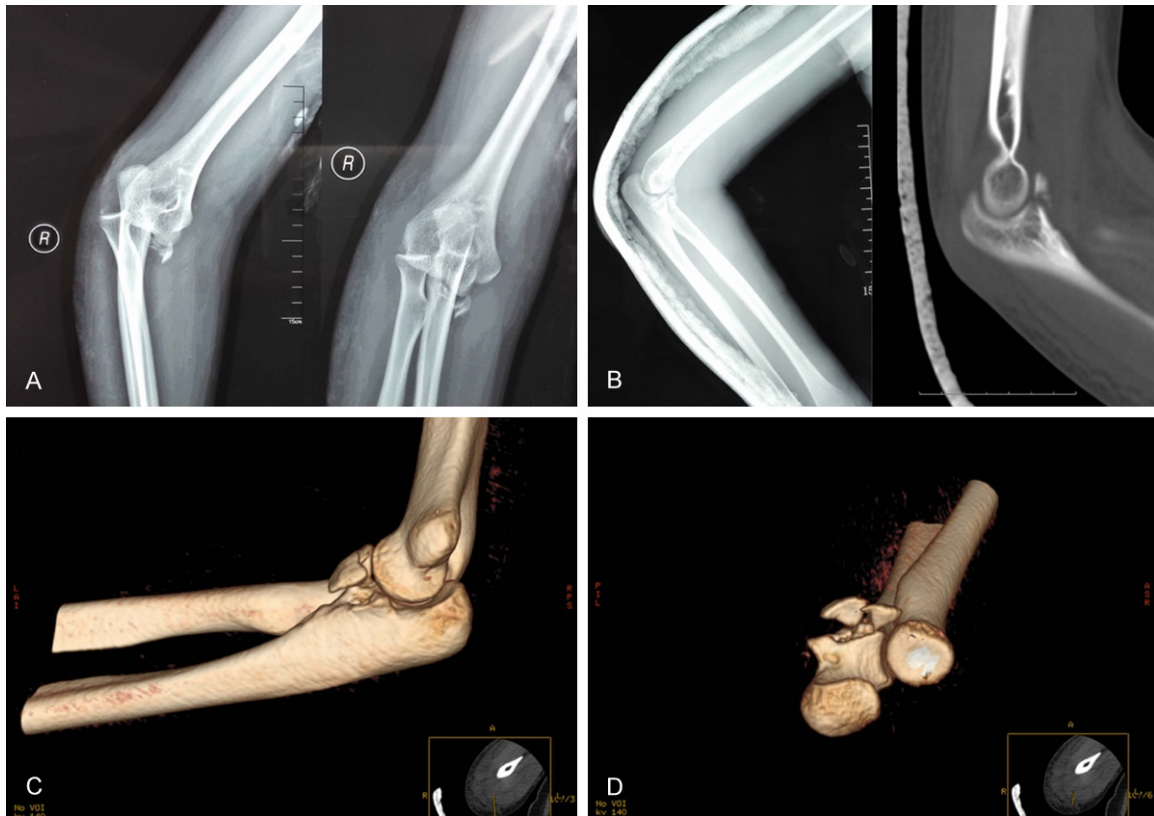
The ulna coronoid process helps to restrict excessive forward movement of the humeral trochlea and to resist introversion stress when extending the elbow; thus it has an important role in anatomy and stability of elbow joints [1, 2]. Approximately 2% to 15% of patients with dislocated elbows are reported to present with a fracture of the ulna coronoid process, which is relatively uncommon. However, it is a more complex injury than originally thought and its treatment remains difficult [3]. Typically, these fractures occur in association with capsuloligamentous disruptions or fractures of the radial head, olecranon process, or epicondyles, as well as "terrible triad injury", resulting in various patterns of complex elbow instability [1]. When coronoid process fractures occur, the anterior bony baffles are destroyed, leading to posterior dislocation, posterolateral dislocation, or subluxation. It was reported that more than 50% of

coronoid process fractures may lead to instability of elbows even though the ligament and other structures are complete [1, 4]. Coronoid process fractures are thought to be the most important component of complex elbow injuries. Treatment for these types of injuries where there is a fracture of the coronoid process is still controversial, and there is no established standard of treatment or appropriate fixation materials [4]. In this study we retrospectively analyzed 7 cases of ulna coronoid process fractures treated with a loop plating technique from October 2012 to May 2015.

## Material and methods

### Patients

This study was approved by the Regional Ethics Committee of Hospital and all patients signed informed consents. Four males and three females were included in this study. The age of



**Figure 1.** X-ray and 3D computed tomography (CT) examinations for elbow joint before surgery. A: X-ray films show dislocation of the elbow joint and fracture of the coronoid process. B: X-ray film and CT slice images show close manipulative reduction and plaster fixation. C, D: Preoperative 3D CT shows comminuted fracture of the coronoid process.

patients ranged from 18-55 years with a mean age of 36 years. All cases were closed fractures, 5 on the right side (71.4%) and 2 on the left (28.6%). All patients were right-hand dominant. According to Regan-Morrey classification [5], there were 4 cases of type II and 3 cases of type III. According to O'Driscoll classification [6], there were 2 cases of type II b, 2 cases of type II c and 3 cases of type III a. According to Adams classification [7], there were 5 cases of type III and 2 cases of type IV. Six cases were complicated by elbow joint dislocations, 7 cases by lateral collateral ligament injuries, and 2 by medial collateral ligament injuries. The duration from injury to admission to our hospital ranged from 5 hours to 9 days. If accompanied with dislocation of an elbow joint (**Figure 1A**), close manipulative reduction and plaster or brace fixation were given after admission (**Figure 1B**). X-ray and 3D computed tomography (CT) examinations were applied to all patients before surgery (**Figure 1C** and **1D**). Surgery was performed after the general conditions of patients were stabilized and soft tissue

conditions had improved. The duration from injury to operation ranged from 5-20 days.

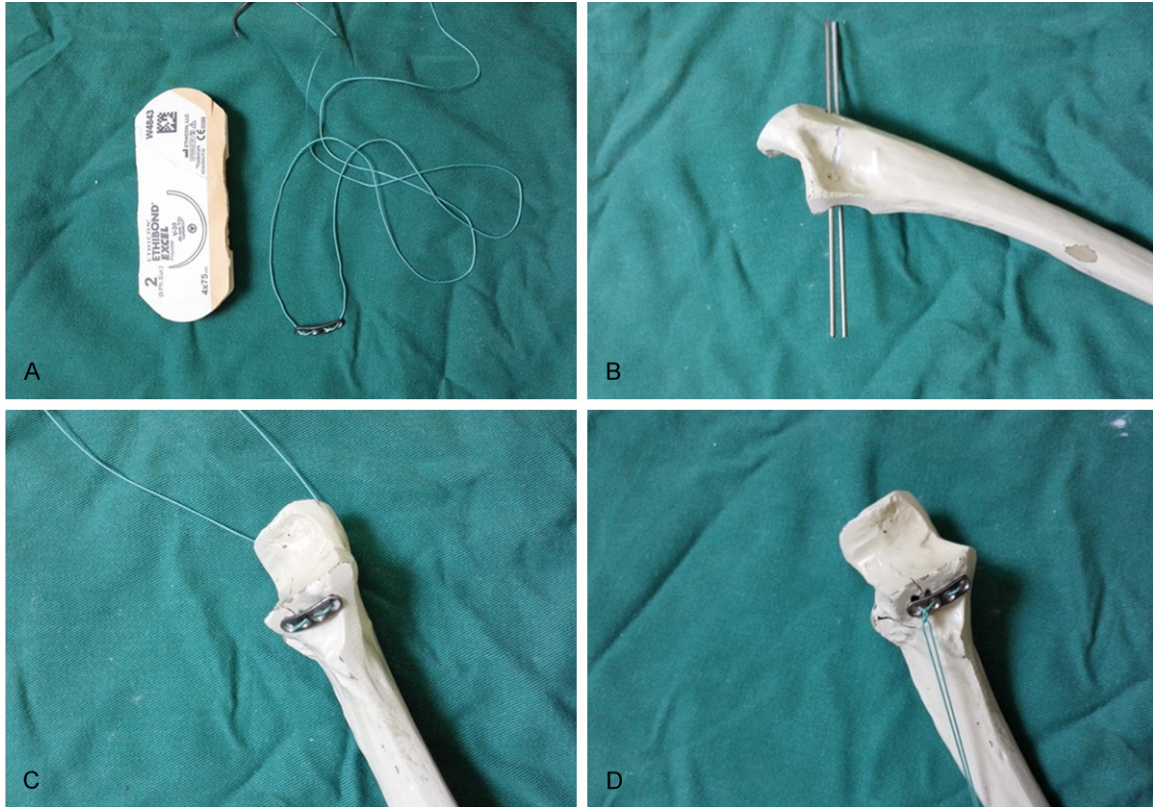
#### *Inclusion and exclusion criteria*

The age of the patients ranged from 16-65 years and the patients should not have had deformity or dysfunction of elbow joints before injury. The duration from injury to operation should be no more than 3 weeks. Closed fractures were included and the fracture type was limited to type IIA to type IIIA according to O'Driscoll classification. The soft tissue conditions should be evaluated as grade 0-2 according to Tscherne-Gotzen Classification. The follow-up time should be more than 12 months. All surgery was performed by the same surgeon. This study was approved by the Regional Ethics Committee of our hospital and all patients signed informed consent.

#### *Surgical technique*

First-generation cephalosporin was given as an intravenous infusion 30 minutes preoperative-

## Loop plating technique in fractures of ulna coronoid process



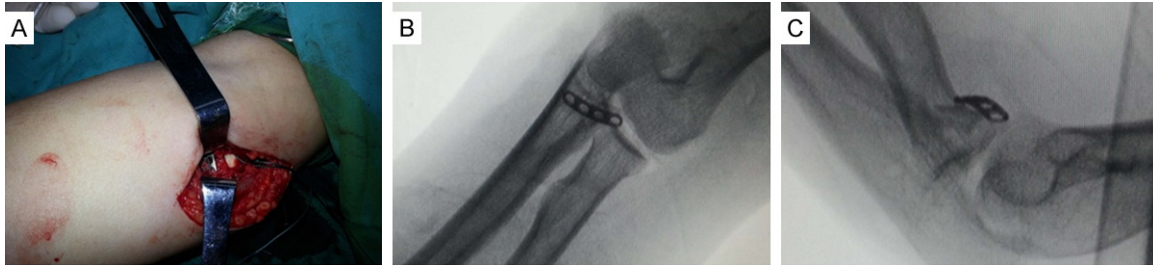**Figure 2.** The operation steps of loop plating technique. A: Self-made loop plating and 2# ETHIBOND suture. B: Two Kirschner pins (2.0 mm) were drilled from the bilateral ulna coronoid process into the rear of the olecranon. C, D: Fixation of the loop plating and stringed and knotted sutures.

ly. Patients were placed in a supine position on a radiolucent operating table. The surgery was performed under general anesthesia or brachial plexus block with a tourniquet on the proximal upper arm. An anteromedial elbow approach [8] was made: the incision was approximately 6-8 cm long, started from a location 3 cm above the medial epicondyle of the humerus, and the distal end extended to a location 3-5 cm from the ulnar coronoid process. After careful dissection, the medial antebrachial cutaneous nerve was identified and protected. The myolemma of pronator teres was incised, and the elbow joint was flexed slightly. The distal part of pronator teres was retracted medially, and the median nerve and humeral vessels were retracted laterally. Then made a longitudinal incision was made in the capsule to expose the ulna coronoid process and the trochlea humeri. Blood clots, embedded soft tissue in the fracture site and intra-articular loose fragments were removed. After reduction of the fracture, Kirschner pins (0.8 mm or 1.0 mm in diameter) were used to fix them temporarily.

Appropriate preflex shaping mini-plate (Wego Inc., Mini-plate, China) and 2# ETHIBOND excel polyester sutures (ETHICON Inc., ETHIBOND EXCEL Polyester, USA) were made into loop plating (**Figure 2A**), which was placed around the fracture (**Figure 3A**). Two Kirschner pins (2.0 mm) were drilled from the bilateral ulna coronoid process into the rear of the olecranon to create two holes for the threading of sutures (**Figure 2B**). Then the loop plating was adjusted to fit the fracture and the sutures were stringed and knotted (**Figure 2C** and **2D**). C-arm X-ray fluoroscopy showed satisfactory reduction and fixation of fractures during surgery (**Figure 3B** and **3C**).

A lateral stress test of the elbows was performed after surgery to check the stability of elbows. Lateral collateral ligament injuries were repaired and reconstructed in 4 cases, including 2 cases with 2# ETHIBOND sutures and other 2 cases with 3.5 mm suture anchor (Smith & Nephew, Inc. Endoscopy Division, Twinfix Ti Preloaded Suture Anchors, USA).

## Loop plating technique in fractures of ulna coronoid process



**Figure 3.** The surgical approach and intraoperative X-ray films. A: Anteromedial approach during surgery. B, C: Intraoperative X-ray films showed satisfactory reduction and fixation.

**Table 1.** Preoperative demographic and clinical data of included patients

No./gender	Age	Injuries	Regan-morrey	O'Driscoll	Adams	Tscherne-Gotzen	Combinations	TII
1/M	41	Traffic accident	II	II b	IV	0	ED, LCL	5 d
2/M	18	Fall from bicycle	III	III a	III	1	ED, LCL	13 d
3/F	21	Traffic accident	III	III a	III	1	ED, LCL	14 d
4/F	39	Fall from a height	II	II b	IV	2	ED, LCL, MCL	17 d
5/M	25	Motor cycle	III	III a	III	1	LCL	20 d
6/F	55	Fall from staircase	II	II c	III	1	ED, LCL, MCL	8 d
7/M	52	Traffic accident	II	II c	III	2	ED, LCL	10 d

ED: elbow dislocation; LCL: lateral collateral ligament injuries; MCL: medial collateral ligament injuries; TII: time of intervention from injury.

Similarly, medial collateral ligament injuries were repaired in 1 case using a 3.5 mm suture anchor during surgery because of instability of the elbows. Then Kirschner pins for fixing the ulna coronoid process was temporarily removed after reconfirmation of elbow stability. Negative pressure drainage tubes were placed in the front of elbows and connected to vacuum bottles (B.Braun Melsungen AG, Wound Drainage Systems, Germany). A long-arm posterior plaster splint was applied to the elbow at 90 degrees of flexion with the forearm in neutral rotation postoperatively.

### Postoperative management

Patients were asked to follow a post-surgery protocol involving prolonged elevation and ice compression of the injured limb. The negative pressure drainage was opened at 4 hours after surgery, then closed and removed at 48 hours after surgery. Within 4 weeks after surgery, plaster cast immobilization of the affected limb was provided to make sure the abduction of ipsilateral shoulder was avoided. Whenever possible, the patients were encouraged to undertake active and passive exercise of the distal part of the affected limb the day after surgery. During the first 2 weeks, plaster casts

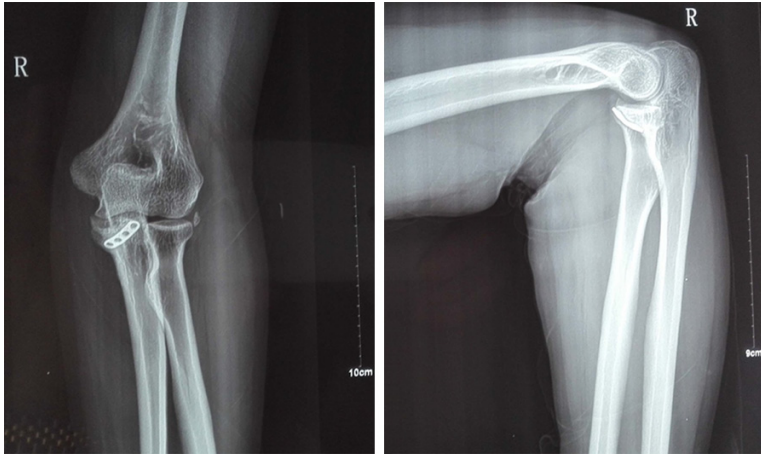
were strictly fixed. During the next 2 weeks, the patients were asked to undertake passive exercise of the affected elbow when the plaster fixation was removed temporarily for 5-30 minutes, 3 times per day. Active exercises of the affected elbow were to be performed at the third week. After 6 weeks, active muscle-strengthening exercises were initiated. If there was evidence of fracture union, unrestricted active elbow motion and forearm rotation were encouraged [9]. The exercise time, frequency, intensity and amplitude were increased gradually.

### Results

Demographic and clinical data of included patients before surgery are summarized in **Table 1**. All 7 patients were followed-up successfully. The follow-up time was from 12-38 months with a mean time of 21.9 months. None of the patients suffered from delayed incision healing, redisplacement, fixation failure or elbow joint instability. X-ray films showed fracture healing in all the patients (**Figure 4**).

At last follow-up, the mean extension-flexion ranges of motion of affected elbows were 5.7° and 124° respectively, and the mean prona-

## Loop plating technique in fractures of ulna coronoid process



**Figure 4.** X-ray films at 12 months after surgery show fracture healing.

tion-supination ranges of motion were 75° and 74°, respectively (**Table 2** and **Figure 5**). The mean Broberg and Morrey score (BM) was 94.1, the Mayo Elbow Performance Index (MEPI) was 92.1, the Ewald scoring system (ECS) was 88.6 and the Disabilities of the Arm, Shoulder and Hand score (DASH) was 5.4. The BM and MEPI score of 2 patients were 100, and the DASH score were both 0.

During follow-up, 1 patient had elbow heterotopic ossification (grade I-II). The extension-flexion range of motion was 25°/90°, and the pronation-supination range of motion was 60°/40° at 9 months after surgery. This patient was graded with a BM of 58, MEPI of 60, ECS of 57 and DASH of 30.3. Because of the poor elbow function, the patient underwent a cleanup of the heterotopic ossification, arthrolysis and fixation of hinged external fixation. The patient's elbow function was recovered at last follow-up (**Table 2**).

### Discussion

The ulna coronoid process is an important component of the humeroulnar joint because it helps to maintain the stability of elbows together with the lateral collateral ligament (LCL), medial collateral ligament, and radial head. A fracture of the ulna coronoid process usually occurs when a combination of rotational forces are applied to the extended elbow with the forearm in introversion or extroversion [10]. It is especially vulnerable to fracture when the elbow is flexed at 80° [11]. The introversion stress and posteromedial rotational forces con-

centrated at elbows may lead to avulsion injury of the LCL. Further continuous forces may lead to impingement between the trochlea humeri and sublime tubercle. Sixty percent of the sublime tubercle is unable to provide effective support of the cortical bone resulting in a greater risk of fracture. This finally causes posteromedial rotational instability, dislocation or subluxation of the elbow joint [1, 12-15]. The extroversion stress and supination forces concentrated at elbows may lead to fracture of the

radial head because of impingement between the radial head and capitulum humeri. The shearing stress of the trochlea humeri might also cause a fracture of the ulna coronoid process. The posterolateral rotation of an elbow joint might cause an avulsion injury of the LCL. This would subsequently cause posterolateral rotational instability and dislocation of the elbow joint [10, 12]. In this study, 6 cases were complicated by elbow joint dislocations, and 7 by LCL injuries, which was in accord with the classical injury mechanisms. A fracture of the ulna coronoid process with or without ligament injury would result in the loss of elbow stability, which always needs to be repaired.

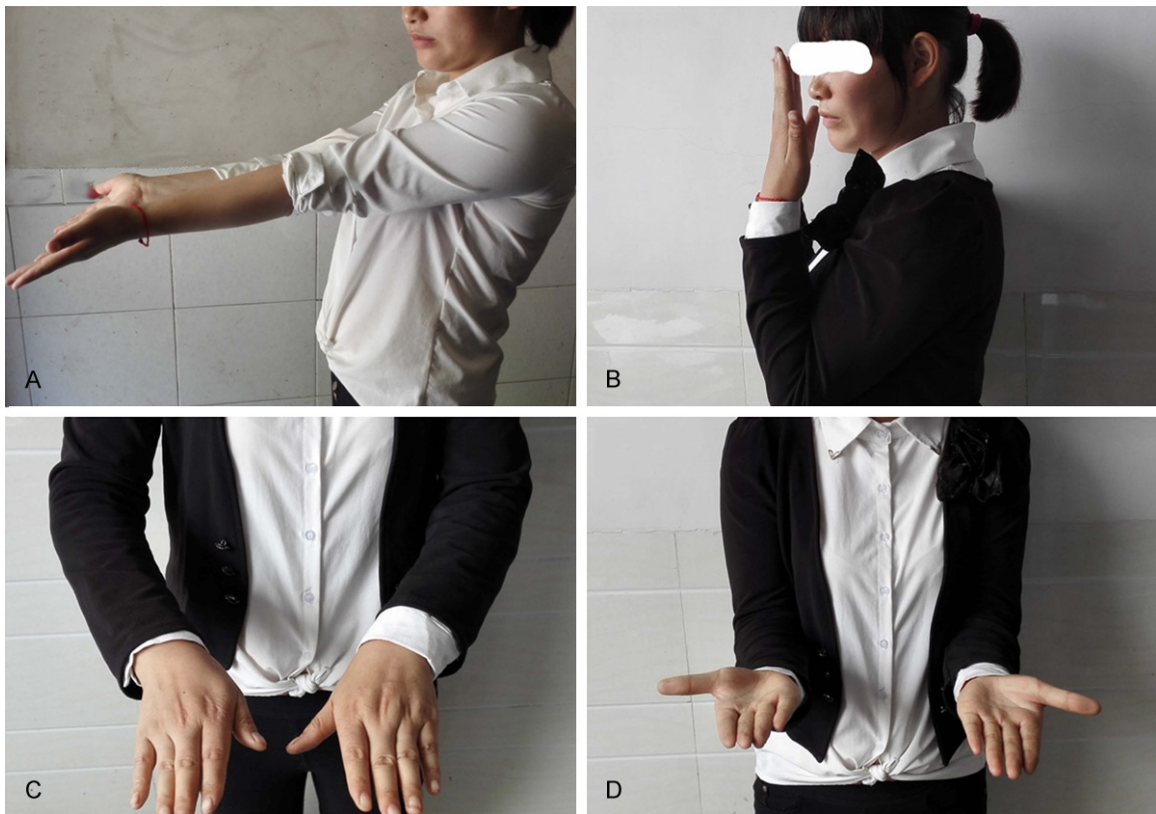The incidence of ulna coronoid process fracture is very low and therefore it was difficult to study large numbers of cases. This study excluded patients with a past history of deformity and dysfunction of elbows before the injury, as well as patients with “terrible triad injury” or accompanied by a fracture of the proximal ulna. The loop plating technique is the main method for surgical intervention, and factors which could be interferential were eliminated during surgery and follow-up. In this study, magnetic resonance imaging was not used as a conventional checking method because it can provide false positive and false negative cases for the early diagnosis of ligament injuries. Therefore, ligament injuries were diagnosed and whether they were to be repaired or reconstructed was determined by preoperative and intraoperative physical examinations combined with X-ray fluoroscopy [13].

## Loop plating technique in fractures of ulna coronoid process

**Table 2.** Functional and Quality-of-Life Outcomes

No./gender	FT	Extension/flexion	Pronation/supination	BM	MEPI	ECS	DASH	Complications
1/M	12	0/135	80/80	100	100	100	0	-
2/M	25	0/125	75/70	97	95	90	2.5	-
3/F	13	5/140	80/85	100	100	95	0	-
4/F	38	15/105	65/60	76.5	75	71	22.5	HO
5/M	18	5/125	75/70	96	95	90	2.5	-
6/F	26	10/125	75/75	92	85	84	5.8	-
7/M	21	5/115	75/80	97	95	90	4.2	-
Average	21.9	5.7/124	75/74	94.1	92.1	88.6	5.4	-

FT: follow-up time, BM: Broberg and Morrey score, MEPI: Mayo Elbow Performance Index, ECS: Ewald scoring system, DASH: disabilities of the Arm, Shoulder and Hand score, HO: Heterotopic ossification.



**Figure 5.** Functional images of follow-up at 13 months.

The coronoid process fractures were exposed and fixed via an anteromedial approach in this study because of its advantages of less trauma, excellent exposure, and convenient surgery. In addition, the combined ligament avulsion or rupture could be repaired. Intraoperative physical examinations combined with X-ray fluoroscopy were used to assess whether avulsion or rupture of the LCL existed, and this lateral approach should be considered [8, 12, 15]. Coronoid process fractures are always accom-

panied with collateral ligament injuries. Physical examination may reveal local tenderness at the medial and lateral part of elbows in some patients, but the lateral stress test of the elbows is often refused because of related pain. In these patients, there is a lack of evidence to determine whether avulsion or rupture of collateral ligament is present. Therefore, the ligament is not intervened if the intraoperative examinations revealed sufficient stability of elbows after reduction and fixation of the coro-

## Loop plating technique in fractures of ulna coronoid process

noid process fractures [16, 17]. Within 4 weeks after surgery, plaster cast immobilization of the affected limb was adopted to facilitate the repair of ligaments and to ensure its stability. All the ligament injuries in this study were fresh, and were repaired and reconstructed through suture anchors or bone drilling and suture techniques. The transference of tendon palmaris longus was also used if necessary [18].

Suture anchors, Kirschner pins, screws and mini-plates were used for fixation of coronoid process fractures [8, 16, 19]. It may be difficult to reduce some coronoid process fractures where the anterior bony baffles are destroyed. In these cases, autologous iliac crest, apex of olecranon, discarded radial head and fibular head bone graft or prosthetic replacement are also used [16, 18, 20-24]. However, these reduction and fixation or reconstruction techniques are limited for wide use in the clinic because of the specific anatomy, mechanical characteristics, and limitations of the fixation instruments. In comminuted coronoid process fractures, there is still a lack of optimal fixation instruments and techniques.

For loop plating technique, 2# ETHIBOND sutures have the advantage of intensity reliability, which may help to tie up and fix the fracture fragments with better reduction [19], less exposure and fewer traumas. The sutures in this study were stringed and knotted at the posterior part of the ulna or at the medial part of the coronoid process or mini-plates. Temporarily fixed Kirschner pins need to be removed after examination of elbow stability or repair of collateral ligaments. It is important not to fix all the fragments and simply wrap the plate around the fragments to retain their shape so that the plate serves as a container for the fragments [14]. Patients with type I fractures and some type II fractures are cured by conservative treatment because the elbow is stable. The decision to perform ulnar neurolysis or nerve anterior transposition is still controversial [25]. Patients in this study had no preoperative symptoms of ulnar nerve injuries, therefore no interventions were adopted to manage ulnar nerves, and no postoperative symptoms of ulnar nerve injuries occurred.

Attention should be paid to hemostasis, and negative pressure drainage was placed in the front of elbows, to avoid postoperative hema-

toma and heterotopic ossification. Oral indomethacin is recommended for 6 weeks after surgery. Previous studies reported that oral selective cox 2 inhibitors might help to prevent the heterotopic ossification (HO) of elbows. Furthermore, there is no statistical difference between postoperative radiotherapy and oral drug therapy [26, 27]. Rehabilitation training plays an important role in the functional recovery of affected elbows, and we advocate the initiation of early rehabilitation exercises as soon as possible on the premise of favorable stability of the elbow joint. During the first 2 weeks, patients are encouraged to undertake active and passive exercise of the distal part of the affected limb and muscular isometric contraction training, which may be beneficial for detumescence, wound healing and repair of ligament and joint capsule. During the next 2 weeks, soft tissue, including ligament and joint capsule, should be repaired to some extent, and the patients were asked to undertake passive exercise of the affected elbows. The exercise time, frequency, intensity and amplitude should be increased gradually, and the plaster casts refixed after exercise. Active exercises of the affected elbows were undertaken at 4 weeks after surgery, because the reconstructed elbows should be relatively stable. Abduction of the ipsilateral shoulder should be avoided during rehabilitation because the introversion stress may lead to dislocation of fractures and fixations.

During follow-up, 1 patient had elbow heterotopic ossification (grade I-II) and therefore underwent cleanup of HO, arthrolysis and fixation of hinged external fixation. At last follow up, the MEPI was good. However, we do not have much experience in surgery of HO under arthroscopy. The incidence rate of HO is estimated to be greater than 20%, and it is considered to be related to fracture and dislocation of elbows. The early conservative therapy of HO has poor efficacy, and surgical treatment should be delayed for 6-9 months when the HO is matured [28, 29].

In our experience, the loop plating technique may be beneficial for the treatment of type III fractures and some type II fractures according to Regan-Morrey classification and O'Driscoll classification. Its best indication may be comminuted coronoid process fractures excluding simple coronoid fractures that are difficult

for reduction and fixation by other existing instruments and methods.

The coronoid process fracture is a rare condition, and in combination with the inclusion criteria, the numbers of patients in this study was small. Statistical analyses were conducted in this study, and other treatment methods were not compared because we only presented a small case series of seven patients to introduce a new method and our experience. More cases and data should be used in future studies to obtain a more scientific analytical result. Because of the insufficient follow-up time, the incidence of traumatic osteoarthritis and heterotopic ossification after this kind of surgery is not clear. There is a lack of relevant biomechanical studies to verify its safety and efficiency.

In summary, the application of a loop plating technique in fractures of the ulna coronoid process has a number of advantages including simple surgery with fewer traumas, less cost and satisfactory efficacy compared to other treatments. Therefore, it should be considered as a potential valid method for the treatment of ulna coronoid process fractures, including various fracture styles, especially for comminuted fractures, but excluding coronion fractures of the ulna coronoid process.

### Disclosure of conflict of interest

None.

**Address correspondence to:** Dr. Zhou Xiang, Department of Orthopaedics, West China Hospital, Sichuan University, 37 Guoxue Xiang, Chengdu 610041, Sichuan, China. Tel: +86-18980601393; Fax: +86-2885423438; E-mail: xiangzhou5@hotmail.com

### References

- [1] Hull JR, Owen JR, Fern SE, Wayne JS, Boardman ND 3rd. Role of the coronoid process in varus osteoarticular stability of the elbow. *J Shoulder Elbow Surg* 2005; 14: 441-6.
- [2] Butler DP, Alsousou J, Keys R. Isolated anterolateral fracture of the coronoid process of the ulna: a case report. *J Shoulder Elbow Surg* 2011; 20: e1-4.
- [3] Wells J, Ablove RH. Coronoid fractures of the elbow. *Clin Med Res* 2008; 6: 40-4.
- [4] Kiene J, Waldchen J, Paech A, Jurgens C, Schulz AP. Midterm Results of 58 Fractures of the Coronoid Process of the Ulna and their Concomitant Injuries. *Open Orthop J* 2013; 7: 86-93.
- [5] Regan W, Morrey B. Fractures of the coronoid process of the ulna. *J Bone Joint Surg Am* 1989; 71: 1348-54.
- [6] O'Driscoll SW, Jupiter JB, Cohen MS, Ring D, McKee MD. Difficult elbow fractures: pearls and pitfalls. *Instr Course Lect* 2003; 52: 113-34.
- [7] Adams JE, Sanchez-Sotelo J, Kallina CF 4th, Morrey BF, Steinmann SP. Fractures of the coronoid: morphology based upon computer tomography scanning. *J Shoulder Elbow Surg* 2012; 21: 782-8.
- [8] Chen HW, Liu GD, Ou S, Fei J, Zhao GS, Wu LJ, Pan J. Operative Treatment of Terrible Triad of the Elbow via Posterolateral and Anteromedial Approaches. *PLoS One* 2015; 10: e0124821.
- [9] Nalbantoğlu U, Gereli A, Kocaoglu B, Haklar U, Turkmen M. Surgical treatment of acute coronoid process fractures. *Acta Orthop Traumatol Turc* 2008; 42: 112-8.
- [10] Manidakis N, Sperelakis I, Hackney R, Kontakis G. Fractures of the ulnar coronoid process. *Injury* 2012; 43: 989-98.
- [11] Closkey RF, Goode JR, Kirschenbaum D, Cody RP. The role of the coronoid process in elbow stability. A biomechanical analysis of axial loading. *J Bone Joint Surg Am* 2000; 82-A: 1749-53.
- [12] Steinmann SP. Coronoid process fracture. *J Am Acad Orthop Surg* 2008; 16: 519-29.
- [13] Reichel LM, Milam GS, Hillin CD, Reitman CA. Osteology of the coronoid process with clinical correlation to coronoid fractures in terrible triad injuries. *J Shoulder Elbow Surg* 2013; 22: 323-8.
- [14] Park SM, Lee JS, Jung JY, Kim JY, Song KS. How should anteromedial coronoid facet fracture be managed? A surgical strategy based on O'Driscoll classification and ligament injury. *J Shoulder Elbow Surg* 2015; 24: 74-82.
- [15] Wang X, Chang SM, Yu GR. Anteromedial coronoid facet fractures. *Eur J Orthop Surg Traumatol* 2013; 23: 251-5.
- [16] Han SH, Yoon HK, Rhee SY, Lee JK. Anterior approach for fixation of isolated type III coronoid process fracture. *Eur J Orthop Surg Traumatol* 2013; 23: 395-405.
- [17] Jeon IH, Oh CW, Kyung HS, Park BC, Kim PT, Ihn JC. Functional outcome after operative treatment of eight type III coronoid process fractures. *J Trauma* 2005; 59: 418-23.
- [18] Wang YH, Meng QB, Wu JD, Ma JC, Liu F. Treatment of fractures of the ulnar coronoid process. *Orthop Surg* 2009; 1: 269-74.
- [19] Garrigues GE, Wray WH 3rd, Lindenhovius AL, Ring DC, Ruch DS. Fixation of the coronoid pro-



## Loop plating technique in fractures of ulna coronoid process

- cess in elbow fracture-dislocations. *J Bone Joint Surg Am* 2011; 93: 1873-1881
- [20] Kalicke T, Muhr G, Frangen TM. Dislocation of the elbow with fractures of the coronoid process and radial head. *Arch Orthop Trauma Surg* 2007; 127: 925-31.
- [21] Ring D, Guss D, Jupiter JB. Reconstruction of the coronoid process using a fragment of discarded radial head. *J Hand Surg Am* 2012; 37: 570-4.
- [22] van Riet RP, Morrey BF, O'Driscoll SW. Use of osteochondral bone graft in coronoid fractures. *J Shoulder Elbow Surg* 2005; 14: 519-23.
- [23] Zhao H, Herman B, Adeeb S, Sheps D, El-Rich M. Investigation of the geometries of the coronoid process and the fibular allograft as a potential surgical replacement. *Clin Biomech (Bristol, Avon)* 2013; 28: 626-34.
- [24] Gray AB, Alolabi B, Ferreira LM, Athwal GS, King GJ, Johnson JA. The effect of a coronoid prosthesis on restoring stability to the coronoid-deficient elbow: a biomechanical study. *J Hand Surg Am* 2013; 38: 1753-61.
- [25] Adams JE, Hoskin TL, Morrey BF, Steinmann SP. Management and outcome of 103 acute fractures of the coronoid process of the ulna. *J Bone Joint Surg Br* 2009; 91: 632-5.
- [26] Egol KA, Immerman I, Paksima N, Tejwani N, Koval KJ. Fracture-dislocation of the elbow functional outcome following treatment with a standardized protocol. *Bull NYU Hosp Jt Dis* 2007; 65: 263-70.
- [27] Zeiders GJ, Patel MK. Management of unstable elbows following complex fracture-dislocations—the “terrible triad” injury. *J Bone Joint Surg Am* 2008; 90 Suppl 4: 75-84.
- [28] Shukla DR, Pillai G, McAnany S, Hausman M, Parsons BO. Heterotopic ossification formation after fracture-dislocations of the elbow. *J Shoulder Elbow Surg* 2015; 24: 333-8.
- [29] Ranganathan K, Loder S, Agarwal S, Wong VC, Forsberg J, Davis TA, Wang S, James AW, Levi B. Heterotopic Ossification: Basic-Science Principles and Clinical Correlates. *J Bone Joint Surg Am* 2015; 97: 1101-11.