

## Original Article

# Improvement of ginkgolide B on diabetic nephropathy in streptozotocin (STZ)-induced rats

Yu-Xin Jiang<sup>1,3\*</sup>, Wei Li<sup>2\*</sup>, Guo-Guang Wang<sup>2</sup>, Wen-Qi Zhang<sup>4</sup>, Ye-Chao Lv<sup>4</sup>, Tian Sun<sup>4</sup>

<sup>1</sup>Anhui Key Laboratory of Active Biomolecules Research, Departments of <sup>2</sup>Pathophysiology, <sup>3</sup>Physiology, <sup>4</sup>Pathogen Biology, Wannan Medical College, Wuhu, Anhui, China. \*Equal contributors.

Received May 4, 2018; Accepted July 26, 2018; Epub December 15, 2018; Published December 30, 2018

**Abstract:** Aim: The goal of this study was to explore ginkgolide B as a therapy for amelioration of diabetic nephropathy. Methods: Healthy male Sprague-Dawley rats were randomly assigned to four groups: the control group, control treatment group, diabetes group, and the diabetes treatment group. Rats from the diabetes group and the diabetes treatment group were intraperitoneally injected with STZ (70 mg/kg) to induce diabetes. After 3 days, rats from the control and diabetes treatment groups received ginkgolide B, and animals of the control and diabetes groups received control diet. After administration of ginkgolide B for 8 weeks, the kidneys were collected for histological examination and analysis of Western blot. Blood samples were used to determine renal function. Results: Compared with the control group, levels of blood urea nitrogen (BUN), creatinine, and malondialdehyde (MDA) in the serum were significantly increased in the diabetes group, and activity of superoxide dismutase (SOD) was decreased. Expression of pro-inflammatory cytokines such as tumor necrosis factor (TNF)- $\alpha$ , interleukin (IL)-6 was increased in the diabetes group. Treatment with ginkgolide B significantly reduced the levels of blood urea nitrogen (BUN), creatinine, and MDA in serum, and 24 hour urea protein. Ginkgolide B significantly decreased expression of TNF- $\alpha$ , IL-6, transforming growth factor (TGF)- $\beta$ , and cyclooxygenase (COX)-2 in the kidney from rats in the diabetes treatment group compared with the diabetes group. Levels of heme oxygenase (HO)-1 and Nrf-2 were increased in kidney in the diabetes treatment group compared with the diabetes group. Conclusion: The results suggest that ginkgolide B ameliorates diabetic nephropathy via improving antioxidant and anti-inflammatory functions, and easing kidney fibrosis.

**Keywords:** Ginkgolide B, diabetic nephropathy, fibrosis

## Introduction

Diabetic nephropathy is one of the most common and complex vascular complications of diabetes, and regarded as a primary cause of chronic kidney lesions [1]. Less knowledge for the pathogenesis of diabetic complications including diabetic nephropathy results in therapeutic limitations. Various studies have suggested that multiple mechanisms are involved in the initiation and deterioration of diabetic nephropathy, such as metabolic disorders, hemodynamic failure, and genetic factors [2-4]. Increasing evidence shows that oxidative stress and inflammation contribute to vascular injuries, and increase the risk of diabetic complications including diabetic nephropathy [5-7]. Sustained hyperglycemia leads to excessive production of reactive oxygen species (ROS) via several

mechanisms such as glucose auto-oxidation, advanced glycosylation end products, xanthine oxidase activity, and activation of the polyol and hexosamine pathways [8, 9], while pro-inflammatory cytokines such as tumor necrosis factor-(TNF-)  $\alpha$ , interleukin-(IL-) 6 are associated with hyperglycemia [10-12]. Further studies indicate that oxidative stress and inflammation are involved in the initiation and progression of diabetic nephropathy and remodeling of the extracellular matrix [12-14]. Therefore, antioxidative and anti-inflammatory agents may be beneficial to diabetic nephropathy.

Ginkgolide B is a natural terpene lactone with bioactivity from ginkgo biloba leaves. Previous studies indicated that ginkgolide B can bind to platelet-activating factor (PAF) receptor, and inhibit activation of platelet [15, 16]. Therefore,

## Ginkgolide B and diabetic nephropathy

ginkgolide B is considered as the PAF antagonist, and decreases release of PAF-induced inflammatory mediators [17, 18]. Further, ginkgolide B has been reported to possess various pharmacological properties including reduction of Toll-like receptors (TLR) 4-mediated inflammatory response [19], protection of neurons against apoptosis induced by ischemia [20], antioxidant function [21], and anti-tumor activity [22]. Our previous and other studies showed the ability of ginkgolide B to improve vascular disorders in diabetes and suppress atherosclerosis [23, 24].

In the present study, we hypothesized that ginkgolide B could ameliorated diabetic nephropathy. Further, we investigated factors that affected the progression of diabetic nephropathy including oxidative stress and inflammation, and the mechanisms.

### Materials and methods

#### Materials

Streptozotocin (STZ) and sodium pentobarbital were purchased from Sigma (Sigma Chemical Co., St. Louis, MO, USA). A horseradish peroxidase-conjugated secondary anti-rabbit antibody, rabbit polyclonal antibodies,  $\beta$ -actin, heme oxygenase (HO)-1, tumor necrosis factor (TNF)- $\alpha$ , interleukin (IL)-6, transforming growth factor (TGF)- $\beta$ , nuclear factor-erythroid 2 (NF-E2)-related factor (Nrf)-2, and cyclooxygenase (COX)-2 were purchased from Abcam (USA). TNF- $\alpha$  and IL-6 specific ELISA kits were purchased from Hefei Bomei Biotechnology CO., LTD, (Hefei, China). Malondialdehyde (MDA) and superoxide dismutase (SOD) commercially available kits were obtained from Nanjing Jiancheng Bioengineering Institute (Nanjing, China).

#### Animals and induction of diabetes

Healthy male Sprague Dawley (SD) rats were obtained from the Animal Experimental Center in Wannan Medical College. Animals were fed in a standard animal laboratory with a controlled temperature of 22°C and a twelve-hour day/night alternate. After 2 weeks of acclimatization, rats were fasted for 12 hours for induction of diabetes. Fasting animals were administered STZ (70 mg/ml, dissolved in pH 4.5 citrate buffer) via intraperitoneal injection, and control

rats with the same volume buffer. Diabetes was diagnosed at 72 hours after injection of STZ by determining the fasting blood glucose concentration. Rats were considered as diabetic while their blood glucose concentrations were above 16.7 mmol/L.

#### Experimental protocol and treatment

After diabetes was confirmed, control and diabetic animals were randomly assigned to four groups: the control group, control treatment group, diabetes group, and the diabetes treatment group. Rats from the control and diabetes groups received a standard food and water *ad libitum*, and animals from the control treatment group and the diabetes treatment group received a standard food and water *ad libitum* and were treated with ginkgolide B (5 mg/kg body weight per day). At the end of the experiment, 24-hour urine was collected for determination of urea protein. After 8 weeks of treatment with ginkgolide B, rats were anesthetized with sodium pentobarbital (45 mg/Kg body weight), and sacrificed. Fasting blood samples were collected for biochemical analyses. Kidneys were harvested, weighed, and divided into two parts, one part was fixed in 4% paraformaldehyde for histopathological observation and the other was preserved under -80°C for analysis of Western blot.

#### Biochemical analysis

Blood urea nitrogen (BUN), creatinine, and 24-hour urea protein were determined with an automatic biochemistry analyzer.

#### Determination of inflammatory cytokines

Serums were separated from fasting blood samples by centrifugation at 2300 g. Inflammatory cytokines including TNF- $\alpha$  and IL-6 in serum were determined by specific ELISA kits according to manufacturer's specifications. Concentrations of TNF- $\alpha$  and IL-6 are presented as pg/ml.

#### Analysis of antioxidant effects

MDA content and SOD activity in serum were measured with commercially available kits according to manufacturer's specifications. MDA content and SOD activity are expressed as nmol/ml and U/ml, respectively.

## Ginkgolide B and diabetic nephropathy

**Table 1.** Effects of ginkgolide B on body weight (BW), kidney weight (KW), BW/KW ratio (mean  $\pm$  SD)

	Initial BW (g)	Final BW (g)	KW (g)	BW/KW ( $\times 10^{-3}$ )
Control	261.1 $\pm$ 11.73	432.1 $\pm$ 31.22	2.86 $\pm$ 0.28	6.62 $\pm$ 0.38
Control Treatment	259.5 $\pm$ 11.02	424.3 $\pm$ 32.65	2.82 $\pm$ 0.23	6.64 $\pm$ 0.39
Diabetes	264.9 $\pm$ 10.07**	243.3 $\pm$ 22.02**	2.50 $\pm$ 0.30**	10.27 $\pm$ 0.71**
Diabetes Treatment	263.4 $\pm$ 9.42##	322.8 $\pm$ 39.40##	2.56 $\pm$ 0.27##	7.96 $\pm$ 0.27##

\*\* $P < 0.01$  compared with the control group; ## $P < 0.01$  compared with the diabetes group.

**Table 2.** Effects of ginkgolide B on BUN, creatinine, and 24-hour urea protein (mean  $\pm$  SD)

	BUN (mmol/L)	Creatinine (mmol/L)	24-h urea protein (mg)
Control	4.90 $\pm$ 0.61	48.91 $\pm$ 7.48	3.97 $\pm$ 0.95
Control Treatment	4.71 $\pm$ 0.65	47.74 $\pm$ 8.92	4.12 $\pm$ 0.91
Diabetes	16.44 $\pm$ 2.27**	94.20 $\pm$ 9.43**	19.92 $\pm$ 4.77**
Diabetes Treatment	10.85 $\pm$ 1.27##	69.18 $\pm$ 9.35**	11.55 $\pm$ 2.36**

\*\* $P < 0.01$  compared with the control group; ## $P < 0.01$  compared with the diabetes group.

### Examination of histology

Fixed kidneys in 4% paraformaldehyde were imbedded in paraffin, and then cut 5- $\mu$ m-thickness sections for Hematoxylin-Eosin (H-E) staining. Morphological changes were observed under a light microscope.

### Western blotting

Kidneys were homogenized and lysed in pre-cooled lysis buffer (50 mmol/L HEPES, 10 mmol/L sodium pyrophosphate, 100 mmol/L sodium fluoride, 1% Triton-X 100, 100 mmol/L sodium orthovanadate) with 2 mmol/LPMSF, 2  $\mu$ g/L leupeptin and aprotinin. Protein in supernatant was quantified with a BCA kit (Bio-Rad). Equal amounts of protein were separated in 10% SDS-PAGE gel and then transferred to nitrocellulose membrane. Membranes were blocked with 5% nonfat milk dissolved in Tris-HCl buffer saline with 0.5% Tween 20 (TBS-T), then incubated with primary antibodies including HO-1, TNF- $\alpha$ , IL-6, TGF- $\beta$ , Nrf-2, and COX-2 (1:500) dissolved in TBS-T containing 5% nonfat milk overnight at 4°C. After washing, the membranes were incubated with a secondary antirabbit antibody (1:10,000) dissolved in TBS-T for 2 hours. Immunoblot of protein was visualized by DAB.

### Statistical analysis

All data are presented as mean  $\pm$  SD. Comparisons between groups were analyzed with

one-way analysis of variance (ANOVA) followed by Duncan's multiple range test (DMRT), or unpaired Student t test by using SPSS 18.0. A value of  $P < 0.05$  was considered to be statistically significant.

## Results

### General characteristics

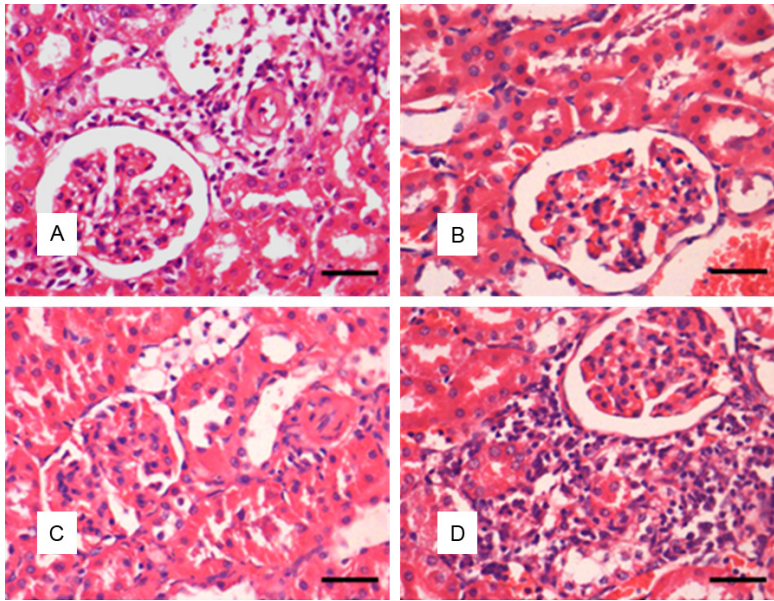
After injection with STZ, animals gradually presented many diabetic characteristics such as polyuria, increase in drinking water, and body weight (BW) loss. On day 3, rats injected with STZ showed hyperglycemia. As shown in **Table 1**, rats from diabetes group significantly lost BW in the final compared with the initial, and BW was significantly lower in diabetes group than in control group at the end of experiment ( $P < 0.01$ ). Change of kidney weight (KW) was not significant in diabetes group compared with control group, but KW/BW ratio was increased ( $P < 0.01$ ). Ginkgolide B treatment significantly reduced loss of BW, and prevented the increase of KW/BW ratio in diabetes treatment group compared with diabetes group.

### Biochemical changes

BUN, creatinine, and urea protein levels were significantly increased in the diabetes group compared with the control group ( $P < 0.01$ ) (**Table 2**). Administration of ginkgolide B to rats from the diabetes treatment group significantly reduced levels of BUN, creatinine, and urea protein to near normal levels ( $P < 0.01$ ) (**Table 2**).

### Morphological changes

Diabetic nephropathy is characterized by kidney hypertrophy, glomerulosclerosis, tubular edema, and thickened basement membrane. Sections stained with HE were observed under light microscopy, the results showed that rats

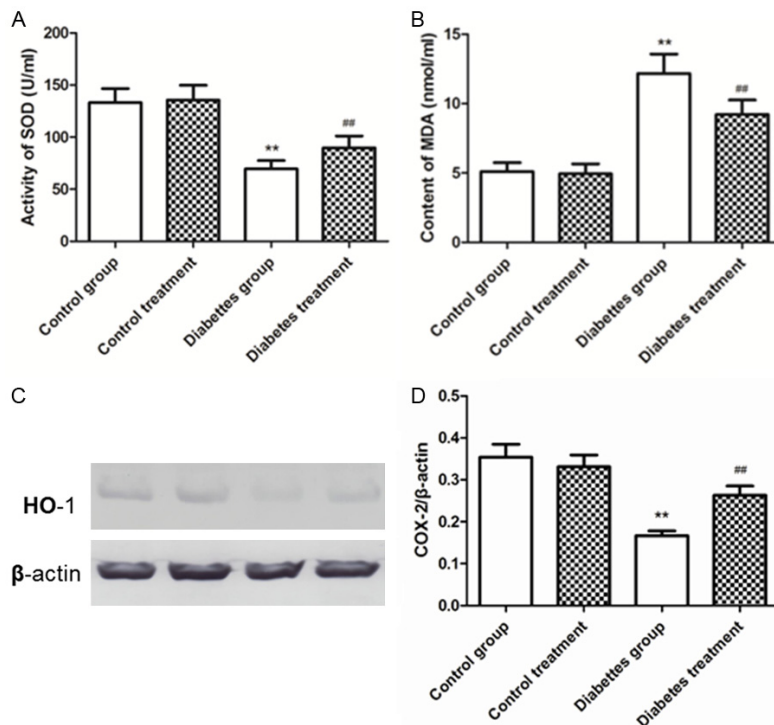


**Figure 1.** Histological changes of the kidney of each group. A. Control group. B. Control rat treatment. C. Diabetes group. D. Diabetes treatment. C. Kidney from the diabetic rats showed markedly severe lesion characterized by glomerular injury, interstitial expansion, and interstitial cellular infiltration. D. Morphology of glomerulus and tubulointerstitial impairments was ameliorated by treatment with ginkgolide B.

from the diabetes group presented marked increase in the glomerular volume compared with control group. Ginkgolide B treatment markedly improved the pathological alterations of the kidney such as decrease of the glomerular volume, and attenuation of renal swelling in diabetes treatment group compared to the diabetes group (**Figure 1**).

*Effects of ginkgolide B on inflammation*

It is well known that ginkgolide B is a natural antagonist of PAF, and reduces release of inflammatory cytokines [15, 16]. Our results showed that levels of inflammatory cytokines such as TNF- $\alpha$  and IL-6 in serum significantly were increased in diabetes group compared with the control group ( $P < 0.01$ ) (**Figure 3**). Treatment with ginkgolide B significantly decreased serum levels of TNF- $\alpha$  and IL-6 in the diabetes treatment group compared to the diabetes group. Further, levels of TNF- $\alpha$  and IL-6 in renal tissues were significantly decreased in the diabetes treatment group ( $P < 0.01$ ) (**Figure 3**).

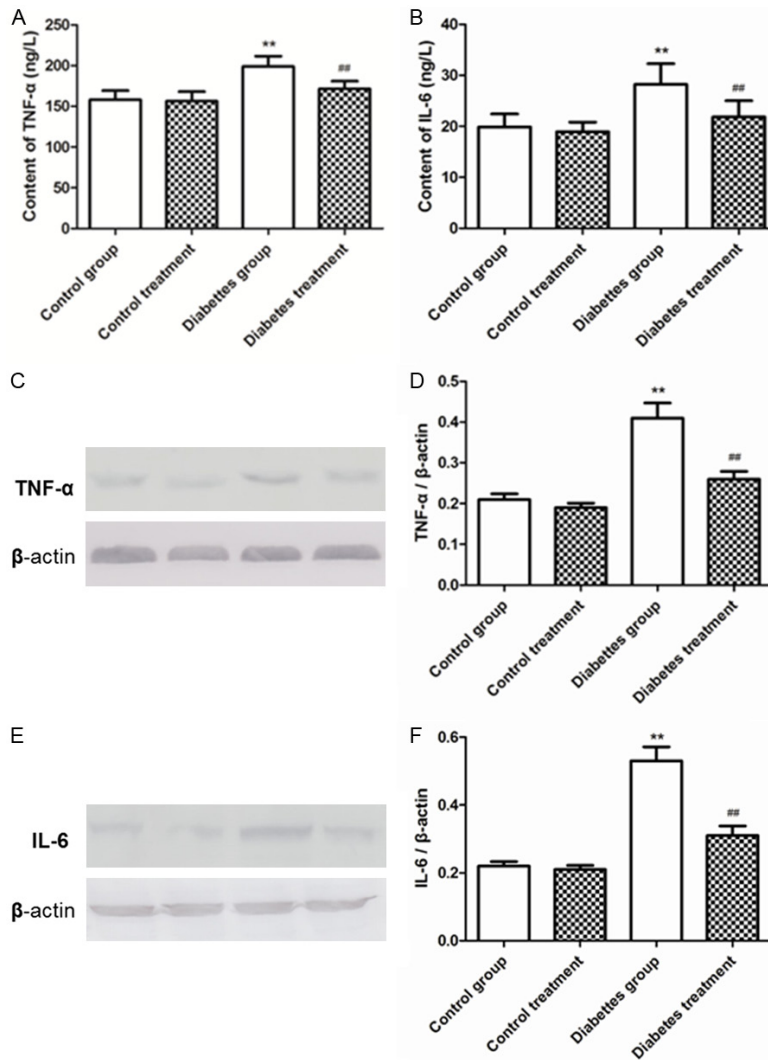


**Figure 2.** Changes of anti-oxidative effects. A. SOD activity in serum was significantly elevated by treatment with ginkgolide B in diabetic rats (\*\* $P < 0.01$  versus control group; ### $P < 0.01$  versus diabetes group). B. Treatment with ginkgolide B reduced MDA content in serum (\*\* $P < 0.01$  versus control group; ### $P < 0.01$  versus diabetes group). C. Expression of HO-1 was detected. D. Relative level of HO-1 was enhanced in diabetic rats treated ginkgolide B (\*\* $P < 0.01$  versus control group; ### $P < 0.01$  versus diabetes group).

*Change of antioxidant effects*

SOD activity was significantly reduced, and MDA content increased in serum from the diabetes group compared with the control group. Treatment with ginkgolide B significantly enhanced SOD activity, and decreased content in serum in the diabetes treatment group compared to the diabetes group ( $P < 0.01$ ) (**Figure 2**). Ginkgolide B significantly increased expres-

## Ginkgolide B and diabetic nephropathy



**Figure 3.** Changes of inflammatory response. A. TNF- $\alpha$  level in serum was significantly decreased in diabetic rats treated with ginkgolide B in diabetic rats (\*\* $P < 0.01$  versus control group; ## $P < 0.01$  versus diabetes group). B. Treatment with ginkgolide B decreased IL-6 level in serum (\*\* $P < 0.01$  versus control group; ## $P < 0.01$  versus diabetes group). C. Expression of TNF- $\alpha$  was detected. D. Relative level of TNF- $\alpha$  was decreased in diabetic rats treated ginkgolide B. E. Expression of IL-6 was detected. F. Relative level of IL-6 was decreased in diabetic rats treated ginkgolide B. (\*\* $P < 0.01$  versus control group; ## $P < 0.01$  versus diabetes group).

sion of HO-1 protein in kidney from the diabetes treatment group while compared to the diabetes group ( $P < 0.01$ ) (Figure 2).

### Effects of ginkgolide B on expression of TGF- $\beta$ , COX-2, and Nrf-2

Rats from diabetes group showed an increase in expression of TGF- $\beta$  and COX-2, and a decrease in expression of Nrf-2 compared with the control group ( $P < 0.01$ ) (Figure 4). Treatment

with ginkgolide B reduced expression TGF- $\beta$  and COX-2, and increased in expression of Nrf-2 in kidney ( $P < 0.01$ ) (Figure 4).

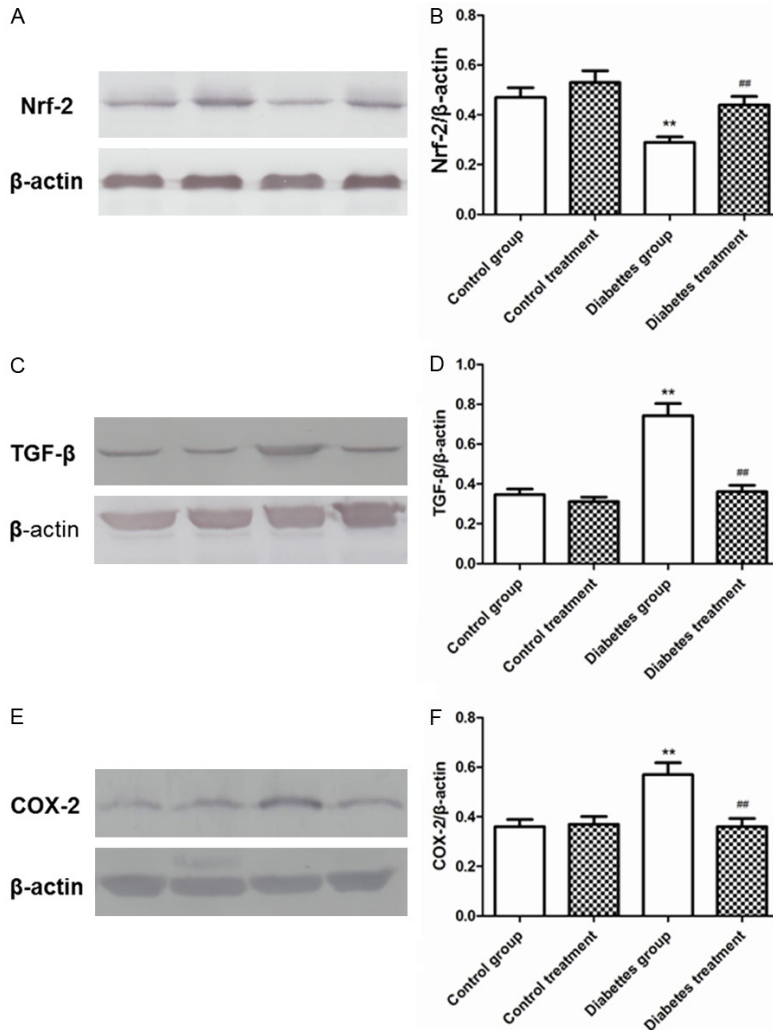
### Discussion

The results from the present study show that treatment with ginkgolide B significantly decreased levels of BUN and creatinine, and volume of 24-hour urea protein in STZ-induced diabetic rats. Further, ginkgolide B protected against development of diabetic nephropathy by reducing inflammatory response, and decreasing oxidation. Ginkgolide B treatment increased expression of Nrf-2 and HO-1 protein, and reduced expression of COX-2 and TGF- $\beta$  protein.

Diabetic nephropathy is one of the most common microvascular complications of diabetes mellitus, and regarded as an important contributor for the development of cardiovascular disease [25, 26]. Pathogenesis of diabetic nephropathy is poorly elucidated. Therefore, the effective therapies of diabetic nephropathy are few, even though when blood glucose was strictly controlled, diabetic nephropathy still developed [27]. In this study, we explored the effect of ginkgolide B on diabetic nephropathy and its possible mechanisms such as antioxidant and anti-inflammatory activities.

Our results show that administration of ginkgolide B to diabetic rats reduced levels of creatinine and BUN, and volume of 24-urea protein. Creatinine and BUN are considered as markers of kidney lesions, and are increased in rats with diabetic nephropathy [28, 29]. Further, ginkgolide B attenuated edema of tubular and glomerular lesion. These results suggest that ginkgolide B ameliorated diabetic nephropathy.

## Ginkgolide B and diabetic nephropathy



**Figure 4.** Effects of ginkgolide B on expression of Nrf-2 and TGF- $\beta$ . A. Expression of Nrf-2 was detected. B. Relative level of Nrf-2 was increased in diabetic rats treated ginkgolide B. C. Expression of TGF- $\beta$  was detected. D. Relative level of TGF- $\beta$  was decreased in diabetic rats treated ginkgolide B. E. Expression of COX-2 was detected. F. Relative level of COX-2 was decreased in diabetic rats treated ginkgolide B. (\*\* $P < 0.01$  versus control group; ## $P < 0.01$  versus diabetes group).

Ginkgolide B, a natural active terpene lactone from *ginkgo biloba*, is known as PAFR antagonist [30]. Increasing studies have shown that ginkgolide B exerts various pharmacological functions. Ginkgolide B has been reported to be able to enhance anti-oxidative activity by scavenging free radicals [31-33], and suppress inflammatory response by antagonizing PAFR and regulating TLR4 [17, 19]. In the present study, ginkgolide B reduced MDA content and levels of TNF- $\alpha$  and IL-6, and increased activity of SOD in serum. In addition, ginkgolide B increased expression of HO-1 and Nrf-1 protein,

and decreased expression of TNF- $\alpha$ , IL-6, and COX-2 in kidney. These data supported anti-oxidant and anti-inflammatory activities of ginkgolide B. It is well known that oxidative stress and inflammation are closely associated with diabetic complications including diabetic nephropathy [5, 7, 34]. Many studies have confirmed that sustained hyperglycemia produces excessive reactive oxygen species (ROS) production via multiple mechanisms such as auto-oxidation of glucose and the polyol and hexosamine pathways [8, 35]. ROS causes vascular injury and results in diabetic complications including diabetic nephropathy [36]. A previous study also demonstrated that ROS stimulates inflammatory response [37]. Nrf2 is an important transcription factor which mediates redox balance, and is regarded as a sensor of oxidative stress. Nrf2 has been reported to upregulate expression of HO-1 and glutathione S-transferase to mediate oxidative stress [38-40]. HO-1 and the by-products of heme catabolism by HO-1 such as heme into bilirubin and carbon monoxide (CO) have been reported to show anti-inflammatory, and

anti-oxidant effects [41], and HO/CO pathway is implicated in regulation of anti-inflammatory and cytoprotection by reducing COX-2 signaling [42, 43]. Our study showed that ginkgolide B upregulates expression of Nrf-2 in kidney from diabetic rats. Therefore, ginkgolide B protected against diabetic renal lesions via enhancing anti-oxidant and anti-inflammatory function.

Increasing evidence confirmed that ROS and inflammatory cytokines elevate TGF- $\beta$  level in the diabetic kidney cortex [44-46]. TGF- $\beta$  has been reported to be implicated in fibrosis of

## Ginkgolide B and diabetic nephropathy

diabetic kidney, therefore plays a vital role in development of diabetic nephropathy [47, 48]. The study showed that TGF- $\beta$  leads to accumulation of extracellular matrix (ECM) via increasing synthesis of ECM and reducing degradation of ECM [49]. Activation of TGF- $\beta$ 1 decreased expression of type I and III collagen, and PAI-1, which suggested that TGF- $\beta$ 1 is critical in the progression of renal fibrosis [50]. This study indicated that treatment with ginkgolide B reduced expression. This suggested that ginkgolide B attenuated diabetic nephropathy by inhibition of TGF- $\beta$  signaling.

In summary, the present study shows that ginkgolide B ameliorates diabetic nephropathy through anti-inflammatory and anti-oxidant functions. Further, ginkgolide B reduced expression of TGF- $\beta$ , a profibrogenic cytokine, which attenuated kidney fibrosis. Therefore, it is significant to further investigate the mechanism of the protective effects of ginkgolide B on diabetic nephropathy.

### Acknowledgements

This work was supported by The National Natural Science Foundation of China: 811-72790 and 81671586.

### Disclosure of conflict of interest

None.

**Address correspondence to:** Guo-Guang Wang, Department of Pathophysiology, Wannan Medical College, 22# Wenchang West Road, Wuhu 241000, Anhui, China. Tel: +86 553 3932476; E-mail: guo-guangw1226@sina.com

### References

- [1] Gilbertson DT, Liu J, Xue JL, Louis TA, Solid CA, Ebben JP and Collins AJ. Projecting the number of patients with end-stage renal disease in the United States to the year 2015. *J Am Soc Nephrol* 2005; 16: 3736-3741.
- [2] Kanwar YS, Sun L, Xie P, Liu FY and Chen S. A glimpse of various pathogenetic mechanisms of diabetic nephropathy. *Annu Rev Pathol* 2011; 6: 395-423.
- [3] Kato M and Natarajan R. Diabetic nephropathy—emerging epigenetic mechanisms. *Nat Rev Nephrol* 2014; 10: 517-530.
- [4] Jerums G, Premaratne E, Panagiotopoulos S, Clarke S, Power DA and MacIsaac RJ. New and old markers of progression of diabetic nephropathy. *Diabetes Res Clin Pract* 2008; 82 Suppl 1: S30-37.
- [5] Mittal M, Siddiqui MR, Tran K, Reddy SP and Malik AB. Reactive oxygen species in inflammation and tissue injury. *Antioxid Redox Signal* 2014; 20: 1126-1167.
- [6] Jha JC, Gray SP, Barit D, Okabe J, El-Osta A, Namikoshi T, Thallas-Bonke V, Wingler K, Szyn-dralewicz C, Heitz F, Touyz RM, Cooper ME, Schmidt HH and Jandeleit-Dahm KA. Genetic targeting or pharmacologic inhibition of NADPH oxidase nox4 provides renoprotection in long-term diabetic nephropathy. *J Am Soc Nephrol* 2014; 25: 1237-1254.
- [7] Tonelli M, Sacks F, Pfeffer M, Jhangri GS and Curhan G. Biomarkers of inflammation and progression of chronic kidney disease. *Kidney Int* 2005; 68: 237-245.
- [8] Nishikawa T, Edelstein D, Du XL, Yamagishi S, Matsumura T, Kaneda Y, Yorek MA, Beebe D, Oates PJ, Hammes HP, Giardino I and Brownlee M. Normalizing mitochondrial superoxide production blocks three pathways of hyperglycaemic damage. *Nature* 2000; 404: 787-790.
- [9] Brownlee M. Biochemistry and molecular cell biology of diabetic complications. *Nature* 2001; 414: 813-820.
- [10] Wu W, Wang M, Sun Z, Wang X, Miao J and Zheng Z. The predictive value of TNF-alpha and IL-6 and the incidence of macrovascular complications in patients with type 2 diabetes. *Acta Diabetol* 2012; 49: 3-7.
- [11] Tuttle HA, Davis-Gorman G, Goldman S, Copeland JG and McDonagh PF. Proinflammatory cytokines are increased in type 2 diabetic women with cardiovascular disease. *J Diabetes Complications* 2004; 18: 343-351.
- [12] Giacco F and Brownlee M. Oxidative stress and diabetic complications. *Circ Res* 2010; 107: 1058-1070.
- [13] Festa A, D'Agostino R Jr, Howard G, Mykkanen L, Tracy RP and Haffner SM. Chronic subclinical inflammation as part of the insulin resistance syndrome: the insulin resistance atherosclerosis study (IRAS). *Circulation* 2000; 102: 42-47.
- [14] Navarro-Gonzalez JF, Mora-Fernandez C, Muros de Fuentes M and Garcia-Perez J. Inflammatory molecules and pathways in the pathogenesis of diabetic nephropathy. *Nat Rev Nephrol* 2011; 7: 327-340.
- [15] Lamant V, Mauco G, Braquet P, Chap H and Douste-Blazy L. Inhibition of the metabolism of platelet activating factor (PAF-acether) by three specific antagonists from Ginkgo biloba. *Biochem Pharmacol* 1987; 36: 2749-2752.
- [16] Ji RL, Xia SH, Di Y and Xu W. Mechanism and dose-effect of ginkgolide B on severe acute pancreatitis of rats. *World J Gastroenterol* 2011; 17: 2241-2247.

## Ginkgolide B and diabetic nephropathy

- [17] Ma L, Liu X, Zhao Y, Chen B, Li X and Qi R. Ginkgolide B reduces LOX-1 expression by inhibiting Akt phosphorylation and increasing Sirt1 expression in oxidized LDL-stimulated human umbilical vein endothelial cells. *PLoS One* 2013; 8: e74769.
- [18] Liu X, Yan Y, Bao L, Chen B, Zhao Y and Qi R. Ginkgolide B inhibits platelet release by blocking Syk and p38 MAPK phosphorylation in thrombin-stimulated platelets. *Thromb Res* 2014; 134: 1066-1073.
- [19] Chen K, Sun W, Jiang Y, Chen B, Zhao Y, Sun J, Gong H and Qi R. Ginkgolide B suppresses TLR4-mediated inflammatory response by inhibiting the phosphorylation of JAK2/STAT3 and p38 MAPK in high glucose-treated HUVECs. *Oxid Med Cell Longev* 2017; 2017: 9371602.
- [20] Wu X, Qian Z, Ke Y, Du F and Zhu L. Ginkgolide B preconditioning protects neurons against ischaemia-induced apoptosis. *J Cell Mol Med* 2009; 13: 4474-4483.
- [21] Jin GH, Huang Z, Tan XF, Tian ML, Zhang XH, Qin JB, Xu HJ, Yew DT and Mak YT. Effects of Ginkgolide on the development of NOS and AChE positive neurons in the embryonic basal forebrain. *Cell Biol Int* 2006; 30: 500-504.
- [22] Chan WH and Hsu YD. Dosage effects of ginkgolide B on ethanol-induced cell death in human hepatoma G2 cells. *Ann N Y Acad Sci* 2007; 1095: 388-398.
- [23] Wang GG, Chen QY, Li W, Lu XH and Zhao X. Ginkgolide B increases hydrogen sulfide and protects against endothelial dysfunction in diabetic rats. *Croat Med J* 2015; 56: 4-13.
- [24] Liu X, Zhao G, Yan Y, Bao L, Chen B and Qi R. Ginkgolide B reduces atherogenesis and vascular inflammation in ApoE(-/-) mice. *PLoS One* 2012; 7: e36237.
- [25] Sarnak MJ, Levey AS, Schoolwerth AC, Coresh J, Cullerton B, Hamm LL, McCullough PA, Kasiske BL, Kelepouris E, Klag MJ, Parfrey P, Pfeffer M, Raij L, Spinosa DJ and Wilson PW. Kidney disease as a risk factor for development of cardiovascular disease: a statement from the American heart association councils on kidney in cardiovascular disease, high blood pressure research, clinical cardiology, and epidemiology and prevention. *Hypertension* 2003; 42: 1050-1065.
- [26] Schiele F. Renal dysfunction and coronary disease: a high-risk combination. *J Nephrol* 2009; 22: 39-45.
- [27] Gao C, Aqie K, Zhu J, Chen G, Xu L, Jiang L and Xu Y. MG132 ameliorates kidney lesions by inhibiting the degradation of Smad7 in streptozotocin-induced diabetic nephropathy. *J Diabetes Res* 2014; 2014: 918396.
- [28] Makino H, Tanaka I, Mukoyama M, Sugawara A, Mori K, Muro S, Suganami T, Yahata K, Ishibashi R, Ohuchida S, Maruyama T, Narumiya S and Nakao K. Prevention of diabetic nephropathy in rats by prostaglandin E receptor EP1-selective antagonist. *J Am Soc Nephrol* 2002; 13: 1757-1765.
- [29] Breyer MD, Bottinger E, Brosius FC 3rd, Coffman TM, Harris RC, Heilig CW and Sharma K. Mouse models of diabetic nephropathy. *J Am Soc Nephrol* 2005; 16: 27-45.
- [30] Cao Y, Stafforini DM, Zimmerman GA, McIntyre TM and Prescott SM. Expression of plasma platelet-activating factor acetylhydrolase is transcriptionally regulated by mediators of inflammation. *J Biol Chem* 1998; 273: 4012-4020.
- [31] Grypioti AD, Kostopanagiotou G, Demopoulos CA, Roussos A and Mykoniatis M. Platelet activating factor (PAF) antagonism with ginkgolide B protects the liver against acute injury. importance of controlling the receptor of PAF. *Dig Dis Sci* 2008; 53: 1054-1062.
- [32] Maitra I, Marcocci L, Droy-Lefaix MT and Packer L. Peroxyl radical scavenging activity of Ginkgo biloba extract EGb 761. *Biochem Pharmacol* 1995; 49: 1649-1655.
- [33] Bate C, Salmona M and Williams A. Ginkgolide B inhibits the neurotoxicity of prions or amyloid-beta1-42. *J Neuroinflammation* 2004; 1: 4.
- [34] Okamura DM and Himmelfarb J. Tipping the redox balance of oxidative stress in fibrogenic pathways in chronic kidney disease. *Pediatr Nephrol* 2009; 24: 2309-2319.
- [35] Evans JL, Goldfine ID, Maddux BA and Grodsky GM. Are oxidative stress-activated signaling pathways mediators of insulin resistance and beta-cell dysfunction? *Diabetes* 2003; 52: 1-8.
- [36] Hakim FA and Pflueger A. Role of oxidative stress in diabetic kidney disease. *Med Sci Monit* 2010; 16: RA37-48.
- [37] Ha H, Yu MR, Choi YJ, Kitamura M and Lee HB. Role of high glucose-induced nuclear factor-kappaB activation in monocyte chemoattractant protein-1 expression by mesangial cells. *J Am Soc Nephrol* 2002; 13: 894-902.
- [38] He X, Kan H, Cai L and Ma Q. Nrf2 is critical in defense against high glucose-induced oxidative damage in cardiomyocytes. *J Mol Cell Cardiol* 2009; 46: 47-58.
- [39] Zhao Y, Tan Y, Dai J, Li B, Guo L, Cui J, Wang G, Shi X, Zhang X, Mellen N, Li W and Cai L. Exacerbation of diabetes-induced testicular apoptosis by zinc deficiency is most likely associated with oxidative stress, p38 MAPK activation, and p53 activation in mice. *Toxicol Lett* 2011; 200: 100-106.



## Ginkgolide B and diabetic nephropathy

- [40] Tan Y, Ichikawa T, Li J, Si Q, Yang H, Chen X, Goldblatt CS, Meyer CJ, Li X, Cai L and Cui T. Diabetic downregulation of Nrf2 activity via ERK contributes to oxidative stress-induced insulin resistance in cardiac cells in vitro and in vivo. *Diabetes* 2011; 60: 625-633.
- [41] Otterbein LE, Bach FH, Alam J, Soares M, Tao Lu H, Wysk M, Davis RJ, Flavell RA and Choi AM. Carbon monoxide has anti-inflammatory effects involving the mitogen-activated protein kinase pathway. *Nat Med* 2000; 6: 422-428.
- [42] Chhikara M, Wang S, Kern SJ, Ferreyra GA, Barb JJ, Munson PJ and Danner RL. Carbon monoxide blocks lipopolysaccharide-induced gene expression by interfering with proximal TLR4 to NF-kappaB signal transduction in human monocytes. *PLoS One* 2009; 4: e8139.
- [43] Chakraborty P, Saraswat G and Kabir SN. alpha-Dihydroxychalcone-glycoside (alpha-DHC) isolated from the heartwood of *Pterocarpus marsupium* inhibits LPS induced MAPK activation and up regulates HO-1 expression in murine RAW 264.7 macrophage. *Toxicol Appl Pharmacol* 2014; 277: 95-107.
- [44] Studer RK, Craven PA and DeRubertis FR. Antioxidant inhibition of protein kinase C-signaled increases in transforming growth factor-beta in mesangial cells. *Metabolism* 1997; 46: 918-925.
- [45] Ha H and Lee HB. Reactive oxygen species as glucose signaling molecules in mesangial cells cultured under high glucose. *Kidney Int Suppl* 2000; 77: S19-25.
- [46] Lindblom R, Higgins G, Coughlan M and de Haan JB. Targeting mitochondria and reactive oxygen species-driven pathogenesis in diabetic nephropathy. *Rev Diabet Stud* 2015; 12: 134-156.
- [47] Shibuya K, Kanasaki K, Isono M, Sato H, Omata M, Sugimoto T, Araki S, Isshiki K, Kashiwagi A, Haneda M and Koya D. N-acetyl-seryl-aspartyl-lysyl-proline prevents renal insufficiency and mesangial matrix expansion in diabetic db/db mice. *Diabetes* 2005; 54: 838-845.
- [48] Border WA and Noble NA. TGF-beta in kidney fibrosis: a target for gene therapy. *Kidney Int* 1997; 51: 1388-1396.
- [49] Sureshbabu A, Muhsin SA and Choi ME. TGF-beta signaling in the kidney: profibrotic and protective effects. *Am J Physiol Renal Physiol* 2016; 310: F596-F606.
- [50] Ma LJ, Yang H, Gaspert A, Carlesso G, Barty MM, Davidson JM, Sheppard D and Fogo AB. Transforming growth factor-beta-dependent and -independent pathways of induction of tubulointerstitial fibrosis in beta6(-/-) mice. *Am J Pathol* 2003; 163: 1261-1273.