

Original Article

A case of Behcet's-like retinopathy of traumatic rupture of the lens capsule

Jingyi Hu*, Liuxueying Zhong*, Wei Chi, Mei Li, Yongxin Zheng

State Key Laboratory of Ophthalmology, Zhongshan Ophthalmic Center, Sun Yat-sen University, Guangzhou, China.
*Equal contributors.

Received May 29, 2018; Accepted August 4, 2018; Epub December 15, 2018; Published December 30, 2018

Abstract: The causes of uveitis included infections, systemic disease, autoimmune syndromes, post-traumatic, post-surgical, and lens-induced. Lens-induced uveitis is commonly associated with break of the lens capsule. We report a unique case, which is the first case to our knowledge, of uveitis caused by traumatic rupture of the lens capsule presenting Behcet's-like fundus change. Ocular manifestation is unique and systemic factors should be considered.

Keywords: Traumatic uveitis, lens-induced uveitis, Behcet's disease, Behcet's-like retinopathy

Introduction

Intraocular antigens exposed like lens cortex without emergency treatment may cause intraocular inflammation, including uveitis. Uveitis can be classified by cause of inflammation such as infections, systemic disease, autoimmune syndromes, post-traumatic, postsurgical, and lens-induced [1, 2]. We report a unique case, presenting unfamiliar manifestation, of lens-induced uveitis and Behcet's-like retinopathy due to traumatic rupture of the lens capsule.

Case report

A 26-year-old male with a history of penetrating injury without foreign body remains two months ago was referred to us to improve the visual acuity. His right eye (OD) was wounded by an iron nail without immediate pain or reduced vision. After pulling out the nail by himself, he went to a local hospital for sutures of laceration of the eyeball. On post-traumatic day 2, visual acuity OD was decreased and he was diagnosed with traumatic cataract OD. On post-traumatic week 1, waves-shaped shadow OD emerged and visual process decreased. The local hospital diagnosed him as endophthalmitis OD, treated him with intraocular injection of vancomycin OD and systemic application of antibiotics. Waves-shaped shadow gradually

disappeared without an increase in visual acuity.

Ophthalmic examination revealed visual acuity of OD and left eye (OS) were finger counts (FC) and 1.5, respectively. Slit lamp examination showed a penetrating corneal laceration suture located on the nasal side of limbus OD, accompanying local posterior synechia and dusty keratic precipitates (KPs). A peripheral posterior capsule rupture could be found at the same clock location after mydriasis. Vitreous OD were clouded and fundus was invisible. OS showed no alteration and ultrasound OD reminded a cloudy with bulky high echo and the presence of a foreign body was excluded (**Figure 1**).

Pars plana vitrectomy (PPV) was performed along with lens-chopping, retinal photocoagulation, vitreous lavage, and fluid-gas exchange. During operation, the cortex of lens was found to overflow from the capsule rupture. Vitreous was severely clouded with low adhesion snowballs. Edema of the retina without proliferation was found. Retinal veins were tortuous and enlarged, as well as hyperemia of the optic disk. No retinal arterial closure or white sheath was found. The retinal hole was visible in the periphery of the retina at 8 o'clock. The size was 1/2PD without retinal detachment (**Figure 2**).

After the operation, postoperative routine antibiotics were provided. At the same time, cultiva-

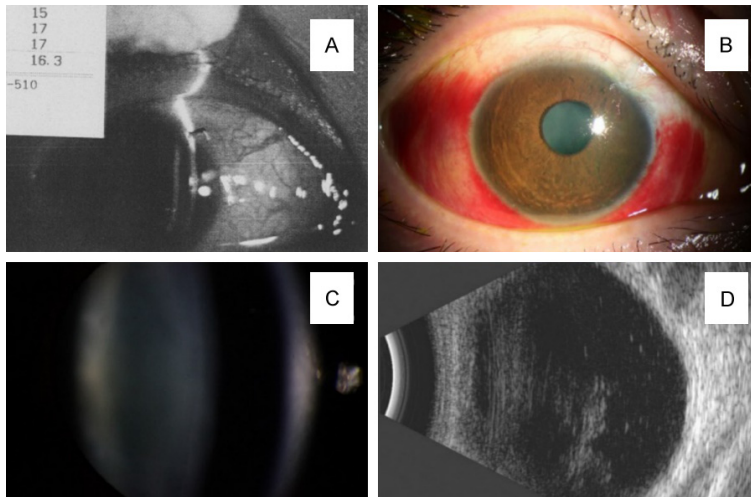


Figure 1. A. Slit lamp examination of the right eye of the patient in the local hospital. Image shows conjunctival congestion and penetrating wound. B. Slit lamp examination of the right eye of the patient in our hospital. Image shows conjunctival congestion and penetrating wound scarring. C. Slit lamp examination of the right eye of the patient in our hospital. Image shows early stage of cataract. D. Ultrasound image of the right eye of the patient in our hospital shows a rough particle in the vitreous cavity without the signs of endophthalmitis.

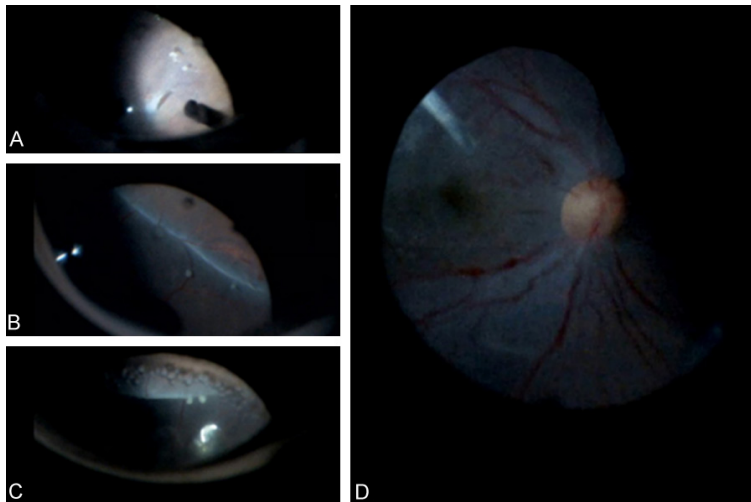


Figure 2. Images of the operation of the right eye. A. Image shows the retinal break. B and C. Image shows low adhesion snow-ball. D. Image shows retinal veins were tortuous and enlarged, as well as hyperemia of the optic disk.

tion samples showed no bacterial or fungus. On post-operative day 10, there was no obvious improvement of the fundus. Fluorescence fundus angiography (FFA) showed retinal capillary dilatation, optic disc edema and leakage at the late stage (**Figure 3**). He was treated with middle dose glucocorticoid. Improvement was not shown until used in combination with cyclosporine. Vision generally improved and edema

of retina slowly regressed (**Figure 4**).

The patient admitted oral aphthosis recurred these years, most frequently three times a month, excluded other skin lesions or joint lesions. However, after this injury, no oral aphthosis reappeared, which was related to the hormone-therapy.

Discussion

In this case, during this two-month course, the patient showed no retinal expression of retinal contusion, acute retinal necrosis or arteritis, only a few white snowballs and a small hole was found. Treatment with antibiotics and glucocorticoids had no obvious effect which can rule out the possibilities of retinal contusion, endophthalmitis, and drug-induced retinopathy.

According to the recurrence of oral aphthosis, the intraoperative findings and FFA corresponded to Behcet's disease and the effectiveness of cyclosporine, suggested T-cell tolerance. Traumatic rupture of the lens capsule induced immune-related endophthalmitis, caused by breakdown of the T-cell tolerance [3]. Lens-induced uveitis and Behcet's disease are diseases that related to the failure of T-cell tolerance. Therefore, rupture of the lens capsule or cortex overflow could induce onset of Behcet's disease. Alexandra van der

Woerdt [3] and some cases presented details of lens-induced uveitis. Inomata Hajime [4] examined 26 patients with Behcet's disease who underwent enucleation which was associated with the development of phacoanaphylactic endophthalmitis. His study displayed that removal of the lens could prevent phacoanaphylaxis in eyes and save patients' vision. However, none of these mentioned specific

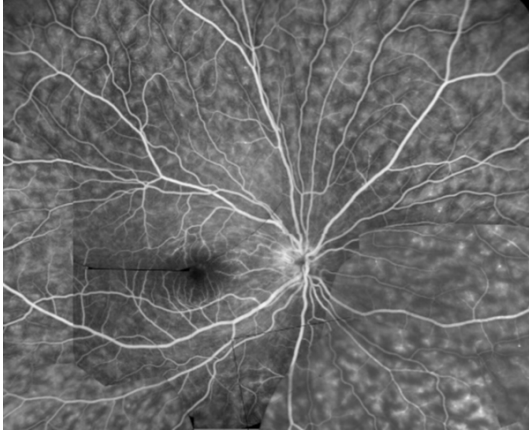


Figure 3. Pieced together Images of the fundus fluorescence angiography of the right eye after the operation showed Behcet's-like fundus, retinal capillary dilatation, optic disc edema, and late stage leakage.

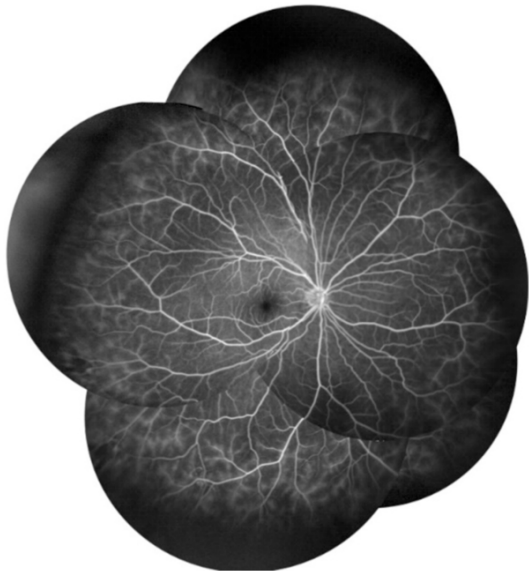


Figure 4. Images of the fundus fluorescence angiography, of the right eye after the operation and the treatment of cyclosporine, show capillary leakage was reduced.

cases of traumatic rupture of the lens capsule trigger for the intraocular manifestation of Behcet's disease. For this case, evidence was not enough to diagnose Behcet's disease. It could be an atypical case of Behcet's disease, or, a particular case that present Behcet's-like retinopathy.

We are not sure if this is an individual case. HLAB*51 was negative and HLAB*40:01, HLAA*11:01, HLAC*03:04, HLAC*07:02, DQB1*03:02, DQB1*04:01, DPB1*05:01, DR-

B1*04:05, DRB1*04:06 was positive in this case, more similar cases need to be recorded to analyze the correlation of HLA. Another patient without oral aphthosis received the operation on post-traumatic day 4. FFA showed retinal capillary dilatation as this case, however, no snow-ball emerged.

It is important to note that examination of aqueous humor was suggested, however, was rejected by the patient. Although tests in animal models would be good methods to explore the causes and manifestations of Behcet's-like retinopathy, it would be a challenge to construct a satisfactory animal model.

To the best of our knowledge, this is the first report of traumatic rupture of the lens capsule that triggers intraocular manifestation of Behcet's disease. Both lens-induced uveitis and Behcet's disease are T-cell tolerance related diseases. Therefore, lens-induced uveitis and Behcet's disease share similar manifestation and treatments. More cases may provide insight into treatments and diagnoses.

Acknowledgements

This work was supported by the grants from the National Natural Science Foundation of China [81570839], [81400384].

Disclosure of conflict of interest

None.

Address correspondence to: Dr. Yongxin Zheng, State Key Laboratory of Ophthalmology, Zhongshan Ophthalmic Center, Sun Yat-sen University, Guangzhou 510060, China. Tel: 8602087331537; E-mail: fdhqs@126.com

References

- [1] Davatchi F, Shahram F, Chams-Davatchi C, Shams H, Nadji A, Akhlaghi M, Faezi T, Ghodsi Z, Faridar A, Ashofteh F, Sadeghi Abdollahi B. Behcet's disease: from east to west. *Clin Rheumatol* 2010; 29: 823-33.
- [2] Harman LE, Margo CE, Roetzheim RG. Uveitis: the collaborative diagnostic evaluation. *Am Fam Physician* 2014; 90: 711-6.
- [3] Van Der Woerd A. Lens-induced uveitis. *Vet Ophthalmol* 2000; 3: 227-234.
- [4] Inomata H, Yoshikawa H, Rao NA. Phacoanaphylaxis in Behcet's disease-A clinicopathologic and immunohistochemical study. *Ophthalmology* 2003; 110: 1942-1945.