

Case Report

Laparoscopic removal of a disrupted Grafenberg ring perforating the uterus in a woman without symptoms after 34 years of insertion

Baorong Gao^{1,2}, Xin Tan², Guolin Luo²

¹Key Laboratory of Birth Defects and Related Diseases of Women and Children (Sichuan University), Ministry of Education, Chengdu, Sichuan, China; ²Department of Obstetrics and Gynaecology, West China Second University Hospital, Sichuan University, No. 20, Section 3, Renmin Nan Lu, Chengdu 610041, Sichuan Province, China

Received June 1, 2020; Accepted December 28, 2020; Epub March 15, 2021; Published March 30, 2021

Abstract: Complications regarding the Grafenberg ring (one type of intrauterine device, IUD) have been rarely reported in recent years due to its low usage and difficult removal process. In this report, we present a rare case of a disrupted Grafenberg ring asymptotically perforating the uterus and the left fallopian tube in a woman. 34 years previously, the patient received a spiral silver Grafenberg ring insertion after her first child was born. 26 years ago, she once tried to remove it but failed. One year later she got pregnant while having the IUD and gave birth to her second child at term. As she was completely asymptomatic, the IUD in the pelvis was found accidentally, and then she was admitted to our hospital to remove it. The location of the IUD was confirmed by transvaginal ultrasound. Exploratory laparoscopy was then performed. The disrupted and deformed IUD was successfully removed, and she was discharged on the third postoperative day without complications.

Keywords: Intrauterine device, perforation, laparoscopy

Introduction

The intrauterine device (IUD) is a widely used contraceptive method due to its reversibility, efficacy, and safety [1]. However, IUDs have some inherent complications, such as disrupted IUD, uterine perforation, and migration [2, 3]. The Grafenberg ring, a type of IUD, is uncommon now due to its low usage and difficulty in removal [2], and the perforation of the uterus by the Grafenberg ring is even rarer. Herein we report a case of a 56-year-old woman with a disrupted Grafenberg ring perforating the uterus but without any symptoms. The Grafenberg ring was successfully removed laparoscopically. This study was approved by the Medical Ethics Committee of West China Second Hospital of Sichuan University. Written informed consent was obtained from the patient.

Case report

A 56-year-old gravida 2, para 2 woman came to our gynecologic clinic to confirm and remove

the Grafenberg ring. 34 years previously, she received a spiral silver Grafenberg ring insertion uneventfully after she delivered her first child. 26 years ago, she tried to retrieve the IUD to have her second pregnancy, but she was told that the IUD was lost without further radiographic evaluation. One year later, she became pregnant and gave birth to her second child via spontaneous vaginal delivery.

The patient reported that she had a history of COPD with a chronic cough, but she denied having any abdominal or pelvic discomfort, so no relevant radiographic or ultrasonic examination was performed. One week prior to her admission to our hospital, a pelvic foreign body was accidentally found when she underwent an x-ray of her lumbar vertebrae. Then she was admitted to our hospital for further examination. The location of the IUD was discovered by transvaginal ultrasonography (**Figure 1**), and an exploratory laparoscopy was then performed by a gynecologist. The posterior wall of the uterus adhered to the anterior wall of the rectum.

Laparoscopic removal of a disrupted IUD

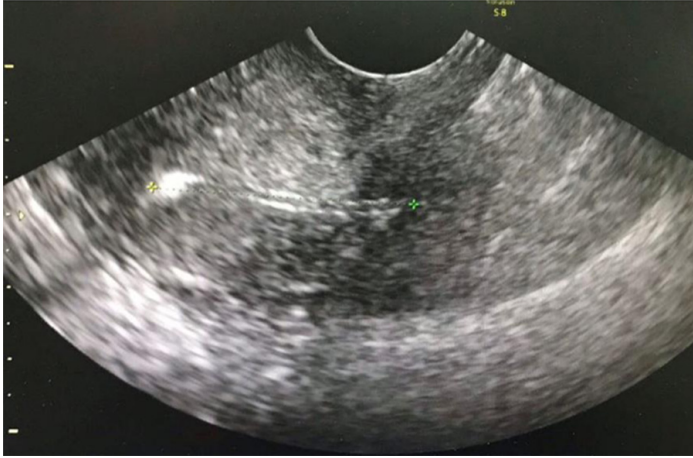

Figure 1. Transvaginal ultrasound showed a linear hyperechoic foreign body in the pelvis, with one end of it having perforated through the posterior wall of the uterus, and the other end having perforated the left fallopian tube with a possible adhesion formation.

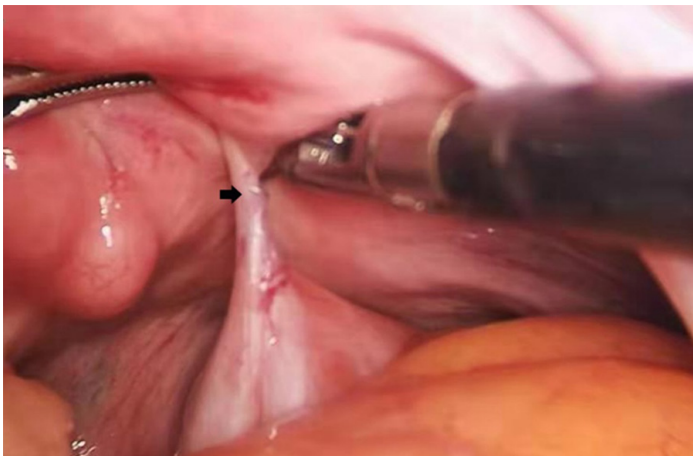


Figure 2. Part of the Grafenberg ring embedded in the adhesive between the posterior wall of the uterus and the anterior wall of the rectum (black arrow).

Careful use of cautery and a sharp dissection of the adhesion revealed a disrupted and deformed Grafenberg ring. One end of it perforated the uterus and obliquely entered the wall of rectum about 2 centimeters, without penetrating the rectal mucosa (**Figure 2**). The left fallopian tube was tightly wrapped and adhered to the sigmoid mesentery. Those adhesions were separated, with the other end of the IUD penetrating through the left cornua and the left fallopian tube (**Figure 3**). The IUD was finally clamped out with forceps and the left fallopian tube was resected. The patient's operative and postoperative courses were unremarkable, and

she was discharged on postoperative day 3 without any complications.

Discussion

The IUD as a foreign body can dislocate, perforate the uterus, and even migrate to an extrauterine location [4]. Uterine perforation is a major, serious complication, especially with an unexpected pregnancy occurring. However, in this case, the patient got pregnant and delivered her child at term uneventfully while still having the IUD. Perforation can occur at any time during or after insertion, depending on the type of device, insertion time, uterine position, and clinician experience [5]. Rare cases have been reported regarding the Grafenberg ring complications in recent years due to its low usage [2]. The patient in our case did not have routine examinations for economic reason, so the exact timing of the IUD perforation remains unknown. It is speculated that the perforation occurred at the time of insertion. However, a secondary perforation cannot be excluded, due to the fact that she once tried to remove the IUD but failed. In addition, we can't rule out that in the process of pregnancy, the soft and weak uterine wall, and the postpartum uterus contractions may have led to the IUD perforation. A retained IUD after menopause may be also a risk factor leading to

uterine perforation, although the exact mechanism is unclear.

The symptoms of IUD perforation and migration are nonspecific, including abdominal or pelvic pain that varies according to the site of migration and the adjacent organ involved. Sometimes, the symptoms may remain silent for many years [6], but rarely more than 20 years [2]. It is hard to believe the patient in our case had no symptoms for more than 30 years, in which maybe the uterine perforation caused by the disrupted and deformed IUD was relatively small, and part of the IUD entering the

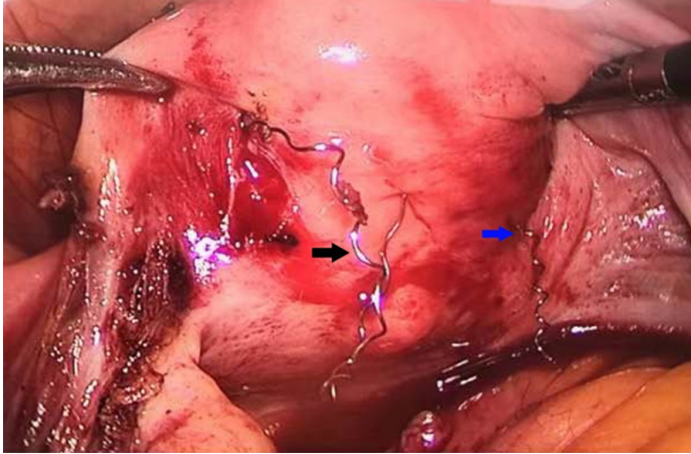


Figure 3. One end of the Grafenberg ring entered the rectum wall (blue arrow), and the other end penetrated the left fallopian tube (black arrow).

rectum did not penetrate the mucosal layer, so there were no intestinal contents flowing into the pelvic cavity, and no symptoms such as pelvic pain occurred. For asymptomatic patients, the diagnosis is unpredicted and accidental. After the IUD insertion, it is important to periodically check to make sure it is still in place. To detect whether there is any perforation, transvaginal ultrasound or plain abdominal radiography should be used.

Once uterine perforation is confirmed, it is recommended to remove the IUD immediately to mitigate the putative life-threatening complications [7], such as bowel strangulation and perforation. A convenient and effective way is via the laparoscopic approach, because it has a low morbidity and minimally invasive. In cases of bowel perforation or the presence of severe sepsis, laparotomy should be considered.

Above all, this case reminds us of the need to maintain a higher level of suspicion of uterine perforation in asymptomatic women after IUD insertion. Once a uterine perforation is confirmed, the preferred treatment for the displaced IUD is to remove it by laparoscopy.

Acknowledgements

We thank our departmental colleagues for their hard work and exemplary guidance throughout the course of this project.

Disclosure of conflict of interest

None.

Address correspondence to: Baorong Gao, Department of Obstetrics and Gynaecology, West China Second University Hospital, Sichuan University, No. 20, Section 3, Renmin Nan Lu, Chengdu, 610041, Sichuan Province, China. Tel: +86-28-88571032; Fax: +86-28-885-71032; E-mail: baorong_gao@163.com

References

- [1] Whaley NS and Burke AE. Intrauterine contraception. *Women's Health (Lond)* 2015; 11: 759-767.
- [2] Chen CH, Liang HS, Chiu LH and Jeng CJ. Broken Grafenberg ring incarcerated in para-ureteral space: a rare case of retained IUD accompanied pregnancy. *Eur J Obstet Gynecol Reprod Biol* 2013; 169: 412-413.
- [3] Wang W and Zhang J. Migration of an intrauterine device into the urethra with calculi formation: a case report. *Int J Clin Exp Med* 2017; 10: 15762-15765
- [4] Zakin D, Stern WZ and Rosenblatt R. Complete and partial uterine perforation and embedding following insertion of intrauterine devices. I. Classification, complications, mechanism, incidence, and missing string. *Obstet Gynecol Surv* 1981; 36: 335-353.
- [5] Sun X, Xue M, Deng X, Lin Y, Tan Y and Wei X. Clinical characteristic and intraoperative findings of uterine perforation patients in using of intrauterine devices (IUDs). *Gynecol Surg* 2018; 15: 3.
- [6] Rowlands S, Oloto E and Horwell DH. Intrauterine devices and risk of uterine perforation: current perspectives. *Open Access J Contracept* 2016; 7: 19-32.
- [7] Markovitch O, Klein Z, Gidoni Y, Holzinger M and Beyth Y. Extrauterine mislocated iud: is surgical removal mandatory? *Contraception* 2002; 66: 105-108.