Int J Clin Exp Med 2021;14(2):1007-1015
www.ijcem.com /ISSN:1940-5901/IJCEM0123797

Original Article

Investigation of ulcer healing, recurrence rate and secondary effect via cinnamyl alcohol foam hardening on patients with varicose veins of lower extremities

Yuhuai Zhou[1], Hongbo Tan[1], Peng Liao[1], Jianjun Li[1], Siyu Liu[1], Xiaolong Li[1], Tianyun Liu[2]

[1]*Department of General Surgery, The First Affiliated Hospital of Shaoyang University, Shaoyang, Hunan Province, China;* [2]*Department of General Surgery, The Central Hospital of Shaoyang, Shaoyang, Hunan Province, China*

Received October 9, 2020; Accepted November 11, 2020; Epub February 15, 2021; Published February 28, 2021

Abstract: Objective: To explore the role of cinnamyl alcohol foam hardening in ulcer healing, recurrence rate and secondary effect on patients with varicose veins of lower extremities. Methods: According to the random number table method, patients with varicose veins of the lower extremities in our hospital were divided into the great saphenous vein high ligation + cinnamyl alcohol foam hardening group (hardening group), including 42 patients; the great saphenous vein high ligation group (ligation group), with a total of 47 patients. The differences in perioperative indicators, secondary effects, postoperative conditions, pain levels, vascular endothelial function indicators (CEC, ET-1, NO), clinical efficacy, and recurrence rate of patients were analyzed between the ligation and hardening groups. Results: The treatment outcome of patients in the hardening group was slightly better than that in the ligation group, but there was no significant difference (χ^2=0.931, P=0.334). Compared with the ligation group, the incision length and intraoperative blood loss in the hardening group were significantly reduced (all P<0.001), however, the operation time was notably increased (P<0.001). Time to get out of bed, ulcer healing time and stays in the hospital were considerably shorter than those in the ligation group (both P<0.001). After treatment, the visual analogy scale scores of the two groups were remarkably lower than those before treatment (both P<0.001), and the pain level in the hardening group was significantly lower than that in the ligation group (P<0.001). Compared with before treatment, CEC, ET-1 and other indicators in the two groups of patients notably decreased (all P<0.001), and the values of CEC and ET-1 and other vascular endothelial function indicators in the hardening group were considerably lower than those of ligation group (all P<0.001). The probability of secondary effects in the hardening group was slightly lower than that in the ligation group, but there was no significant difference (χ^2=1.253, P=0.210). After three months of follow-up, the recurrence rate of patients in the hardening group was slightly lower than that in the ligation group, however, there was no significant difference (χ^2=1.454, P=0.146). Conclusion: Compared with the great saphenous vein high ligation method, the combination of cinnamyl alcohol foam hardening and the ligation demonstrates a better therapeutic effect, which can significantly shorten the incision length, decrease intraoperative blood loss, reduce the pain level of patients, shorten the postoperative stays in the hospital, improve the vascular endothelial function, and reduce the recurrence rate and secondary effects of patients.

Keywords: Cinnamyl alcohol foam hardening, secondary effect, ulcer healing, varicose veins of lower extremities, recurrence rate

Introduction

Varicose veins of lower extremities are a common venous disease in clinical practice, of which the incidence is relatively high among the manual labor population. The initial symptom of this disease is not obvious, which causes it to be overlooked. However, with the disease progression, it will gradually develop into lower extremity edema, darkening of the calf skin, stasis dermatitis, and chronic ulcers in the late stage, which are not easy to be cured, and patients' activities are also restricted, which will cause severe and irreversible influence on patients' daily work [1, 2]. In clinical practice, there are many therapeutic strategies for varicose veins of the lower extremities, such as treatment via elastic bandage, surgery, hardening, and so on. Previously, patients with recurrent varicose veins have been treated with

great saphenous vein high ligation and stripping surgery, which has shown good outcome, however, the surgical trauma is extensive, and postoperative recovery is delayed [3]. In recent years, cinnamyl alcohol foam sclerosant has been gradually applied in the treatment of this disease as a minimal invasive approach, which has obtained some clinical outcomes and received more attentions [4]. Currently, the number of patients treated with great saphenous vein high ligation and stripping surgery combined with cinnamyl alcohol foam hardening has gradually increased, however, the clinical indicators, therapeutic efficacy and secondary effects via combined treatment and/or single treatment have not been studied. Therefore, this study compares the therapeutic effects of two different treatment strategies, cinnamyl alcohol foam hardening and great saphenous vein high ligation in the treatment of varicose veins of lower extremities.

Materials and methods

General information

According to the random number table method, 89 patients with varicose veins of the lower extremities (from January 2017 to December 2019 in The First Affiliated Hospital of Shaoyang University, Shaoyang) were divided into the great saphenous vein high ligation group (ligation group), including 47 patients, and the great saphenous vein high ligation + cinnamyl foam alcohol hardening group (hardening group), containing 42 patients. This study was approved by the Ethics Committee of The First Affiliated Hospital of Shaoyang University, Shaoyang and all patients signed the informed consent.

Inclusion and exclusion criteria

Inclusion criteria: (1) patients with superficial venous swelling, hyperpigmentation and other clinical symptoms; (2) patients diagnosed with unilateral varicose veins [5]; (3) patients with increased diameter of vein, no deep vein thrombosis, and smooth blood circulation; (4) patients informed and agreed to this experiment. Exclusion criteria: (1) patients with deep vein thrombosis and other venous diseases by preoperative angiography; (2) patients with varicose veins due to malignancies; (3) patients who could not clearly describe their status; (4) patients with sclerosis contraindications or allergies.

Therapeutic approaches

Ligation group: patients in this group underwent high ligation of the main great saphenous vein laid flat on the bed. After local anesthesia, a small incision of about 0.5 cm was made from the lower part of the main great saphenous vein of the thigh, 3-5 cm below the inner side of the knee joint of the patients. Around 1 cm lesion vein at the incision was ligated using No. 4 silk thread and sutured with No. 0 silk thread.

Hardening group: patients in this group were treated with cinnamyl alcohol foam hardening on the basis of ligation group patients. The cinnamyl alcohol (1%) and air were mixed in a ratio of 1:4 just before the surgery. After high ligation of the great saphenous vein, lauric alcohol foam sclerosant (5 mL) was infused into the trunk of the vein, and the surgical incision was sutured. Five milliliters of sclerosant was subsequently injected to stop bleeding. Finally, bleeding was drawn back at each puncture point, and then 1.2 mL of sclerosant was injected, by which the total volume of injection was less than 20 mL, and pressure bandage (elastic bandage) was applied after puncture.

Outcome measures

The main observation indices included evaluation of clinical efficacy, pain level, vascular endothelial function, and recurrence rate; secondary observation indicators included perioperative indicators, postoperative recovery, and secondary effects.

Evaluation of clinical efficacy: One week after the treatment, the clinical efficacy of two groups of patients was evaluated [6]. Excellent: the clinical symptoms and manifestations of varicose veins of the lower extremities have all been improved; good: the clinical symptoms have generally disappeared; medium: the clinical symptoms have been significantly improved, the varicose veins have generally disappeared; poor: patients' clinical symptoms have no obvious changes or have shown signs of aggravation on the contrary.

Perioperative indicators: During the treatment, the relevant perioperative indicators (operating

Table 1. Comparison of general information ($\bar{x}$ ± sd)

Factors	Ligation group (n=47)	Hardening group (n=42)	X^2/t	P
Gender			1.303	0.192
Male	31	22		
Female	16	20		
Comorbidity				
Hypertension	12	10	0.021	0.883
Diabetes	11	13	0.167	0.682
Heart disease	9	8	0.059	0.808
Others	15	11	0.061	0.432
Way of working			0.034	0.853
Sedentariness	15	14		
Long station	12	9		
Others	20	19		
Body mass index (kg/cm^2)	20.74±4.09	20.83±4.16	0.102	0.918
Course of disease (year)	9.65±3.80	9.64±3.57	0.012	0.989
Age (year)	52.0±2.6	52.7±3.6	1.095	0.276

time, incision length, and intraoperative blood loss) of patients were observed and recorded in the ligation and hardening groups.

Postoperative recovery: After treatment, the postoperative conditions of the patients in the ligation and the hardening groups were recorded (time to get out of bed, time to heal ulcers, and stays in hospital).

Pain level: Upon hospitalization and 72 hours after the treatment, the visual analogy scale (VAS) score was applied to compare the pain level of the ligation and the hardening groups. The comprehensive score of the VAS was 10, and the higher the score, the higher the pain level.

Vascular endothelial function: Upon hospitalization and 72 hours after the treatment, fasting venous blood from patients in the ligation and the hardening groups were routinely collected. The count of endothelial cell (CEC) was measured by density gradient method. Briefly, the sample was centrifuged at 1,800 r/min for 15 min, the plasma in upper layer was removed and the bottom layer was mixed well with phosphate buffered saline (PBS). Then, centrifugation at 1,300 r/min for 5 min was applied, the supernatant was removed, the lower cell suspension in the blood cell counting well was titrated, and the number of CECs in 9 large squares was counted under a light microscope. This procedure was repeated 4 times to obtain the mean value. The endothelin-1 (ET-1) level was determined by radioimmunoassay, and the ET-1 radioimmunoassay kit was purchased from Freerunze Biological Co., Ltd., China. Basically, the sample was boiled in PBS for 3 min, and 0.5 mL of 1 mol/L glacial acetic acid was added to prepare a homogenate. Then, 0.5 mL of 1 mol/L sodium hydroxide was added via centrifugation at 3,500 r/min for 10 min, by which the supernatant for testing was saved. The ET-1 concentration was measured in plasma and aortic tissue according to the instructions. Nitric oxide (NO) was measured by the Griess method, by which the sample was centrifuged at 3,500 r/min for 10 min to obtain 40 μL of supernatant, and 160 μL of Griess reagent (0.1% naphthalene ethylene diamine, 1% sulfonamide and 5% phosphoric acid solution, freshly prepared before the experiment) was added and then incubated in a 37°C water bath for 20 min to measure the absorbance value and quantify the NO amount.

The occurrence of secondary effects: Twenty-four hours after the treatment, the occurrence of secondary effects of patients such as subcutaneous blood stasis, subcutaneous induration, etc. in the ligation and the hardening groups were recorded and analyzed.

Recurrence: Follow-up was done after 3 months to check the recurrence of patients in the ligation and hardening groups, during which the number of recurrences and the recurrence rate were investigated.

Statistical analysis

The data were processed using SPSS 23.00 statistical software, and the differences regarding perioperative indicators, clinical efficacy, secondary effects, postoperative general conditions, vascular endothelial function, recurrence, and pain in the ligation and hardening groups were analyzed. The quantitative results were presented by the mean ± standard deviation ($\bar{x}$ ± sd), and the paired t test was

Table 2. Comparison of clinical efficacy between the ligation and hardening groups (n, %)

Groups	Excellent	Good	Moderate	Poor	Excellent/good rate
Ligation group (n=47)	22 (46.81)	16 (34.04)	8 (17.02)	1 (2.13)	38 (80.85)
Hardening group (n=42)	28 (66.67)	11 (26.19)	3 (7.14)	0 (0.00)	39 (92.86)
X^2		0.884			0.931
P		0.346			0.334

Table 3. Comparison of perioperative indices between ligation and hardening groups ($\bar{x}$ ± sd)

Groups	Operation time (min)	Incision length (cm)	Blood loss (mL)
Ligation group (n=47)	43.85±8.76	6.16±1.43	45.73±6.56
Hardening group (n=42)	73.63±10.59	3.08±0.59	23.82±5.48
t	14.350	13.001	16.990
P	<0.001	<0.001	<0.001

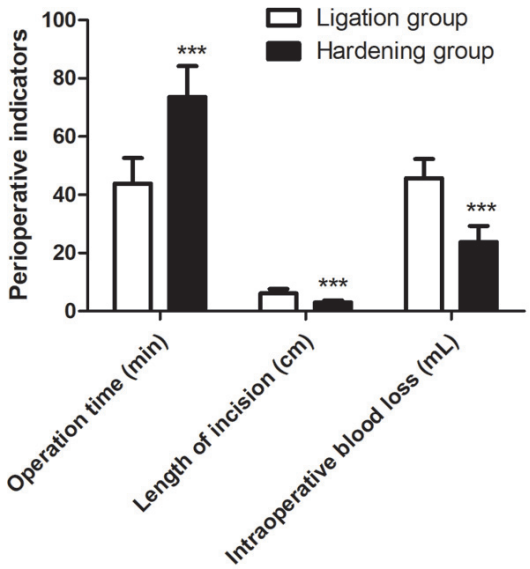

Figure 1. Comparison of perioperative indices between ligation and hardening groups. Compared with the ligation group, ***P<0.001.

carried out for the comparison between groups. The counting data were presented as n (%), and the Chi-square test was utilized for the comparison between groups. P<0.05 indicated the statistically significant difference.

Results

Comparison of general information between the ligation and hardening groups

There was no significant difference in terms of general information between the ligation and the hardening groups (P>0.05; **Table 1**).

Comparison of clinical efficacy between the ligation and hardening groups

As shown in **Table 2**, after treatment, 38 patients in the ligation group were evaluated as excellent and good treatments, and 9 were demonstrated as moderate or poor treatments. In the hardening group, 39 patients were evaluated as excellent or good treatments. The number of patients with moderate and poor results was 3. The treatment outcome of patients in the hardening group was slightly better than that in the ligation group, but there was no significant difference (χ^2=0.931, P=0.334; **Table 2**).

Comparison of perioperative indices between ligation and hardening groups

The results demonstrated that the operation time, incision length, and intraoperative blood loss were 73.63±10.59 min, 3.08±0.59 cm, 23.82±5.48 mL and 43.85±8.76 min, 6.16±1.43 cm, 45.73±6.56 mL in the hardening and ligation groups, respectively. Compared with the ligation group, the incision length and intraoperative blood loss indices were significantly lower in the hardening group (both P<0.001; **Table 3** and **Figure 1**).

Comparison of postoperative recovery of patients in ligation and hardening groups

The results showed that the postoperative conditions such as the time to get out of bed, ulcer healing, and hospitalization days were 2.45±1.21, 31.67±7.86, 9.47±2.45 days and 0.82±0.09, 19.33±3.35, 5.15±1.08 days in the hardening and ligation groups, respectively. The general postoperative conditions of the patients in the hardening group were notably better than those in the ligation group (all P<0.001; **Table 4** and **Figure 2**).

Table 4. Comparison of postoperative recovery of patients in ligation and hardening groups ($\bar{x}$ ± sd)

Groups	Time to get out of bed (d)	Ulcer healing time (d)	Hospitalization days (d)
Ligation group (n=47)	2.45±1.21	31.67±7.86	9.47±2.45
Hardening group (n=42)	0.82±0.09	19.33±3.35	5.15±1.08
t	8.703	9.433	10.540
P	<0.001	<0.001	<0.001

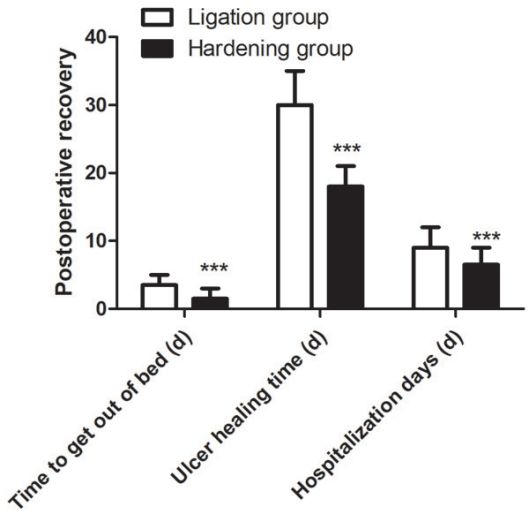

Figure 2. Comparison of postoperative recovery of patients in ligation and hardening groups. Compared with the ligation group, ***P<0.001.

Comparison of VAS scores between ligation and hardening groups

It can be seen from **Table 5** that the pain scores of the patients in the ligation and hardening groups before treatment were 6.58±1.05 and 6.62±1.11, respectively, with a small and insignificant difference (t=0.174, P=0.861). After treatment, the scores of the two groups were 4.64±1.65 and 2.32±0.89, all significantly lower compared with those before treatment (all P<0.001), and the pain level of patients in the hardening group was remarkably lower than that in the ligation group (P<0.001; **Table 5** and **Figure 3**).

Comparison of vascular endothelial function indices between ligation and hardening group

The results revealed that the levels of CEC, ET-1 and other indicators of the ligation group and hardening groups before treatment were slightly different (all P>0.05). After treatment, the CEC and ET-1 levels of the two groups of patients were significantly decreased (P<0.001), and the vascular endothelial function indices such as CEC and ET-1 in the hardening group were considerably lower than those in the ligation group (P<0.001; **Table 6** and **Figure 4**).

Comparison of secondary effects between patients in ligation and hardening groups

Table 7 demonstrated that a total of 8 patients in the ligation group had secondary effects, accounting for 17.02%, and a total of 3 patients in the hardening group showed secondary effects, accounting for 7.14%. The incidence of secondary effects in the hardening group was slightly lower than that in the ligation group, but there was no significant difference (χ^2=1.253, P=0.210; **Table 7**).

Comparison of recurrence rate between ligation and hardening groups

After three months of follow-up, the results showed that there were 5 patients with lower extremity varicose veins in the ligation group, and the recurrence rate was 10.64%, while the hardening group had 1 patient with lower extremity varicose veins, and the recurrence rate was 2.38%. The recurrence rate of patients in the hardening group was slightly lower than that in the ligation group, but there was no significant difference (χ^2=1.454, P=0.146).

Discussion

Varicose vein of the lower extremities is a common venous disease occurred in lower limbs, affecting approximately 50% of adults. If not treated in time, it will cause great impact on the patients, possibly leading to thrombotic superficial phlebitis and venous ulcers. At the same time, this disease is characterized by a high recurrence rate that impedes the treatment after relapse [7]. Studies have shown that there are many causes of the disease. After the occurrence of varicose veins in the lower extremities, it can result in excessive increase of total blood volume, heaviness and swelling in the lower extremities, slowing down the venous blood flow, prolonging blood circulation

Table 5. Comparison of VAS scores between ligation and hardening groups ($\bar{x}$ ± sd)

Groups	Before treatment	After treatment	t	P
Ligation group (n=47)	6.58±1.05	4.64±1.65	6.800	<0.001
Hardening group (n=42)	6.62±1.11	2.32±0.89	19.590	<0.001
t	0.174	8.115		
P	0.861	<0.001		

Note: VAS: visual analogy scale.

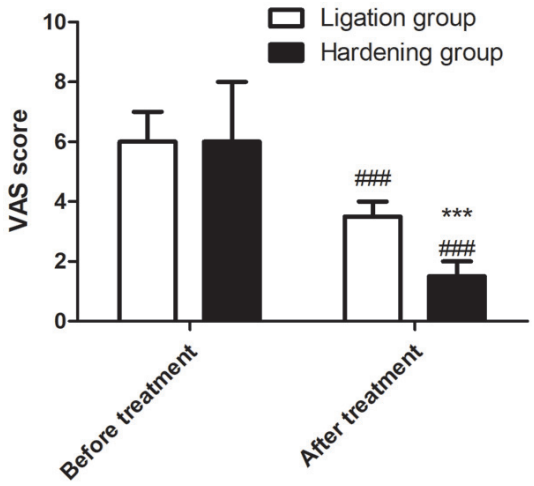

Figure 3. Comparison of VAS scores between ligation and hardening groups. Compared with the ligation group after treatment, ***P<0.001; compared with the same group before treatment, ###P<0.001. VAS: visual analogy scale.

time to a large extent, and ultimately pathological changes in terms of the nutrition of the lower extremities and the skin and soft tissues, which could cause venous inflammation or thrombosis and may also be accompanied by symptoms such as eczema, skin itching, etc., requiring timely surgical treatment [8]. However, some patients demonstrate the recurrence of this disease after treatment. Related statistical analyses have shown that the postoperative recurrence rate of patients with superficial varicose veins of lower extremities is as high as 21%, which greatly hinders the treatment. Therefore, more reasonable and effective treatment strategies to optimize the surgery and reduce the recurrence rate are of concerns in the clinical practice.

Great saphenous vein high ligation is a traditional clinical method with curative effects for the treatment of patients with varicose veins of the lower extremities. However, the operation of this approach can easily cause large injuries. In addition, the relatively long incision significantly increases blood loss and pain in patients, which is not beneficial for postoperative recovery. Meanwhile, residual communicating veins can increase the risk of disease recurrence [9]. The results in this paper demonstrate that the treatment efficacy in the hardening group is slightly better than that of the ligation group; the perioperative indices of patients in the hardening group are significantly lower than those in the ligation group; and the postoperative recovery of patients in the hardening group is significantly better than that in the ligation group. Before treatment, the pain score, CEC, ET-1 and other vascular endothelial function indicators of patients in the ligation and the hardening groups were similar, however, after treatment, the pain level of patients in the hardening group was significantly lower than that of the ligation group. After treatment, the CEC and ET-1 indices of the two groups of patients were significantly decreased, and compared with the hardening group, the CEC and ET-1 indices of the hardening group were considerably lower than those of the ligation group; the incidence and recurrence rate of secondary effects in the hardening group are slightly lower than those in the ligation group. Studies have shown that cinnamyl alcohol foam sclerosant is a hardening treatment approach, among which cinnamyl alcohol is a membrane active compound that mainly functions on the membrane lipids of epidermal cells and induces venous endothelial damage, thereby causing vascular endothelial cells to fall off, which accelerates thrombosis, and blocks blood vessels [10]. The cinnamyl alcohol foam sclerosant mainly mixes a right amount of air with cinnamyl alcohol to produce micro-foam and to play a gas embolism effect. At the same time, it has no effect on blood flow movement and does not damage skin cells. Studies have illustrated that the disease condition of patients with great saphenous veins undergoing high ligation of the main trunk of the veins was under control. After the surgery, patients who have been injected with cinnamyl alcohol foam sclerosant have shown a significantly faster recovery rate, and postoperative complications are significantly reduced, which

Table 6. Comparison of vascular endothelial function indices between ligation and hardening group ($\bar{x}$ ± sd)

Time	CEC (cells/L)	ET-1 (ng/L)	NO (μmol/L)
Before treatment			
Ligation group (n=47)	6789.25±1975.33	75.14±10.25	1.17±0.34
Hardening group (n=42)	6802.14±1876.34	75.68±9.68	1.16±0.35
t	0.031	0.254	0.136
P	0.974	0.799	0.891
After treatment			
Ligation group (n=47)	3951.02±652.13###	49.35±6.51###	0.87±0.21###
Hardening group (n=42)	1245.05±241.32###	21.05±4.48###	0.49±0.11###
t	25.370	23.610	10.510
P	<0.001	<0.001	<0.001

Note: CEC: count of endothelial cell; ET-1: endothelin-1; NO: Nitric oxide. ###P<0.001, compared with the same group before treatment.

indicates that this therapeutic approach has a decent effect on varicose veins [11, 12]. Clinical data have suggested that the use of cinnamyl alcohol foam sclerosant can promote the occlusion of the great saphenous vein in patients with varicose veins of the lower extremities, thereby effectively reducing the degree of surgical trauma and intraoperative blood loss, and helping to accelerate the postoperative recovery process [13, 14]. Studies have shown that cinnamyl alcohol foam sclerosant can effectively inhibit the development of varicose veins and has a certain promoting effect on the treatment of varicose veins of the lower extremities to reduce the recovery time of patients after surgery [15]. Studies have also reported that the great saphenous vein high ligation can avoid the occurrence of femoral saphenous vein valve insufficiency, and the combination of cinnamyl alcohol foam sclerosant can significantly reduce the risk of recurrence, effectively prevent the foam cinnamyl from returning to the deep veins, and avoid the entry of thrombus femoral vein to prevent complications such as pulmonary embolism [16, 17]. Chen et al. have shown that the use of cinnamyl alcohol foam hardening has a significant therapeutic effect in patients with varicose veins. The trauma and the impact on the patients are minor, which could significantly reduce blood loss and shorten the surgery and the length of incision. Additionally, the postoperative recovery is faster and the therapeutic effect is reliable, without severe postoperative complications such as obvious scars [18]. Zhu et al. have shown that ligation combined with foam hardening can completely ligate the communicating veins of patients with varicose veins, by which the curative effect is accurate and the operation is simple, which blocks the abnormal blood flow on the ulcer surface, improves the patients' clinical symptoms, and effectively prevents the occurrence of deep vein thrombosis [19]. Shan et al. have demonstrated that ultrasound-guided foam hardening treatment can significantly improve clinical effectiveness, significantly improve vascular endothelial function, and have revealed a better prognosis [20]. Zhang et al. have investigated that intracavitary laser combined with foam hardening could improve the treatment of varicose veins of lower extremity, reduce complications, and improve the patients' blood hypercoagulability and vascular endothelial function [21]. Zhe et al. have shown that patients with varicose veins in the lower extremities have vascular endothelial cell damage, and the changes of CEC, ET-1 and NO values in peripheral blood before and after laser surgery contribute to the evaluation of clinical efficacy [22]. Li et al. have suggested that the use of acupuncture to treat varicose veins of the lower extremities can effectively improve blood rheology, endothelial cell function, and the quality of life [23].

There are some caveats in this study. Due to the budget, a comprehensive physical examination was not performed on all participants. It cannot be ruled out that other factors such as changes in the level of vascular endothelial function caused by other diseases could also contribute to the results. Due to the short period of time, the number of patients with varicose veins of the lower extremities in this hospital was small, and the number of selected trials was not enough (a larger number of trials should be included for the comparison of secondary effects), which may lead to the result bias. Fewer treatment methods were applied in our research, which makes it impossible to compare the results in parallel. Other strategies such as percutaneous continuous circular suture of superficial vein, intracavitary laser,

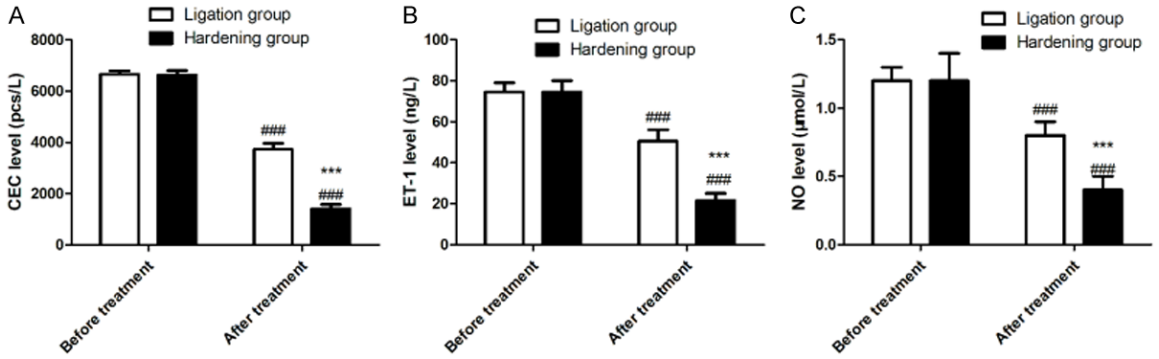

Figure 4. Comparison of vascular endothelial function indices between ligation and hardening group. A. Comparison of CEC levels in the two groups of patients. B. Comparison of ET-1 levels in the two groups of patients. C. Comparison of NO levels in the two groups of patients. Compared with the ligation group after treatment, ***P<0.001; compared with the same group before treatment, ###P<0.001. CEC: count of endothelial cell; ET-1: endothelin-1; NO: Nitric oxide.

Table 7. Comparison of secondary effects between patients in ligation and hardening groups (n, %)

Groups	Numbness of lower limbs	Skin pigmentation	Subcutaneous stasis	Subcutaneous induration	Incidence
Ligation group (n=47)	2 (4.26)	3 (6.38)	2 (4.26)	1 (2.13)	8 (17.02)
Hardening group (n=42)	0 (0.00)	2 (4.76)	1 (2.38)	0 (0.00)	3 (7.14)
X^2	1.753	0.098	0.223	0.884	1.253
P	0.185	0.753	0.636	0.346	0.210

etc. can be considered in the future studies, which could provide more comprehensive experimental support for the treatment of patients with varicose veins of lower extremities.

In conclusion, compared with the great saphenous vein high ligation method, the combination of the cinnamyl alcohol foam hardening and ligation has a better therapeutic effect, which can significantly shorten the incision length, decrease intraoperative blood loss, reduce the pain level of patients, shorten the postoperative hospital stays, improve the vascular endothelial function, and reduce the recurrence rate and secondary effects of patients.

Acknowledgements

This work was supported by the Scientific Research Project of Hunan Provincial Department of Education (18C0795).

Disclosure of conflict of interest

None.

Address correspondence to: Tianyun Liu, Department of General Surgery, The Central Hospital of Shaoyang, No. 36 Qianyuan Street, Daxiang District, Shaoyang 422000, Hunan Province, China. Tel: +86-13973599830; E-mail: 254145303@qq.com

References

[1] Zhao MP, Han XQ, Wang WM, Chen G, Sheng YG and Wu J. Efficacy analysis of one-stop hybrid operation on iliac vein compression syndrome combined with lower extremity varicose veins. Chin J Interv Radiol (Electr Ed) 2019; 43: 43-47.

[2] Guo XK, Cui HP and Wen XP. Treatment of varicose veins of lower extremity: a literature review. Int J Clin Exp Med 2019; 12: 2142-2150.

[3] Pan YQ, Li Y, Mao JQ, Li K and Gan SJ. Subfascial endoscopic perforator surgery combined with endovenous laser ablation in treatment of lower extremity varicose veins. Surg Theory Prac 2018; 23: 539-541.

[4] Huang TD. Management of varicose veins of lower extremity by the TriVex minimally invasive system. J Vasc Endovasc Surg 2019, 5: 293-295.

[5] Zhang JJ and Song JL. Effect of postoperative combined nursing for patients with lower extremity varicose veins of deficiency of both qi and blood. Lab Med Clin 2018; 43: 1025-1027.

[6] Yu WS, Liu J, Yang HW, Wang ZH, Xia YD, Liu PJ and Zhu GX. Application of the Trivex system in

the treatment of primary severe superficial varicose veins of the lower extremity. J Interv Med 2019; 2: 146-149.
[7] Katsushi O. Study of tributary varices laser ablation using a radial 2ring fiber in patients with varicose veins of lower extremity. JA J Phlebol 2019; 30: 27-31.
[8] Depopas E and Brown M. Varicose veins and lower extremity venous insufficiency. Semin Interv Radiol 2018; 35: 56-61.
[9] Zhou MF and Song JM. Efficacy of polyocaine foam sclerosing agent combined with high saphenous vein ligation in treatment of varicose veins of great saphenous vein. Guizhou Med J 2018; 42: 73-74.
[10] Chen JH, Zhu PJ, Ren Y, Xiong HL, Liu L, Hu Y and Wang YX. Evaluation of the curative effect of injection of lauric alcohol foam sclerotherapy through medial malleolus puncture cannula in the treatment of varicose veins of lower extremities. J Pract Radiol 2018; 18: 76-79.
[11] Li GW, Gu SZ, Huang MP, Huang B, Xiong ZP and Tang T. Lauromacrogol foam sclerotherapy for the treatment of venous malformations: evaluation of its curative effect and safety. J Interv Radiol 2018; 27: 680-684.
[12] Sun SL, Zhang F, Wang X, Wang L, Li Y and Zhang XL. Study on foam sclerosing agent combined with high ligation of great saphenous vein in treatment of varicose vein of lower extremity. Syst Med 2018; 3: 87-89.
[13] Wang J, Qian SG, Bai XG and Zhu ZH. Evaluation of the therapeutic effect of DSA guided foam sclerotherapy in the treatment of varicose veins of lower extremity with ulcer. J Chin Clin Med Imaging 2018; 98: 754-765.
[14] Zhang YC, Zhang YM, Wu XG, Ying XX, Hu YX, Chen XZ and Zhu RW. Efficacy of radiofrequency ablation combined with foam sclerotherapy and punctate stripping in the treatment of varicose veins of great saphenous vein. Zhejiang Med J 2018; 40: 2155-2157.
[15] Ning JG. Application of sclerosing foam injection and high ligation of great saphenous vein in treatment of lower extremity varicose vein. Chin Med Eng 2018; 56: 55-65.
[16] Zhu YQ, Wu DQ, Sun DH, Song K, Li J and Lin J. Clinical effect of ultrasound combined with fluoroscopy guided foam sclerotherapy in the treatment of venous ulcers of the lower extremities. J Interv Radiol 2019; 13: 934-937.
[17] Lu F. Treatment of 35 cases of varicose veins of lower extremity with small incision saphenous vein high ligation and stripping combined with percutaneous superficial vein continuous annular suture. Syst Med 2019; 33: 89-97.
[18] Chen J, Yang YH, Fan B and Tang J. Effect contrast of foam sclerotherapy of lauromacrogol and high ligation of great saphenous vein for varicose vein of lower extremity. China Med Her 2015; 32: 77-80.
[19] Zhu YQ, Xu JX, Chen JY, Wu Y, Zhang CH and Li L. The clinical efficacy observation of fluoroscopy-guided foam sclerotherapy with lauromacrogol for varicose veins of the lower extremities. Chin J Radiol 2012; 46: 836-839.
[20] Shan SY, Yuan P, Yue TH, Wu S, Wu JD and Huang XC. The effect of ultrasound-guided lauric alcohol foam sclerotherapy on the peripheral blood CEC, ET-1 and NO values of patients with varicose veins. J Cardiovasc Rehabil Med 2019; 34: 32-34.
[21] Zhang Y and Su MN. Combined curative effect of intracavitary laser and foam hardener on varicose veins of lower limbs and its influence on hypercoagulability and vascular endothelial functions. Chin J Laser Med Surg 2019; 32: 272-277.
[22] Zhe FT, Zeng J, Wang CX, Han LN, Gu Y and Wang XL. Alteration of vascular endothelial function in patients with simple leg varicosity after laser treatment. Chin J Laser Med Surg 2015; 24: 1-4.
[23] Li SH, Li B, Tang JR, Zhu AL, Dai ZW and Chen WZ. Effect of acupuncture on hemorheology, endothelial cell function and quality of life in patients with varicose veins of lower limbs. Shenzhen J Integr Tradit Chin and West Med 2017; 27: 51-52.